



<https://www.biodiversitylibrary.org/>

Philosophical transactions of the Royal Society of London

London, Royal Society of London, [1666]-1886

<https://www.biodiversitylibrary.org/bibliography/62536>

v.157 (1867): <https://www.biodiversitylibrary.org/item/232766>

[illegible]

Holding Institution: Natural History Museum Library, London

Sponsored by: Natural History Museum Library, London

This page intentionally left blank.

XIX. *Contribution to the Anatomy of Hatteria* (Rhynchocephalus, OWEN).

By ALBERT GÜNTHER, M.A., Ph.D., M.D. Communicated by Professor OWEN, F.R.S.

Received April 4,—Read May 2, 1867.

THE remarkable Saurian which forms the subject of this memoir, appears to have been first mentioned in a diary by Mr. ANDERSON, the companion of Captain COOK, to whom “a monstrous animal of the lizard kind” was described by the two New Zealand boys who joined the expedition whilst staying in Queen Charlotte’s Sound (COOK’s Third Voyage, 2d edit., 1785, vol. i. p. 153). POLACK (New Zealand, 1838, vol. i. p. 317) speaks of it as a creature well known to the settlers. “The gigantic lizard or guana exists principally in the island of Victoria. Some are found in the isles of the Bay of Plenty. The natives relate ogre-killing stories of this reptile, but doubtless it is harmless.”

Dr. DIEFFENBACH has the merit of having first made us acquainted with it. In his ‘Travels in New Zealand,’ vol. ii. (1843) p. 205, he has the following notes:—“I had been apprized of the existence of a large lizard, which the natives called Tuatera, or Narara, with a general name, and of which they were much afraid. But although looking for it at the places where it was said to be found, and offering great rewards for a specimen, it was only a few days before my departure from New Zealand that I obtained one, which had been caught at a small rocky islet called Karewa, which is about two miles from the coast, in the Bay of Plenty. From all that I could gather about this Tuatera, it appears that it was formerly common in the islands; lived in holes, often in sand-hills near the sea-shore; and the natives killed it for food. Owing to this latter cause, and no doubt also to the introduction of pigs, it is now very scarce; and many even of the older residents of the islands have never seen it. The specimen from which the description is taken I had alive, and kept for some time in captivity; it was extremely sluggish, and could be handled without any attempt at resistance or biting.”

This specimen was presented by DIEFFENBACH to the British Museum, where it still is—in the most perfect state of preservation. Dr. GRAY recognized it at once as the type of a distinct genus, which he characterized in the ‘Zoological Miscellany,’ March 1842, p. 72, referring it to the family of *Agamidae*, and naming it *Hatteria punctata*. The same diagnosis is republished in the ‘Catalogue of Lizards,’ 1845, p. 249; and an excellent figure of the entire animal was given in the ‘Zoology of the Erebus and Terror,’ together with a drawing of the skull* exhibiting its general configuration. Unfortunately no letterpress accompanies this figure.

* This skull is still in the British Museum. Mr. FORD has introduced into this drawing an erect process of the lower jaw, just below the tympanic condyle; this, however, is merely the remainder of a dried ligament.

About that period several other examples or parts of such reached England: the British Museum received four (adult and young) from Dr. F. KNOX, Captain DRURY, and the Collection of Haslar Hospital. Sir A. SMITH obtained two living specimens, which he kept for some time; and finally the Royal College of Surgeons came into possession of a skull and some vertebræ, by which Professor OWEN was enabled to point out some of the peculiarities which render this lizard so highly interesting (*Rhynchocephalus*, in Trans. Geol. Soc. vol. vii., 1845, p. 64, pl. 6, figs. 5-7 (skull), and in Catal. Osteol. Ser. Collect. Roy. Coll. of Surg. vol. i., 1853, pp. 142, 143).

No other specimen appears to have reached Europe; indeed, as far as I am aware, no Museum out of England appears to possess *Hatteria*. French Herpetologists do not even mention it; STANNIUS appears to have overlooked Professor OWEN's observations. Evidently restricted in its distribution, exposed to easy capture by its sluggish habits, esteemed as food by the natives, pursued by pigs, it is one of the rarest objects in zoological and anatomical collections, and may one day be enumerated among the forms of animal life which have become extinct within the memory of man.

I may be allowed to pass over a detailed description of the *external* characters of *Hatteria*, which are sufficiently known from the diagnosis and figure given by Dr. GRAY (*loc. cit.*).

The Skull (figs. 1-7)*.

The *occipital* arch is distinguished by its unusual shortness, the basioccipital being, on its lower surface, only 5 millims. long†. The foramen occipitale has the not very usual appearance of being higher than broad; more than one-third of its circumference is formed by the superoccipital, the exoccipitals‡ contributing but little to the formation of the condyle, which in our specimen is of the usual width, not broader than in *Monitor*, *Iguana*, *Grammatophora*, *Crocodylus*. The superoccipital is raised into a short mesial crest, entirely separate from the superstructure of the parietal. The exoccipital (*a*) (most closely united with the alisphenoid, *b*) is dilated and swollen at its base to receive the acoustic cavity, and emits its lateral process in an oblique but only slightly backward direction. This process is styloid, though strong, deeply grooved below along its entire length, to receive the long stapes (*c*); it is strengthened by a paroccipital (*d*), which covers nearly the entire side of the process, and is united with the occipital part by only partly distinct sutures.

The *basisphenoid* is comparatively long, the posterior pair of hypapophyses (*e*) (tubercles for insertion of the musculus rectus capitis anticus) being in close proximity to the occipital condyle, but rather remote from the anterior pair (*f*) for the articulation of the pterygoids). The brain-capsule being much compressed, the *parietal* bone (*g*) is very narrow, and elevated into a strong mesial crest, which, although appearing simple in an individual

* The figures in this Paper refer to Plates XXVI., XXVII., and XXVIII.

† As I shall have occasion to give the dimensions of some parts of the skull in millimetres, I must remark that the description is taken from a skull 57 millims. long (between end of premaxillary and occipital condyle) and 47 millims. broad (between the outer surfaces of the tympanic bones).

‡ The sutures between these bones are so indistinct that they could not be represented in the drawing.

of advanced age, evidently consisted of two lateral halves in youth, and which diverges into two slight arched ridges in front, running across the posterior part of the postfrontals, and into two blade-like processes behind. Each of the latter joins a portion of the mastoid (*h*), forming the parieto-tympanic bars; but, whilst in other Lizards (*Iguana*, *Varanus*) the parietal process forms the predominant portion of this bar, in *Hatteria* it is comparatively short, and far surpassed in extent by the mastoid portion. This bar is also much less backwardly directed than in other Lizards, being nearly at right angles with the parietal crest. The fontanelle in front of the sagittal suture, present in many but not in all Lizards, is also present here; it is entirely within the parietals, although these bones are, at this place, overlapped by the frontals and postfrontals.

The *frontal* bones are united by a distinct suture; they are narrow, elongate, tapering in front and behind, forming but a small part of the orbit; a very distinct groove runs along their lower edge for the reception of the olfactory nerve. *Nasal* bones large, trapezoid, forming the greater part of the upper surface of the snout, the nasal openings being entirely lateral and of rather inconsiderable width.

The prefrontal (*i*) is narrow, with the outer margin nearly straight, not forming a projection in front of the orbit; on the inner upperside of the orbit it extends backwards to its middle, but does not reach so far on the upper surface of the skull; below it terminates as soon as it reaches the maxillary and palatine, covering the lacrymal (*k*) entirely, so that, of the latter bone, a small part only, above the ascending branch of the maxillary, is visible.

We have now arrived at a portion of the skull which differs remarkably from that of other lizards, the homologies of which have been differently interpreted by authors, and which, therefore, deserves our particular attention—viz. the bones intercalated between the frontals and maxillary on one side, and the quadrate bone on the other. These bones form in *Hatteria* a vertical orbital bar which is connected by an upper (temporal) and lower (zygomatic) horizontal bar with the os quadratum. In all other Lizards (as far as they have been examined at present) the lower bar is absent, in some of them (Geckos) also the upper; and, again, in others (*Varanus*) even the orbital ring is incomplete, whilst in Crocodiles we find the same arrangement as in *Hatteria*. The bones composing these bars are the following:—

1. The postfrontal (*l*) has a considerable extent, forming the hinder part of the roof of the orbit, and extending backwards to the commencement of the parietal crest; therefore it participates, at least externally, in the formation of the brain-capsule; its posterior portion is crossed by an arched ridge. It is united by a suture with

2. A three-branched bone (*m*), the upper branch of which contributes to the formation of the upper part of the orbit; the second is directed backwards, forming one half of the temporal bar; and, finally, the lower descends to the zygomatic, to complete the orbital ring.

3. The temporal bar is completed by a portion of the mastoid (*h*), a branch of which descends along the anterior outer edge of the quadrate bone.

4. The zygomatic (*n*) is much developed; it emits one process to meet the lower branch of bone *m*, and a second to the os quadratum (*o*), forming the lower horizontal bar.

As regards the second of the bones described (*n*), it is evidently the same which we find more or less separate from the postfrontal, and forming part of the temporal bar, in Lizards generally. It is described by STANNIUS (Vergl. Anat. Wirbelth. vol. ii. p. 159) as *os quadrato-jugale*; but from the way in which he speaks of this bone as being found, "in most Saurians and the Crocodiles, connected with the os zygomaticum and frontale posterius," and as "constantly reaching the tympanic," it is evident that he confounded* the temporal bar of the Lizards with the zygomatic bar of Crocodilians, and the bone in question with the squamosal of Crocodilians (see CUVIER, Oss. Foss. vol. v. pl. 3. fig. 1, *p*, or OWEN, Anat. Vertebr. vol. i. p. 145, fig. 95, bone marked 27). The squamosal, as it exists in Crocodilians, belongs to the lower, zygomatic bar, and completes the connexion between the zygomatic and quadrate bones; this squamosal is absent in Lizards generally, and also in *Hatteria*, where the zygomatic is in immediate connexion with the quadrate. On the other hand, the bone, more or less closely attached to the postfrontal in Lizards, does not exist in the Crocodile as an independent bone, the postfrontal entering into direct sutural connexion with the mastoid (temporal bar) and with the zygomatic: but from the position and form of the Crocodile's postfrontal it is perfectly clear that this bone of Lacertians is nothing but a detached portion of the postfrontal; and for such it has been taken by CUVIER, at least in *Iguana* (Oss. Foss. vol. v. pl. 16. fig. 23, *i*); in *Monitor* and *Varanus* it is also present, although its sutural connexion with the postfrontal has been left unnoticed by CUVIER; in *Grammatophora* it is absent. Professor OWEN does not describe it as a separate bone (Osteol. Catal. vol. i. p. 663, or Anat. Vertebr. vol. i. p. 154), but mentions it as a continuous portion of the postfrontal†.

HOLLARD, who has made researches into the developments and homologies of these bones, has come to the conclusion that the bone considered by CUVIER to be the mastoid in Reptiles and Fishes, is in fact the squamosal. A comparison of the skull of the Crocodile with that of *Hatteria* seems to support this view, inasmuch as CUVIER's "partie écaillée du temporal" of Crocodiles appears merely as a segment of the zygomatic‡, with which it is reunited in *Hatteria*.

Very remarkable is the form of the *os quadratum* (*o*) and its junction with the hind part of the pterygoid (*r*); both bones are much dilated, forming a vertical plate composed of two laminae, the laminae being immoveably united by suture, the quadrate being the anterior plate, the pterygoid the posterior. This sutural kind of union appears to be unique among Lizards, which have those two bones united by a joint allowing of mobility to a more or less considerable extent. The condyle of the quadrate has a deep

* This view is maintained also in the 2nd edition, pp. 52 and 57.

† It must be mentioned that RATHKE (Untersuchungen über die Entwicklung der Crocodile, 1866, p. 33) does not appear to have observed a division of the postfrontal into two parts in embryos of an Alligator.

‡ RATHKE (*loc. cit.* p. 34) has found it and the zygomatic in an equally advanced state of ossification whilst the tympanic was still nearly entirely cartilaginous.

depression across its middle : and there is a very singular wide foramen above the condyle ; it is filled with loose cellular tissue.

The *columella* (*p*) arises from above the suture between the pterygoid and quadrate bones ; it differs in its form from that of other Lizards, being very broad (8 millims.), spatulate at its upper and lower ends, and constricted in the middle. Being fixed by an irregular suture to the pterygoid and quadrate, and attached to the parietal by a narrow strip of cartilage, it contributes materially to the solidity and immoveability of the pterygo-tympanic arch. A crescentic space between alisphenoid and columella remains cartilaginous ; and the fore part of the cranial cavity is closed by fibro-cartilaginous membrane without a trace of ossification.

The *maxillo-palatal* portion of the skull offers no less peculiarities than the parts described before. The *intermaxillaries* are paired ; their posterior portion is tapering and wedged in between the nasals ; there is no discontinuity of the osseous substance whatever on the upperside of the snout, the nostril being entirely lateral ; the fore part of the nasal opening is formed by the intermaxillary. This bone resembles in some measure that of a Rodent, each half being armed with an extremely strong incisor as broad as the bone to which it is anchylosed. The horizontal part of the *maxillary* is extremely narrow, reduced to a simple although strong alveolar ridge ; its ascending nasal process is (with the nostril) much advanced forwards, in the anterior third of the bone. The foramina maxillaria superiora are present as in other Lizards.

The *vomer* (*q*) is paired, each half being of an elongate triangular shape, broader behind than in front ; it forms nearly entirely the inner edges of the choanæ, and its posterior extremity is even behind their level. Most singularly it is in immediate contact with the front part of the pterygoids (*r*)*, which thus prevent the palatines (*s*) from reaching the median line of the palate.

The *palatine* bones (*s*) are entirely separate from each other, each being closely united by suture to the posterior two-thirds of the maxillary ; and being armed along its maxillary margin with a series of teeth similar and parallel to that of the maxillary, the two series are in close proximity, so as to give to the maxillary the appearance of having a double dentigerous ridge. The inner part of the palatine is unusually broad, participating but little in the formation of the choana, from which it is shut out by the vomer, but forming about one half of the bottom of the orbit, which is rendered almost completely osseous by the accession of the pterygoid, zygomatic, and os transversum.

The *pterygoid* bones (*r*) are suturally connected with the vomer, separated in the middle by a comparatively narrow cleft, *meeting again* where they are immovably joined to the basisphenoid processes (*f*) which are close together, and finally *suturally* attached to the quadrate bone as described above. They are toothless, but traversed in their middle

* The perfect preservation of the sutures in a specimen prepared by myself has enabled me to point out this very unusual arrangement of the bones of the palate. Professor OWEN designated, in *Rhynchocephalus*, these bones according to the position usually occupied by them in Lizards, viz. the front part of the pterygoid as palatines, and the palatines as palatal plates of the maxillary.

by a low, sharp ridge, the two ridges converging behind. The process for the attachment of the ectopterygoid (*t*) is unusually long, rectangular at the base; two of the branches of the ectopterygoid receive this angular process between them.

Before I pass to the description of the remaining part of the skull, the mandible, I may be allowed to notice the appearance of the *palate* whilst covered with the soft parts and the mucous membrane. Corresponding to the interpterygoid vacuity in the skull, there is a longitudinal arrow-shaped deep depression in the median line of the palate, commencing on a level with the hinder end of the palatine teeth. This depression is generally widened behind in Lizards, or at least continuous with the plane of the base of the skull; but in *Hatteria* it is entirely closed behind, in consequence of the proximity of the hypapophyses of the basisphenoid. Another, small but very deep, recess exists immediately behind the palatine series of teeth, in front of the long styliform process of the pterygoid and ectopterygoid. The boundary between palatine and pterygoid is marked by a slight ridge of the mucous membrane, nearly corresponding to the suture between those two bones; this ridge runs forward to the inner hinder angle of the choana; and posteriorly it is arched outwards, to form the gingival fold of the palatine series of teeth; it is split into two folds in front of this series, one to accompany the alveolar edge of the maxillary, whilst the other runs along the outer margin of the choana, which can be nearly entirely covered or closed by it. The choanæ are rather narrow slits not extending backwards to the palatine teeth. The auditory recess is rather shallow, eustachian tubes being absent with the tympanic cavity.

The symphysis of the *mandibles* is formed by a fibrous ligament allowing of some mobility; the persistent cartilage of Meckel is entirely replaced by fibrous tissue near the symphysis*. A part of the sutures between the bones of which the lower jaw of Lizards is generally composed have entirely disappeared (if they ever existed), so that the following bones only can be distinguished. The *dentary* (*u*) forms nearly entirely the outer surface of the mandible, a comparatively small articular portion and the top of the coronoid process excepted. The foramina mentalia vary in number from two to four, and are small. There is a very distinct foramen between the dentary and articular, penetrating to the inner surface of the mandible; it is identical with the large vacuity of the lower jaw of the Crocodile, and very indistinct or entirely closed on the outer surface in the Lizards. The *splénial* (*v*) is narrow elongate, behind twisted downwards to the lower side of the mandible and terminating about 3 millims. from its extremity. The *coronoid* (*x*) is triangular, covering with one angle the cartilage of Meckel, and forming with another the coronoid process. The *articular* bone (*w*) is very peculiar: if an angular bone was present at an early age, it has now entirely coalesced with the splénial, there being scarcely any osseous projection behind the articular surface†. The articular

* Indeed *Heloderma* appears to be the only Lizard in which this cartilage forms the symphysis (Troschel, Wieg. Archiv, 1853, p. 301).

† In *Grammatophora*, *Monitor*, and in a great number of Lizards the angular bone projects far beyond the articular surface, frequently turned upwards in an oblique direction. Two muscles arise from this projection,

surface itself does not correspond in form with the condyle of the quadrate bone, being much elongate in the direction of the longitudinal axis of the body, and, in fact, nearly four times as long as the opposite articular surface.

When the jaws are closed, the upper condyles rest on the hindmost part of the lower articular surface; but when in action, the lower jaw can be moved *backwards* to a considerable extent, the condyles advancing to the front part of the joint. As the upper condyles are concave, moving on a longitudinal convexity of the lower surface, they cannot escape sideways, but press the hind part of the mandibles outwards; this again would not be possible, if the mandibles were anchylosed at the symphysis; so that their ligamentous junction finds now its explanation in the peculiar structure of the maxillary joints. When the jaws are at rest, the distance between the posterior extremities of the mandibles is 28 millims.; when the lower jaw is drawn backwards, the distance is 34 millims. It is evident that this structure is connected with the mode of feeding of this animal, which leads us next to a description of its dentition.

Dentition (figs. 8–15).

Dentition of full-grown specimens.—*Hatteria* is an acrodont in the strictest meaning of the term, the teeth being so intimately anchylosed with the cutting alveolar edge of the maxillary and palatine, as to appear mere prominences of these bones. *The alveolar edges themselves are highly polished like the teeth, and perform the function of teeth* when these are ground down to the edge in advanced age. This, however, is not the case with the premaxillaries, each of which is armed with a single broad smooth tooth, notched at the crown in individuals of middle age (fig. 9); this notch disappears when the tooth is somewhat ground down (fig. 8), and the teeth have then the appearance of the upper incisors of a Rodent. The teeth of the maxillary and palatine (figs. 2 & 4) are rather short, triangular, pointed, longitudinally compressed; there are originally about eighteen in each maxillary, and eleven in each palatine. However, those of the anterior half of the maxillary appear to be soon ground down to the alveolar edge, with the exception of one midway between incisor and first palatine tooth, a trace of which is visible in the oldest example examined*. From the level of the first palatine tooth, the maxillary teeth are persistent, although more worn than those of the palatine. The

the outer of which is the *M. digastricus*, generally very distinctly separated into two portions; the inner is a simple short supplementary muscle. In *Hatteria*, where the *M. digastricus* has only a narrow space for its origin, it is thin and simple, vertically ascending to the mastoid; there is no supplementary muscle beneath it, but a strong fascia connecting the mandibular joint with the point of junction of exoccipital and quadrate bones, and covering the terminal cartilage of the stapes.

* The examples figured by GRAY and OWEN had their teeth complete; and although the one figured in the 'Zoology of the Erebus and Terror' was not only full-grown, but unusually large, it does not appear to have been old. The example also of which a full figure has been given by Dr. GRAY has its teeth complete. I have well considered the question whether I had not to deal with two species (perhaps one from the northern, and the other from the southern island); but, after a very careful examination, no characters to justify a specific distinction were revealed.

first palatine tooth is much stronger than, and separated by a short interspace from, the succeeding. Each mandible is armed in front by two incisors and a canine tooth, more or less confluent at the base, so that the three teeth together, when ground down by the action of the upper incisor, present an uninterrupted oblique edge, most deeply chiselled out towards the symphysis (figs. 6 & 7). The alveolar edge of the mandible is polished, bearing about sixteen teeth as long as the number is complete; but (as in the maxillary) the teeth are gradually lost from the front backwards, and there is, corresponding to the remaining anterior maxillary tooth, a very shallow and long concavity scooped out by the vertical and *horizontal* action of this tooth. The toothed, or rather serrated hinder portion of the dentary fits closely between the maxillary and palatine series.

Dentition of young examples.—I have mentioned above that the upper incisors of a full-grown example are notched; this is explained by the remarkable circumstance that each is, in fact, composed of two teeth, which are conical and perfectly distinct in young examples about 7 inches long (figs. 10 & 11). Also the incisors of the lower jaw are separate to their base, and the lateral canine tooth is somewhat removed from them. The other mandibular, maxillary, and palatine teeth do not differ peculiarly from those of older examples. No polished surface can be distinguished on the alveolar edges*.

Although the peculiarities mentioned render the dentition of *Hatteria* unique, I find on examining a number of acrodont Lizards, that a recent and a fossil genus approach it closely in this respect. *Uromastyx*, an Agamoid genus inhabiting sandy plains of Northern Africa and Hindostan, has a very narrow, strong, single intermaxillary, arched downwards and more or less overlapping the symphysis of the lower jaw, more so in adult examples than in immature (figs. 12, 13, 15). In a half-grown *Uromastyx hardwickii* (fig. 14) the intermaxillary does not project below the level of the maxillary, and is armed with four small, closely set, incisor-like teeth. The maxillary and mandibular teeth are similar, and occupy in an uninterrupted series the alveolar edges of the jaws. This dentition is in time worn away: in the adult of the same species (figs. 12 & 13) the intermaxillary and the fore part of the maxillaries and mandibles are edentulous, the sharpened alveolar edges performing the function of teeth; the intermaxillary and the upper anterior angle of each mandible project, and these projections have their surfaces polished and bevelled as true teeth. In an old specimen of *Uromastyx spinipes* (fig. 15) I find the teeth complete in both jaws, but the intermaxillary projects considerably below the level of the maxillary, overlapping the mandibular symphysis. The osteological characters of *Uromastyx* do not indicate a further affinity with *Hatteria*. It is worthy of notice that *Uromastyx hardwickii* is strictly herbivorous; I am not acquainted with the food of *U. spinipes*.

The fossil genus which I would compare with these recent forms is *Rhynchosaurus* (OWEN), from the New Red Sandstone of Shropshire. In this Lizard the premaxillaries are paired, and bent downwards over the symphysis of the lower jaw; are these produced

* I cannot speak quite positively on this point, on account of the specimen having lain for some time in some fluid which affected the bones.

ends of the premaxillaries dilated teeth anchylosed to the bone as in *Hatteria*? And even if they really be part of the bone itself, the step from the premaxillary dentition of *Hatteria* to this beak of *Rhynchosaurus* can scarcely be regarded as greater than that from the dentition of the young *Hatteria* to that of the fully developed. However, a real affinity between the recent Lizards mentioned and *Rhynchosaurus* can only be conjectured, as its toothless lateral alveolar edges have been seen in one specimen only; nothing is known of the palate, or of the arrangement of the bones in the temporal region; its orbit is complete.

It will be a point of great interest to know whether those extinct Saurians which are distinguished either by entirely edentulous jaws, or by a combination of teeth with an edentulous and cutting alveolar edge (*Cryptodontia* and *Dicynodontia* of OWEN), are completely toothed when young. This does not appear to be at all improbable; and if it should prove to be the case, the transition from the normal Saurian dentition to that of the Turtle will be complete*. Among Fishes the family of *Labridæ* offers a strikingly similar series of forms of dentition; and the observations made on *Hatteria* and *Uromastix* go far to prove the correctness of the views advocated in the 'Catalogue of Fishes,' vol. i.v, viz. that small fishes with complete dentition (referred by other authors to different species and genera) are merely the young of others with partly edentulous jaws, and that the Scaroid and Odacoid fishes cannot be separated from the Labroids on account of their dentition. Thus in this most natural family we find the majority of generic forms provided with a normal complete dentition; in others (*Chærops*, *Xiphochilus*, *Pseudodax*, &c.) the lateral teeth are gradually and normally replaced by a more or less cutting edge of the mandible; and finally, in the *Scarina* and *Odacina* the entire mass of the teeth and jaws are coalesced, forming a beak with sharp cutting edges, the single teeth being still visible in the true *Scarus*, whilst they have entirely disappeared in adult *Pseudoscarus* and *Odax*. Unfortunately, up to this time, we are unacquainted with the dentition of very young Scaroid fishes.

All Lizards masticate their food in some degree; in so doing their lower jaw is moved, in a vertical direction only, towards the upper. In full-grown specimens of *Hatteria* a great portion of the side of the jaws has a *sharp cutting* edge, whilst the toothed portion also has more the appearance of a *cutting serrated* edge than of series of teeth. The force in cutting and sawing is, of course, considerably increased by the property of moving the lower jaw backwards and forwards, a property dependent on the peculiarity of the maxillary joint as described above.

All the specimens examined had the stomach and upper part of the intestine empty; but the rectum of one contained a great mass of the remains of the young of some bird which probably builds on the ground; the plumes of the feathers without quills (which being still soft had been digested), together with the condition of the bills and bones, could not leave any doubt as to the age of the bird. The same mass contained also one fragment of the elytron of a beetle. It is known, from actual observation of living speci-

* The embryo of *Trionyx* shows numerous rudiments of teeth.—OWEN, *Odontography*, p. 179.

mens, that *Hatteria* is very slow and sluggish in its movements*; therefore its food must chiefly consist of other Lizards of similarly sluggish habits, and young birds or insects accidentally approaching its mouth. Young specimens feed probably on insects only.

Before I proceed to the description of the trunk of the skeleton, I may be allowed to recapitulate the peculiarities in the structure of the skull; they are—

1. Persistence of the sutures, especially of those between the lateral halves of the skull, combined with a great development of its ossified parts as it appears in the expanse of the bones forming the upperside of the facial portion, in the completeness of an orbital ring with a temporal and zygomatic bar (Crocodilia), in the much expanded columella, in the completely osseous bottom of the orbit, and in the almost continuous roof of the palate—the palato-narial and interpterygoid vacuities being very narrow.

2. Firm and solid union of the os quadratum with the skull, and of the bones of the palate with the quadrate, as shown by the sutural connexion of quadrate and pterygoid, broad sutural connexion of the columella with quadrate and pterygoid, immoveable pterygo-sphenoid joint, firm and extensive attachment of pterygoid to ectopterygoid.

3. This restriction of the mobility of the bones named is compensated by an increased and modified mobility of the lower jaw, the mandibles being united by a ligament and provided with an elongate articular surface.

4. Displacement of the palatine bones which are separated by the pterygoids, and replace a palatal portion of the maxillaries.

5. Dentition unique, viz.:—two large cutting teeth above, formed by the confluence of two pairs of conical “milk”-teeth; alveolar edges of the jaws and palatines cutting and polished (in the adult), only partially armed with teeth (forming a serrature); palatine teeth in close proximity and parallel to maxillary series, both series receiving between them in a groove the similarly serrated edge of the mandible.

6. Finally, perforation of quadrate bone and extremely short postarticular process of mandible.

The Vertebral Column.

Professor OWEN has discovered the biconcavity of the vertebræ† (figs. 19, 22, 23). Those of the trunk (from the third cervical vertebra to the fourth or fifth caudal) are distinguished by their uniformly developed, strong and compressed neural spines, which become more slender and remote on the tail, disappearing only on about the last ten vertebræ. The total number of vertebræ is 63, viz.:—

- 3 cervical (1–3) without pleurapophyses.
- 5 cervical (4–8) with pleurapophyses.
- 3 dorsal (9–11) with ribs attached to sternum.
- 11 dorsal (12–22) with ribs and abdominal ribs.
- 3 lumbar (23–25).

* I am indebted to Sir ANDREW SMITH for this observation.

† Catal. Osteol. Ser. Roy. Coll. of Surgeons, vol. i. p. 142 (1853).

2 sacral (26, 27).

36 caudal (28-63).

As regards the first five vertebræ (fig. 17), Professor OWEN (*l. c.*) has given so detailed a description of them, that I may be allowed to quote it in full.

“The atlas consists chiefly of the hypapophysis and neurapophyses; the former is in the form of a transverse arched bar, concave upwards, with the anterior border cut obliquely to receive the under part of the occipital condyle; the posterior border is convex vertically, and adapted to the transverse trochlear groove in the fore part of the odontoid process; the neurapophyses have a small articular surface at the fore part of their base for the occipital condyle, and a second at their inner and back part for their proper centrum, the odontoid process. They are expanded superiorly, develop a small posterior zygapophysis, exterior to which is a tubercle; and they come in contact, but do not coalesce, above the neural canal. The odontoid process [fig. 18] has coalesced with the body of the axis, which it equals in height and exceeds in breadth; it is convex from side to side, concave vertically at its lower half, having, as it were, a channel scooped out from side to side; this kind of joint will allow of great extent and freedom of motion of the atlas with the head from side to side; whilst the vertical movements would be restricted. The neurapophyses of the axis have coalesced with the centrum below, and with each other above, where they develop a strong ridge or spine, which is most produced in the antero-posterior direction. An autogenous hypapophysis [fig. 17, *e*] is wedged into the inferior interspace between the centrum of the axis and the third vertebra. The centrum and neurapophyses of the third vertebra have coalesced; a short diapophysis projects from the line of union. The anterior and posterior zygapophyses form the angles of the broad base of the neural spine; this spine is of moderate length, thick and trihedral. There is a small wedge-shaped hypapophysis beneath the interspace of the third and fourth vertebræ. The fourth vertebra has a short pleurapophysis on each side, with a bifurcate proximal end articulated by a broad tubercle to the diapophysis and by a slender neck and head to a rudimental parapophysis; but this is very feebly marked off from the diapophysis. In the fifth vertebra the parapophysis and diapophysis form together an oblique ridge, chiefly extended vertically, and to which the expanded head of the pleurapophysis articulates by a single surface. There is a wedge-shaped hypapophysis at the interspace of the fourth and fifth vertebræ.”

This description agrees in every point with the three skeletons examined by myself, except that, in one example, the pleurapophysis of the fourth vertebra is not bifurcate, the lower branch being replaced by a ligament, and no trace of a parapophysis can be distinguished.

The hindmost autogenous hypapophysis (fig. 17, *e'*) corresponds to the seventh and eighth vertebræ. The dorsal vertebræ differ scarcely from the middle and posterior cervical; the zygapophyses are more distant from one another; and the oblique ridge formed by coalesced diapophysis and parapophysis is less prominent, receding nearly to the level of the centrum, on the hinder dorsal vertebræ. The centrum, the lower half

of which is rather compressed in the vertebræ of the anterior two-thirds of the trunk, becomes more flattened on its abdominal surface in the lumbar region, and still more in the sacral and two or three anterior caudal vertebræ.

The three *lumbar* vertebræ are distinguished merely by the shortness of the hæmapophysis, which does not reach the abdominal sternum, and is quite rudimentary at the second and third lumbar vertebræ; their pleurapophyses form horizontal transverse processes, not entirely anchylosed to the diapophysis, a suture being visible; however they do not appear to be moveable.

The pleurapophyses of the two sacral vertebræ are about thrice as strong as the preceding, constricted in the middle, and swollen at both ends, the sutures by which they are united with correspondingly increased diapophyses and with the ilium being very distinct; their iliac extremities are in contact with each other.

Hatteria is one of those Lizards in which the tail, when mutilated, is reproduced*; however, it is much less easily broken than in the *Lacertidæ*, *Geckonidæ*, &c., its external integuments being less distinctly divided into segments or verticelli, and strengthened by a thick layer of strong subcutaneous fibrous tissue. The centrum of each caudal vertebra (fig. 23) is divided into an anterior and a posterior portion, as in other Lizards with verticellated tail†, the epiphysial line passing *through the middle*, and *behind* the transverse process; this line corresponds to the external vertical furrow between two verticelli. The neural spines, which on the three anterior caudal vertebræ are as strong as those of the sacral region, become gradually shorter and thinner, and disappear entirely on the posterior third of the tail. The hæmapophyses, coalesced as in other Lizards, appear first between the third and fourth caudal vertebræ (fig. 21), are there rather longer but much narrower than the neural spines, and, becoming more feeble towards the extremity of the tail, disappear entirely on the last six or seven vertebræ. The transverse processes of the first two caudal vertebræ are nearly vertical to the longitudinal axis of the vertebral column, and not much shorter than those of the sacrum; all the remainder are obliquely directed forwards, and become rudimentary with the eighth vertebra.

Ribs and Sternal Apparatus of Thorax and Abdomen.

The pleurapophyses of the fourth and fifth vertebræ have been described above (p. 11); those of the sixth and seventh are not much longer than that of the fifth; but their distal ends are considerably more dilated (fig. 17). All the pleurapophyses mentioned have cartilaginous hæmapophyses slightly ossified at the base. The anterior (of fourth vertebra) is quite rudimentary; but the third and also the fourth (of sixth and seventh vertebræ) are much dilated at the base, the dilatation extending some way upwards along the *posterior* edge of the pleurapophysis, and overlapping the *succeeding* pleurapophysis. There is no anterior projection as in Crocodiles. The pleurapophysis of the eighth vertebra is slender,

* One specimen, in which the posterior third is reproduced, has a rudimentary appendage at the base of the reproduced portion, an anomaly frequently observed in other Lizards.

† CUVIER, *Recherches*, vol. x. p. 13.

twice as long as the preceding one, terminating in a short terminal cartilaginous or semio ssified hæmapophysis; *in the middle of its length, on its posterior edge, it is (like all the following ribs) provided with an apophysis directed obliquely backwards and upwards, overlapping the following rib, of the same form as, and homologous with, the processus uncinatus of birds.* The first of these apophyses is fibro-cartilaginous; the two or three following are semio ssified, the following entirely osseous, and the posterior, again, less ossified than the middle. None of them are completely anchylosed to the rib, but attached to it by a short suture strengthened by ligaments*. When we consider the transition from the dilated hæmapophysis of the sixth and seventh vertebræ to the completely ossified uncinatè (epipleural) process of one of the middle dorsal vertebræ, we shall be inclined to regard these uncinatè processes as parts of the hæmapophyses, separate and removed from the distal end of the pleurapophyses in proportion as the latter increase in length†.

All the complete ribs, fourteen in number, have a broad, compressed head, joined to a low oblique ridge of the centrum of the vertebræ; they are entirely smooth, without any tubercle in their arched basal region, which has a shallow longitudinal groove in front; they are slender, becoming gradually a little broader towards their distal extremity. The anterior are but little, the posterior considerably, shorter than the middle, the length of which is nearly equal to the extent of five dorsal vertebræ. The hæmapophyses of all (the last two excepted) are divided into two semio ssified pieces united by a joint (fig. 24); the upper (*a*), thinner and shorter piece (of about one-fourth or one-fifth the length of the rib) follows the direction of the rib, whilst the lower is directed inwards and forwards. The hæmapophyses of the first three ribs reach the sternum, the two foremost not showing any peculiarity of form, and the third approaching the succeeding in form by having a slight expansion in front and behind. The lower pieces of the hæmapophyses of all the following ribs are much dilated and imbricate (fig. 24, *b*, and fig. 20), each with a rounded wing-like expansion in front and behind; they have the form of a trapezoid situated obliquely on each side of the medial line of the abdomen; its upper anterior angle is one of the expansions overlapping the preceding hæmapophysis; the upper posterior angle is produced to meet the costal piece of the hæmapophysis; the lower posterior angle is the other expansion overlapped by the produced lower anterior angle of the succeeding hæmapophysis; and this latter angle reaches one of the bones of the abdominal sternum. The hæmapophysis of the two hindmost ribs consists of one long bent semio ssified cartilage only, and the expansions are less developed than in the other ribs.

* In young pheasants, just on the point of being hatched, I have found the uncinatè processes of the anterior and posterior ribs cartilaginous, ossification having commenced only in those of the middle ribs, at some distance from the rib; the body of the ribs was completely ossified; of course, no anchylosis of the processes to the bone had taken place. The same I found to be the case in a *Talegalla* of the same age, a bird which is capable of flying almost as soon as it leaves the egg-shell.

† I am confirmed in this view by a comparison of the same parts of the Crocodile, where a similar process is developed near the distal end of the ribs; in young individuals this process is still confluent with the hæmapophysis, as in the fourth rib of *Hatteria*.

The *sternum* (fig. 26, *a*) does not essentially differ from that of other Lizards; it is a five-sided plate with a very thin ossified layer imbedded in its cartilaginous substance; no division into lateral halves is perceptible. Its hinder margin passes into a broad ligament connecting it with the first abdominal rib, to the posterior lateral margins the hæmapophyses of the first three ribs are joined; the anterior lateral margins are entirely cartilaginous, and grooved for the reception of the coracoid (fig. 26, *e d*); and, finally, at its front angle enters the episternum (fig. 17, *b*; fig. 26, *b*), which is very long, styliform, in continuity with a median keel of the sternal plate, and terminates in a transverse bar which is suturally united with the clavicles (fig. 17, *c*; fig. 26, *c*).

The eleven posterior ribs are connected by means of their double hæmapophyses with a series of bones crossing the abdominal region and situated in the subcutaneous ligamentous tissue extending from the sternum to the pelvis (fig. 26). This system of bones is similar to, but essentially different from, that observed in Crocodiles and some Lizards (*Chamæleon*, *Polychrus*, &c.), known as abdominal ribs or abdominal sternum, and considered to be the ossified inscriptions tendineæ of the abdominal muscles.

The first point of interest is, that in *Hatteria* the number of these abdominal ribs does not equal that of the corresponding true ribs and vertebræ, being nearly double that number (I have counted from twenty-five to twenty-six); it equals rather the number of transverse series of plates into which the external integument of the abdomen is divided, so that each abdominal rib runs along, and is firmly attached by tissue to, the anterior margin of one of those transverse series of plates. Each abdominal rib has the form of an angular, thin, very slender bone, tapering at the extremities, and somewhat dilated at the angle, which is directed forwards and obtuse. The angles of all these ribs lie in the same line, in the median line of the abdomen. Each consists of three bones, united by the closest juxtaposition—a central and a pair of lateral, the lateral being about as long as one of the halves of the central; however, these three bones are so firmly united that it is very difficult to separate them*. Normally the ribs are entirely separate from one another, and only exceptionally two or three coalesced by a narrow osseous strip in the median line. Every alternate abdominal rib (fig. 20) is suspended from the hæmapophyses of a pair of ribs, the suspension being effected by a short ligament in which the produced extremity of the dilated piece of the hæmapophysis terminates. The point of attachment is on the inner side of the abdominal rib, near the junction of its central and lateral pieces. The intermediate abdominal ribs are “floating,” but otherwise not distinguished from the others.

* The first example examined by me showed a very curious anomaly as regards the union of the three bones of which the abdominal ribs consist; *they were united by joints*. That these joints are not the result of some accident—of fracture of the ribs at a former period—is proved by the circumstance that they exist only in every alternate rib, viz. in those which are connected with hæmapophyses, and, secondly, that they occupy exactly the same place, namely, at a short distance from the attachment of the hæmapophysis, towards the median line of the belly. The intermediate abdominal ribs have no joints, their bones being juxtaposed as I have described above. I cannot offer any explanation of this singularity, which I must consider anomalous, not having met with it in five other examples. It is represented in fig. 20.

Before I proceed to the next portion of the skeleton, I shall describe what I have noticed with regard to the muscles connected with this complex apparatus of ribs, in order to determine its probable function.

After the skin and the *latissimus dorsi* (which, thinned into a cutis-muscle, descends to the middle of the side of the trunk) are removed, the series of the uncinat apophyses of the ribs are seen imbedded (fig. 33), and forming the boundary line between two large masses of muscles, the dorsal of which corresponds to the *longissimus dorsi* (including the *sacro-lumbaris*), the ventral to the *obliquus externus*. Their effects are antagonistic. The *longissimus dorsi* is divided by *ligamenta intermuscularia* (in number equal to the dorsal and lumbar vertebræ), each of them terminating at and attaching itself to the hinder edge of a rib and to the extremity of its apophysis. This division of the mass of this muscle renders it possible that certain portions of it can be called into action independently of the others. It raises the ribs, or part of them. Towards the middle of the back it is covered by a strong aponeurosis, from the median line of which arises a series of short, erect, conical muscles (fig. 33, *b*), each enclosed in an aponeurotic sheath, destined to move parts or the whole of the dorsal crest.

The ventral muscular mass forms a much thinner layer; and although it can be divided into three strata, the whole must be regarded as *M. obliquus externus*, as all the fascicles run backwards and downwards (fig. 33, *c*). The outer stratum (*c'*) is fixed to the abdominal aponeurotic band; and immediately below this line of attachment lies the hinder portion of the *pectoralis major* (*d*), which thus is received in a sheath, formed by a separation of the two outer strata of the *obliquus externus*. The innermost stratum is very thin, and frequently interrupted. The three strata coalesce as they approach the costal apophyses, the mass being divided into fifteen parts, each of which is inserted into the lower edge of a costal apophysis. The function of this muscle is to depress and draw backwards the ribs.

Beside the *intercostales*, the outer stratum of which runs backwards and downwards, the inner having a backward and upward direction, irregular muscles, passing two or three ribs to insert themselves at the third and fourth, assist the function of the true *intercostales*; they are found both on the inside and the outside of the ribs.

Each of the dilated costal hæmapophyses has two muscles: one (fig. 33, *g*) is flat, thin and broad, and arises from the concave anterior edge of its ventral portion, and is attached behind the insertion of the corresponding muscle of the preceding cartilage; its fibres run obliquely forward and inward. The second muscle (*h*) arises from the outer surface of the dorsal portion of the hæmapophysis, and is attached to the inner side of the joint between the next following cartilage and its rib; its fibres run obliquely backward and outward. Sometimes a small fascicle is detached from this muscle, coalescing with the *intercostalis* of the same rib. I shall speak subsequently of the use of these muscles.

On examining the *ventral region of the trunk* (fig. 32), we find that the cutis, which is so easily detached in other Saurians, is most intimately attached to a layer of strong fibrous tissue (*c c*) extending over the entire lower surface of the abdomen to, and passing into,

the aponeurotic borders of the *MM. pectoralis major* and *obliqui externi*, the latter being situated entirely on the sides of the trunk. The fibrous tissue is so strong, that the cutis can only be removed with the knife; and it adheres not less firmly to the outer surface of the abdominal ribs; the portions stretched from one rib to another are, although firm, very pliable, allowing of an easy approximation of the ribs. Immediately below this fibrous layer is the *M. rectus* (*d*), in the superficial substance of which the abdominal ribs are imbedded, and which transversely extends from one extremity of an abdominal rib to the other. Below the *M. rectus* is the *fascia abdominalis* (*f*), covered by the black peritoneum, and passing laterally into a very thin *M. transversus abdominis*. The dilated hæmapophyses with their special muscles lie between the *M. rectus* and the *fascia abdominalis*. Finally, it must be mentioned that the extremities of the fifteen anterior abdominal ribs are attached to the hinder portion of the *pectoralis major*.

Abdominal ribs are developed in many Saurians and in a great number of Teleosteous Fishes; they may serve merely to strengthen the abdominal muscle and to afford a firmer and larger base for the attachment of muscular fibres, forming, as for instance in Saurians living on the ground, a kind of abdominal sole. When in continuity with the ribs proper (as in the Chameleon), they will essentially contribute to the support of the contents of the abdominal cavity, especially when these are pressed backwards by much inflated lungs, or when their weight is much increased by the addition of developed ova*. But in no Saurian, so far as we know at present, have they any relation to the external integuments; this we find to be the case in many Clupeoids, where their dilated centre protects the sharp abdominal edge.

As regards *Hatteria*, their increased number (exactly corresponding to that of cross series of external ventral plates) and their peculiar connexion with hæmapophyses dilated into a broad base for the attachment of muscles show plainly enough that this apparatus is subservient to some special function, viz. *to assist in locomotion*.

I have arrived at this conclusion from the following considerations:—

1. *Hatteria* lives on the ground, in rocky parts of the sea-shore, in sandhill-holes made by some other animal; its limbs, although muscular, are, compared with the majority of ground-lizards, short, especially the hind limbs. Its claws are comparatively very feeble, and acutely pointed†, showing that in a normal state they cannot be much used in dragging the heavy body, or even in burrowing.

2. The series of external ventral plates are not less imbricate than their homologues in Ophidians; they are covered with a very firm epidermis, much worn on the posterior edges.

3. Each transverse series of ventral plates, although consisting of fifteen or sixteen

* In the latter case they perform a service analogous to the ossified tendon of the *M. obliquus externus* of Marsupials.

† They are so in the specimens killed at the time of capture; in two examples kept for some time in captivity they are worn down to the base; this was doubtless caused by efforts to escape, as we observe in other lizards under similar conditions.

separate plates, is worked as if it were but a single piece, like an abdominal plate of a snake, all the plates being firmly united to the underlying abdominal rib.

4. When the fore part of the body is fixed, the action of the *M. rectus* (assisted by the *pectoralis major*) is to approximate the abdominal ribs and plates to one another, or to draw the hind part of the body forwards.

5. The end of the hæmapophysis is fixed in the *middle* of each branch of the abdominal rib—that is, exactly at the point where the greatest effect on the rib can be produced.

6. The action of the pair of hæmapophysial muscles is to draw the hæmapophysis, and with it the abdominal rib, backwards; the abdominal rib being attached to the base of the ventral plates, the edges of the latter must be raised, thus taking hold of any roughness of the ground with which they come in contact. The advantage derived therefrom, when the animal ascends a declivity, is evident.

I do not for a moment entertain the idea that an individual of *Hatteria* with the limbs disabled could glide from the spot where it lies, nor am I convinced that the action of the abdominal apparatus is constantly superadded to that of the limbs; but in the case of a lizard living on the rocks and sand-hills of the sea-shore the occasions must be frequent when the feebleness of its claws is complemented and assisted by its ventral plates. If the supposition should be confirmed that *Hatteria* lives in holes, where the free action of the limbs is naturally more or less impeded, the abdominal apparatus would be of material service. However, this habit has been attributed to it by DIERFENBACH only on the authority of natives, and it is not in accordance with the feeble development of the claws and with the presence of a much developed dorsal crest; at all events it is obvious that the holes could not have been burrowed by the animal itself.

Bones of the Fore Limb.

The cartilaginous portions of the *scapula* and *coracoid* (figs. 25 & 26) are very broad, that of the former being larger than the ossified portion. The osseous scapula (*g*) is, as usual, constricted in the middle, and there is in the concavity of the anterior margin a very distinct acromial tuberosity (*h*), to which the clavicle is attached by a strong ligament. The *coracoid* has no notch whatever; its osseous portion (*e*) is an irregularly subsemicircular disk, with a narrow foramen* (for the passage of blood-vessels) near the suture formed with the scapula, and with a second, less distinct, near its posterior extremity; its cartilaginous border is narrowest in its posterior half, where it is received into the glenoid cavity of the sternum; towards the front it widens to fill the angular space between episternum and clavicle. The glenoid cavity of the sternum is deep and long, like a slit, and the entire joint is formed by cartilage; the ligaments connecting these cartilages and fixing the coracoid to episternum and clavicle are strong, though very loose, allowing of great extent of motion. The *humerus* is very similar in form to that of *Varanus*, *Uromastyx* and others, being much expanded at its extremities, and

* It is also very distinct in the Crocodile and *Varanus*.

subcylindrical in the middle; the transverse axes of the expanded extremities intersect each other at an angle of about 40° ; the entire bone is somewhat longer than the ulna. The *ulna* and *radius* do not exhibit any peculiarity; the facet of the former for articulation with the humerus is small, not larger than that of the olecranon, which is a well-developed, oblong, tetrahedral bone. The distal extremities of the bones of the forearm are not in contact with each other. The *carpus* is composed of ten bones, five in each series; most of them are broader on the inner (palmar) surface than on the outer. The ulna articulates with three: one (*pisiforme*) is, as it were, pushed out and attached to the outer side of the extremity of the ulna, where it forms a very conspicuous prominence for the attachment of the ligaments and muscles which will be mentioned subsequently; the two others (*triquetrum* and *lunatum*) are the largest of all these bones, making up for the shortness of the ulna, which does not reach so far downwards as the radius. The radius articulates with two bones, which together may be regarded as an *os naviculare*; the outer of them projects more than the other, and sometimes articulates with the fifth digit. The bones of the second series correspond to the metacarpals, that of the second digit (*capitatum*) being somewhat more prominent than the others. Variations of this arrangement of the carpal bones do not appear to be scarce; thus, for instance, the *os lunatum* has been found removed from the ulna, pushed between the two series. Of the *metacarpals* the third and fourth are longer, the first and fifth shorter, than, and the second as long as the two following phalanges together. The *phalanges* are two, three, four, five, and three in number, and the penultimate is never longer than the preceding (as, for instance, in *Monitor*).

Muscles of the Fore Limb.

Muscles of the humeral region and upper arm.—The *MM. deltoideus* and *latissimus dorsi* do not show any peculiarity; the former arises only from the surface of the cartilaginous portion of the scapula. The mass of muscles nearest to the bone and passing over the humeral joint, homologous with the *MM. supra- and infraspinatus et teretes*, is only partially subdivided. All these muscles lift and approximate the limb to the trunk; and this is done in a direction more or less backward, according to the degree in which the *M. latissimus dorsi* is brought into action.

Two muscles take their origin from the bony arch formed by the transverse piece of the episternum and clavicle:—first, the *portio clavicularis* of the *M. pectoralis major*, which is elongate, hammer-shaped, its fibres converging into a very strong tendon, in advance of the middle of its outer margin, and inserted, as usual, into the *tuberculum majus*. Although its fibres are in perfect contiguity, and all tend to depress the limb towards the chest, they are so disposed that the anterior portion draws it forward, the posterior backward, and the middle vertically to the longitudinal axis of the body. The *second* muscle arising from the clavicle has no homologue in the fleshy part of Mammalia; it is the *claviculo-brachialis* of *Emys*, and situated immediately below the *portio clavicularis* of the *pectoralis major*, flat, arises from the whole posterior side of the clavicle,

and terminates in a tendon attached to the outer convex surface of the end of the humerus, immediately above the insertion of the *M. brachialis internus*. This muscle assists materially in drawing the limb *forward*.

The *M. biceps brachii* is situated as in higher animals, but divided into two distinct muscles running parallel to each other, being separated superiorly only by the insertion of the pectoralis major: the *inner* muscle (corresponding to the *caput breve* of human myology) is the longer, indeed the longest muscle of the arm, extending from the sternal margin of the coracoid to the *upper end of the ulna*; above its middle, where it is crossed by the tendon of the pectoralis major, it is reduced to a narrow tendon, so that there is no friction between the two muscles although they cross each other; it is fleshy again towards the margin of the coracoid. The *outer* muscle, fixed to the upper end of the radius, is arrested in its course by the tuberculum majus humeri, to which it is attached by the side of the pectoralis major; a strong ligament running from this tubercle to the scapula may be regarded as the continuation of the tendon of this muscle, and as homologous with the "*caput longum*."

A very slender muscle accompanies this part of the *M. biceps*; and being also attached to the upper end of the radius, and passing uninterruptedly into the ligament described as homologous with the "*corpus longum*," it may properly be taken as a third detached part of the *biceps*.

The *M. coraco-brachialis* has, in accordance with the development of the coracoid bone, become a very powerful muscle; it may be incompletely divided into two portions, the *anterior* of which is broad, flat, arising nearly from the entire surface of the bone, and inserted all over the *concave* surface of the end of the humerus, downwards to the middle of its length, where it is confluent with the *inferior* portion; this is a more slender muscle, taking its origin from the lower posterior angle of the coracoid, and inserted at the condylus externus humeri. The function of the entire muscle is to depress the limb, and to effect a simultaneous rotatory movement of its longitudinal axis.

The *M. brachialis internus* is well developed, and does not essentially differ from that of *Emys* or of *Mammalia*.

The *M. triceps* is very peculiar; it consists of two strong portions, an inner and a superficial, both confluent with each other and with the *M. brachialis internus* near the olecranon: the inner portion is attached along the body of the humerus between olecranon and tuberculum minus. The superficial stronger portion passes between the tendinous ends of the *Latissimus dorsi* and *Deltoides*, and is inserted into the contracted part of the scapula; however, before it passes the tendon of the *Latissimus dorsi*, it emits another, long, slender tendon, crossing the plexus nervorum brachialis and attaching itself to the inside of the posterior angle of the coracoid. This tendon appears to serve merely as an additional point of attachment to the muscle.

Muscles of the lower arm.—The *flexor* muscles arise chiefly from the inner condyle of the humerus and the inner surface of the bones of the lower arm. Their number is reduced to three, viz.:—First, the *M. flexor digitorum profundus*, terminating in five tendons for the

extreme phalanges of the fingers, without a trace of *MM. lumbricales*; a *M. flexor digitorum sublimis* appears to be represented in a rudimental condition by a flat and thin muscle, which takes its origin from the fascia covering the lower part of the *profundus*, and chiefly from a ligament extended between the *os pisiforme* and *os naviculare*; it is fan-like, expanded over the palm, and at the base of each digit the fibres diverge for the passage of the tendons of the *profundus*; for this reason I am inclined to regard this muscle as a rudimental *l. d. sublimis* rather than as a muscular *fascia palmaris*. A strong aponeurotic palmar fascia is not developed. Secondly, the *flexor carpi radialis* and *M. pronator teres* arise united into one muscle, the latter becoming distinct towards its insertion on the middle of the radius, and being entirely covered by the former, which, as usual, descends to the end of the radius and to the carpus. Thirdly, the *flexor carpi ulnaris*, subdivided by a broad aponeurosis along the middle of its interior; a part of it passes the carpus and forms an *abductor digiti minimi*.

The *extensor* muscles arise chiefly from the outer condyle of the humerus and the outer surface of the bones of the lower arm; they are less powerful than the flexors, and more intimately connected with each other by intervening tissue, which disappears entirely towards their origins; so that their separation is artificial for a part of their length. Six can be distinguished, viz.:—The *M. supinator longus* and the *extensor carpi radialis brevis* and *longus*; they are slender, running parallel to each other, and inserted more distinctly into the carpal bones than into the metacarpals. The *extensor digitorum communis* is the most powerful muscle of this region, and in its lower part divided into two portions, the longer of which terminates in an aponeurosis attached to the metacarpal bones, whilst the shorter coalesces with the distal portion of the *extensor carpi radialis brevis*. Covered by the proximal portion of the muscle last described, and situated inwards of the olecranon, is a very distinct oblique muscle, arising from the condylus internus humeri, and attaching itself to the outer surface of the olecranal part of the ulna; it occupies exactly the position of the *Anconæus quartus*, and may be regarded as such, or as an *Extensor carpi ulnaris* (which otherwise could not be accounted for). Finally, the muscles which in Man are divided into the abductor and extensors of the thumb, form in *Hatteria* one flat layer covered by the *Extensor digitorum communis*, arising from the distal half of the ulna, and spreading over the bones of the carpus, to which they are attached; the fibres nearest to the radial margin are collected into a tendon which is inserted at the metacarpal bone of the thumb.

There is no *ligamentum osseum* between ulna and radius; it is replaced by a strong muscle, the fibres of which are transverse, either vertical to the longitudinal axis of the arm, or obliquely descending from the ulna to the radius.

Of the *muscles of the hand*, besides those mentioned above and the *interossei*, one remains to be noticed, lying below the *flexor digitorum communis* on the metacarpal bones; it arises from the second series of carpal bones, its fibres diverging chiefly from the carpal bone of the fourth digit (*os hamatum*) to the base of the proximal phalanges of the digits; it essentially assists in adduction and flexion of the digits.

Bones of the Hind Limb.

The *pelvis* (figs. 27 & 28) represents the Lacertian, and not the Crocodilian type, and differs from the former in the subvertical direction of the ascending part of the ilium, the axis of which forms with that of the vertebral column an angle of about 80°. Its lower surface is flatter and less convex than in the majority of Lizards. The ascending part of the ilium is about thrice as high as broad, and projects much beyond the transverse processes of the sacrum; its hinder margin is nearly straight, the anterior having two very slight tuberosities—the upper opposite the junction with the sacrum, and the lower on the ilio-pubic suture. The acetabulum is formed by the three pelvic bones, as in Lizards. The pubic and ischium are very similar in form, and form with their fellows moderately broad symphyses; the obturator vacuity is of the usual extent, divided into two by a strip of the symphyseal cartilage. The pubic has a remarkably developed uncinat process (*c*) in the middle of its anterior margin; and still more prominent is the *tuberositas ischii* (*d*), the distance of the latter from the uncinat pubic process of the same side being quite equal to that between the two pubic processes. These processes serve for the attachment of ligaments and muscles, to be described subsequently. The pubic bone is perforated by a nerve and blood-vessels for the abductor muscles of the femur, about midway between the uncinat process and the foramen obturatorium. The symphyseal cartilage shows scarcely a trace of ossification.

The bones of the *upper* and *lower* leg do not differ from the Lacertian type: there is one large trochanter (corresponding in position to the *trochanter minor*), no ossification in the *ligamentum patellare*, no sesamoid bone between femur and fibula, as in *Varanus*.

The tarsal and metatarsal bones agree with those of *Varanus* in number and arrangement; all are thin and flattened. The first series is composed of the two bones which may be briefly designated as *astragalus* and *calcaneum*; the suture between them is scarcely visible, but it may be distinctly seen that the fibula is articulated with the calcaneum alone, without coming in contact with the astragalus. The second series consists also of two bones (the inner being very small), intercalated between the first series and the three middle metatarsals. The fifth metatarsal has the proximal end dilated, this dilatation having the irregular form of a tarsal. A thick cartilage, without ossification, intervenes between the first metatarsal and astragalus. The first metatarsal is shorter, the three middle longer, than, and the fifth as long as the two proximal phalanges together. The number of phalanges is 2, 3, 4, 5, 4.

Muscles of the Hind Limb.

The determination of the homologies of several of these muscles (fig. 34) is a matter of uncertainty; I am guided in it chiefly by the proximal point of their insertion, in the second place by their function, considering their development and extent a matter of but little importance. The powerful extensor known as *MM. rectus* and *vasti*, and properly regarded as one muscle by HYRTL (*extensor cruris quadriceps*), is at once recognized; it

is formed by three heads: the broadest and most superficial arises from the *os ilium**; the second is slender and comes from a slight tubercular prominence on the end of the ilio-pubic suture; the third is covered by the two former and attached to the anterior surface of the lower half of the femur.

The second muscle, which takes its origin from the ascending portion of the *os ilium*, may be regarded as *M. iliacus internus*; it is entirely covered by the *M. rectus*, and terminates along the outer and hinder surface of the upper half of the femur; it draws the limb backwards and upwards.

The *M. pectineus* arises from the ventral surface of *os pubis* and *ilium* and from their anterior edge, and, descending over the humeral joint to the antero-interior surface of the humerus, terminates just above the lower (third) branch of the *extensor cruris*; it draws the limb forwards†.

The *M. gracilis* runs parallel to the slender head of the *M. extensor cruris*; it arises from the uncinat process of the *os pubis*, and is inserted into the hinder side of the end of the tibia.

Immediately below the skin, the pelvic region is covered by a flat and thin muscle arising from the symphysis ossium pubis et ischii and the uncinat process of the *os pubis*; it is the hindmost part of the *M. obliquus abdominis externus*. On removing this muscle a strong ligament, stretched from the uncinat process to the hinder end of the symphysis ossium ischii, becomes apparent. From this ligament, as well as from the tuber ischii, arises a mass of muscles divided into more or less distinct portions, which, however, cannot well be designated by names taken from human anatomy. We can only determine it so far in a general manner, that, to judge from its origin and from its function of bending the lower leg, it corresponds to the *MM. semimembranaceus, semitendinosus, biceps* (and *glutæus*?) (fig. 34, *b c*). Its largest portion covers nearly entirely the lower side of the leg, and is inserted into the outer side of the end of the tibia; it emits a branch to the inner side of the distal half of the femur, which has the function of an *adductor femoris*. The other, more slender, portion is entirely on the hinder side of the leg; its fibres are confluent with those of the larger portion, near their origin; another portion

* This head is described by Dr. HAUGHTON as *M. glutæus maximus*, in the Crocodile (Ann. & Mag. Nat. Hist. 1865, vol. xvi. p. 327). It has in the Crocodile exactly the same anterior position, the same origin, and the same extent as in *Hatteria* (and other Lizards); but it is somewhat more feeble. It passes into the tendon of the *extensor cruris* (*ligamentum patellæ proprium*), from which it can be severed only artificially; moreover it is one of the chief extensor muscles of the lower leg. For these reasons I cannot adopt Dr. HAUGHTON's determination, but I regard it as the *rectus* portion of the *extensor cruris quadriceps*. A *M. glutæus magnus* is not developed in Saurians. Also BUTTMANN ('Dissert. de Musculis Crocodili,' dedicated to MECKEL) describes it as a part of the extensor (*vastus externus*), and does not mention a *glutæus magnus*. What I have described as the second and slender head of the extensor, and has also by BUTTMANN been identified with the *vastus internus*, is named *M. rectus* by Dr. HAUGHTON. In *Hatteria* it passes simply into the *ligamentum patellæ*, and there is no connexion with any of the muscles of the calf of the leg.

† This muscle might be taken for the *psaos*; but its origin is far distant from the vertebral column; indeed a *psaos* descending from the lumbar region to the humerus is not developed in *Hatteria*.

of its fibres arises from a strong ligament extended between tuber ischii and the root of the tail (*d*); its tendon is inserted into the inner side of the end of the tibia.

A very peculiar muscle (*a*) takes its origin from the eight or nine first inferior spinous processes of the caudal vertebral column and the lower surface of the corresponding vertebræ; it is very strong, imbedded between the caudal muscles proper*, compressed, with the lower margin rounded, and separated from the surrounding muscles by very loose cellular tissue. It tapers behind into a point; and becoming gradually stronger towards the trunk, it passes below and crosses the ligament extending from the tuber ischii to the root of the tail (*d*); the greater part of its fibres are here collected into a broad and strong tendon, which is attached to the inner trochanter-like protuberance of the femur; but another portion (*a'*), strengthened by additional fascicles from the broad ligament mentioned, passes into a slender chord-like tendon (*a''*) which runs along the entire length of the femur, and is inserted into the end of the fibula. This muscle draws the limb backwards and rolls it outwards; and with its slender tendon it assists in bending the lower leg†.

A very long and slender muscle (*h*) accompanies the ischiatic nerve; it arises from the os sacrum, passes along the outer side of the femur, and is inserted into the outer side of the fibula; it bends the lower leg (*M. agitator caudæ* of Dr. HAUGHTON).

A very short muscle, entirely hidden by the two muscles last described, reaches from the *tuber ischii* to that part of the femur where, in Mammalia, the *trochanter major* projects; it is an abductor muscle, and rolls the leg slightly outwards (*M. quadratus femoris*).

Finally, a broad muscle, arising from, and lying immediately on, the entire lower surface of the pelvis, is inserted into the prominent inner tuberosity of the head of the femur; it is covered by the hinder part of the *obliquus externus* and by the foremost part of the large flexor muscle; it is the principal *adductor* of the limb.

Of the *muscles of the lower leg*, those on the *anterior* side are readily distinguished as *tibialis anticus*, *extensor digitorum (communis longus)*, and *peroneus longus*; the *extensor* terminates in two slender tendons only, inserted into the metatarsal bones of the second and third toes.

The muscles on the *hinder* side of the lower leg are disposed in several layers. The

* In a male *Grammatophora* it is situated above the penis and its muscle.

† Dr. HAUGHTON (*l. c.*) describes and figures this muscle in the Crocodile as *M. extensor femoris caudalis*, and expresses its use in the following words:—"The Crocodile, resting on mud, progresses chiefly by using his hind feet as paddles; and in this use of them the great caudal extensor of the thigh is the most powerful and important muscle employed." The fact that this muscle is developed in ground- and tree-lizards as well as in the Crocodile, prevents us from adopting the idea of its being an organ specially adapted for the mode of life of the latter. When in the progress of ordinary locomotion one of the hind limbs is advanced, and its sole becomes the fixed point, this muscle lifts the hind part of the body forwards, in which it is materially assisted by having a double insertion, viz. on the upper end of the upper leg, and by its slender tendon on the lower. When the trunk is fixed, this muscle simply draws backwards the limb, effecting at the same time a slight flexion of the lower leg.

outermost layer consists of two muscles equivalent to the *MM. soleus* (*l*) and *gastrocnemius* (*k*), although their origins are somewhat modified*. The *M. soleus* occupies the tibial side, and arises from the upper end of the tibia, emitting a tendon which is confluent with the slender portion of the great flexor (*biceps*?) of the femoral region; it terminates in a broad tendon thinned into a fascia extending across the tarsus, and chiefly attached to the astragalus on one side and to the metatarsus of the fifth toe on the other. In order to have a full view of the *M. gastrocnemius*, it is necessary to remove the *soleus*; it is much larger than the *soleus*, and occupies the fibular half of the lower leg; it has two heads; the larger arises from the femur and long tendon of the *extensor femoris caudalis*, and passes, in the tarsal region, uninterruptedly into the *flexor digitorum communis brevis*, the division between both muscles being faintly marked by a transverse tendinous inscription. The second head is very slender, and arises from the tendon of the great *flexor* of the femoral region, being confluent at its origin with the *M. soleus*.

The *second* layer consists of the *flexor digitorum communis longus* only; but this muscle has three heads, which are united into an exceedingly strong tendon in the tarsal region, which, as usual, is split into five branches, each perforating the corresponding branch of the short flexor. The longest and most superficial of the three heads is confluent with the large head of the *gastrocnemius*, both having the same origin on the femur. The second head is situated below, and covered by the first, and arises from the upper ends of tibia and fibula. The third head is additional, and may be regarded as a separate muscle, running and working in a quite different direction from the others; it is flat, rhomboid, and arises from the outer edge of the lower end of the fibula and of the tarsus, runs transversely to the longitudinal axis of the limb, and meets the common tendon at an angle of 45° : whilst the two longer heads of the muscle act and bend the toes in the direction of the longitudinal axis of the bone, the action of this short head crosses it obliquely, and bends the three inner toes only.

The *third* layer consists of the *M. tibialis posticus*; it arises from the entire posterior side of the tibia, its fibres descending obliquely, and converging into a broad tendon inserted into the metatarsals of the three inner toes; it draws the foot backwards and inwards.

The space between tibia and fibula is filled by a muscle the fibres of which run transversely from one bone to the other.

The *muscles of the foot* agree perfectly with those of *Grammatophora* and *Iguana*, of which latter lizard they have been described by MECKEL†.

I have given a detailed description of the muscles of the extremities, not in the hope of finding any peculiarity by which *Hatteria* might be distinguished, or which might assist in determining its affinities, but because little attention has been paid to the special myology of Saurians, and because the muscles of the hind limb of the Crocodile have

* Dr. HAUGHTON appears to have named the *M. gastrocnemius Plantaris*, and the *M. soleus Gastrocnemius*.

† System d. vergl. Anat. vol. iii. p. 285.

been recently treated of in a separate paper*. I have chosen for collateral examination *Grammatophora*, *Iguana*, *Varanus*, and *Crocodilus (americanus)*, young, 18 inches long), and found the general arrangement of the muscles remarkably uniform. Dr. HAUGHTON describes as a peculiarity of the Crocodile an interlacing of the tendons of various muscles, and says that the effect of it must be to produce simultaneity of action among them. Such a connexion of muscles by means of tendons has been described above as existing between the *Extensor femoris caudalis* and *Gastrocnemius*, and between a portion of the *Flexor cruris (biceps)* and *Soleus*; but I have failed to find the connexion between the "*M. rectus and plantaris*" (so named by Dr. HAUGHTON).

Generally speaking, and not taking into consideration the numerous instances which might be adduced to the contrary, the actions of the limbs are less diversified in Saurians than in the higher classes of Vertebrata. The energy of the contractions of their muscles, although it may be momentarily great, is less enduring, so that the disproportion between their feebly developed limbs and the size of the body appears only the greater. In accordance with this the muscles are found reduced in number, and simplified in their arrangement, inasmuch as muscles the origins of which are in close proximity are frequently partly confluent, or a fascicle of one muscle passes into the substance of its neighbour. There is no doubt that such muscles act simultaneously; but this want of separation refers to *collateral* muscles only.

A want of separation of muscles belonging to *different regions*, such as the interlacing of the tendons of the muscles of the upper and lower legs, does not prove the simultaneity of their actions,—first, because the connexion between them is effected by tendons more or less intimately attached to the bone, which *interrupts* the continuity of contraction of the upper and lower muscles. Secondly, the simultaneity of action could not be produced without the simultaneous influence of the nerves entering those muscles; and as it is dependent on the nerves, the tendinous connexion is not needed to produce it. It is a circumstance worthy of notice that all these interlacements are in the *fossa poplitea*, behind the knee-joint, which in Saurians is almost always in a state of flexion, and that these animals are able to draw the lower leg so far upwards as to lie alongside of the upper. This will readily account for the unusually high insertion of a part of the tendinous terminations of the lower muscles, at a place above and somewhat remote from the end of the femur, and more especially into the tendons of the upper muscles, there being no room on the bone itself.

In *Hatteria*, as well as in other lizards, I have observed that parts of one and the same muscle are often so loosely united that it may be easily, though artificially, split from one end to the other, thereby tempting one to adopt a nomenclature created for higher Vertebrates with a more diversified action of the limbs and a greater multiplicity of distinct muscles. Thus the muscular system of the limbs of lizards appears to be characterized not only by the partial confluence of the fascicles and tendons of different muscles, but also by the loose connexion of the fascicles of the muscles generally.

* "On the Muscular Anatomy of the Leg of the Crocodile. By the Rev. SAMUEL HAUGHTON, M.D.," in *Ann. and Mag. Nat. Hist.* 1865, vol. xvi. pp. 326-331.

Integuments.

The external modifications of the integuments are fully noticed in the diagnoses and figure published by Dr. GRAY; and the external arrangement of the ventral plates has been mentioned above; so that I have but little to add. No part of the cutis contains any ossification. There are no cutaneous glands in any part of the body, except the pair of large anal glands, which may be more properly described with the organs of propagation. So-called femoral and præanal pores are entirely absent, with the subcutaneous follicles.

Organs of Sense.*

A simple turbinal bone occupies the bottom of the entrance of the *nasal cavity*, and an undulated cartilage projects far into it from its roof; the latter may be distinctly seen from the palatal opening.

The *eye* is protected above by an upper very short eyelid; the lower shuts the eye entirely, and contains a cartilaginous subsemiglobular disk, as in Agamoids generally; a membrana nictitans and the lachrymal gland are present. The sclerotic ring is composed of seventeen bony lamellæ. The iris is divided into two lateral halves by an upper and a lower strip of accumulated elastic fibres, covered with an intensely black pigment on the inner surface; the pupil appears, in preserved specimens, nearly round, but is slightly contracted vertically. The lens is, as in other lizards, globular, flattened in front; but *Hatteria* differs from them in not having a *pecten* (falciform process).

With the *tympanum* a *tympanic cavity* is entirely absent. The only remaining portion of this sphere of the ear is the *stapes* (*c* in figs. 2 & 5), 11 millims. long; it lies in a groove of the exoccipital, imbedded in cellular tissue between other soft parts immediately below the membrane of the auditory recess of the pharynx, and terminates at its outer extremity in a subsemicircular cartilaginous disk, to which the outer horn of the hyoid bone is attached by a fibro-cartilaginous ligament. At its inner extremity it is thickened into a knob fitting into the *fenestra ovalis*.

After removal of the bony part of the exoccipital and basisphenoid, which forms the bottom of the *labyrinth*, a cartilaginous capsule becomes apparent; its thickness is half a millimetre; the membrane coating the walls of the cavity is of a deep black colour. The *sacculus vestibuli* contains a single pear-shaped otolith 3 millims. long and 2 millims. broad at its widest (inner) end. The cochlea is more developed than in other lizards, showing the commencement of a spiral turn; the membrane at its base contains the terminations of the cochlear nerve, which is abruptly split into four dichotomically divided and fan-like branches. The three semicircular canals lie behind and somewhat outward of the cochlea, and are also membranaceous, otherwise well developed, being from 12 to 15 millims. long.

* The following remarks on the anatomy of the soft parts are of necessity incomplete, as, besides a perfectly emaciated and badly preserved one, only a single example (and this preserved in spirits for nearly twenty years) has been available for dissection; and I have not thought myself justified in destroying parts of the head of so rare a specimen, in order to investigate points in which *Hatteria* may reasonably be expected not to differ from the Lacertian type.

Organs of Digestion.

The *teeth* have been described in connexion with the bones of the jaws.

The *tongue* (fig. 16) is fleshy, elongate-triangular, posteriorly with the base entirely grown to the bottom of the mouth, and angularly incised to receive the glottis*. Its surface is densely covered with soft pointed papillæ, without any tubercles or scales, and divided into two lateral halves by a shallow median furrow.

The *salivary* organs are but little developed; the mucous membrane on the outer side of the middle of the mandible has a spongy appearance, the surface being irregularly reticulated. Along the side of the base of the tongue there are simple solitary glands in small number, nowhere aggregated into a larger mass. Their openings are minute, and most distinct on the side of the root of the tongue.

The *hyoid* does not show any peculiarity, except as regards its attachment to the skull. The body is arrow-shaped, but little ossified, tapering into a long point in front, and split into a pair of accessory horns behind. The anterior horn consists of two pieces, nearly entirely cartilaginous, the inner much longer than the outer, which is attached by a ligament to the terminal cartilage of the stapes (see p. 26). The posterior horn consists of a long, arched, entirely osseous piece, to which a short terminal cartilage is joined. No part of the horns is dilated.

The *œsophagus* is wide, and passes, without distinct separation, into the elongate, spindle-shaped *stomach*; the muscular layer of the latter is nowhere conspicuously thickened, and its mucous membrane is raised into only a few longitudinal folds. No *curvatura major* can be distinguished. The pylorus is indicated by the cessation of the longitudinal folds; the duodenum is 9 millims. long, and separated from the small intestine by a circular valve only about 1.5 millim. deep, and consequently not entirely shutting the duodenum†. No part of the small intestine is provided with *valvulæ conniventes*, all the folds running in a longitudinal direction; they are numerous and very low and narrow in the upper fourth, broad and less numerous in the middle, and disappear entirely towards the rectum. There are no patches of accumulated glands anywhere. The passage into the very wide rectum is narrowed by an incomplete valve. The cloaca is separated from the rectum on the dorsal side only by a fold of the mucosa.

The walls of the intestines are throughout very thin; the small intestine makes two complete circumvolutions, and is 180 millims. long, the rectum with the cloaca 100 millims.

The *liver* is conspicuously divided into two lateral portions, each of which is subdivided in a curious and apparently irregular manner. The bridge between the two portions crosses the lower surface of the posterior part of the stomach. The *left* portion lies in the lower part of the abdominal cavity, is thin, twice as long as broad, and fixed by an exceedingly strong and long filament to the pubic bone. This portion is at some places

* This posterior incision is still deeper in *Grammatophora*, in which, moreover, each posterior angle of the tongue is produced into a short, scaly, pointed lobe.

† Cf. a similar arrangement in *Regenia* and *Monitor*, Proc. Zool. Soc. 1861, pp. 60, 110.

very thin; and at others the parenchyma is entirely interrupted, so that the peritoneal coverings of both sides are in immediate contact with each other. Several small lobes project from the dorsal surface; and one larger, long, spindle-shaped lobe (about 1 inch long) adheres to the body of the liver by a thin style only. The *right* portion is extremely irregular in shape, with several projecting appendages, and considerably thicker (although, on the whole, not larger) than the left*.

The *gall-bladder* is of the size of a currant-berry, and imbedded in the right lobe close to its transition into the left. The *spleen* and *pancreas* are very elongate and narrow. No trace of *corpora adiposa*.

Heart.

The hearts of two examples were examined; but in both the substance had become so deteriorated that it was impossible to obtain a clear insight into their structure. The muscular part is extremely thick, the ventricular cavity being very small and apparently simple. The two atria are entirely separate, of nearly equal size. The aortæ and arteriæ pulmonales are externally united into one stem; and although there is only one ostium for the aortæ, the truncus aortæ is extremely short.

Organs of Respiration.

The *larynx* (fig. 16) is composed of a complete posterior cartilaginous ring and a pair of separate anterior cartilages. The ring is broadest laterally and narrowest anteriorly; it has a slight protuberance (*c'*) in the middle of its lateral posterior margin for the insertion of the *M. dilatator glottidis* (*c*). The anterior cartilages are separated in front by a wide interspace and united posteriorly by a ligament; they are produced to form the glottis, which, compared with Agamoid Lizards', is very wide. Two muscles are attached to the larynx on each side: the *M. dilatator glottidis* covers the outer lateral surface, being extended from the margin of the *glottis* to the posterior tubercle, as mentioned above. The *compressor glottidis* lies within the glottis, and extends from its antero-interior margin transversely to the hyoid bone.

The *trachea* (fig. 16) has none of the cartilaginous rings closed on the dorsal side; and many reach only to the median line in front: they are very irregularly arranged, and soft and flexible like membrane. The two bronchi are very short, and terminate immediately behind their entrance into the lungs. The *lungs* of both sides are of nearly the same capacity, rather large; they are simple bags with large cells in small number, more resembling the lung of a Batrachian than of a Lizard.

Uropoëtic Organs.

The *kidneys* are situated in the hindmost part of the abdominal cavity, viz. within the pelvis; they are flat, entirely separate from each other, and the left is considerably larger and different in shape from the right. Each is incompletely divided into four or five lobes very irregular in form. The right is of an elongate-ovate shape, without any pro-

* In a specimen kept for some time in captivity, the entire liver was shrunk to the thinness of a membrane.

jecting parts; the left is of nearly twice the extent of the right, and has a lobe-like appendix in front, situated in the cavity between the transverse processes of the two sacral vertebræ. As the kidneys lie in the closest proximity to the cloaca, the ureters are extremely short, each opening, together with the vas deferens of its side, in a papilla situated in the recess behind the fold of the mucous membrane which separates the rectum from the cloaca. The urinary bladder is large, elongate, subcylindrical, opening at the usual place into the cloaca.

The *testicles** are elongate-ovate, situated in the anterior half of the abdominal cavity, nearly opposite to each other. The *vas deferens* lies at some distance outwards from the testicle, receiving the "efferent canals" at nearly right angles; its course is but slightly undulated. *There is no trace of an intromittent copulatory organ in Hatteria*, either at the root of the tail, or in the anterior wall of the cloaca,—a peculiarity quite unique among Saurians. The pair of lateral *anal glands*, however, which open into the outer corner of the anal cleft, are quite as much developed as in other lizards. They have been but little noticed by anatomists, although they appear to be present in most lizards. They lie, quite free or surrounded by very loose cellular tissue, in a hollow on the lower side of the root of the tail, behind the caudo-ischadic ligament. They are of a globular form, and open into the base of the exsertile male organ. In *Grammatophora* and *Gecko* a portion of the corpus cavernosum extends to the base of the gland, whilst it is perfectly isolated in *Uromastyx*. I have not found it in *Amphisbæna*, which has a paired penis. STANNIUS designates the secretion of this gland as *smegma*. In *Hatteria* the gland (fig. 34, *o*) has a diameter of about four lines, and is quite free in the cavity behind the ischium: its opening is closed by a perforated membrane (fig. 29, *b*); and the contents are discharged by about eight small foramina. The interior has a spongy appearance, being divided into many irregular smaller and larger compartments, separated by septa with partly free or floating margins (figs. 30, 31). They are small and short towards the periphery of the gland, imbedded in dense fibrous tissue, becoming larger and more elongate in the middle; the larger have a tendency to radiate towards the external opening, behind which they empty into a common vacuity. All these compartments were found to contain a finely granular secretion, which of course was much altered by the action of the spirit in which the specimens were preserved.

Concluding Remarks.

Before concluding this paper with a few words on the position of *Hatteria* in the system, I shall briefly review the more noteworthy peculiarities by which it is distinguished from other Saurians. Those presented by the skull have been already recapitulated (p. 10).

1. Above all, the amphiœlian structure of the vertebræ must be mentioned, a character which does not occur in any of the recent Saurians, except in the degraded type Geckotidæ. The vertical division of the centra of the caudal vertebræ observed in

* Unfortunately both specimens examined were males.

the majority of lizards occurs also here, but each centrum is split into two equal halves. The property of reproducing lost portions of the tail is indicative of low organization; yet it is evidently much less pronounced in *Hatteria* than in other lizards of a similarly low type. In other respects the vertebral column of *Hatteria* does not deviate from the Lacertian type, such points as the uniform development of strong neural spines, or the singularly oblique direction of the caudal pleurapophyses, which point forwards, being of minor importance.

2. The modifications of the costal hæmapophyses:—*a*, into a series of appendages identical in position with the uncinatæ processes of birds; and, *b*, into a double terminal series connecting the ribs with the thoracic and abdominal sterna, the distal pieces being much dilated to form the base of a system of muscles.

3. The development of a system of abdominal ribs, neither floating (Crocodile) nor mere continuations of the true ribs (Chamæleon), but standing in functional relation to the ventral integuments.

4. The continuity of the ossifications of the coracoid, the presence of an acromial tuberosity of the scapula, and the subvertical direction of the os ilium are very remarkable deviations from the Lacertian type; whilst the arrangement of the bones of the limbs does not show any peculiarity, except in the articulation of the *fibula*, which is joined to the *calcaneum* only.

5. Absence of the pecten of the eye. Entire absence of the tympanic cavity; attachment of the hyoid bone to the terminal cartilage of the stapes; commencement of a spiral turn of the cochlea.

6. Although the details of the structure of the heart are, for the present, unknown, it has been ascertained to be of the Lacertian, and not of the Crocodilian type.

7. The organs of respiration and digestion adhere closely to the Lacertian, and more especially to the Agamoid type, as does the greater portion of the uropoëtic organs. However, the kidneys are entirely within the pelvis; and the absence of a copulatory organ is a character by which *Hatteria* is distinguished from all other Saurians.

There can be no doubt that *Hatteria* must be removed from the family of *Agamidæ*, and that it is the type of a distinct group; but the question is whether this group should be subordinated to the Saurians as a family like the *Agamidæ*, *Iguanidæ*, &c., or whether the characters pointed out are deemed of sufficient importance to assign to it a more distant position from the other Lizards. In a system founded upon external characters only, the former course would be taken, and a family *Hatteriidæ* would be placed near the *Agamidæ*, with which it agrees in the majority of its external characters. However, there is scarcely a systematist of the present day who does not pay more or less attention to anatomical characters in establishing the higher divisions. Thus Dr. GRAY admits into the diagnosis of his section *Squamata* (= Lizards and Ophidians) the articulation of the tympanic to the skull and the paired copulatory organs as principal

characters, by which it is distinguished from the second section *Cataphracta* (= Tortoises and Crocodilians + Amphisbænians). The division proposed by STANNIUS into *Streptostylica* (= Snakes and Lizards + Amphisbænians) and *Monimostylica* (Tortoises + Crocodilians) is founded essentially on the same characters as that of GRAY. *Hatteria* would not enter any of the divisions defined in those two systems. Professor OWEN refers the recent Reptiles to four coordinate orders—*Chelonia*, *Lacertilia*, *Ophidia*, and *Crocodylia*; *Hatteria* would probably enter the second, inasmuch as the character of “procælian vertebræ” assigned to this order, is the only one by which *Hatteria* would be excluded, but the Geckos, which are Lacertilians in Professor OWEN’S system, also have amphi-cælian vertebræ. In the *Crocodylia*, likewise, this is not considered an ordinal character, but is used for the distinction of the suborders.

In these three systems the Crocodiles are removed from the Lizards, into a distinct order or section, on the ground of osteological characters as well as on account of the higher organization of their soft parts. Now in *Hatteria* the modifications of the Lacertian skeleton extend to the same parts as in the Crocodiles (except the anterior ribs and thoracic sternum), although they are frequently of a different nature; and the repetition of Lacertian characters in its soft organs is in some measure counterbalanced by the absence of copulatory organs. Therefore we cannot hesitate to claim for it a rank higher than that of a family. The presence of a double bar across the temporal region, the intimate and firm connexion of the os quadratum with the skull and pterygoids, the erect ilium, and the uncinæ processes of the ribs are characters by which a tendency towards the Crocodilians is manifested; but here the resemblance ceases; and the affinities of *Hatteria* with the Lizards are far more numerous and of greater importance. I need only mention the structure of the heart, of the organs of respiration and digestion, the absence of a diaphragm and of peritoneal canals, the transverse anal cleft, the absence of an external ear, the free tongue, &c. Yet were we to associate it with the Lizards in one group, the unity of this group would be entirely destroyed. I propose, therefore, the following modification of STANNIUS’S division of recent Reptilia, adding a few of the characters which appear to be of special importance in the determination of the affinities of *Hatteria*:—

RECENT REPTILIA.

I. SQUAMATA. Anal cleft transverse. Copulatory organs paired, if present. All the ribs single-headed, sacral vertebræ two or none.

First order: *Ophidia*. Quadrate bone articulated to the skull; brain-capsule entirely osseous; rami of the mandible united by ligament. Copulatory organs present.

Second order: *Lacertilia*. Quadrate bone articulated to the skull; parts of the alio- and orbito-sphenoid regions fibro-cartilaginous; rami of the mandible united by suture; temporal region without, or with only one horizontal bar. Copulatory organs present.

Suborder A. *Amphisbænoidea*. Vertebræ procœlian. No posterior orbital ring or temporal bar; no columella.

Suborder B. *Cionocrania*. Vertebræ procœlian. An orbital ring with a temporal bar more or less complete. Columella present.

Suborder C. *Chamæleoidea*. Vertebræ procœlian; a bar crossing from the parietal to the mastoid; temporal bar complete. No columella.

Suborder D. *Nyctisaura*. Vertebræ amphicœlian; orbital ring and temporal bars not developed. A columella.

Third order: *Rhynchocephalia**. Quadrate bone suturally and immoveably united with the skull and pterygoid; columella present. Parts of the ali- and orbito-sphenoid regions fibro-cartilaginous; rami of the mandible united by a short fibrous ligament. Temporal region with two horizontal bars. Vertebræ amphicœlian. Copulatory organs none.

II. LORICATA. Anal cleft longitudinal; copulatory organ simple. Anterior ribs bifurcate; sacral vertebræ two.

Fourth order: *Crocodilia*. Quadrate bone suturally united with the skull; parts of the ali- and orbito-sphenoid regions fibro-cartilaginous; rami of the mandible united by suture. Choanæ formed by pterygoid and palatine bones.

III. CATAPHRACTA. Anal cleft longitudinal; copulatory organ simple. Trunk-ribs and sternum dilated, more or less completely united by suture.

Fifth order: *Chelonia*.

The skeleton of *Hatteria*—with its amphicœlian vertebræ and abdominal sternum on the one hand, and its highly developed osseous skull and uncinæ apophyses of the ribs on the other—presents a strange combination of elements of high and low organization; and this is the more significant as this peculiar animal occurs in a part of the globe remarkable for the low and scanty development of Reptilian life. The New Zealand of the present period is inhabited by only a few (about nine) small species of the cosmopolitan Geckos and Skinks and by a single species of frog; and it is not probable that this small list will be considerably increased by future researches. With more confidence may we look forward to discoveries of remains of extinct forms, of which one *Plesiosaurus* only, the *Plesiosaurus australis* of OWEN, is known at present; but whether they will be of such a nature as to afford a better insight into the history of development of the Rhynchocephalian type, whether they will show that *Hatteria* was at one time not its only representative, and whether such evidence will be found in New Zealand at all, the future must decide.

* In this way the name *Rhynchocephalus* may be preserved, which, otherwise, must give way to the prior *Hatteria*.

EXPLANATION OF FIGURES.

PLATE XXVI.

Figs. 1-7. Skull. In fig. 3 the temporal and zygomatic arches are removed to show the side of the base of the skull.

a. Exoccipital.
b. Alisphenoid.
c. Stapes.
d. Paroccipital.
e. Posterior hypapophysis of basisphenoid.
f. Anterior hypapophysis of basisphenoid.
g. Parietal.
h. Mastoid.
i. Prefrontal.
k. Lacrymal.
l. Postfrontal.
m. Os quadrato-jugale of Stannius.

n. Zygomatic.
o. Os quadratum.
p. Columella.
q. Vomer.
r. Pterygoid.
s. Palatine.
t. Ectopterygoid.
u. Dentary.
v. Splenial.
w. Articular.
x. Coronoid.

Figs. 8-15. Dentition.

Fig. 8. Front view of the intermaxillary teeth of a very old example.

Fig. 9. The same of an example of less age, or of one in which the teeth had not been used for some time.

Fig. 10. Front view of the intermaxillary teeth of a young example.

Fig. 11. Lateral view of the dentition of the same example.

Fig. 12. Lateral view of the dentition of an adult *Uromastix hardwickii*.

Fig. 13. Front view of the same. *i.* Intermaxillary. *n.* Nasal opening. *m.* Dental process of mandible.

Fig. 14. Front view of the anterior teeth of a young *Uromastix hardwickii*.

Fig. 15. Front view of the anterior teeth of an adult *Uromastix spinipes*.

Fig. 16. Tongue and trachea, the latter slit open behind the larynx.

a. Anterior cartilage.
b. Posterior cartilage; *b'*, its tuberosity for insertion of the dilatator-muscle.
c. Musculus dilatator glottidis.

PLATE XXVII.

Fig. 17. First nine vertebræ. Development of hæmapophysis into uncinæ process.

a. Sternum with lateral slit for articulation with coracoid.
b. Episternum.
c. Clavicle.
d. Hæmapophysis of first sternal rib.
e, e'. Hypapophyses.

Fig. 18. Front view of epistropheus.

Fig. 19. Back view of the same.

Fig. 20. Inner view of the middle portion of the abdominal sternum.

a. Anomalous joint between central and lateral pieces of abdominal rib.

b. Intermediate (floating) abdominal rib.

c. Dilated lower piece of hæmapophysis.

Fig. 21. The five anterior caudal vertebræ, lower view. *a.* Hæmapophysis.

Fig. 22. Vertical section of three dorsal vertebræ.

Fig. 23. Vertical section of four (7th to 10th) caudal vertebræ. *a.* Epiphysial line passing through the middle of centrum.

Fig. 24. Isolated rib of 17th vertebra.

a. Upper (dorsal) hæmapophysial piece.

b. Lower (ventral) hæmapophysial piece.

c. Right half of abdominal rib.

Fig. 25. Separate view of scapula and coracoid.

d. Cartilaginous; and *e*, osseous portion of coracoid.

f. Cartilaginous; and *g*, osseous portion of scapula.

h. Acromial tuberosity.

Fig. 26. Sternum with abdominal ribs. Bones of the shoulder in their natural position.

a. Sternum. *b.* Episternum. *c.* Clavicle. *d-h*, as in fig. 25.

Fig. 27. Lateral; and fig. 28, lower view of pelvis.

a. The two sacral vertebræ.

b. Os ilium.

c. Uncinate process of os pubis.

d. Tuberositas ischii.

Fig. 29. Vent with the reticulated openings of the paired anal gland. A scalpel is introduced on one side to press the gland outwards.

Fig. 30. Vertical; and fig. 31, transverse section of the anal gland (3 × natural size).

a. Vacuity behind external opening.

b. An unusually broad septum.

PLATE XXVIII.

Fig. 32. Muscles of ventral region.

a. Musculus pectoralis major.

b. Part of outer layer of musculus obliquus externus.

c. Subcutaneous fibrous tissue.

d. Musculus rectus.

e. Ninth; and *e'*, eleventh abdominal rib with corresponding hæmapophyses.

f. Abdominal fascia.

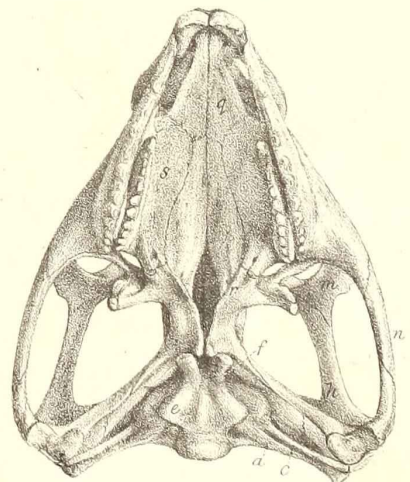
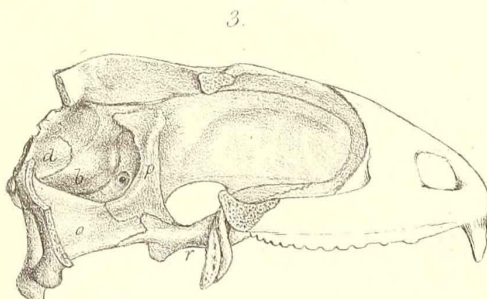
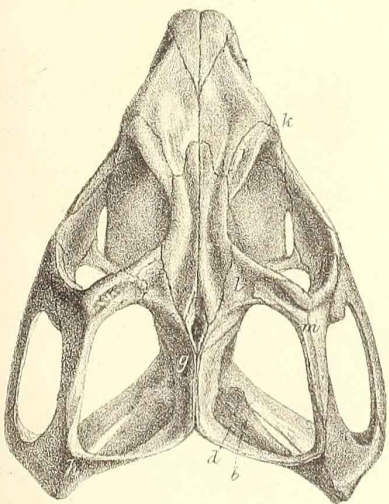
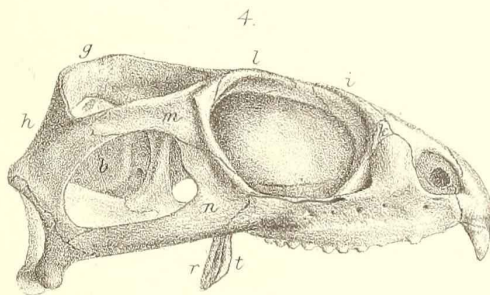
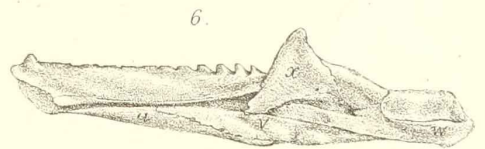
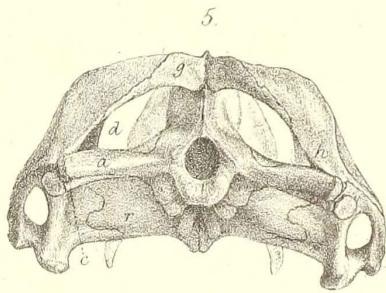
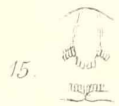
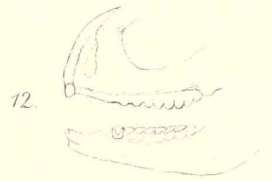
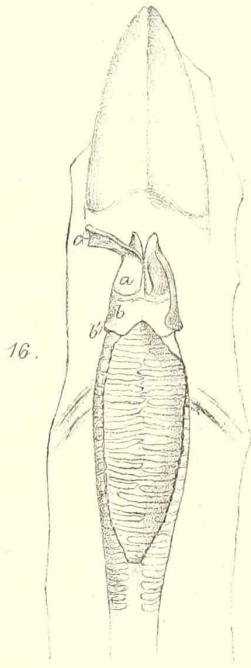
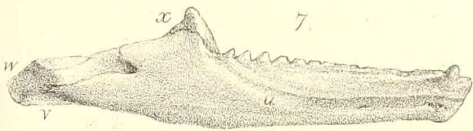
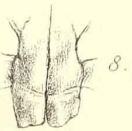
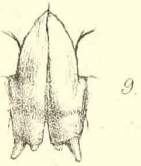
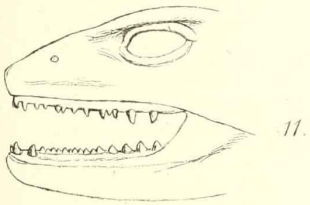
g. Three of the transverse series of ventral plates.

Fig. 33. Lateral muscles of trunk (the Latissimus dorsi is removed).

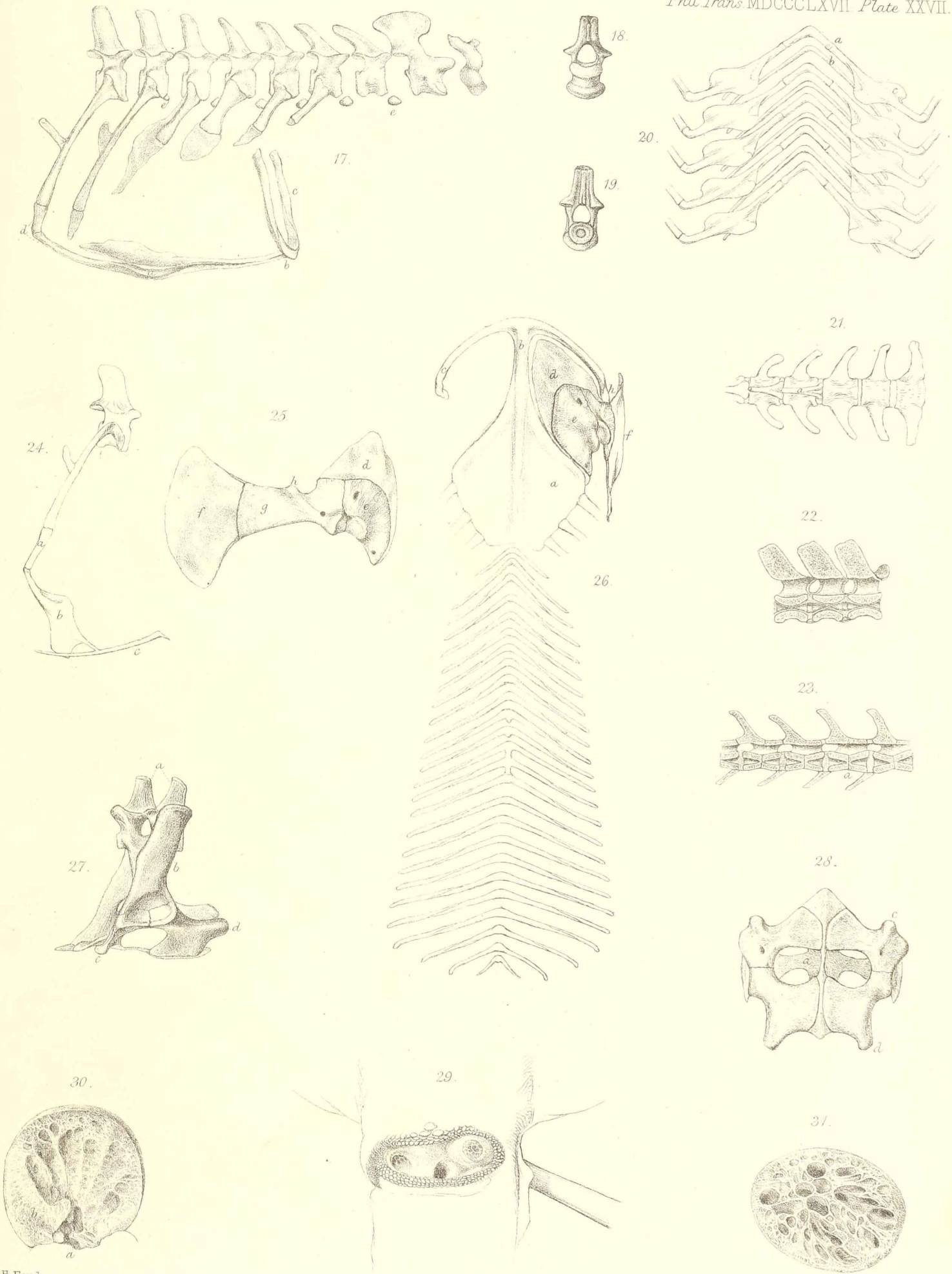
- a.* Longissimus dorsi confluent with Sacrolumbaris.
- b.* Small muscles for the spines of the dorsal crest.
- c.* Obliquus externus; *c'*. outer layer; *c''*. middle layer.
- d.* Hinder portion of pectoralis major, partly intercalated between the outer and middle layers of obliquus externus.
- e-h.* A portion of the obliquus externus has been removed to show:—
- e.* Upper anterior angle of the dilated costal hæmapophysis.
- f.* Musculus intercostalis.
- g.* Muscle connecting the bodies of two costal hæmapophyses.
- h.* Muscle connecting the body of a hæmapophysis with the upper posterior angle of the succeeding hæmapophysis.
- i, i.* Uncinate processes of the ribs.

Fig. 34. Muscles of hind limb. The hind limb is drawn forwards, showing its posterior side.

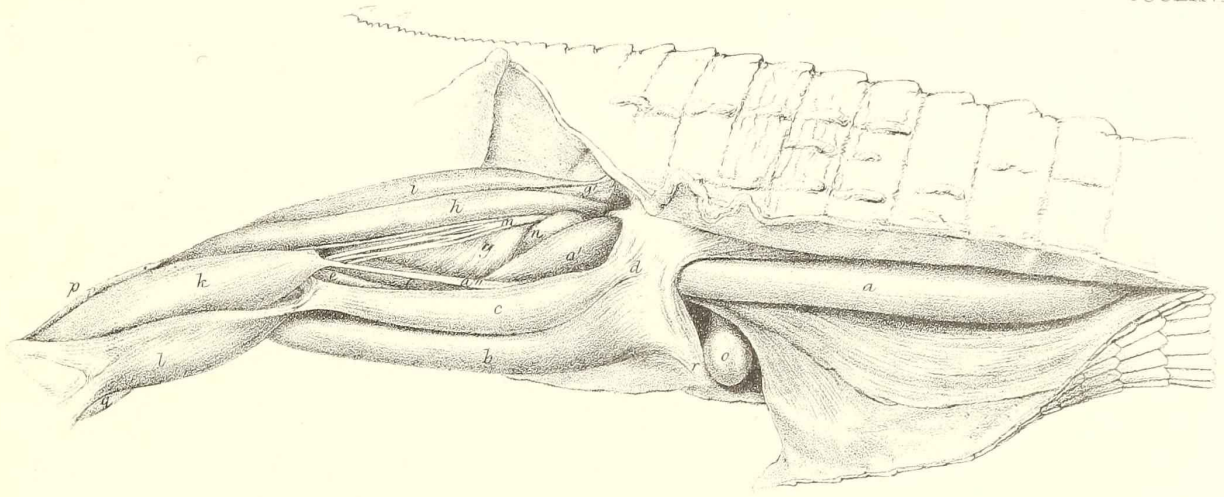
- a.* Extensor femoris caudalis. *a'*. Continuation of the same with additional fascicles from ligament *d*. *a''*. Long tendon of the same muscle.
- b.* Part of the great Flexor cruris (Semimembranosus and Semitendinosus).
- c.* Slender portion of the great Flexor cruris (Biceps). The two latter muscles are drawn downwards, the margins of *c* and *h* being collateral.
- d.* Transverse ligament between tuber ischii (*r*) and root of tail.
- e.* Terminal portion of Musculus gracilis.
- f.* Adductor-branch of the great Flexor cruris.
- g.* Musculus iliacus internus. *g'*. Its origin, covered by the M. rectus (*i*).
- h.* Musculus agitator caudæ.
- i.* Principal head of the Extensor cruris (M. rectus).
- k.* Gastrocnemius.
- l.* Soleus.
- m.* Nervus cruralis.
- n.* Trochanter-region of femur.
- o.* Anal gland.
- p.* Musculus peronæus longus.
- q.* Musculus tibialis anticus.
- r.* Tuber ischii.



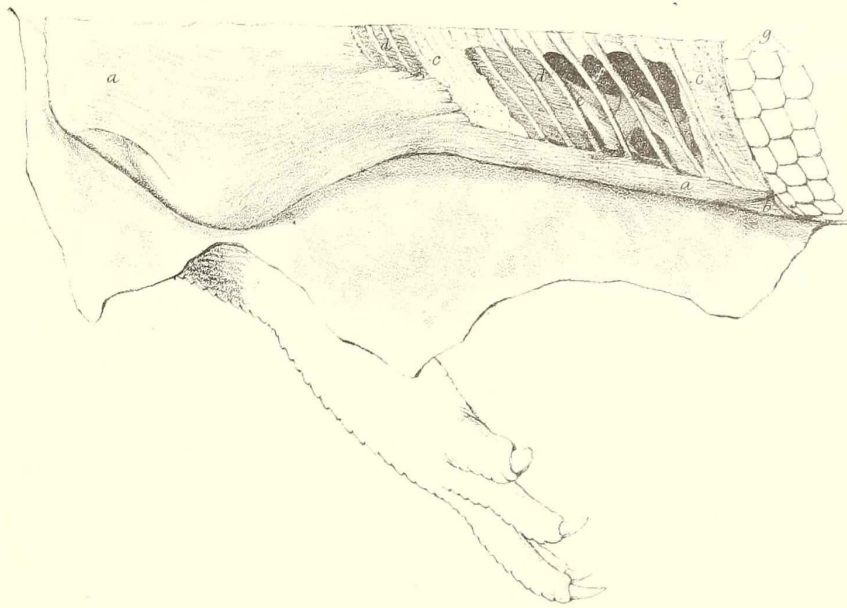




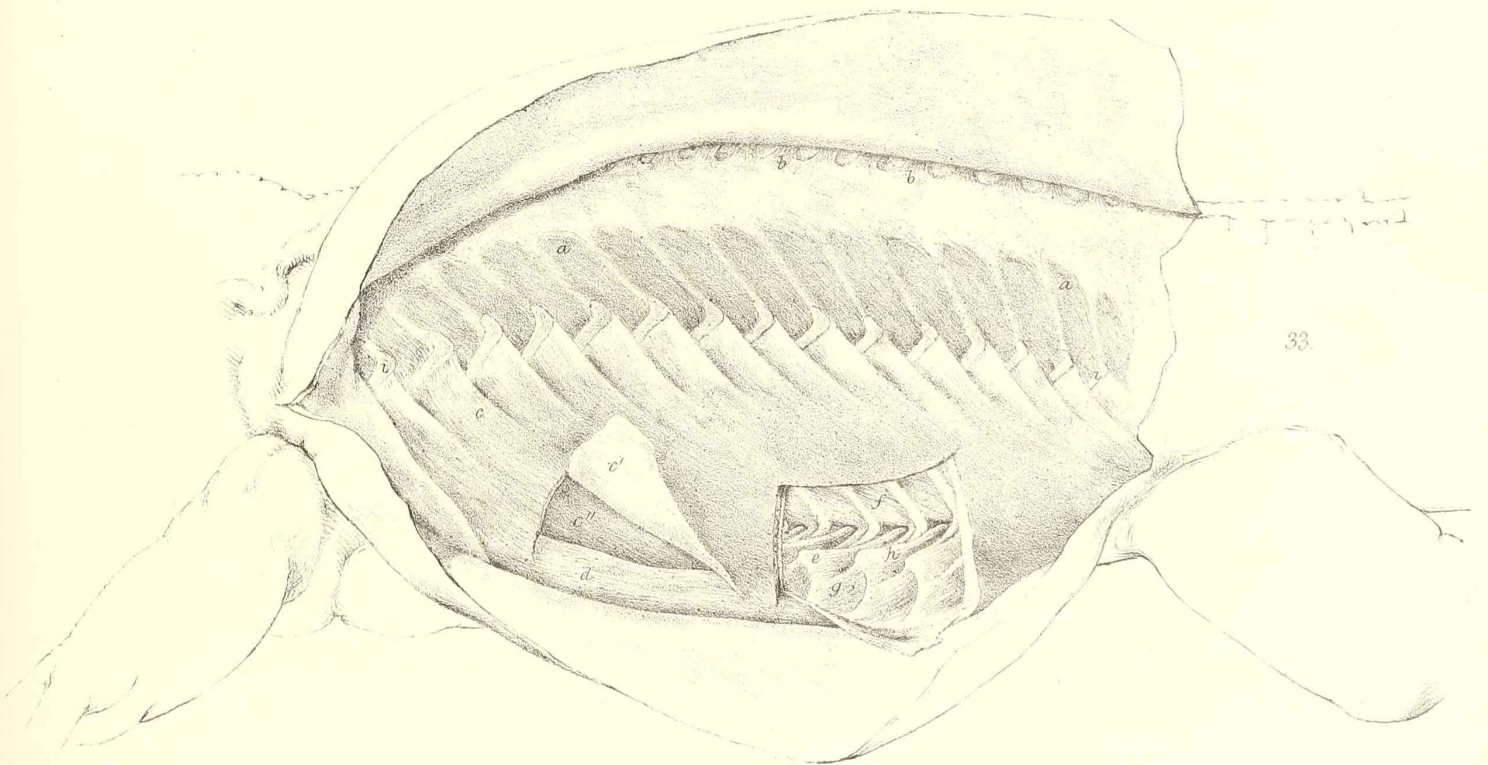




34



32



33