

2/99

Kohler Collection

DARWIN
BC AD 1710

413795-1001

T. C. Jones

127

JT/kk



7
A MANUAL


OF THE

ANATOMY OF VERTEBRATED ANIMALS.

A MANUAL
OF THE
ANATOMY OF VERTEBRATED
ANIMALS.

BY

THOMAS H. HUXLEY, LL.D., F.R.S.



LONDON:

J. & A. CHURCHILL, NEW BURLINGTON STREET.

1871.

P R E F A C E.

THE present work is intended to provide students of comparative anatomy with a condensed statement of the most important facts relating to the structure of vertebrated animals, which have hitherto been ascertained. Except in a very few cases, I have intentionally abstained from burdening the text with references; and, therefore, the reader, while he is justly entitled to hold me responsible for any errors he may detect, will do well to give me no credit for what may seem original, unless his knowledge is sufficient to render him a competent judge on that head.

About two-thirds of the illustrations are original, the rest* are copied from figures given by Agassiz, Bischoff, Burmeister, Busch, Carus, Dugès, Flower, Gegenbaur, Hyrtl, Von Meyer, Müller, Pander and D'Alton, Parker, Quatrefages, and Traquair.

A considerable portion of the book has been in type for

* Namely, Figures 1, 6, 10, 11, 12, 13, 15, 18, 23, 26, 28, 29, 30, 31, 36, 39, 41, 42, 46, 50, 51, 54, 55, 56, 57, 58, 59, 60, 61, 75, 79, 82, 101, 107, 108, 109, 110.

some years; and this circumstance must be my excuse for appearing to ignore the views of several valued contemporaries. I refer more especially to those contained in recently published works of Professors Flower and Gegenbaur.

London, September, 1871.

CONTENTS.



CHAPTER I.

	PAGE
A General View of the Organization of the Vertebrata—the Vertebrate Skeleton	1

CHAPTER II.

The Muscles and the Viscera—A General View of the Organiza- tion of the Vertebrata	45
---	----

CHAPTER III.

The Provinces of the Vertebrata—The Class Pisces	112
--	-----

CHAPTER IV.

The Class Amphibia.	172
-----------------------------	-----

CHAPTER V.

The Classification and the Osteology of the Reptilia	193
--	-----

CHAPTER VI.

The Classification and the Osteology of Birds	272
---	-----

CHAPTER VII.

The Muscles and the Viscera of the Sauropsida	299
---	-----

CHAPTER VIII.

The Classification and Organization of the Mammalia	319
---	-----

THE ANATOMY

OF

VERTEBRATED ANIMALS.

CHAPTER I.

A GENERAL VIEW OF THE ORGANIZATION OF THE VERTEBRATA—THE VERTEBRATE SKELETON.

The Distinctive Characters of the Vertebrata.—The *Vertebrata* are distinguished from all other animals by the circumstance that a transverse and vertical section of the body exhibits two cavities, completely separated from one another by a partition. The dorsal cavity contains the cerebro-spinal nervous system; the ventral, the alimentary canal, the heart, and, usually, a double chain of ganglia, which passes under the name of the “sympathetic.” It is probable that this sympathetic nervous system represents, wholly or partially, the principal nervous system of the *Annulosa* and *Mollusca*. And, in any case, the central parts of the cerebro-spinal nervous system, viz. the brain and the spinal cord, would appear to be unrepresented among invertebrated animals. For these structures are the results of the metamorphosis of a part of the primitive epidermic covering of the germ, and only acquire their ultimate position, in the interior of the dorsal tube, by the development and union of outgrowths of the blastoderm, which are not formed in the *Invertebrata*.*

* It is possible that an exception to this rule may be found in the *Ascidians*. The tails of the larvæ of these animals exhibit an axial structure, which has a cer-

tain resemblance to a vertebrate notochord; and the walls of the pharynx are perforated, much as in *Amphioxus*.

Again, in the partition between the cerebro-spinal and visceral tubes, certain structures, which are not represented in invertebrated animals, are contained. During the embryonic condition of all vertebrates, the centre of the partition is occupied by an elongated, cellular, cylindroidal mass—the *notochord*, or *chorda dorsalis*. And this structure persists throughout life in some *Vertebrata*; but, in most, it is more or less completely replaced by a jointed, partly fibrous and cartilaginous, and partly bony, *vertebral column*.

In all *Vertebrata*, that part of the wall of the visceral tube which lies at the sides of, and immediately behind, the mouth, exhibits, at a certain stage of embryonic development, a series of thickenings, parallel with one another and transverse to the axis of the body, which may be five or more in number, and are termed the *visceral arches*. The intervals between these arches become clefts, which place the pharyngeal cavity, temporarily or permanently, in communication with the exterior. Nothing corresponding with these arches and clefts is known in the *Invertebrata*.

A vertebrated animal may be devoid of articulated limbs, and it never possesses more than two pairs. These are always provided with an internal skeleton, to which the muscles moving the limbs are attached. The limbs of invertebrated animals are commonly more numerous, and their skeleton is always external.

When invertebrated animals are provided with masticatory organs, the latter are either hard productions of the alimentary mucous membrane, or are modified limbs. Vertebrated animals also commonly possess hard productions of the alimentary mucous membrane in the form of teeth; but their jaws are always parts of the walls of the parietes of the head, and have nothing to do with limbs.

All vertebrated animals have a complete vascular system. In the thorax and abdomen, in place of a single perivisceral cavity in communication with the vascular system, and serving as a blood-sinus, there are one or more serous sacs. These invest the principal viscera, and may or may

not communicate with the exterior—recalling, in the latter case, the atrial cavities of *Mollusca*.

In all *Vertebrata*, except *Amphioxus*, there is a single valvular heart, and all possess a *hepatic portal system*; the blood of the alimentary canal never being wholly returned directly to the heart by the ordinary veins, but being more or less completely collected into a trunk—the *portal vein*, which ramifies through and supplies the liver.

The Development of the Vertebrata.—The ova of *Vertebrata* have the same primary composition as those of other animals, consisting of a *germinal vesicle*, containing one or many *germinal spots*, and included within a *vitellus*, upon the amount of which the very variable size of the vertebrate ovum chiefly depends. The vitellus is surrounded by a *vitelline membrane*, and this may receive additional investments in the form of layers of *albumen*, and of an outer, coriaceous, or calcified *shell*.

The *spermatozoa* are always actively mobile, and, save in some rare and exceptional cases, are developed in distinct individuals from those which produce ova.

Impregnation may take place, either subsequently to the extrusion of the egg, when, of course, the whole development of the young goes on outside the body of the *oviparous* parent; or it may occur before the extrusion of the egg. In the latter case, the development of the egg in the interior of the body may go no further than the formation of a patch of primary tissue; as in birds, where the so-called *cicatricula*, or “tread,” which is observable in the new-laid egg, is of this nature. Or, the development of the young may be completed while the egg remains in the interior of the body of the parent, but quite free and unconnected with it; as in those vertebrates which are termed *ovoviviparous*. Or, the young may receive nourishment from its *viviparous* parent, before birth, by the close apposition of certain vascular appendages of its body to the walls of the cavity in which it undergoes its development.

The vascular appendages in question constitute the chief

part of what is called the *placenta*, and may be developed from the umbilical vesicle (as in *Mustelus* among Sharks), or from the allantois and chorion (as in most mammals). At birth, they may be either simply detached from the substance of the parental organism, or a part of the latter may be thrown off along with them and replaced by a new growth. In

Fig. 1.

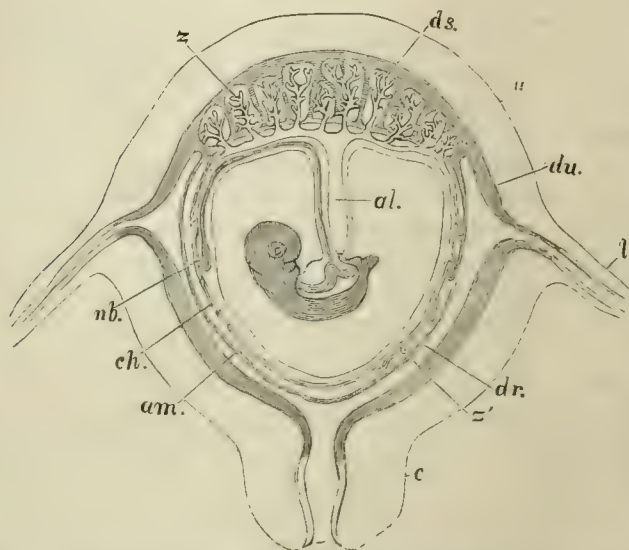


Fig. 1.—Diagrammatic section of the pregnant uterus of a deciduate placental mammal (*Homo*): *u*, uterus; *l*, Fallopian tube; *c*, neck of the uterus; *du*, uterine decidua; *ds*, decidua serotina; *dr*, decidua reflexa; *z*, *z'*, villi; *ch*, chorion; *am*, amnion; *nb*, umbilical vesicle; *al*, allantois.

the highest vertebrates, the dependence of the young upon the parent for nutrition does not cease even at birth; but certain cutaneous glands secrete a fluid called *milk*, upon which the young is fed for a longer or shorter time.

When development takes place outside the body, it may be independent of parental aid, as in ordinary fishes; but, among some reptiles and in most birds, the parent supplies

the amount of heat, in excess of the ordinary temperature of the air, which is required, from its own body, by the process of *incubation*.

The first step in the development of the embryo is the division of the vitelline substance into *cleavage-masses*, of which there are at first two, then four, then eight, and so on. The germinal vesicle is no longer seen, but each cleavage-mass contains a *nucleus*. The cleavage-masses eventually become very small, and are called *embryo-cells*, as the body of the embryo is built up out of them. The process of yolk-division may be either *complete* or *partial*. In the former case, it, from the first, affects the whole yolk; in the latter, it commences in part of the yolk, and gradually extends to the rest. The *blastoderm*, or embryogenic tissue in which it results, very early exhibits two distinguishable strata—an inner, the so-called *mucous stratum* (*hypoblast*), which gives rise to the epithelium of the alimentary tract; and an outer, the *serous stratum* (*epiblast*), from which the epidermis and the cerebro-spinal nervous centres are evolved. Between these appears the *intermediate stratum* (*mesoblast*), which gives rise to all the structures (save the brain and spinal marrow) which, in the adult, are included between the epidermis of the integument and the epithelium of the alimentary tract and its appendages.

A linear depression, the *primitive groove* (Fig. 2, A, c), makes its appearance on the surface of the blastoderm, and the substance of the mesoblast along each side of this groove grows up, carrying with it the superjacent epiblast. Thus are produced the two *dorsal laminæ*, the free edges of which arch over towards one another, and eventually unite, so as to convert the primitive groove into the cerebro-spinal canal. The portion of the epiblast which lines this, cut off from the rest, becomes thickened, and takes on the structure of the brain, or *Encephalon*, in the region of the head; and of the spinal cord, or *Myelon*, in the region of the spine. The rest of the epiblast is converted into the epidermis.

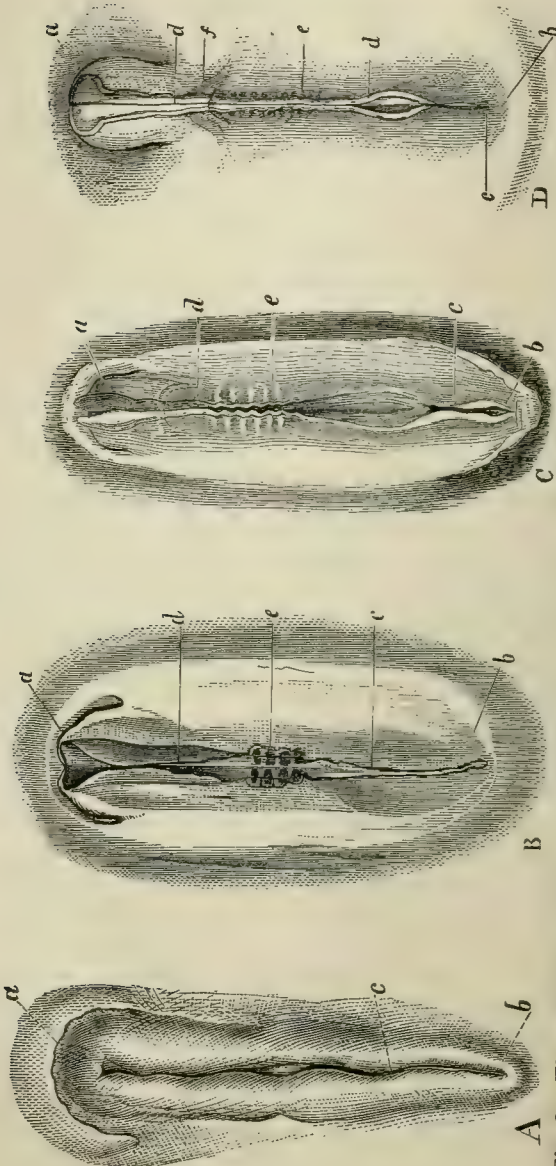


Fig. 2.

Fig. 2.—The early stages of the development of the body of a Fowl.—A, the first rudiment of the embryo; *a* its cephalic, *b* its caudal, end; *c*, the primitive groove.—B, the embryo further advanced; *a*, *b*, *c*, as before; *d*, the dorsal laminae as yet developed only in the cephalic region, and not quite united in the middle line; *e*, the proto-vertebrae.—C, the letters as before. The dorsal laminae have united throughout the greater part of the cephalic region, and are beginning to unite in the anterior spinal region.—D, embryo further advanced (the second day of incubation), the dorsal laminae having united throughout nearly their whole length. The protovertebrae have increased in number, and the omphalomeseraic veins, *f*, are visible. The embryos are drawn of the same absolute length, but, in nature, the older are longer than the younger.

The part of the blastoderm which lies external to the dorsal laminæ forms the *ventral laminæ*; and these bend downwards and inwards, at a short distance on either side of the dorsal tube, to become the walls of a ventral, or visceral, tube. The ventral laminæ carry the epiblast on their outer surfaces, and the hypoblast on their inner surfaces, and thus, in most cases, tend to constrict off the central from the peripheral portions of the blastoderm. The latter, extending over the yelk, incloses it in a kind of bag. This bag is the first-formed and the most constant of the temporary, or fœtal, appendages of the young vertebrate, the *umbilical vesicle*.

While these changes are occurring, the mesoblast splits, throughout the regions of the thorax and abdomen, from its ventral margin, nearly up to the *notochord* (which has been developed, in the meanwhile, by histological differentiation of the axial indifferent tissue, immediately under the floor of the primitive groove), into two *lamellæ*. One of these, the *visceral lamella*, remains closely adherent to the hypoblast, forming with it the *splanchnopleure*, and eventually becomes the proper wall of the enteric canal; while the other, the *parietal lamella*, follows the epiblast, forming with it the *somatopleure*, which is converted into the parietes of the thorax and abdomen. The point of the middle line of the abdomen at which the somatopleures eventually unite, is the *umbilicus*.

The walls of the cavity formed by the splitting of the ventral laminæ acquire an epithelial lining, and become the great *pleuroperitoneal* serous membranes.

The Fœtal Appendages of the Vertebrata.—At its outer margin, that part of the somatopleure which is to be converted into the thoracic and abdominal wall of the embryo, grows up anteriorly, posteriorly, and laterally, over the body of the embryo. The free margins of this fold gradually approach one another, and, ultimately uniting, the inner layer of the fold becomes converted into a sac filled with a clear fluid, the *Amnion*; while the outer layer either disappears, or coa-

lesces with the vitelline membrane, to form the *Chorion* (Fig. 3).

Fig. 3.

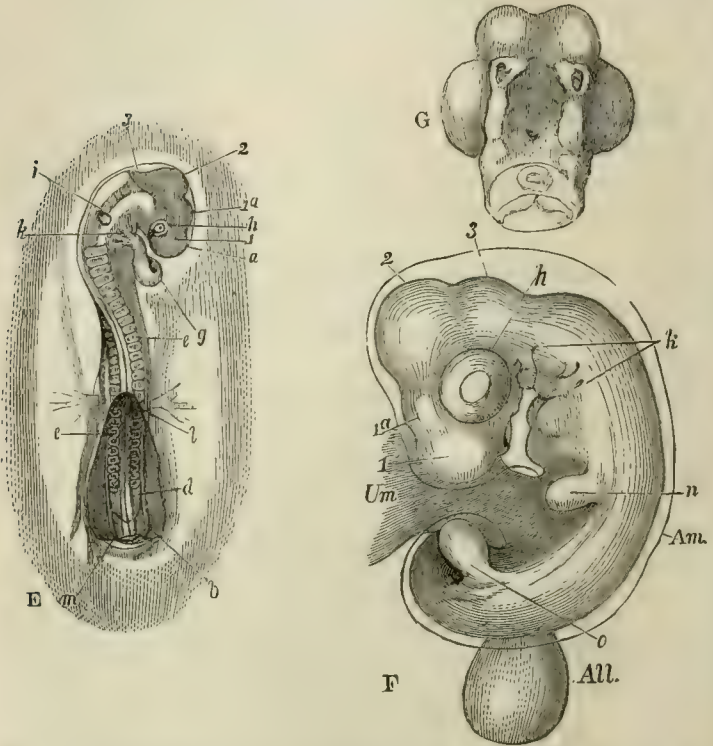


Fig. 3.—Later stages of the development of the body of a Fowl than those represented in Fig. 2.—E, embryo at the third day of incubation; *g*, heart; *h*, eye; *i*, ear; *k*, visceral arches and clefts; *l*, *m*, anterior and posterior folds of the amnion which have not yet united over the body; 1, 2, 3, first, second, and third cerebral vesicles; 1^a, vesicle of the third ventricle.—F, embryo at the fifth day of incubation. The letters as before, except *n*, *o*, rudiments of the anterior and posterior extremities; *Am*, amnion; *All* (the allantois, hanging down from its pedicle); *Um*, umbilical vesicle.—G, under-view of the head of the foregoing, the first visceral arch being cut away.

Thus the amnion incloses the body of the embryo, but not the umbilical sac. At most, as the constricted neck,

which unites the umbilical sac with the cavity of the future intestine, becomes narrowed and elongated into the *vitelline duct*, and as the sac itself diminishes in relative size, the amnion, increasing in absolute and relative dimensions, and becoming distended with fluid, is reflected over it (Fig. 1).

A third foetal appendage, the *Allantois*, commences as a single, or double, outgrowth from the under-surface of the mesoblast, behind the alimentary tract; but soon takes the form of a vesicle, and receives the ducts of the *primordial kidneys*, or *Wolffian bodies*. It is supplied with blood by two arteries, called *hypogastric*, which spring from the aorta; and it varies very much in its development. It may become so large as to invest all the rest of the embryo, in the respiratory, or nutritive, processes of which it then takes an important share.

The splitting of the ventral laminæ, and the formation of a pleuroperitoneal cavity, appear to take place in all *Vertebrata*. Usually, there is a more or less distinct umbilical sac; but in fishes and *Amphibia* there is no amnion; and the allantois, if it is developed at all, remains very small in these two groups.

Reptiles, birds, and mammals have all these foetal appendages. At birth, or when the egg is hatched, the amnion bursts and is thrown off, and so much of the allantois as lies outside the walls of the body, is similarly exuviated; but that part of it which is situated within the body is very generally converted, behind and below, into the urinary bladder, and, in front and above, into a ligamentous cord, the *urachus*, which connects the bladder with the front wall of the abdomen. The umbilical vesicle may either be cast off, or taken into the interior of the body and gradually absorbed.

The majority of the visceral clefts of fishes and of many *Amphibia* remain open throughout life; and the visceral arches of all fishes (except *Amphioxus*), and of all *Amphibia*, throw out filamentous or lamellar processes, which receive branches from the aortic arches, and, as *branchiæ*, subserve

respiration. In other *Vertebrata* all the visceral clefts become closed and, with the frequent exception of the first, obliterated; and no branchiæ are developed upon any of the visceral arches.

In all vertebrated animals, a system of relatively, or absolutely, hard parts affords protection, or support, to the softer tissues of the body. These, according as they are situated upon the surface of the body, or are deeper-seated, are called *exoskeleton*, or *endoskeleton*.

The Vertebrate Endoskeleton.—This consists of connective tissue, to which cartilage and bone may be added in various proportions; together with the tissue of the notochord and its sheath, which cannot be classed under either of these heads. The endoskeleton is distinguishable into two independent portions—the one *axial*, or belonging to the head and trunk; the other, *appendicular*, to the limbs.

The *axial endoskeleton* usually consists of two systems of skeletal parts, the *spinal system*, and the *cranial system*, the distinction between which arises in the following way in the higher *Vertebrata*.

The primitive groove is, at first, a simple straight depression, of equal diameter throughout; but, as its sides rise, and the dorsal laminae gradually close over (this process commencing in the anterior moiety of their length, in the future cephalic region), the one part becomes wider than the other, and indicates the cephalic region (Fig. 4, A). The notochord, which underlies the groove, terminates in a point, at a little distance behind the anterior end of the cephalic enlargement, and indeed under the median of three dilations which it presents. So much of the floor of the enlargement as lies in front of the end of the notochord, bends down at right angles to the rest; so that the anterior enlargement, or *anterior cerebral vesicle*, as it is now called, lies in front of the end of the notochord; the median enlargement, or the *middle cerebral vesicle*, above its extremity; and the hinder enlargement, or the *posterior cerebral vesicle*, behind that extremity (Fig. 4, D and E). The under-

surface of the anterior vesicle lies in a kind of pit, in front of, and rather below, the apex of the notochord, and the *pituitary gland* is developed in connection with it. From the opposite upper surface of the same vesicle the *pineal gland* is evolved, and the part of the anterior cerebral vesicle in connection with which these remarkable bodies arise, is the future *third ventricle*.

Behind, the posterior cerebral vesicle passes into the primitively tubular spinal cord (Fig. 4, A). Where it does so, the head ends, and the spinal column begins; but no line of demarcation is, at first, visible between these two, the indifferent tissues which ensheath the notochord passing, without interruption, from one region to the other, and retaining the same character throughout.

The first essential differentiation between the skull and the vertebral column is effected by the appearance of the *protovertebræ*. At regular intervals, commencing at the anterior part of the cervical region, and gradually extending backwards, the indifferent tissue on each side of the notochord undergoes a histological change, and gives rise to more opaque quadrate masses, on opposite sides of the notochord (Fig. 2, B, C). Each pair of these gradually unite above and below that structure, and send arched prolongations into the walls of the spinal canal, so as to constitute a *protovertebra*.

No *protovertebræ* appear in the floor of the skull, so that, even in this early stage, a clear distinction is drawn between the skull and the spinal column.

The Spinal System.—The *protovertebræ* consist at first of mere indifferent tissue; and it is by a process of histological differentiation within the *protovertebral* masses, that, from its deeper parts, one of the *spinal ganglia* and a *cartilaginous vertebral centrum*,—from its superficial layer, a *segment of the dorsal muscles*, are produced.

Chondrification extends upwards into the walls of the dorsal tube, to produce the *neural arch* and *spine* of each *vertebra*; and, outwards, into the wall of the thoracic and

Fig. 4.

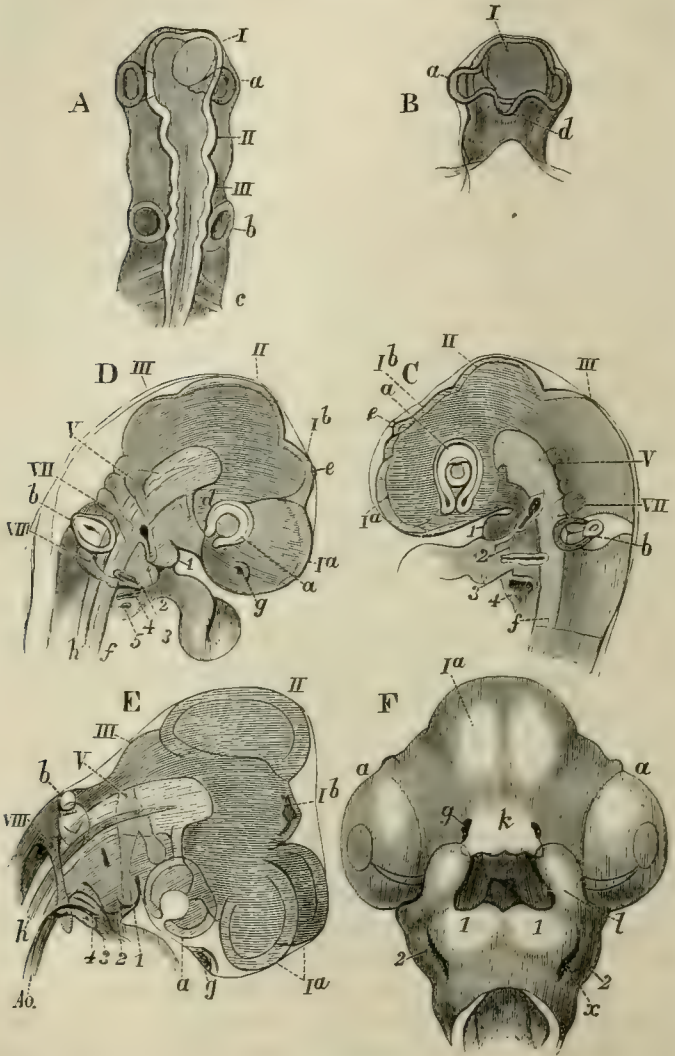


Fig. 4.—Successive stages of the development of the head of a Chick. I, II, III, first, second, and third cerebral vesicles; *Ia*, vesicle of the cerebral hemisphere; *Ib*, vesicle of the third ventricle; *a*, rudiments of the eyes and optic nerves; *b*, of the ears; *g*, of the olfactory

organs; *d*, the infundibulum; *e*, the pineal gland; *c*, protovertebræ; *h*, notochord; 1, 2, 3, 4, 5, visceral arches; V, VII, VIII, the trigeminal, portio dura, and ninth and tenth pairs of cranial nerves; *k*, the nasal process; *l*, the maxillary process; *x*, the first visceral cleft. A, B, upper and under views of the head of a Chick at the end of the second day. C, side-view at the third day. D, side-view at seventy-five hours. E, side-view of the head of a Chick at the fifth day, which has been subjected to slight pressure. F, head of a Chick at the sixth day, viewed from below.

abdominal part of the ventral tube, to give rise to the *transverse processes* and *ribs*. In fishes, the latter remain distinct and separate from one another, at their distal ends; but, in most reptiles, in birds, and in mammals, the ends of some of the anterior ribs, on both sides, unite together, and then the united parts coalesce in the middle line to form a median subthoracic cartilage—the *sternum*.

When ossification sets in, the centra of the vertebræ are usually ossified, in great measure, from ringlike deposits which closely invest the notochord; the arches, from two lateral deposits, which may extend more or less into the centrum. The vertebral and the sternal portions of a rib may each have a separate ossific centre, and become distinct bones; or the sternal parts may remain always cartilaginous. The sternum itself is variously ossified.

Between the completely ossified condition of the vertebral column and its earliest state, there are a multitude of gradations, most of which are more or less completely realised in the adult condition of certain vertebrated animals. The vertebral column may be represented by nothing but a notochord with a structureless, or more or less fibrous, or cartilaginous sheath, with or without rudiments of cartilaginous arches and ribs. Or there may be bony rings, or ensheathing ossifications, in its walls; or it may have ossified neural arches and ribs only, without cartilaginous or osseous centra. The vertebræ may be completely ossified, with very deeply biconcave bodies, the notochord remaining persistent in the doubly conical intervertebral substance; or, ossification may extend, so as to render the centrum concave on one surface and convex on the other, or even convex at each end.

Vertebræ which have centra concave at each end have been conveniently termed *amphicæulous*; those with a cavity in front and a convexity behind, *procæulous*; where the position of the concavity and convexity is reversed, they are *opisthocæulous*.

In the *Mammalia*, the centra of the vertebræ are usually flat at each end, the terminal faces being discoidal *epiphyses*, developed from centres of ossification distinct from that of the centrum itself.

The centra of the vertebræ may be united together by synovial joints, or by ligamentous fibres—the *intervertebral ligaments*. The arches are connected by ligaments, and generally, in addition, by overlapping articular processes called *zygapophyses*, or oblique processes.

In a great many *Vertebrata*, the first and second cervical, or *atlas* and *axis*, vertebræ undergo a singular change; the central ossification of the body of the atlas not coalescing with its lateral and inferior ossifications, but either persisting as a distinct *os odontoideum*, or ankylosing with the body of the axis, and becoming the so-called *odontoid process* of this vertebra.

In *Vertebrata* with well-developed hind limbs, one or more vertebræ, situated at the posterior part of the trunk, usually become peculiarly modified, and give rise to a *sacrum*, with which the pelvic arch is connected by the intermediation of expanded and ankylosed ribs. In front of the sacrum the vertebræ are artificially classed as *cervical*, *dorsal*, and *lumbar*. The first vertebra, the ribs of which are connected with the sternum, is *dorsal*, and all those which lie behind it, and have distinct ribs, are dorsal. Vertebræ without distinct ribs, between the last dorsal and the sacrum, are *lumbar*. Vertebræ, with or without ribs, in front of the first dorsal are *cervical*.

The vertebræ which lie behind the sacrum are *caudal* or *coccygeal*. Very frequently, downward processes of these vertebræ inclose the backward continuation of the aorta, and may be separately ossified as *subcaudal*, or chevron, bones.

A tolerably complete segment of the spinal skeleton may be studied in the anterior part of the thorax of a crocodile (Fig. 5). It presents a proœlous vertebral *centrum* (*C*), united with which by the *neurocentral suture* is the *neural arch*, which rises into the *neural spine* (*N.S.*). Two processes, the *prezygapophyses* (*Z*), extend from the front part of the arch, and have flat articular surfaces turned dorsally. Two others of similar form, but having their articular surfaces turned ventrally, proceed from the posterior face of the neural arch, and are the *postzygapophyses* (*Z'*). By these, which are

Fig. 5.

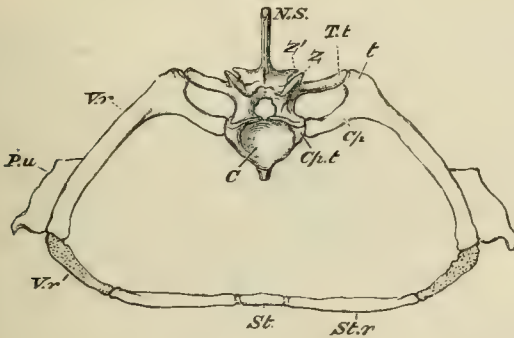


Fig. 5.—A segment of the endoskeleton in the anterior thoracic region of the body of a Crocodile.—*C*, the centrum or body of the vertebra; *N. S.*, the neural spine; *Z*, the prezygapophysis; *Z'*, the postzygapophysis; *T.t*, the transverse process which articulates with the tuberculum of the rib (*t*); *Cp.t*, that which articulates with the capitulum of the rib (*Cp*); *V.r*, the ossified vertebral rib; *V.r'*, the part of the vertebral rib which remains cartilaginous; *St.r*, the sternal rib; *St*, an artificially separated segment of the sternum; *P.u*, the uncinatè process.

often called oblique, or articular, processes, the vertebra articulates with the corresponding processes of its predecessor or successor in the series. The *transverse processes* are two on each side, one superior and one inferior. The former (*T.t*) articulates with the *tuberculum* of the rib, the latter (*Cp.t*) with its *capitulum*. They may, therefore, be called *capitular* and *tubercular transverse processes* respectively. Each rib is divided by an articulation into

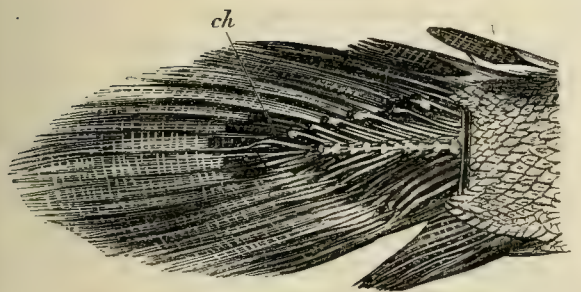
a vertebral (*V.r*) and a sternal (*St.r*) part. The former remains unossified for a considerable distance at its distal end (*V.r'*); the latter is more or less converted into cartilage bone. The proximal end of the vertebral rib bifurcates into a *tuberculum* (*t*) and a *capitulum* (*Cp*). The distal end of the sternal rib unites with the more or less ossified but unsegmented cartilage, which forms the sternum (*St*). A cartilaginous, or partly ossified, *uncinate process* (*P.u*) projects from the posterior edge of the vertebral rib, over the intercostal space. The student will find it convenient to familiarise himself with the conception of such a spinal segment as this, as a type, and to consider the modifications hereafter described with reference to it.

In the majority of the *Vertebrata*, the caudal vertebræ gradually diminish in size towards the extremity of the body, and become reduced, by the non-development of osseous processes or arches, to mere centra. But, in many fishes, which possess well-ossified trunk vertebræ, no distinct centra are developed at the extremity of the caudal region, and the notochord, invested in a more or less thickened, fibrous, or cartilaginous sheath, persists. Notwithstanding this embryonic condition of the axis of the tail, the superior and inferior arches, and the interspinous bones, may be completely formed in cartilage or bone.

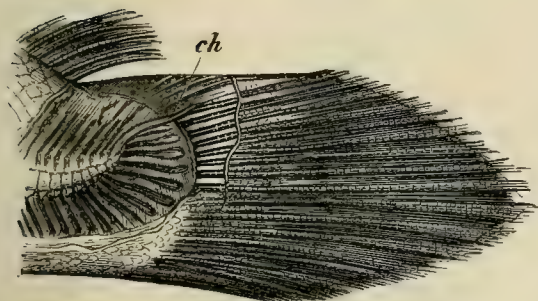
Whatever the condition of the extreme end of the spine of a fish, it occasionally retains the same direction as the trunk part, but is far more generally bent up, so as to form an obtuse angle with the latter. In the former case, the extremity of the spine divides the caudal fin-rays into two nearly equal moieties, an upper and a lower, and the fish is said to be *diphycercal* (Fig. 6, A). In the latter case, the upper division of the caudal fin-rays is much smaller than the lower, and the fish is *heterocercal* (Fig. 6, B, C).

In most osseous fishes the *hypural* bones which support the fin-rays of the inferior division become much expanded, and either remain separate, or coalesce into a wedge-shaped, nearly symmetrical bone, which becomes ankylosed with the last ossified vertebral centrum. The inferior fin-

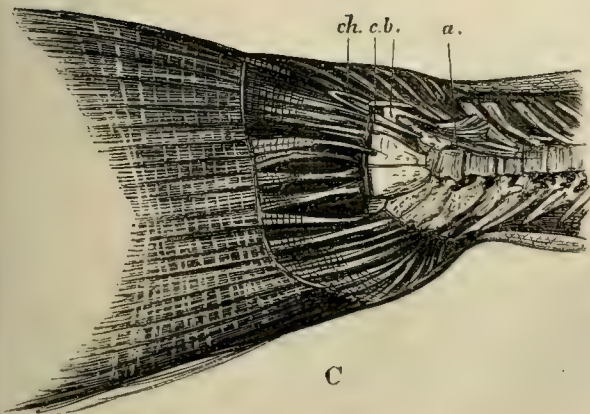
Fig. 6.



A



B



C

Fig. 6.—The caudal extremities of *Polypterus* (A), *Amia* (B), and *Salmo* (C). *Polypterus* is nearly diphy-cercal, the extremity of the notochord (*ch*) being hardly at all bent up. *Amia* is extremely heterocercal, but the hypural bones are hardly modified, and the notochord is invested only by cartilage. *Salmo*, finally, is strongly heterocercal, with expanded hypural bones, and a persistent notochord covered by the osseous plates *a*, *b*, and *c*.

rays are now disposed in such a manner as to give the tail an appearance of symmetry with respect to the axis of the body, and such fishes have been called *homocercal*. Of these homocercal fish, some (as the Salmon, Fig. 6) have the notochord unossified, and protected only by bony plates developed at its sides. In others (as the Stickleback, Perch, &c.), the sheath of the notochord becomes completely ossified and united with the centrum of the last vertebra, which then appears to be prolonged into a bony *urostyle*.

The Cranial System.—As has been stated, no provertebræ appear on the floor of the skull; nor is there any

Fig. 7.

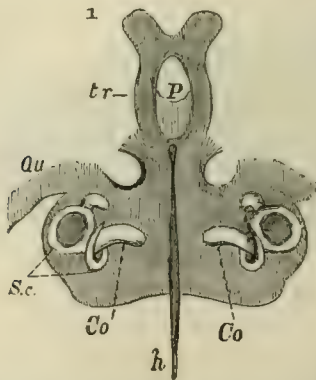


Fig. 7.—The cartilaginous cranium of a Fowl at the sixth day of incubation, viewed from below.—*P*, the pituitary space; *tr*, the *trabecula*, uniting in front, in the bifurcated ethmovomerine plate; *Qu*, the quadrate cartilage; *Sc*, the semicircular canals; *Co*, the cochlea; *h*, the notochord imbedded in the basilar plate.

cranium, nor any developmental stage of a cranium, in which separate cartilaginous centres are known to occur in this region.

On the contrary, when chondrification takes place, it extends continuously forward, on each side of the notochord, and usually invests the anterior termination of that body, more or less completely, as a *basilar* plate.

The basilar plate does not extend under the floor of the pituitary fossa, but the cartilage is continued forwards on each side of this, in the form of two bars, the *trabeculae cranii*. In front of the fossa, the trabeculae reunite and end in a broad plate, usually bifurcated in the middle line—the *ethmovomerine* plate.

On each side of the posterior boundary of the skull, the basilar cartilage grows upwards, and meets with its fellow in the middle line, thus circumscribing the *occipital foramen*, and furnishing the only cartilaginous part of the roof of the skull; for any cartilaginous upgrowths which may be developed in the more anterior parts of the skull do not ordinarily reach its roof, but leave a wide, merely membranous space, or *fontanelle*, over the greater part of the brain.

Before the skull has attained this condition, the organs of the three higher senses have made their appearance in pairs at its sides; the *olfactory* being most anterior, the *ocular* next, the *auditory* posterior (Fig. 4).

Each of these organs is, primitively, an involution, or sac, of the integument; and each acquires a particular skeleton, which, in the case of the nose, is furnished by the ethmovomerine part of the skull; while, in that of the eyes, it appertains to the organ, is fibrous, cartilaginous, or osseous, and remains distinct from the skull. In the case of the ear, it is cartilaginous, and eventually osseous: whether primitively distinct or not, it early forms one mass with the skull, immediately in front of the occipital arch, and often constitutes a very important part of the walls of the fully-formed cranium.

The ethmovomerine cartilages spread over the nasal sacs, roof them in, cover them externally, and send down a partition between them. The partition is the proper *ethmoid*, the *lamina perpendicularis* of human anatomy; the posterolateral parts of the ethmovomerine cartilages, on each side of the partition, occupy the situation of the *pre-frontals*, or *lateral masses of the ethmoid* of human anatomy. The ingrowths of the lateral walls, by which the nasal

mucous membrane acquires a larger surface, are the *turbinals*.

Riblike cartilaginous rods appear in the first, second, and, more or fewer, of the succeeding, visceral arches in all but the lowest *Vertebrata*. The upper ends of the first and second of these become connected with the auditory capsule, which lies immediately above them.

The first visceral arch bounds the cavity of the mouth behind, and marks the position of the *mandible* or lower jaw. The cartilage which it contains is termed *Meckel's cartilage*.

The cartilaginous rod contained in the second visceral arch of each side is the rudiment of the *hyoidean* apparatus.

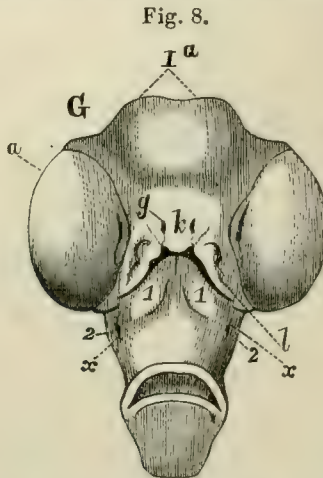


Fig. 8.—Under-view of the head of a Fowl at the seventh day of incubation.—*Ia*, the cerebral hemispheres causing the integument to bulge; *a*, the eyes; *g*, the olfactory sacs; *h*, the fronto-nasal process; *l*, the maxillary process; 1, 2, the first and second visceral arches; *x*, the remains of the first visceral cleft.

Like the preceding, it unites with its fellow in the ventral median line, where the so-called "body" of the hyoid arises.

A ridge, continued forward from the first visceral arch to the olfactory sac (Fig. 4, F; Fig. 8, *l*), bounds the mouth on each side, and is called the *maxillary process*. A cartilaginous *palato-pterygoid* rod, developed in this process,

becomes connected with Meckel's cartilage behind, and with the prefrontal cartilage in front.

The maxillary process is, at first, separated by a notch corresponding with each nasal sac, from the boundary of the antero-median part of the mouth, which is formed by the free posterior edge of a *fronto-nasal process* (Fig. 4, F; Fig. 8, *k*). This separates the nasal sacs, and contains the cartilaginous, ethmovomerine, anterior termination of the skull. The notch is eventually obliterated by the union of the fronto-nasal and maxillary processes, externally; but it may remain open internally, and then gives rise to the *posterior nasal aperture*, by which the nasal cavity is placed in communication with that of the mouth.

The General Modifications of the Vertebrate Skull.—The lowest vertebrated animal, *Amphioxus*, has no skull. In a great many fishes the development of the skull carries it no further than to a condition which is substantially similar to one of the embryonic stages now described; that is to say, there is a cartilaginous *primordial cranium*, with or without superficial granular ossifications, but devoid of any proper cranial bones. The facial apparatus is either incompletely developed, as in the Lamprey; or, the upper jaw is represented, on each side, by a cartilage answering to the palato-pterygoid and part of Meckel's cartilage, while the larger, distal portion of that cartilage becomes articulated with the rest, and forms the lower jaw. This condition is observable in the Sharks and Rays. In other fishes, and in all the higher *Vertebrata*, the cartilaginous cranium and facial arches may persist to a greater or less extent; but bones are added to them, which may be almost wholly membrane bones, as in the Sturgeon; or may be the result of the ossification of the cartilaginous cranium itself, from definite centres, as well as of the development of superimposed membrane bones.

The Osseous Brain-case.—When the skull undergoes complete ossification, osseous matter is thrown down at not fewer than three points in the middle of its cartilaginous

floor. The ossific deposit, nearest the occipital foramen, becomes the *basi-occipital* bone; that which takes place in the floor of the pituitary fossa becomes the *basisphenoid*; that which appears in the reunited trabeculæ, in front of the fossa, gives rise to the *presphenoid*. Again, in front of, and outside, the cranial cavity, the *ethmoid* may be represented by one or more distinct ossifications.

An ossific centre may appear in the cartilage on each side of the occipital foramen, and give rise to the *ex-occipital*; and above it, to form the *supra-occipital*. The four occipital elements, uniting together more or less closely, compose the *occipital segment* of the skull.

In front of the auditory capsules and of the exit of the third division of the fifth nerve, a centre of ossification may appear on each side and give rise to the *alisphenoid*; which, normally, becomes united below with the *basisphenoid*.

In front of, or above, the exits of the optic nerves, the *orbitosphenoidal* ossifications may appear and unite below with the *presphenoid*.

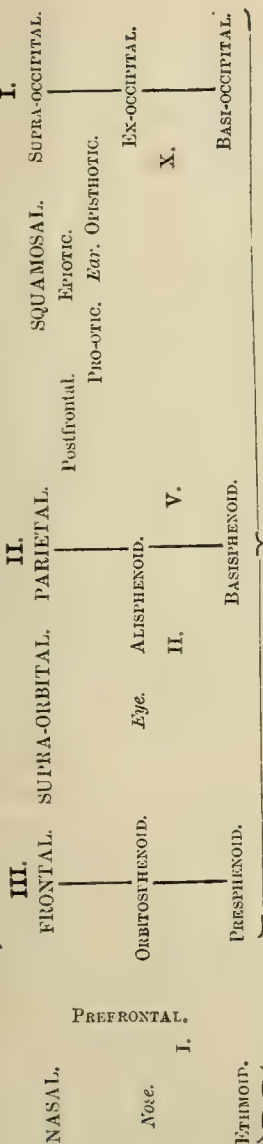
In front of the occipital segment, the roof of the skull is formed by membrane; and the bones which complete the two segments of which the *basisphenoid* and *presphenoid* form the basal parts, are membrane bones, and are disposed in two pairs. The posterior are the *parietals*, the anterior the *frontals*; and the segments which they complete are respectively called *parietal* and *frontal*. Thus the walls of the cranial cavity in the typical ossified skull are divisible into three segments—I. **Occipital**, II. **Parietal**, III. **Frontal**—the parts of which are arranged with reference to one another, the sensory organs and the exits of the first, second, fifth, and tenth pairs of cranial nerves (I., II., V., and X.), in the manner shown in the annexed diagram* :—

* The names of the purely membrane bones in this diagram are in large capitals, as **PARIETAL**; while those of the bones

which are preformed in cartilage are in smaller type, as **BASISPHENOID**.

THE BRAIN-CASE.

Segments.



Branchial apparatus.

Hyoidean apparatus.

TYMPANIC.

Mandibular Suspensorium.

PARASPHENOID.

PTERYGOD.

QUAD. JUGAL.

PALATINE.

JUGAL.
MAXILLA.

ARTICULAR.

Mandible.

PREMAXILLA.

LACHRYMAL.

DENTARY.

The cartilaginous cases of the organs of hearing, or the *periotic capsules*, are, as has been said, incorporated with the skull between the ex-occipitals and the alisphenoids—or, in other words, between the occipital and the parietal segments of the skull. Each of them may have three principal ossifications of its own. The one in front is the *pro-otic*; the one behind and below, the *opisthotic*; and the one which lies above, and externally, the *epiotic*. The last is in especial relation with the posterior vertical semicircular canal; the first with the anterior vertical semicircular canal, between which, and the exit of the third division of the fifth nerve, it lies. These three ossifications may coalesce into one, as when they constitute the *petrosal* and *mastoid* parts of the temporal bone of human anatomy; or the epiotic, or the opisthotic, or both, may coalesce with the adjacent supra-occipital and ex-occipitals, leaving the pro-otic distinct. The pro-otic is, in fact, one of the most constant bones of the skull in the lower *Vertebrata*, though it is commonly mistaken, on the one hand for the alisphenoid, and on the other for the entire petro-mastoid. Sometimes a fourth, *pterotoc* ossification, is added to the three already mentioned. It lies on the upper and outer part of the ear-capsule between the pro-otic and the epiotic (see the figure of the cartilaginous cranium of the Pike, *infra*).

In some *Vertebrata* the base of the skull exhibits a long and distinct splint-like membrane bone*—the *parasphenoid*, which underlies it from the basi-occipital to the pre-

* Bones may be formed in two ways. They may be preceded by cartilage, and the ossific deposit in the place of the future bone may at first be deposited in the matrix of that cartilage; or the ossific deposit may take place, from the first, in indifferent, or rudimentary connective, tissue. In this case the bone is not pre-figured by cartilage. In the skulls of Elasmobranch fishes, and in the sternum and epicoracoid of

Lizards, the bony matter is simply ossified cartilage, or cartilage bone. The parietal or frontal bones, on the other hand, are always devoid of cartilaginous rudiments, or, in other words, are *membrane bones*.

In the higher *Vertebrata* the cartilage bones rarely, if ever, remain as such; but the primitive ossified cartilage becomes, in great measure, absorbed and replaced by membrane bone, derived from the perichondrium.

sphenoidal region. In ordinary fishes and *Amphibia*, this bone appears to replace the basisphenoid and presphenoid functionally, while in the higher *Vertebrata* it becomes confounded with the basisphenoid. The *Vomer* is a similar, splint-like, single or double, membrane bone, which, in like manner, underlies the ethmoid region of the skull.

In addition to the bones already mentioned, a *prefrontal* bone may be developed in the prefrontal region of the nasal capsule, and bound the exit of the olfactory nerve externally.

A *postfrontal* bone may appear behind the orbit above the alisphenoid. Sometimes it seems to be a mere dismemberment of that bone; but, in most cases, the bone so named is a distinct membrane bone.

Furthermore, on the outer and upper surface of the auditory capsule a membrane bone, the *squamosal*, is very commonly developed; and another pair of splint-bones, the *nasals*, cover the upper part of the ethmovomerine chambers, in which the olfactory organs are lodged.

The Osseous Facial Apparatus.—The bones of the face, which constitute the inferior arches of the skull, appear within the various processes and visceral arches which have been enumerated. Thus, the *premaxillæ* are two bones developed in the oral part of the naso-frontal process, one on each side of the middle line, between the external nasal apertures, or *anterior nares*, and the anterior boundary of the mouth.

Ossification occurs in the palato-pterygoid cartilage at two chief points, one in front and one behind. The anterior gives rise to the *palatine* bone, the posterior to the *pterygoid*. Outside these, several membrane bones may make their appearance in the same process. The chief of these is the *maxilla*, which commonly unites, in front, with the premaxilla. Behind the maxilla there may be a second, the *jugal*; and occasionally behind this lies a third, the *quadrato-jugal*.

Between the maxilla, the prefrontal, and the premaxilla, another membrane bone, called *lachrymal*, from its ordinary

relation to the lachrymal canal, is very generally developed; and one or more *supra-orbital* and *post-orbital* ossifications may be connected with the bony boundaries of the orbit.

When these and the postfrontal membrane bone are simultaneously developed, they form two series of bony splints attached to the lateral wall of the skull, one set above and one below the orbit, which converge to the lachrymal. The upper series (lachrymal, supra-orbital, postfrontal, squamosal), terminates posteriorly over the proximal end of the *quadrate bone*, or *mandibular suspensorium*. The lower series (lachrymal, maxillary, jugal, quadrato-jugal) ends over the distal end of that bone, with which the quadrato-jugal is connected. The two series are connected behind the orbit by the post-orbital (when it exists), but more commonly by the union of the jugal with the postfrontal and squamosal. The *Ichthyosauria*, *Chelonia*, *Crocodylia*, and some *Lacertilia*, exhibit this double series of bones most completely.

Each nasal passage, at first very short, passes between the premaxilla below, the ethmoid and vomer on the inner side, the prefrontal above and externally, and the palatine behind, to open into the fore part of the mouth. And, before the cleft between the outer posterior angle of the naso-frontal process and the maxillary process is closed, this passage communicates, laterally, with the exterior, and, posteriorly, with the cavity of the orbit. When the maxillary and the naso-frontal processes unite, the direct external communication ceases; but the orbito-nasal passage, or *lachrymal canal*, as it is called, in consequence of its function of conveying away the secretion of the lachrymal gland, may persist, and the *lachrymal bone* may be developed in especial relation with it.

In the higher *Vertebrata*, the nasal passages no longer communicate with the fore part of the cavity of the mouth; for the maxillaries and palatines, regularly, and the pterygoid bones, occasionally, send processes downwards and inwards, which meet in the middle line, and shut off from the mouth

a canal which receives the nasal passages in front, while it opens, behind, into the pharynx, by what are now the *posterior nares*.

Two ossifications commonly appear near the proximal end of Meckel's cartilage, and become bones moveably articulated together. The proximal of these is the *quadrate* bone found in most vertebrates, the *malleus* of mammals; the distal is the *os articulare* of the lower jaw in most vertebrates, but

Fig. 9.

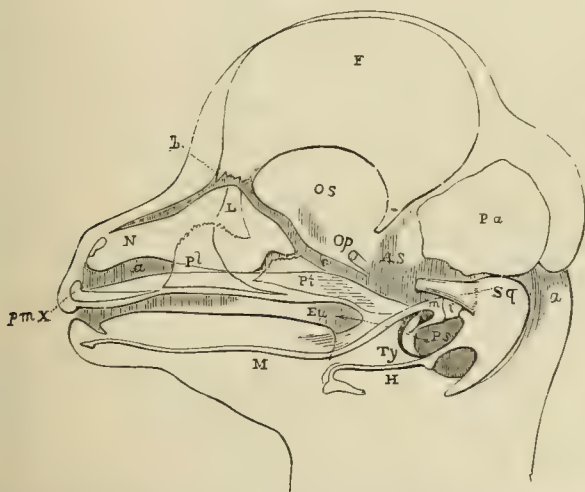


Fig. 9.—The head of a foetal Lamb dissected so as to show Meckel's cartilage, *M*; the malleus, *m*; the incus, *i*; the tympanic, *Ty*; the hyoid, *H*; the squamosal, *Sq*; pterygoid, *Pt*; palatine, *pl*; lachrymal, *L*; premaxilla, *pmx*; nasal sac, *N*; Eustachian tube, *Eu*.

does not seem to be represented in mammals. The remainder of Meckel's cartilage usually persists for a longer or shorter time, but does not ossify. It becomes surrounded by bone, arising from one or several centres in the adjacent membrane, and the *ramus of the mandible* thus formed, articulates with the squamosal bone in mammals, but in other *Vertebrata* is immoveably united with the *os articulare*. Hence the complete ramus of the mandible articulates

directly with the skull in mammals, but only indirectly, or through the intermediation of the quadrate, in other *Vertebrata*. In birds and reptiles, the proximal end of the quadrate bone, articulates directly (with a merely apparent exception in *Ophidia*), and independently of the hyoidean apparatus, with the periotic capsule. In most, if not all fishes, the connection of the mandibular arch with the skull is effected indirectly, by its attachment to a single cartilage or bone, the *hyomandibular*, which represents the proximal end of the hyoidean arch (see Fig. 24).

The ossification of the hyoidean apparatus varies immensely in detail, but usually gives rise to bony lateral arches, and a median portion, bearing much the same relation to them as the sternum has to the ribs. When the lateral arches are complete they are connected directly with the periotic capsule.

The proximal end of the hyoidean arch is often united, more or less closely, with the outer extremity of the bone, called *columella auris*, or *stapes*, the inner end of which, in the higher *Vertebrata*, is attached to the membrane of the *fenestra ovalis*.

In ordinary fishes, a fold of the integument extends backwards from the second visceral arch over the persistent branchial clefts; within this is developed a series of raylike membrane bones, termed *opercular* and *branchiostegal*, which become closely connected with the hyoidean arch. A corresponding process of the skin is developed in the Batrachian Tadpole, and grows backwards over the branchiæ. Its posterior edge, at first free, eventually unites with the integument of the body, behind the branchial clefts, the union being completed much earlier on the right side, than on the left.

In most mammals a similar fold of integument gives rise to the *pinna*, or external ear.

The *branchial* skeleton bears the same relation to the posterior visceral arches that the hyoidean does to the second. When fully developed, it exhibits ossified lateral arches, connected by median pieces, and, frequently, pro-

vided with radiating appendages which give support to the branchial mucous membrane. It is only found in those *Vertebrata* which breathe by gills—the classes *Pisces* and

Fig. 10.

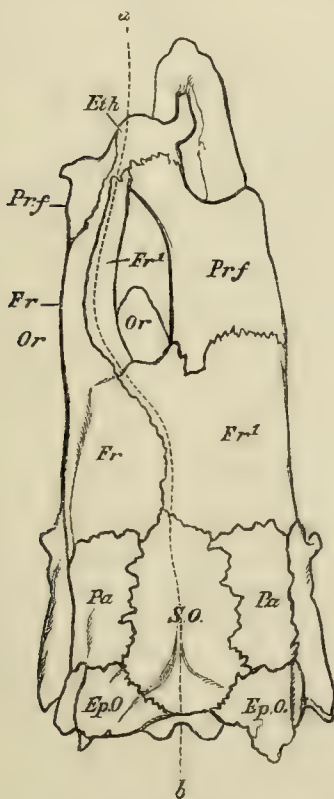


Fig. 10.—The skull of a Plaice (*Platessa vulgaris*), viewed from above. The dotted line *a, b*, is the true morphological median line; *Or, Or*, the position of the two eyes in their orbits; *Eth*, ethmoid; *Prf*, prefrontal; *Fr*, left frontal; *Fr1*, right frontal; *Pa*, parietal; *SO*, supra-occipital; *Ep.O.*, epiotic.

Amphibia. In the higher *Vertebrata*, the posterior of the two pairs of cornua with which the hyoidean apparatus is generally provided, are the only remains of the branchial skeleton.

The skull and face are usually symmetrical in reference to a median vertical plane. But, in some *Cetacea*, the bones about the region of the nose are unequally developed, and the skull becomes asymmetrical. In the Flatfishes (*Pleuronectidæ*), the skull becomes so completely distorted that the two eyes lie on one side of the body, which is, in some cases, the left, and, in others, the right side. In certain of these fishes, the rest of the skull and facial bones, the spine, and even the limbs, partake in this asymmetry. The base of the skull and its occipital region are comparatively little affected; but, in the interorbital region, the frontal bones and the subjacent cartilaginous, or membranous, side-walls of the cranium are thrown over to one side; and, frequently, undergo a flexure, so that they become convex towards that side, and concave in the opposite direction. The prefrontal bone of the side from which the skull is twisted sends back a great process above the eye of that side, which unites with the frontal bone, and thus incloses this eye in a complete bony orbit. It is along this fronto-prefrontal bridge that the dorsal fin-rays are continued forwards, just as if this bridge represented the morphological middle of the skull. (Fig. 10.)

The embryonic *Pleuronectidæ* have the eyes in their normal places, upon opposite sides of the head; and the cranial distortion commences only after the fish are hatched.

The Appendicular Endoskeleton.—The limbs of all vertebrated animals make their appearance as buds on each side of the body. In all but fishes, these buds become divided by constrictions into three segments. Of these, the proximal is called *brachium* in the fore-limbs, *femur* in the hind; the middle is *antebrachium*, or *crus*; the distal is *manus*, or *pes*. Each of these divisions has its proper skeleton, composed of cartilage and bone. The proximal division, normally, contains only one bone, *os humeri*, or *humerus*, in the brachium—and *os femoris*, or *femur*, in the thigh; the middle, two bones, side by side, *radius* and *ulna*, or *tibia* and *fibula*; the distal, many bones, so disposed as to form not more than five longitudinal series, except in the

Ichthyosauria, where marginal bones are added, and some of the digits bifurcate.

The skeletal elements of the manus and pes are divisible into a proximal set, constituting the *carpus* or *tarsus*; and a distal set, the *digits*, of which there are normally five, articulated with the distal bones of the carpus and tarsus. Each digit has a proximal *basi-digital* (*metacarpal*, or *metatarsal*) bone, upon which follows a linear series of *phalanges*. It is convenient always to count the digits in the same way, commencing from the radial or tibial side. Thus, the thumb is the first digit of the hand in man; and the great toe the first digit of the foot. Adopting this system, the digits may be represented by the numbers i, ii, iii, iv, v.

There is reason to believe that, when least modified, the carpus and the tarsus are composed of skeletal elements which are alike in number and in arrangement. One of these, primitively situated in the centre of the carpus or tarsus, is termed the *centrale*; on the distal side of this are five *carpalia*, or *tarsalia*, which articulate with the several metacarpal or metatarsal bones; while, on its proximal side, are three bones—one *radiale* or *tibiale*, articulating with the radius or tibia; one *ulnare* or *fibulare*, with the ulna or fibula; and one *intermedium*, situated between the foregoing. Carpal and tarsal bones, or cartilages, thus disposed are to be met with in some *Amphibia* and *Chelonia* (Fig. 11), but, commonly, the typical arrangement is disturbed by the suppression of some of these elements, or their coalescence with one another. Thus, in the carpus of man, the radiale, intermedium, and ulnare are represented by the *scaphoides*, *lunare*, and *cuneiforme* respectively. The *pisiforme* is a sesamoid bone developed in the tendon of the *flexor carpi ulnaris*, which has nothing to do with the primitive carpus. The centrale is not represented in a distinct shape, having probably coalesced with one of the other elements of the carpus. The fourth and fifth carpalia have coalesced, and form the single *unciforme*. In the tarsus of man the *astragalus* represents the coalesced tibiale and intermedium; the *calcaneum*, the fibulare. The *naviculare* is the centrale. Like

the corresponding bones in the carpus, the fourth and fifth tarsalia have coalesced to form the *cuboides*.

Fig. 11.

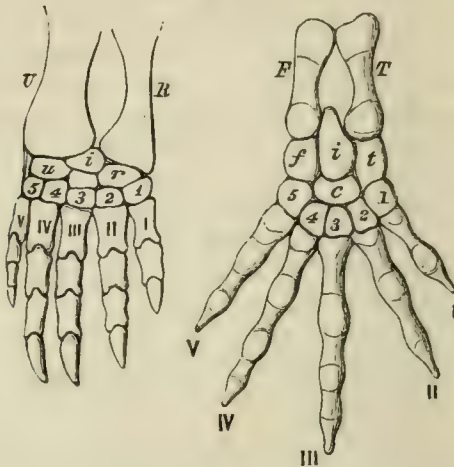


Fig. 11.—The right forefoot of the Chelonian *Chelydra*, and the right hind-foot of the Amphibian *Salamandra*.—*U.* ulna; *R.* radius; *F.* fibula; *T.* tibia.

Proximal carpal bones: *r.* radiale; *i.* intermedium; *u.* ulnare; the centrale is the middle unlettered bone.

Proximal tarsal bones: *t.* tibiale; *i.* intermedium; *f.* fibulare; *c.* centrale; 1, 2, 3, 4, 5, distal carpalia and tarsalia; I, II, III, IV, V, digits.

The Position of the Limbs.—In their primitive position, the limbs are straight, and are directed outwards, at right angles to the axis of the body; but, as development proceeds, they become bent in such a manner that, in the first place, the middle division of each limb is flexed downwards and towards the middle line, upon the proximal division; while the distal division takes an opposite bend upon the middle division. Thus the ventral aspects of the *antebrachium* and *crus* come to look inwardly, and the dorsal aspects outwardly; while the ventral aspects of the *manus* and *pes* look downwards, and their dorsal aspects look upwards. When the position of the limbs has been no further

altered than this, the radius in the antebrachium, and the tibia in the crus, are turned forwards, or towards the head; the ulna and the fibula backwards, or towards the caudal extremity. On looking at these parts with respect to the axis of the limb itself, the radius and the tibia are *pre-axial*, or in front of the axis; while the ulna and fibula are *post-axial*, or behind it. The same axis traverses the centre of the middle digit, and there are therefore two pre-axial, or radial, or tibial digits; and two post-axial, or ulnar, or fibular digits, in each limb. The most anterior of the digits (i) is called *pollex*, in the manus; and *hallux*, in the pes. The second digit (ii) is the *index*; the third (iii) the *medius*; the fourth (iv) the *annularis*; and the fifth (v) the *minimus*.

In many *Amphibia* and *Reptilia*, the limbs of the adult do not greatly depart from this primitive position; but in birds and in mammals, further changes occur. Thus, in all ordinary quadrupeds, the brachium is turned backwards and the thigh forwards, so that both elbow and knee lie close to the sides of the body. At the same time, the forearm is flexed upon the arm, and the leg upon the thigh. In Man a still greater change occurs. In the natural erect posture, the axes of both arm and leg are parallel with that of the body, instead of being perpendicular to it. The proper ventral surface of the brachium looks forwards, and that of the thigh backwards, while the dorsal surface of the latter looks forwards. The dorsal surface of the antebrachium looks outwards and backwards, that of the leg directly forwards. The dorsal surface of the manus is external, that of the pes, superior. Thus, speaking broadly, the back of the arm corresponds with the front of the leg, and the outer side of the leg with the inner side of the arm, in the erect position.

In Bats, a line drawn from the acetabulum to the foot is also, in the natural position, nearly parallel with the long axis of the body. But, in attaining this position, the leg is bent at the knee and turned backwards; the proper dorsal surface of the thigh looking upwards and forwards,

while the corresponding surface of the leg looks backwards and upwards, and the ungual phalanges are turned backwards.

The chief modifications of the manus and pes arise from the excess, or defect, in the development of particular digits, and from the manner in which the digits are connected with one another, and with the carpus or tarsus. In the *Ichthyosauria* and *Plesiosauria*, the Turtles, the *Cetacea* and *Sirenia*, and, in a less degree, in the Seals, the digits are bound together and cased in a common sheath of integument, so as to form *paddles*, in which the several digits have little or no motion on one another.

The fourth digit of the manus in the *Pterosauria*, and the four ulnar digits in the Bats, are vastly elongated, to support the web which enables these animals to fly. In existing birds the two ulnar, or post-axial, digits are aborted, the metacarpals of the second and third are ankylosed together, and the digits themselves are inclosed in a common integumentary sheath; the third invariably, and the second usually, is devoid of a claw. The metacarpal of the pollex is ankylosed with the others, but the rest of that digit is free, and frequently provided with a claw.

Among terrestrial mammals, the most striking changes of the manus and pes arise from the gradual reduction in the number of the perfect digits from the normal number of five to four (*Sus*), three (*Rhinoceros*), two (most *Ruminantia*), or one (*Equidæ*).

The Pectoral and Pelvic Arches.—The proximal skeletal elements of each pair of limbs (*humeri* or *femora*) are supported by a primitively cartilaginous, *pectoral*, or *pelvic* girdle, which lies external to the costal elements of the vertebral skeleton. This girdle may consist of a simple cartilaginous arc (as in the Sharks and Rays), or it may be complicated by subdivisions and additions.

The pectoral arch may be connected with the skull, or with the vertebral column, by muscles, ligaments, or dermal ossifications, though, primitively, it is perfectly free from

and independent of, both; but it is never united with the vertebræ by the intermediation of ribs. At first, it consists of one continuous cartilage, on each side of the body, distinguishable only into regions and processes, and affording an articular surface to the bones, or cartilages, of the limb. But ossification usually sets up in the cartilage, in such a way, as to give rise to a dorsal bone, called the *scapula*, or shoulderblade, which meets, in the articular, *glenoidal* cavity for the humerus, with a ventral ossification, termed the *coracoid*.

By differences in the mode of ossification of the various parts, and by other changes, that region of the primitively

Fig. 12.

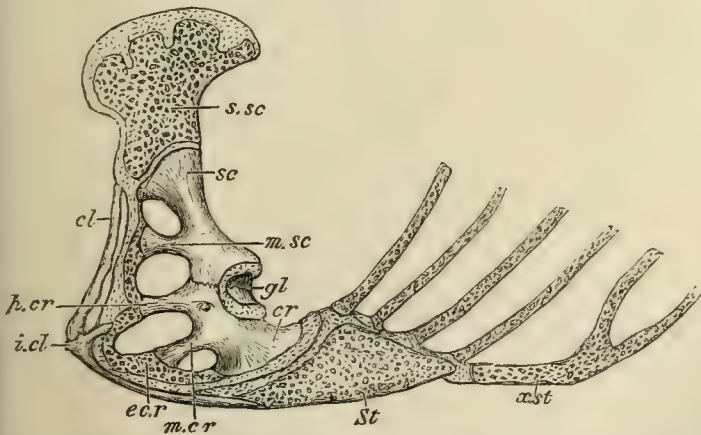


Fig. 12.—Side-view of the pectoral arch and sternum of a Lizard (*Iguana tuberculata*).—*Sc*, scapula; *s.sc*, supra-scapula; *cr*, coracoid; *gl*, glenoidal cavity; *St*, sternum; *x.st*, xiphisternum; *m.sc*, mesoscapula; *p.cr*, precoracoid; *m.cr*, mesocoracoid; *e.cr*, epicoracoid; *cl*, clavicle; *i.cl*, interclavicle.

cartilaginous pectoral arch, which lies above the glenoidal cavity, may be ultimately divided into a *scapula* and a *supra-scapula*; while that which lies on the ventral side may present not only a *coracoid*, but a *precoracoid* and an *epicoracoid*.

In the great majority of the *Vertebrata* above fishes, the

coracoids are large, and articulate with the antero-external margins of the primitively cartilaginous *sternum*, or breast-bone. But, in most mammals, they do not reach the sternum, and, becoming ankylosed with the scapula, they appear, in adult life, as mere processes of that bone.

Numerous Vertebrates possess a *clavicula*, or collar-bone, which is connected with the pre-axial margin of the *scapula* and *coracoid*, but takes no part in the formation of the

Fig. 13.

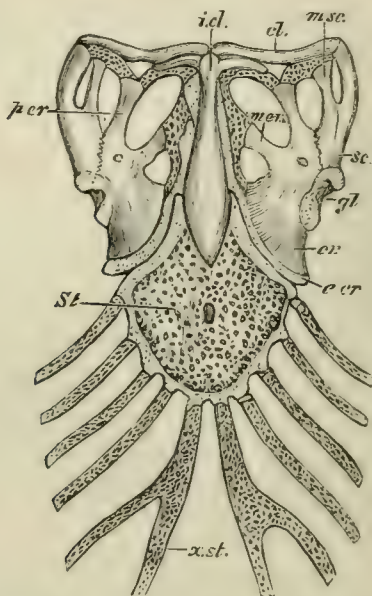


Fig. 13.—Ventral view of the sternum and pectoral arches of *Iguana tuberculata*. The letters as in Fig. 12.

glenoid cavity, and is usually, if not always, a membrane bone. In many *Vertebrata*, the inner ends of the clavicles are connected with, and supported by, a median membrane bone which is closely connected with the ventral face of the sternum. This is the *interclavicle*, frequently called *episternum*.

The pelvic, like the pectoral, arch at first consists of a simple continuous cartilage on each side, which, in *Vertebrata* higher than fishes, is divided by the *acetabulum*, or articular cavity for the reception of the head of the femur, into a dorsal and a ventral moiety.

Three separate ossifications usually take place in this cartilage—one in the dorsal, and two in the ventral, moiety. Hence, the pelvic arch eventually consists of a dorsal portion, called the *ilium*, and of two ventral elements, the *pubis* anteriorly, and the *ischium* posteriorly. All these generally enter into the composition of the acetabulum.

The ilium corresponds with the scapula. In the higher *Vertebrata* the outer surface of the latter bone becomes

Fig. 14.

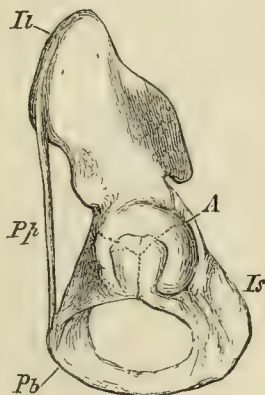


Fig. 14.—Side-view of the left Os innominatum of Man: *Il*, ilium; *Is*, ischium; *Pb*, pubis; *A*, acetabulum; *Pp*, Poupart's ligament.

divided by a ridge into two fossæ. The ridge, called the *spine of the scapula*, frequently ends in a prominent process termed the *acromion*, and with this, in *Mammalia*, the clavicle articulates. In like manner, the outer surface of the ilium becomes divided by a ridge which grows out into a great crest in Man and other *Mammalia*, and gives attachment to muscles and ligaments.

The ischium corresponds very nearly with the coracoid

in the pectoral arch; the pubis with the precoracoid, and more or less of the epicoracoid.

The pelvis possesses no osseous element corresponding with the clavicle, but a strong ligament, the so-called *Poupart's ligament*, stretches from the ilium to the pubis in many *Vertebrata*, and takes its place. (Fig. 14, Pp.)

On the other hand, the *marsupial bones* of certain mammals, which are ossifications of the tendons of the external oblique muscles, seem to be unrepresented in the pectoral arch; while there appears to be nothing clearly corresponding with a sternum in the pelvic arch, though the *precloacal cartilage*, or *ossicle*, of Lizards has much the same relation to the ischia as the sternum has to the coracoids.

Very generally, though not universally, the ilia are closely articulated with the modified ribs of the sacrum. The pubes and ischia of opposite sides usually meet in a median ventral symphysis; but in all birds, except the Ostrich, this union does not take place.

The Limbs of Fishes.—The limbs of Fishes have an endoskeleton which only imperfectly corresponds with that of the higher Vertebrates. For while homologues of the cartilaginous, and even of the bony, constituents of the pectoral and pelvic arches of the latter are traceable in Fishes, the cartilaginous, or ossified, basal and radial supports of the fins themselves cannot be identified, unless in the most general way, with the limb-bones, or cartilages, of the other *Vertebrata*.

In its least modified form, as in *Lepidosiren*, the endoskeleton of the fish's fin is a simple cartilaginous rod, divided into many joints; and articulated, by its proximal end, with the pectoral arch. The *Elasmobranchii* possess three *basal* cartilages which articulate with the pectoral arch, and are called, respectively, from before backwards—*propterygial*, *mesopterygial*, and *metapterygial basalia*. With these are articulated linear series of *radial* cartilages, upon which osseous, or horny, dermal fin-rays are superimposed. (Fig. 15.)

Among the Ganoid fishes, the fins of *Polypterus* are, fundamentally, like those of the *Elasmobranchii*; but the propterygial, mesopterygial, and metapterygial *basalia*, are more or less ossified, and are succeeded by a series of elongated *radialia*, which are also, for the most part, ossified. Beyond these follow some small additional *radialia*, which

Fig. 15.

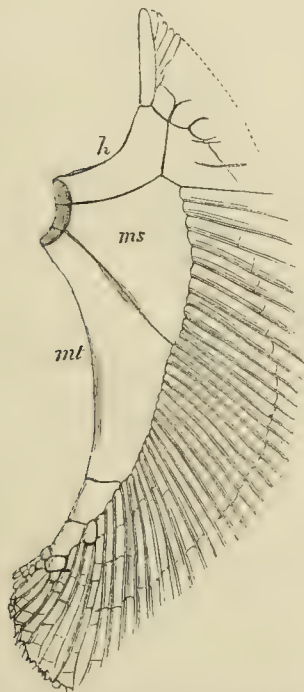


Fig. 15.—The right pectoral member of the Monkfish (*Squatina*): *h*, propterygium; *ms*, mesopterygium; *mt*, metapterygium.

remain cartilaginous, and are embraced by the bases of the fin-rays. In the other Ganoids the propterygial basale disappears, and some of the radialia, pushing themselves between the mesopterygial and metapterygial basalia, articulate directly with the pectoral arch. The mesopterygial

basale is embraced by, and becomes more or less incorporated with, the large anterior fin-ray.

From these Ganoids the passage is easy to the *Teleostei*, in which, also, the mesopterygial basale always becomes fused with the anterior fin-ray, whence the latter seems to articulate directly with the shoulder-girdle. Four bones, of very similar general form, usually articulate with the pectoral arch, beneath and behind the mesopterygial basale and its fin-ray. At their distal ends small cartilaginous nodules may lie, and these are embraced by the fin-rays. Of these four bones, or partially ossified cartilages, the lowermost and hindermost answers to the metapterygial basale of the Shark; the others seem to be *radialia*. (See the figure of the Pike's pectoral fin, *infra*.)

The ventral fins have basal and radial cartilages and fin-rays, more or less resembling those of the fore limbs.

In most Ganoids and Teleosteans the pectoral and pelvic arches are, in part, or completely, ossified; the former frequently presenting distinct scapular and coracoid bones. To these, in all Ganoids and Teleosteans, membrane bones, representing a clavicle, with *supra-clavicular* and *post-clavicular* ossifications, are added.

In all Elasmobranchs and Ganoids, and in a large proportion of the Teleosteans, the pelvic fins are situated far back on the underside of the body, and are said to be "ventral" in position; but, in other Teleosteans, the ventral fins may move forward, so as to be placed immediately behind, or even in front of, the pectoral fins. In the former case they are said to be "thoracic," in the latter "jugular."

The Vertebrate Exoskeleton.—The *Exoskeleton* never attains, in vertebrated animals, the functional importance which it so frequently possesses among the *Invertebrata*, and it varies very greatly in the degree of its development.

The *integument* consists of two layers—a superficial, non-vascular substance, the *epidermis*, composed of cells, which are constantly growing and multiplying in the deeper, and being thrown off in the superficial, layers; and a deep vascular tissue, the *dermis*, composed of more or less

completely-formed connective tissue. An exoskeleton may be developed by the hardening of either the epidermis, or the dermis.

The *epidermal exoskeleton* results from the conversion into horny matter of the superficial cells of the epidermis. The horny plates thus formed are moulded upon, and follow the configuration of, *areæ*, or processes, of the dermis. When the latter are overlapping folds, the horny epidermic investment is called a scale, *squama*. When the dermic process is papilliform, and sunk in a pit of the dermis, the conical cap of modified epidermis which coats it, is either a *hair* or a *feather*. To become a hair, the horny cone simply elongates by continual addition of new cells to its base; but, in a feather, the horny cone, which also elongates by addition to its base, splits up, for a greater or less distance along the middle line of its under-surface, and then spreads out into a flat vane, subdivided into *barbs*, *barbules*, &c., by a further process of splitting of the primary horny cone.

The epidermis remains soft and delicate in Fishes and *Amphibia*. In *Reptilia* it sometimes takes the form of plates, which attain a great size in many *Chelonia*; sometimes, that of overlapping scales, as in *Ophidia* and many *Lacertilia*; but, sometimes, it remains soft, as in some *Chelonia* and in the Chamæleons. Epidermic plates in the form of *nails* appear upon the terminal phalanges of the limbs.

All *Aves* possess feathers. In addition, the beak is partly or completely ensheathed in horn, as in some *Reptilia*. Cornified epidermic tubercles, or plates, are developed on the tarsi and toes, the terminal phalanges of which (and sometimes those of the wing) have nails. Beside these, some birds possess spurs, which are ensheathed in horn, on the legs or wings.

In *Mammalia* the horny exoskeleton may take all the forms already mentioned, except that of feathers. In some *Cetacea* it is almost absent, being reduced to a few hairs, present only in the foetal state. The Pangolin (*Manis*), on the other hand, is almost completely covered with scales, the Armadillos with plates, and most terrestrial mammals

with a thick coat of hair. The greater part of the mass of the horns of Oxen, Sheep, and Antelopes, is due to the epidermic sheath which covers the bony core. Where the horny epidermis becomes very thick, as in the hoof of the Horse, and in the horn of the Rhinoceros, numerous long papillæ of the dermis extend into it. These papillæ, however, are comparable to the ridges of the bed of the nail, not to the papillæ of the hairs.

Fig. 16.

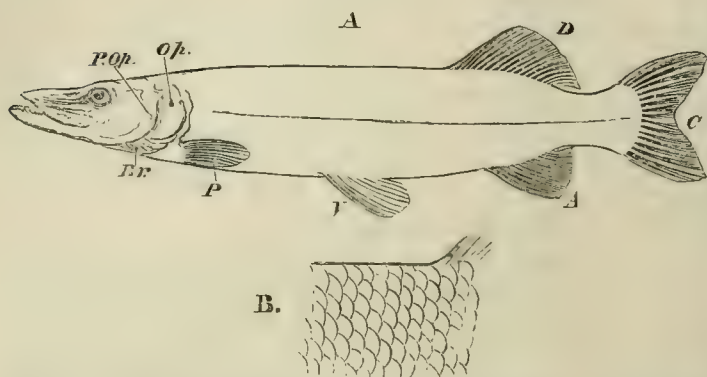


Fig. 16.—A, outline of a Pike (*Esox*), to show the fins: *P*, pectoral; *V*, ventral; *A*, anal; *C*, caudal; *D*, dorsal, fins. *Op.*, operculum; *P.Op.*, preoperculum; *Br.*, branchiostegal rays.—B, scales of the dermal exoskeleton of the same fish.

The *dermal exoskeleton* arises from the hardening of the dermis; in the majority of cases by the deposit of bone-earth, in more or less completely-formed connective tissue, though the resulting hard tissue has by no means always the structure of bone. It may happen that cartilage is developed in the dermis; and, either in its primary state, or ossified, gives rise to exoskeletal parts.

No dermal exoskeleton (except that of the fin-rays) is found in the lowest fishes, *Amphioxus* and the *Marsipobranchii*. In most *Teleostei* the integument is raised up into overlapping folds; and, in these, calcification takes

place in laminæ, of which the oldest is the most superficial, and lies immediately beneath the epidermis. As a general rule, the calcified tissue of the "scale" thus formed, does not possess the structure of true bone in the *Teleostei*. But in other fishes, the dermal calcification may consist of true bone (as in the Sturgeon); or, as in the Sharks and Rays, may take on the structure of teeth, and consist mainly of a tissue exactly comparable to dentine, capped with enamel, and continuous by its base with a mass of true bone, which takes the place of the *crusta petrosa*, or cement of the teeth.

A form of dermal exoskeleton, which is peculiar to and highly characteristic of fishes, is found in the *fin-rays*. These are developed in the integument either of the median line of the body, or in that of the limbs. In the former case, they usually enter into, or support, folds of the integument which are termed *dorsal*, *caudal*, or *anal fins*—according as they lie in the dorsal region, or at the extremity of the body, or on the ventral aspect, behind the anus. Ordinary fin-rays are composed of a hornlike, or more or less calcified, substance, and are simple at the base, but become jointed transversely, and split up longitudinally, towards their extremities (Fig. 6). Each fin-ray consists of two nearly equal and similar parts, which cohere by their applied faces for the greater part of their extent; but, at the base of the ray, the halves commonly diverge, to embrace, or more or less completely coalesce with, cartilaginous or osseous elements of the exoskeleton. In the median fins, these are the *interspinous* cartilages, or bones, which lie between the fin-rays and the superior or inferior spines of the vertebræ. In the paired fins, they are radial or basal, cartilaginous or osseous, elements of the endoskeleton.

The *Amphibia* in general are devoid of dermal exoskeleton, but the *Cæciliæ* have scales like those of fishes. *Ceratophrys* has plates of bone developed in the dorsal integument, which seem to foreshadow the plates of the carapace of the *Chelonia*; and the extinct Labyrinthodonts possessed a very remarkable ventral exoskeleton.

The *Ophidia* have no dermal exoskeleton. Many Lizards

have bony dermal plates corresponding in form and size with the epidermal scales. All *Crocodylia* have such bony plates in the dorsal region of the body and tail; and in some, such as the Jacares and Caimans, and the extinct *Teleosauria*, they are also developed in the ventral region. In these animals there is a certain correspondence between the segments of the exoskeleton and those of the endoskeleton. But the dermal exoskeleton attains its greatest development in the *Chelonia*, and will be particularly described under the head of that order.

In the *Mammalia* the development of a dermal exoskeleton is exceptional, and occurs only in the loricated *Edentata*, in which the dorsal region of the head and body, and the whole of the tail, may be covered with shields of dermal bone.

In connection with the dermis and epidermis, the glandular and pigmentary organs of the integument may be mentioned. Integumentary glands do not appear to exist in Fishes, but they attain an immense development in some of the *Amphibia*, as the Frog. Among *Reptilia*, Lizards frequently present such glands in the femoral and cloacal regions; and, in Crocodiles, integumentary glands, which secrete a musky substance, lie beneath the jaw. In Birds they attain a considerable size in the uropygial gland; and, in *Mammalia*, acquire a large development in connection with the sacs of the hairs, or as independent organs, in the form of sweat-glands, musk-glands, or mammary glands.

The colour of the integument may arise from pigment-granules, deposited either in the epidermis or in the dermis; and in the latter case, it is sometimes contained in distinct chromatophores, as in the *Chamæleon*.

CHAPTER II.

THE MUSCLES AND THE VISCERA—A GENERAL VIEW OF
THE ORGANIZATION OF THE VERTEBRATA.

THE muscular system of the *Vertebrata* consists of muscles related partly to the exoskeleton, partly to the endoskeleton, and partly to the viscera, and formed both of striated and unstriated muscular fibre. The latter is confined to the vessels, the viscera, and the integument; the parts of the endoskeleton being moved upon one another exclusively by striated muscular fibre. The muscles of the endoskeleton may be divided, like the endoskeleton itself, into one system appertaining to the trunk and head, and another belonging to the limbs.

The Muscular System of the Trunk and Head.—This consists of two portions, which differ fundamentally in their origin, and in their relations to the endoskeleton. The one takes its origin in the protovertebræ; each protovertebra becoming differentiated, as we have seen, into three parts; a spinal ganglion and a segment of the vertebral endoskeleton, in the same plane, and a more superficial sheet of muscular fibres. These muscular fibres are consequently situated above the endoskeleton, or are *episkeletal*. Other muscular fibres are developed below the endoskeleton, and may be termed *hyposkeletal* muscles. The *hyposkeletal* muscles are separated from the *episkeletal*, not only by the endoskeleton of the trunk (or the vertebræ and their prolongations, the ribs), but by the ventral branches of the spinal nerves.

As the *episkeletal* muscles are developed out of the protovertebræ, they necessarily, at first, present as many seg-

ments as there are vertebræ, the interspaces between them appearing as *intermuscular septa*. The development of the hyoskeletal muscles has not been worked out, but it appears to take place much later than that of the episkeletal set.

In the lowest *Vertebrata*—as, for example, in ordinary fishes—the chief muscular system of the trunk consists of the episkeletal muscles, which form thick lateral masses of longitudinal fibres, divided by transverse intermuscular septa into segments (or *Myotomes*) corresponding with the vertebræ. The lateral muscles meet in the middle line below, and divide, in front, into a dorso-lateral mass connected with the skull, and a ventro-lateral attached, in part, to the pectoral arch, and, in part, continued forwards to the skull, to the hyoidean apparatus, and to the mandible. Posteriorly, the lateral muscles are continued to the extremity of the tail. The hyoskeletal muscular system appears to be undeveloped.

In the higher *Vertebrata*, both the episkeletal and hyoskeletal muscular systems are represented by considerable numbers of more or less distinct muscles. The dorso-lateral division of the lateral muscle of the fish is represented by the superior caudal muscles, and by the *erector spinæ*; which, as it splits up, anteriorly, and becomes attached to the vertebræ, and to the ribs, and to the skull, acquires the names of *spinalis*, *semispinalis*, *longissimus dorsi*, *sacro-lumbalis*, *inter-transversalis*, *levatores costarum*, *complexus*, *splenius*, *recti postici*, and *recti laterales*.

The ventro-lateral division of the fish's lateral muscle is represented, in the middle line of the trunk and head, by a series of longitudinal muscles; and, at the sides, by obliquely-directed muscles. The former are the *recti abdominis*, extending from the pelvis to the sternum—the *sterno-hyoidei*, between the sternum and the hyoidean apparatus—the *genio-hyoidei*, which pass from the hyoid to the symphysis of the mandible. The latter are the *obliqui externi* of the abdomen—the external *intercostales* of the thorax—the *sub-clavius* stretching from the first rib to the clavicle; the *scaleni* from the anterior dorsal ribs to the cervical ribs and

transverse processes, and the *sterno-* and *cleido-mastoidei* from the sternum and clavicle to the skull.

The fibres of all these oblique muscles take a direction, from parts which are dorsal and anterior, to others which are ventral and posterior.

The trunk muscles of the lower *Amphibia* exhibit arrangements which are transitional between those observed in Fishes and that which has been described in Man, and which substantially obtains in all abranchiata *Vertebrata*.

The muscles of the jaws and of the hyoidean apparatus appear to be, in part, episkeletal, and, in part, hyoskeletal. The mandible is depressed by a muscle, the *digastric*, arising from the skull, and supplied by a branch of the seventh nerve: it is raised by a muscular mass, which is separable into *masseter*, *temporal*, and *pterygoid* muscles, according to its connection with the maxillo-jugal bones, the sides of the skull, or the palato-ptyergoid bones, and is supplied by the fifth nerve.

The proper facial muscles belong to the system of cutaneous muscles, and receive branches from the seventh nerve.

The hyoskeletal system is formed, partly, of longitudinal muscles which underlie the vertebral column; and partly, of more or less oblique, or even transverse fibres, which form the innermost muscular walls of the thorax and of the abdomen.

The former are the subcaudal intrinsic flexors of the tail; the *pyriformis*, *psoas*, and other muscles proceeding from the inferior faces of the vertebræ to the hind limb; the *longus colli*, or intrinsic flexor of the anterior part of the vertebral column; and the *recti capitis antici*, or flexors of the head upon the vertebral column. The latter are the *obliquus internus* of the abdomen, the fibres of which take a direction crossing that of the external oblique muscle; and the *transversalis*, which lies innermost of the abdominal muscles, and has its fibres transverse. In the thorax, the *intercostales interni* continue the direction of the internal oblique, and the *triangularis sterni* that of the *transversalis*. The *diaphragm* and the *levator ani* must also be enumerated among

the hyposkeletal muscles. The hyposkeletal muscles of the posterior moiety of the body attain a great development in those *Vertebrata* which have no hind limbs, such as *Ophidia* and *Cetacea*.

The Muscular System of the Limbs.—The muscles of the limbs of Fishes are very simple, consisting, on each face of the limb, of bundles of fibres, which proceed (usually in two layers) obliquely, from the clavicle and supraclavicle to the fin-rays. The pectoral and pelvic arches themselves are imbedded in the lateral muscles.

In the *Amphibia* and all the higher *Vertebrata*, the muscles of the limbs are divisible into—*intrinsic*, or those which take their origin within the anatomical limits of the limb (including the pectoral or pelvic arch); and *extrinsic*, or those which arise outside the limb.

Supposing the limb to be extended at right angles to the spine (its primitive position), it will present a *dorsal aspect* and a *ventral aspect*, with an anterior, or *pre-axial*, and a posterior, or *post-axial*, side.

In the *Vertebrata* above fishes, the following muscles, which occur in Man, are very generally represented:

Extrinsic muscles attached to the pectoral and pelvic arches, on the dorsal aspect.—In the fore limb, the *cleidomastoideus*, from the posterolateral region of the skull to the clavicle; the *trapezius*, from the skull and spines of many of the vertebræ to the scapula and clavicle; the *rhomboidei*, from the spines of vertebræ to the vertebral edge of the scapula, beneath the foregoing. Sometimes there is a *trachelo-acromialis*, from the transverse processes of the cervical vertebræ to the scapula.

On the ventral aspect, the *subclavius*, which passes from the anterior rib to the clavicle, may be regarded as, in part, a muscle of the limb; the *pectoralis minor*, from the ribs to the coracoid.

Between the dorsal and the ventral aspects muscular fibres arise from the cervical and dorsal ribs, and pass to the inner aspect of the vertebral end of the scapula: anteriorly, these are called *levator anguliscapulæ*; posteriorly, *serratus magnus*.

An *omohyoid* muscle frequently connects the scapula with the hyoidean arch.

The posterior limb does not seem to offer any muscles exactly homologous with the foregoing. So far, however, as the *recti abdominis*, the *obliquus externus*, and the fibres of the *erector spinæ*, are attached to the pelvic girdle, they correspond in a general way with the pre-axial, or protractor, muscles of the pectoral arch; and the ischio-coccygeal muscles, when they are developed, are, in relation to the pelvic arch, retractors, though, owing to the relative fixity of the pelvis, they act in protracting, or flexing, the caudal region.

The *psoas minor*, proceeding from the under-surfaces of posterior dorsal (or lumbar) vertebræ to the ilium, or pubis, is a protractor of the pelvis, but, as a hyoskeletal muscle, has no homologue in the fore limb.

Extrinsic muscles attached to the humerus or femur, on the dorsal aspect.—In the fore limb there is the post-axial *latissimus dorsi* passing from spines of dorsal vertebræ to the humerus. On the ventral aspect, the *pectoralis major* extends from the sternum and ribs to the humerus.

In the hind limb, the *glutæus maximus*, so far as it arises from the sacral and coccygeal vertebræ, and is inserted into the femur, repeats the relations of the *latissimus dorsi*. In the absence of anything corresponding with the sternum, or the ribs, no exact homologue of the *pectoralis major* can be said to exist, though the *pectineus* comes near it. The *psoas major*, passing from posterior dorsal or lumbar vertebræ—the *pyriformis* from sacral vertebræ—the *femoro-coccygeus* (when it exists) from caudal vertebræ—to the femur, are all hyoskeletal muscles, without homologues in the anterior extremity.

All the other muscles of the limbs are *intrinsic*, taking their origins from the pectoral or pelvic arches, or from some of the more proximal segments of the limb-skeleton, and having their insertion in the more distal segments. They are thus arranged in Man and the higher *Mammalia* :

Intrinsic muscles proceeding from the pectoral or pelvic

arches to the humerus or femur, on the dorsal aspect.—In the fore limb, the *deltoides* proceeds from the clavicle and scapula to the humerus. This superficial shoulder-muscle continues the direction of the fibres of the *trapezius*; and, when the clavicle is rudimentary, the adjacent portions of the two muscles coalesce into a *cephalo-humeralis* muscle. Beneath the deltoid the *supra-spinatus*, on the pre-axial side of the spine of the scapula; the *infra-spinatus*, and the *teres major* and *minor*, on its post-axial side, run from the dorsal aspect of the scapula to that of the head of the humerus.

In the hind limb, the *tensor vaginæ femoris*, which passes from that part of the ilium which corresponds with the spine and acromion of the scapula, to the femur, appears to answer better to the deltoid than does the *glutæus maximus*, which, at first sight, would seem to be the homologue of that muscle.

The *iliacus*, proceeding from the inner surface of the crest of the ilium to the smaller trochanter, answers to the *supra-spinatus*; the *glutæus medius* and *minimus*, which arise from the outer surface of the ilium, to the *infra-spinatus* and *teres*.

In the fore limb, a muscle, the *subscapularis*, is attached to the inner face of the scapula, and is inserted into the humerus. No muscle exactly corresponding with this appears to exist in the hind limb.

On the ventral aspect in the fore limb, the *coracobrachialis* passes from the coracoid to the humerus. In the hind limb, a number of muscles proceed from the corresponding (ischio-pubic) part of the pelvic arch to the femur. These are, from the outer surface of the pubis, the *pectineus*, and the great *adductors* of the femur; with the *obturator externus*, from the outer side of the ischiopubic fontanelle, or obturator membrane. The *gemelli* and the *quadratus femoris* take their origin from the ischium.

No muscle is attached to the proper inner surface of the ilium, so that there is no homologue of the *subscapularis* in the hind limb. On the other hand, a muscle, the *obturator internus*, attached to the inner surface of the ischiopubic fontanelle, and winding round to the femur, has no homo-

logue in the upper extremity of the higher *Vertebrata*, unless it be the so-called *coracobrachialis*, which arises from the inner surface of the coracoid in many *Sauropsida*.

Muscles of the Antebrachium and Crus.—On the dorsal aspect of the fore limb, as of the hind limb, certain muscles arise in part from the arch, and, in part, from the bone of the proximal segment of the limb, and go to be inserted into the two bones of the second segment. These are, in the fore limb, the *triceps extensor* and the *supinator brevis*; in the hind limb, the *quadriceps extensor*.

There is this difference between these two homologous groups of muscles—that in the fore limb, the principal mass of the muscular fibres goes, as the *triceps*, to be inserted into the post-axial bone (ulna), and the less portion, as *supinator brevis*, into the pre-axial bone (radius); whereas, in the hind limb, it is the other way, almost the whole of the muscular fibres passing, as the *quadriceps*, to the pre-axial bone (tibia), the tendon commonly developing a sesamoid *patella*; while only a few fibres of that division of the *quadriceps* which is called the “*vastus externus*” pass to the post-axial bone (fibula).

On the *ventral aspect*, the fore limb presents three muscles, arising either from the pectoral arch, or from the humerus, and inserted into the two bones of the forearm. On the pre-axial side are two muscles; one double-headed, the *biceps*, arising from the scapula and the coracoid, and inserted into the radius. A second, the *supinator longus*, passes from the humerus to the radius. On the post-axial side, the *brachialis anticus* arises from the humerus, and is inserted into the ulna. The hind limb has two muscles, the *sartorius*, arising from the ilium, and the *gracilis*, from the pubis, in place of the *biceps brachii*, and inserted into the pre-axial bone, the tibia, which corresponds with the radius. Two other muscles, the *semi-membranosus* and *semi-tendinosus*, pass from the ischium to the tibia, and replace, without exactly representing, the *supinator longus*. Corresponding with the *brachialis anticus* is the short head of the *biceps femoris*, arising from the femur, and inserted into the post-

axial bone of the leg, the fibula. The long head of the *biceps femoris*, which proceeds from the ischium, appears to have no representative in the fore limb.

In the fore limb, a muscle, the *pronator teres*, passes obliquely from the post-axial condyle of the humerus to the radius. In the hind limb, a corresponding muscle, the *popliteus*, proceeds from the post-axial condyle of the femur to the tibia. The *pronator quadratus*, which passes from the ulna to the radius, has its analogue, in some *Marsupialia* and *Reptilia*, in muscles which extend from the fibula to the tibia.

The Muscles of the Digits.—The remaining muscles of the two limbs are, primarily, muscles of the digits, and are attached either to the basi-digital (metacarpal or metatarsal) bones, or to the phalanges, though they may acquire secondary connections with bones of the tarsus or carpus. The plan upon which they are arranged, when they are most completely developed, will be best understood by commencing with the study of their insertion in any one of those digits which possesses a complete set; such, for example, as the fifth digit of the manus, or little finger, in Man and the higher *Primates*.

On the dorsal aspect this digit presents: first, attached to the base of its metacarpal bone, the tendon of a distinct muscle, the *extensor carpi ulnaris*. Secondly, spreading out over the phalanges into an aponeurosis, which is principally attached to the first and second, is a tendon belonging to another muscle, the *extensor minimi digiti*. Thirdly, entering the same expansion is one tendon of the *extensor communis digitorum*.

On the ventral aspect there are: first, attached to the base of the metacarpal, the tendon of a distinct muscle, the *flexor carpi ulnaris*; secondly, arising from the sides and ventral face of the metacarpal, and inserted into either side of the base of the proximal phalanx, two muscles, the *interossei*; thirdly, inserted into the sides of the middle phalanx by two slips, a tendon of the *flexor perforatus*; and fourthly, passing between these two slips, and inserted into the base

of the distal phalanx, a tendon of the *flexor perforans*. Thus there are special depressors, or flexors, for each segment of the digit. There appear, at first, to be but three elevators, or extensors, but, practically, each segment has its elevator. For the tendons of the *extensor communis* and *extensor minimi digiti* are attached to the middle and the proximal phalanges; and the distal phalanx is specially elevated by the tendons of two little muscles, which, in Man, are usually mere subdivisions of the *interossei*, and pass upwards,

Fig. 17.

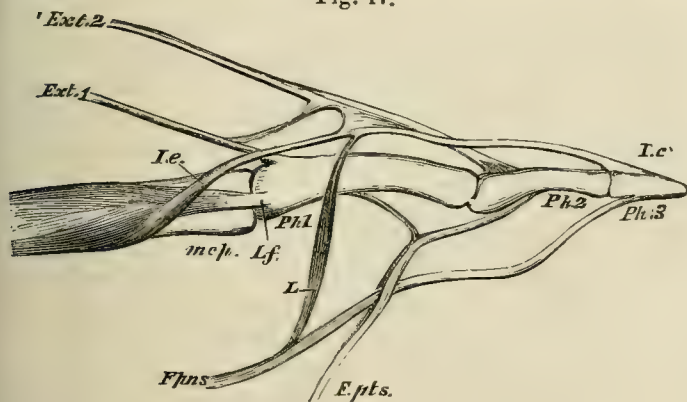


Fig. 17.—Part of the middle digit of the manus of an Orang with the flexors and extensors of the phalanges:—*mcp.*, metacarpal bone; *Ph. 1*, *Ph. 2*, *Ph. 3*, the three phalanges; *Ext. 1*, the deep long extensor tendon from the *extensor indicis*; *Ext. 2*, the superficial long extensor tendon from the *extensor communis*; *I.e.* the interosseous short extensor; *I.f.* the interosseous short flexor; *F.pns.* the deep long flexor (*perforans*); *F.pns.* the superficial long flexor (*perforatus*).

joining the extensor sheath, to be finally inserted into the distal phalanx.

The fifth digit of the pes, or little toe, sometimes presents the same disposition of muscles, namely:

On the dorsal aspect: first, the *peronæus tertius* for the metatarsal bone; secondly, one tendon from the *extensor digitorum brevis*, but this last is commonly absent in Man; thirdly, one tendon from the *extensor digitorum longus*.

On the ventral aspect: first, the *peronæus brevis*, attached

to the base of the metatarsal; secondly, two *interossei*; thirdly, a perforated flexor; and fourthly, a perforating flexor, like those of the manus. The divisions of the *interossei*, which send tendons to the extensor sheath on the dorsum of the digits of the foot in Man, are hardly distinct from the ventral divisions of those muscles.

In addition to the muscles which have been mentioned, the fifth digit has an *abductor* and an *adductor*, which may be regarded as subdivisions of the *interossei*, arising within the manus or pes, and inserted into opposite sides of the proximal phalanx; and an *opponens*, a muscle attached to the ventral face of the carpus or the tarsus, and inserted into the post-axial edge of the shaft of the metacarpal or metatarsal.

Finally, a *lumbricalis* muscle proceeds from the tendon of the perforating flexor, on the pre-axial side of the digit, to the extensor sheath.

None of the other digits of the manus, or of the pes, has a greater number of muscles than this; in fact, all the others have fewer muscles, some of those enumerated being suppressed. What are often regarded as muscles special to man, such as the *extensor proprius indicis* and *extensor minimi digiti*, are only remains of muscles which are more fully developed in lower mammals, and send tendons to all four of the ulnar digits.

Only the pollex has an *opponens*.* Only the pollex and hallux have *adductors* and *abductors*. Some of the digits lack one or more of the ventral, or of the dorsal, muscles.

The correspondence between the muscles which have been mentioned, at their insertion in the digits, is clear enough, but some difficulties present themselves when the muscles are traced to their origins.

In Man the flexors and extensors of the digits (except the *interossei*) of the fore limb, arise in part from the humerus, and in part from the bones of the forearm, but not within the manus. On the contrary, none of the flexors and extensors of the digits of the pes arise from the femur, while some of them arise within the pes itself. The origins of

* I have seen an *opponens* in the hallux of an Orang.

the muscles seem to be, as it were, higher up in the fore limb than in the hind limb. Nevertheless, several of the muscles correspond very closely. Thus, on the dorsal aspect, the *extensor ossis metacarpi pollicis* passes from the post-axial side of the proximal region of the antebrachium obliquely to the trapezium and the metacarpal of the pollex, just as its homologue, the *tibialis anticus*, passes from the post-axial side of the upper part of the leg to the entocuneiform and the base of the metatarsal of the hallux; the two muscles correspond exactly. But the extensors of the phalanges of the pollex, and the deep extensors of the other digits of the manus, arise on the same side of the antebrachium, below the *extensor ossis metacarpi pollicis*; while, in the leg, one of the deep extensors of the hallux, and all those of the other digits, arise still lower down, viz. from the calcaneum.

Not less remarkable is the contrast between the more superficial sets of extensors in the two limbs. In the fore limb, proceeding from the pre-axial to the post-axial side, the following extensor muscles arise from the external or pre-axial condyle of the humerus: the *extensor carpi radialis longus* to the base of the second metacarpal; the *extensor carpi radialis brevis* to the base of the third metacarpal; the *extensor communis digitorum* to the four ulnar digits; the *extensor minimi digiti* to the fifth digit; the *extensor carpi ulnaris* to the base of the fifth metacarpal. In the hind limb, there are no homologues of the first two of these muscles. The homologue of the *extensor communis* is the long extensor, which arises, not from the femur, but from the fibula. The *peronæus tertius*,* passing from the dorsal face of the fibula to the fifth metatarsal, is the only representative of the *extensor carpi ulnaris*.

On the ventral aspect of the human fore limb, two deep

* This muscle, which lies altogether on the dorsal face of the hind limb, and which I have seen only in Man, should not be confounded, as it often is, with one or more muscles, the *peronæi 3tii, 4ti, et 5ti digiti*, which are very

often developed in other *Mammalia*, but arise on the ventral face of the fibula, and send their tendons below the external malleolus to the extensor sheaths of the fifth, fourth, and even third digits.

flexors arise from the radius, ulna, and interosseous membrane, and run parallel with one another, though disconnected, to the digits. These are, on the pre-axial side—the *flexor pollicis longus*, to the distal phalanx of the pollex; and the *flexor digitorum perforans*, to the distal phalanges of the other digits.

In the hind limb, two homologous muscles, the *flexor hallucis longus* and the *flexor digitorum perforans*, arise from the tibia and fibula and interosseous membrane, and their tendons are distributed to the distal phalanges of the digits. But, before they divide, the tendons become connected together in such a way, that many of the digits receive tendinous fibres from both sources.

In the fore limb, there are no other deep flexors, but the internal, or post-axial, condyle of the humerus gives origin to a number of muscles. These, proceeding from the pre-axial to the post-axial side, are the *flexor carpi radialis* to the base of the second metacarpal; the *palmaris longus* to the fascia of the palm, the *flexor perforatus digitorum* to the middle phalanges of the four ulnar digits; the *flexor carpi ulnaris* to the base of the fifth metacarpal. The sesamoid, pisiform bone is developed in the tendon of the last muscle.

The only muscle which exactly corresponds with any of these, in the hind limb, is the *plantaris*; which, in Man, is a slender and insignificant muscle proceeding from the outer (post-axial) condyle of the femur to the plantar fascia—and answers to the *palmaris longus*. In many quadrupeds, as the Rabbit and Pig, the *plantaris* is a large muscle, the tendon of which passes over the end of the calcaneal process ensheathed in the *tendo-achillis*, and divides into slips, which become the perforated tendons of more or fewer of the digits. The *flexor carpi radialis* is also roughly represented by the *tibialis posticus*—a muscle which passes from the tibia and interosseous membrane to the entocuneiform, and therefore differs in insertion, as well as in origin, from its analogue in the fore limb. The *flexor perforatus digitorum* of the foot takes its origin sometimes from the calcaneum; sometimes, in part from the calcaneum, and in

part from the perforating flexor; or it may be closely connected with the tendons of the *plantaris*. The *peronæus brevis* represents the *flexor carpi ulnaris* by its insertion, but it arises no higher than the fibula, and has no sesamoid.

Two most important muscles yet remain to be considered in the leg. The one of these is that which is inserted by the *tendo-achillis* into the calcaneum, and arises by four heads, two from the condyles of the femur (called *gastrocnemius*), and two from the tibia and fibula (called *soleus*). The other muscle is the *peronæus longus*, arising from the fibula, passing behind the external malleolus, and then crossing the foot to the base of the metatarsal of the hallux.

The latter muscle does not appear to have any representative in the fore limb. The *gastrocnemius* and *soleus* may possibly represent the crural part of the perforated flexor, since in many of the *Vertebrata*, the *tendo-achillis* is but loosely connected with the calcaneum, and passes over it into the plantar fascia and the perforated tendons. A peculiar adductor muscle of the hallux in Man and Apes is the *transversalis pedis*, which is inserted into the basal phalanx of the hallux, and arises from the distal ends of the metatarsals of the other digits. The muscle sometimes has an analogue in the manus.

Electrical Organs.—Certain fishes belonging to the genera *Torpedo* (among the *Elasmobranchii*), *Gymnotus*, *Malapterurus*, and *Mormyrus* (among the *Teleostei*), possess organs which convert nervous energy into electricity, just as muscles convert the same energy into ordinary motion, and therefore may well be mentioned in connection with the nervous system. The “electrical organ” is always composed of nearly parallel lamellæ of connective tissue, inclosing small chambers, in which lie what are termed the *electrical plates*. These are cellular structures, in one face of which the final ramifications of the nerves, which are supplied to the organ by one or many trunks, are distributed. The face on which the nerves ramify is in all

the plates the same, being inferior in *Torpedo*, where the lamellæ are disposed parallel to the upper and under surfaces of the body; posterior in *Gymnotus*, and anterior in *Malapterurus*, the lamellæ being disposed perpendicularly to the axis in these two fishes. And this surface, when the discharge takes place, is always negative to the other.

Fig. 18.

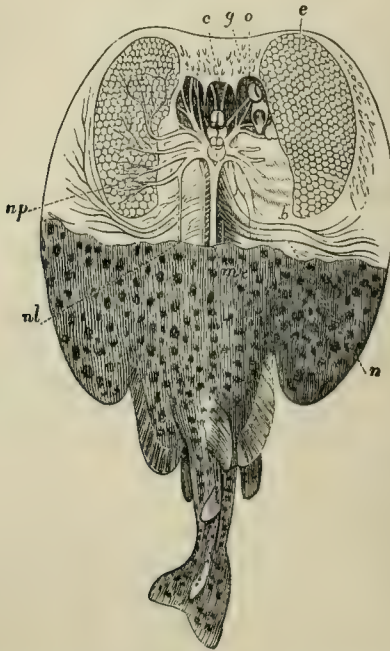


Fig. 18.—The *Torpedo*, with its electrical apparatus displayed.—*b*, branchiæ; *c*, brain; *e*, electric organ; *g*, cranium; *m e*, spinal cord; *n*, nerves to the pectoral fins; *nl*, *nervi laterales*; *np*, branches of the pneumogastric nerves going to the electric organ; *o*, eye.

In *Torpedo* the nerves of the electrical organs proceed from the fifth pair, and from the “electric lobe” of the *medulla oblongata*, which appears to be developed at the origin of the pneumogastrics. In the other electrical fishes

the organs are supplied by spinal nerves; and in *Malapterurus*, the nerve consists of a single gigantic primitive fibre, which subdivides in the electrical organ.

The ordinary Rays possess organs of much the same structure as the electrical apparatus, at the sides of the tail.

The Nervous System: the Encephalon.—In all vertebrated animals except *Amphioxus*, the brain exhibits that separation into a *fore-brain*, *mid-brain*, and *hind-brain*, which results from its embryonic division by two constrictions, into the three thin-walled vesicles—the anterior, middle, and posterior cerebral vesicles—already mentioned. The cavities of these vesicles—the primitive ventricles of the brain—freely communicate at first, but become gradually diminished by the thickening of their sides and floors. The cavity of the anterior vesicle is, in the adult human brain, represented by the so-called *third ventricle*; that of the middle vesicle, by the *iter a tertio ad quartum ventriculum*; that of the posterior vesicle, by the *fourth ventricle*.

The floor and sides of the posterior vesicle, in fact, thicken and become the *medulla oblongata*; together with the *pons varolii*, in those animals which possess the latter structure. The posterior part of the roof is not converted into nervous matter, but remains thin and attenuated; the *ependyma*, or lining of the cerebral cavity, and the *arachnoid*, or serous membrane which covers the brain externally, coming nearly into contact, and forming, to all appearance, a single thin membrane, which tears with great readiness, and lays open the cavity of the fourth ventricle. Anteriorly, on the other hand, the roof becomes converted into nervous matter, and may enlarge into a complex mass, which overhangs the posterior division, and is called the *cerebellum*. The *pons varolii*, when it exists, is the expression of commissural fibres, which are developed in the sides and floor of the anterior part of the posterior cerebral vesicle, and connect one half of the cerebellum with the other.

Thus the *hind-brain* differs from the posterior cerebral vesicle in being differentiated into the *medulla oblongata*

(or *myelencephalon*) behind, and the cerebellum with the pons varolii (which together constitute the *metencephalon*) in front.

Fig. 19.

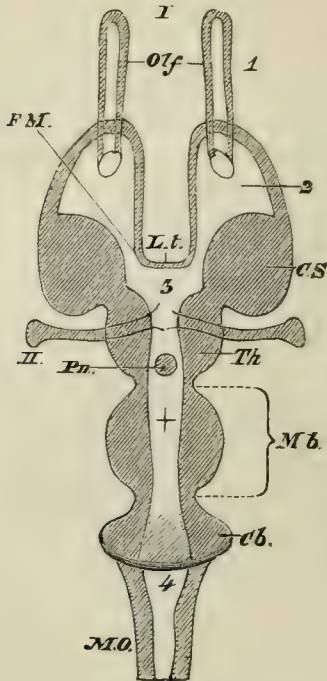


Fig. 19.—Diagrammatic horizontal section of a Vertebrate brain. The following letters serve for both this figure and Fig. 20:—*Mb*, Mid-brain. What lies in front of this is the fore-brain, and what lies behind, the hind-brain. *L.t.* the lamina terminalis; *Olf*, the olfactory lobes; *Hmp*, the hemispheres; *Th.E*, the thalamencephalon; *Pn*, the pineal gland; *Py*, the pituitary body; *FM*, the foramen of Munro; *CS*, the corpus striatum; *Th*, the optic thalamus; *CQ*, the corpora quadrigemina; *CC*, the crura cerebri; *Cb*, the cerebellum; *PV*, the pons varolii; *MO*, the medulla oblongata; *I*, olfactorii; *II*, optici; *III*, point of exit from the brain of the motores oculorum; *IV*, of the pathetici; *VI*, of the abducentes; *V-XII*, origins of the other cerebral nerves. 1, olfactory ventricle; 2, lateral ventricle; 3, third ventricle; 4, fourth ventricle; +, *iter a tertio ad quartum ventriculum*.

The floor of the middle cerebral vesicle thickens, and becomes converted into two great bundles of longitudinal

fibres, the *crura cerebri*. Its roof, divided into two, or four, convexities by a single longitudinal, or a crucial, depression, is converted into the "optic lobes," *corpora bigemina* or *quadrigemina*. And these parts, the optic lobes, the *crura cerebri*, and the interposed cavity, which either retains the form of a ventricle, or is reduced to a mere canal (the *iter a tertio ad quartum ventriculum*), are the components of the *mid-brain* or *mesencephalon*.

Fig. 20.

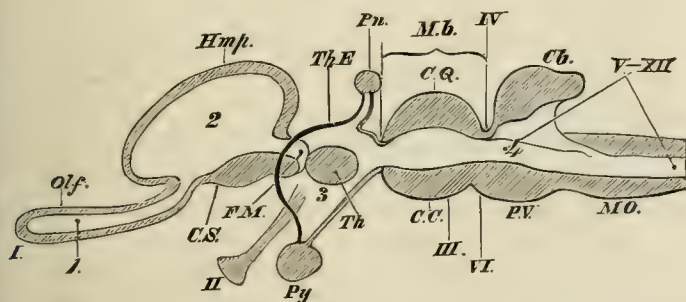


Fig. 20.—A longitudinal and vertical section of a Vertebrate brain. The letters as before. The *lamina terminalis* is represented by the strong black line between *FM* and 3.

The anterior cerebral vesicle undergoes much greater changes than either of the foregoing; for, in the first place, it throws out from its anterior lateral parietes two hollow prolongations, the *hemispheres* (or *prosencephala*), and each of these again protrudes from its anterior end a smaller hollow process, the *olfactory lobe* (or *rhinencephalon*). By the development of these processes the anterior vesicle becomes divided into five parts—one median and posterior, and four anterior and paired. The median and posterior, which remains as the representative of the greater part of the original anterior cerebral vesicle, is the *vesicle of the third ventricle* (or *thalamencephalon*). Its floor is produced into a conical process, the *infundibulum*, the blind end of which is connected with the pituitary body, or *hypophysis cerebri*. Its sides thicken greatly, acquire a ganglionic

structure, and become the *optic thalami*. Its roof, on the other hand, resembles that of the fourth ventricle, in remaining very thin, and, indeed, a mere membrane. The pineal gland, or *epiphysis cerebri*, is developed in connection with the upper wall of the third ventricle; and, at the sides of its roof, are two nervous bands, which run to the pineal gland, and are called its peduncles.

The front wall of the vesicle, in part, becomes the so-called *lamina terminalis*, which is the delicate anterior boundary of the third ventricle. In certain directions, however, it thickens and gives rise to three sets of fibres, one transverse and two vertical—the former lying in front of the latter. The transverse fibres pass on either side into the *corpora striata*, and constitute the *anterior commissure* which connects those bodies. The vertical fibres are the *anterior pillars of the fornix*, and they pass below into the floor of the third ventricle, and into the *corpora mammillaria*, when those structures are developed.

The outer and under wall of each cerebral hemisphere thickens and becomes the *corpus striatum*, a ganglionic structure which, from its origin, necessarily abuts against the outer and anterior part of the *optic thalamus*. The line of demarcation between the two corresponds with the lower lip (*tænia semicircularis*) of the aperture of communication (called the *foramen of Munro*) between the third ventricle and the cavity of the cerebral hemisphere, which is now termed the *lateral ventricle*. In the higher *Vertebrata*, the upper lip of the foramen of Munro thickens, and becomes converted into a bundle of longitudinal fibres, which is continuous, anteriorly, with the anterior pillars of the fornix before mentioned. Posteriorly, these longitudinal fibres are continued backwards and downwards along the inner wall of the cerebral hemisphere, following the junction of the *corpora striata* and *optic thalami*, and pass into a thickening of the wall of the hemisphere, which projects into the lateral ventricle, and is called the *hippocampus major*. Thus a longitudinal commissural band of nervous fibres, extending from the floor of the third ventricle to that of the lateral

ventricle, and arching over the foramen of Munro, is produced. The fibres of opposite sides unite over the roof of the third ventricle, and constitute what is called the body of the *fornix*. Behind this union the bands receive the name of the *posterior pillars of the fornix*.

The optic thalami may be connected by a *grey soft commissure*; and a *posterior commissure*, consisting of transverse nerve-fibres, is generally developed between the posterior ends of the two thalami.

In the *Mammalia*, a structure, which is absent in other *Vertebrata*, makes its appearance; and, in the higher members of that class, this *corpus callosum* is the greatest and most important mass of commissural fibres. It is a series of transverse fibres, which extends from the roof of one lateral ventricle to that of the other, across the interval which separates the inner wall of one hemisphere from that of the other.

When the corpus callosum is largely developed, its anterior part crosses the interspace between the hemispheres considerably above the level of the fornix; so that between the fornix and it, a certain portion of the inner wall of each hemisphere, with the intervening space, is intercepted. The portion of the two inner walls and their interspace, thus isolated from the rest, constitutes the *septum lucidum*, with its contained *fifth ventricle*.

The Modifications of the Brain.—The chief modifications in the general form of the brain arise from the development of the hemispheres relatively to the other parts. In the lower vertebrates the hemispheres remain small, or of so moderate a size as not to hide, by overlapping, the other divisions of the brain. But, in the higher *Mammalia*, they extend forwards over the olfactory lobes, and backwards over the optic lobes and cerebellum, so as completely to cover these parts; and, in addition, they are enlarged downwards towards the base of the brain. The cerebral hemisphere is thus, as it were, bent round its *corpus striatum*, and it becomes distinguished into regions, or *lobes*, which are not separated by any very sharp lines of demarcation. These regions are named the *frontal, parietal,*

occipital, and *temporal* lobes—while, on the outer side of the *corpus striatum*, a *central* lobe (the *insula* of Reil) lies in the midst of these. The lateral ventricles are prolonged into the frontal, occipital, and temporal lobes, and acquire what are termed their *anterior*, *posterior*, and *descending*, *cornua*.

Furthermore, while, in the lower vertebrates, the surface of the cerebral hemispheres is smooth; in the higher, it becomes complicated by ridges and furrows, the *gyri* and *sulci*, which follow particular patterns. The superficial vascular layer of connective tissue which covers the brain, and is called *pia mater*, dips into these sulci: but the *arachnoid*, or delicate serous membrane, which, on the one hand, covers the brain, and, on the other, lines the cranium, passes from convolution to convolution without entering the sulci. The dense periosteal membrane which lines the interior of the skull, and is itself lined by the parietal layer of the arachnoid, goes by the name of the *dura mater*.

The general nature of the modifications observable in the brain as we pass from the lower to the higher *mammalia* is very well shown by the accompanying figures of the brain of a Rabbit, a Pig, and a Chimpanzee (Figs. 21 & 22).

In the Rabbit, the cerebral hemispheres leave the cerebellum completely exposed when the brain is viewed from above. There is but a mere rudiment of the Sylvian fissure at *Sy*, and the three principal lobes, frontal (*A*), occipital (*B*), and temporal (*C*), are only indicated. The olfactory nerves are enormous, and pass by a broad smooth tract, which occupies a great space in the lateral aspect of the brain, into the natiform protuberance of the temporal lobe (*C*).

In the Pig, the olfactory nerves and tract are hardly less conspicuous; but the natiform protuberance is more sharply notched off, and begins to resemble the unciform gyrus in the higher *Mammalia*, of which it is the homologue. The temporal gyri (*C*¹), though still very small, begin to enlarge downwards and forwards over this. The upper part of the cerebral hemisphere is much enlarged, not only in the frontal, but also in the occipital region, and to a great extent

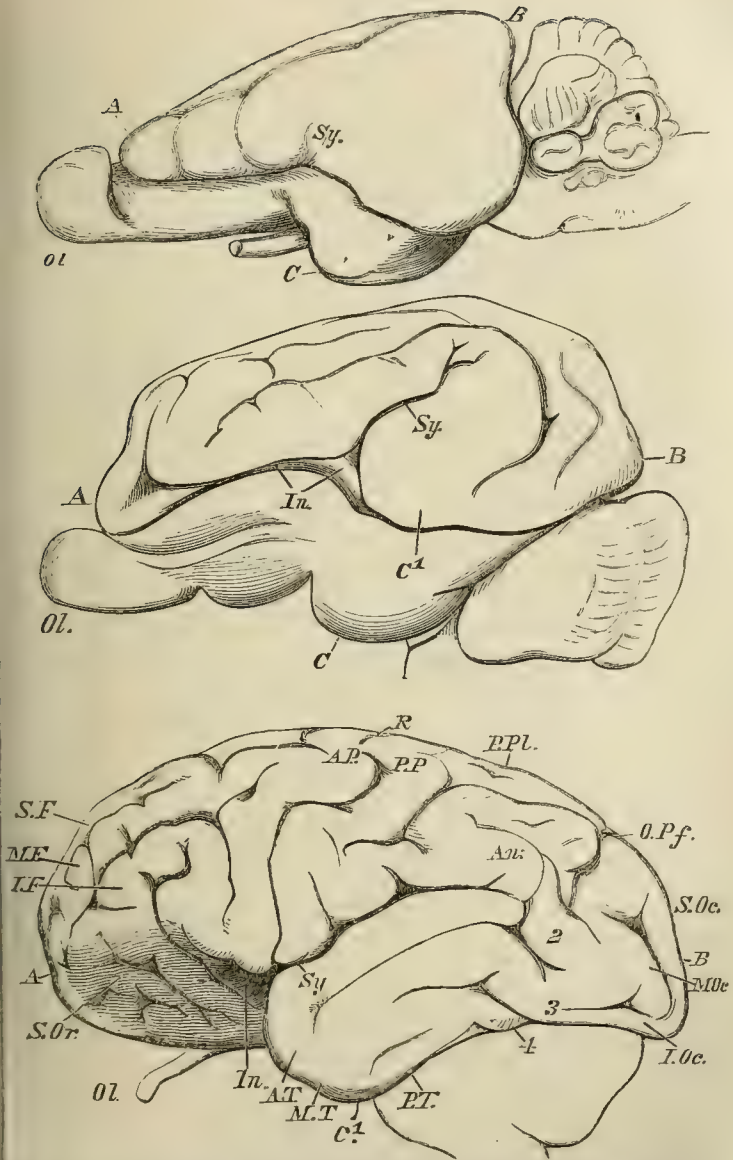


Fig. 21.—Lateral views of the brains of a Rabbit, a Pig, and a Chimpanzee, drawn of nearly the same absolute size. The Rabbit's brain is at the top; the Pig's, in the middle, the Chimpanzee's, lowest.

Ol, the olfactory lobe; *A.*, the frontal lobe; *B.*, the occipital lobe; *C.*, the temporal lobe; *Sy.*, the Sylvian fissure; *In.*, the insula; *S. Or.*, supraorbital; *S.F.*, *M.F.*, *I.F.*, superior, middle, and inferior frontal gyri; *A.P.*, antero-parietal; *P.P.*, postero-parietal gyri; *R.*, sulcus of Rolando; *P.Pl.*, postero-parietal lobule; *O.Pf.*, external perpendicular or occipito-temporal sulcus; *An.*, angular gyrus; 2, 3, 4, annectent gyri; *A.T.*, *M.T.*, *P.T.* the three temporal, and *S.Oc.*, *M.Oc.*, *I.Oc.* the three occipital gyri.

hides the cerebellum when the brain is viewed from above. What in the Rabbit was a mere angulation at *Sy*, in the Pig has become a long sulcus—the *Sylvian fissure*, the lips of which are formed by a gyrus, the *Sylvian*, or *angular*, gyrus. Two other sets of gyri, more or less parallel with this, are visible upon the outer surface of the hemisphere; and at the entrance of the Sylvian fissure, at *In*, there is an elevation which answers to the *insula*, or *central lobe*.

In the Chimpanzee, the olfactory nerves, or rather lobes, are, relatively, very small, and the tracts which connect them with the uncinatæ gyri (*substantiæ perforatæ*) are completely hidden by the temporal gyri (*C*¹). The Sylvian fissure is very long and deep, and begins to hide the *insula*, on which a few fan-shaped gyri are developed. The frontal lobes are very large, and overlap the olfactory nerves for a long distance; while the occipital lobes completely cover and extend beyond the cerebellum, so as to hide it completely from an eye placed above. The gyri and sulci have now attained an arrangement which is characteristic of all the highest *Mammalia*. The fissure of Rolando (*R*) divides the antero-parietal gyrus (*A.P*) from the postero-parietal (*P.P*). These two gyri, with the postero-parietal lobule (*P.Pl.*), and part of the angular gyrus (*An*), constitute the *Parietal lobe*. The *frontal lobe*, which lies anterior to this, the *occipital lobe*, which lies behind it, and the *temporal lobe*, which lies below it, each present three tiers of gyri, which, in the case of the frontal and occipital lobes, are called superior, middle, and inferior—in that of the temporal lobe, anterior, middle, and posterior. The inferior surface of the frontal lobe, which lies on the roof of the orbit (*S. Or.*), presents many small sulci and gyri.

On the inner face of the cerebral hemisphere (Fig. 22)

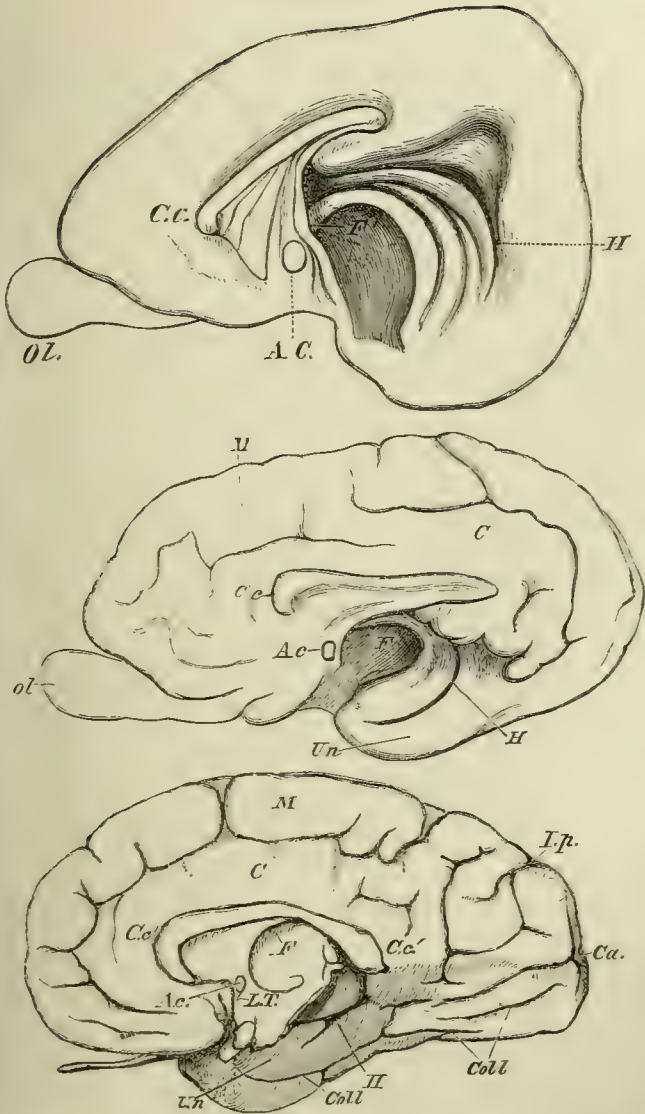


Fig. 22.—Inner views of the cerebral hemispheres of the Rabbit, Pig, and Chimpanzee. drawn as before, and placed in the same order
Ol. olfactory lobe; *C.c.* corpus callosum; *A.c.* anterior commissure; *H.* hippocampal sulcus; *Un.* uncinate; *M.* marginal; *C.* callosal gyri; *I.p.* internal perpendicular; *Ca.* calcarine; *Coll.* collateral sulci; *F.* fornix.

the only sulcus presented by the Rabbit's brain is that deep and broad depression (*H*), which runs parallel with the posterior pillar of the fornix, and gives rise, in the interior of the descending cornu of the lateral ventricle, to the projection which is termed the *hippocampus major*. In the Pig, this *hippocampal sulcus* (*H*) is much narrower and less conspicuous; and a *marginal* (*M*) and a *callosal* (*C*) gyrus are separated by a well-marked *calloso-marginal* sulcus. As in the Rabbit, the uncinete gyrus forms the inferior boundary of the hemisphere. In the Chimpanzee, the marginal and callosal gyri are still better marked. There is a deep internal perpendicular, or *occipito-parietal*, sulcus (*Lp*). The *calcarine* sulcus (*Ca*) causes a projection into the floor of the posterior cornu, which is the *hippocampus minor*; while the *collateral* sulcus (*Coll*) gives rise to the eminence of that name in both the posterior and descending cornua. The hippocampal sulcus (*H*) is relatively insignificant, and the lower edge of the temporal lobe is formed by the posterior temporal gyrus.

In the Rabbit, the corpus callosum is relatively small, much inclined upwards and backwards; and its anterior extremity is but slightly bent downwards, so that the so-called *genu* and *rostrum* are inconspicuous. The Pig's corpus callosum is larger, more horizontal, and possesses more of a rostrum: in the Chimpanzee, it is still larger, somewhat deflexed, and very thick posteriorly; and has a large rostrum. In proportion to the hemispheres, the anterior commissure is largest in the Rabbit and smallest in the Chimpanzee. The Rabbit and the Pig have a single *corpus mammillare*, the Chimpanzee has two. The cerebellum of the Rabbit is very large in proportion to the hemispheres, and is left completely uncovered by them in the dorsal view. Its median division, or *vermis*, is straight, symmetrical, and large in proportion to the lateral lobes. The *flocculi*, or accessory lobules developed from the latter, are large, and project far beyond the margins of the lateral lobes. The ventral face of the metencephalon presents on each side, behind the posterior margin of the pons

varolii, flattened rectangular areae, the so-called *corpora trapezoidea*.

In the Pig, the cerebellum is relatively smaller, and is partially covered by the hemispheres; the lateral lobes are larger in proportion to the vermis and the flocculi, and extend over the latter. The *corpora trapezoidea* are smaller. In the *Chimpanzee*, the relatively still smaller cerebellum is completely covered; the vermis is very small in relation to the lateral lobes, which cover and hide the insignificant flocculi. There are no *corpora trapezoidea*.

In all the characters now mentioned the brain of Man differs far less from that of the *Chimpanzee* than that of the latter does from the Pig's brain.

The Myelon.—The spinal canal, and the cord which it contains, are lined by continuations of the three membranes which protect the encephalon. The cord is sub-cylindrical, and contains a median longitudinal canal, the *canalis centralis*, the remains of the primitive groove. It is divided by anterior and posterior median fissures into two lateral halves, which are, usually, connected only by the comparatively narrow isthmus, which immediately surrounds the *canalis centralis*. The cord may, in the adult, extend through the whole spinal canal, or it may come to an end at any point between the caudal extremity and the anterior thoracic region.

The distribution of the two essential constituents of nervous tissue, ganglionic corpuscles and nerve-fibres, is very definite in the spinal cord, ganglionic corpuscles being confined to the so-called "grey matter" which constitutes the isthmus, and spreads out into two masses, each of which ends in an anterior (or ventral) and a posterior (or dorsal) horn. Nerve-fibres also abound in the grey matter; but the so-called "white matter," which constitutes the external substance of the cord, contains only the fibrous nervous matter, and has no ganglionic corpuscles.

The spinal nerves arise in opposite pairs from the two halves of the cord, and usually correspond in number with

Fig. 23.

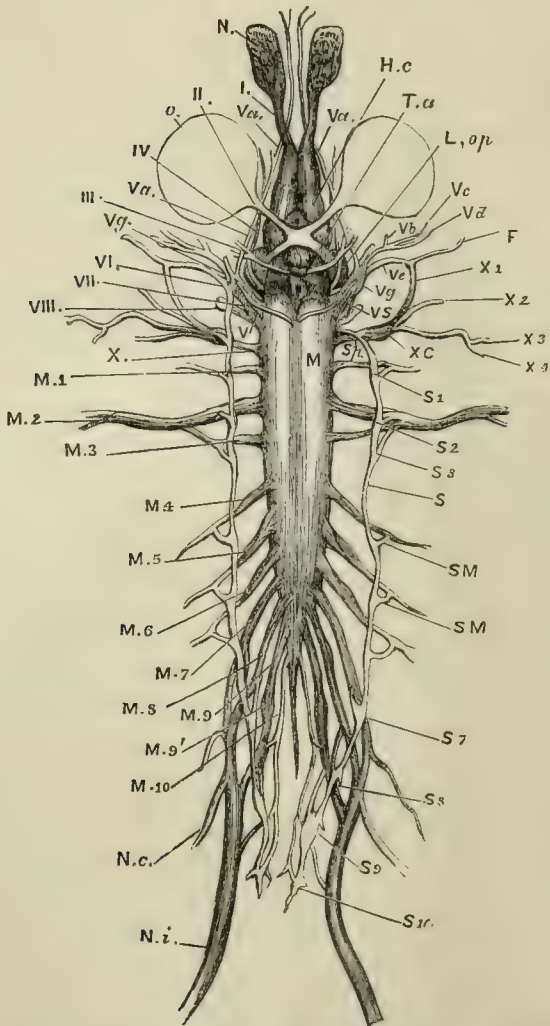


Fig. 23.—A diagrammatic view of the Chief Trunks of the Cerebrospinal and Sympathetic Nervous Systems of *Rana esculenta* seen from below (twice the size of nature). I. The olfactory nerves. N. The olfactory sac. II. The optic nerve. O. The eye. L. op. The optic lobes. Ta. Optic tracts passing from the optic lobes to

the chiasma, behind which lies the pituitary body. III. *Oculomotorius*. IV. *Patheticus*. V. The trigeminal, with which the *abducens* (VI.), *facialis* (VII.), and the upper end of the sympathetic (V.S.), are closely connected. Branches of this nervous plexus are *V.a.*, the nasal and ophthalmic branches of the fifth and the *abducens* *V.b, c, d.*, the palatine, maxillary, and mandibular branches of the fifth. *V.e.*, the tympanic branch into which the proper facial nerve (VII.) enters, and, with a branch of the vagus, forms the so-called facial nerve of the Frog, *F.* VIII. The auditory nerve. *X.*, with its branches *X¹, X², X³, X⁴,* represents the glossopharyngeal and the vagus. The medulla oblongata (*Myelencephalon*) ends, and the medulla spinalis (*Myelon*) begins, about the region marked by the letter *M.* *M 1-10,* the spinal nerves. *M 2,* the brachial nerves, *M 7, 8, 9,* the ischiatic plexus, from which proceed the crural (*N. c.*) and ischiatic (*N. i.*) nerves. *S.* The trunk of the sympathetic. *S.M.* The communicating branches with the spinal ganglia. *S 1-10.* The sympathetic ganglia.

the vertebræ through, or between, which they pass out (Fig. 23). Each nerve has two roots, one from the dorsal, and one from the ventral, region of its half of the cord. The former root has a ganglionic enlargement, and only contains sensory fibres; the latter has no ganglion, and exclusively contains motor fibres.* After leaving the vertebral canal, each spinal nerve usually divides into a dorsal and a ventral branch; but, in the Ganoid fishes, each of these branches is a distinct nerve, arising by its own proper roots.

The Cerebral Nerves.—The greatest number of pairs of nerves ever given off from the vertebrate brain is twelve, including the so-called olfactory nerves, and the optic nerves, which, as has been seen, are more properly diverticula of the brain, than nerves in the proper sense of the word.

The olfactory “nerves” (*olfactorii*) constitute the *first pair* of cerebral nerves. They always retain their primary connection with the cerebral hemispheres, and frequently contain, throughout life, a cavity, the *olfactory ventricle*, which communicates with the lateral ventricle.

The optic “nerves” (*optici*) are the *second pair* of cerebral nerves. In the Lampreys and Hags (*Marsipobranchii*) these nerves retain their embryonic origin from the thala-

* *Amphioxus* appears to be an exception to this, as to most other, rules of Vertebrate anatomy.

mencephalon, and each goes to the eye of its own side. In other *Vertebrata*, the nerves cross one another at the base of the brain (*Teleostei*), or are fused together into a *chiasma* (*Ganoidei*, *Elasmobranchii*, and all the higher *Vertebrata*). In the higher *Vertebrata*, again, the fibres of the optic nerves become connected chiefly with the mesencephalon.

All the other cerebral nerves differ from these in arising, not as diverticula of any of the cerebral vesicles, but by histological differentiation of the primitive brain-case, or *laminæ dorsales* of the skull.

The *third* (*motores oculorum*) and *fourth* (*pathetici*) pairs of nerves are distributed to the muscles of the eye; the third to the majority of these muscles, the fourth to the superior oblique muscles. The third pair of nerves issues from the *crura cerebri*, or inferior division of the metencephalon, upon the base of the brain; the fourth pair, from the forepart of the upper division of the metencephalon, immediately behind the optic lobes, upon the superior surface of the brain. This region is known as the *Valve of Vieussens* in the *Mammalia*.

All the other cerebral nerves originate in the posterior division of the *hind-brain*—the myelencephalon. The great *fifth* pair (*trigemini*) passes out from the sides of the metencephalon, and supplies sensory nerves to the integument of the head, and motor nerves to most of the muscles of the jaws, by its three divisions—the *ophthalmic*, the *superior maxillary*, and the *inferior maxillary*, nerves.

Of these divisions the two latter are, very generally, closely connected together, while the ophthalmic division remains distinct. The ophthalmic division passes to the cleft between the trabecula and the maxillary process (which nearly corresponds with the orbit, and might be termed the *orbito-nasal* cleft), and is distributed to the inner and the outer side of that cleft. Hence its main branches are nasal and lachrymal. The two maxillary nerves, on the other hand, are distributed to the inner and outer sides, or anterior and posterior boundaries, of the buccal cleft. Hence the superior maxillary belongs to the posterior, or outer,

side of the maxillary process, while the inferior maxillary appertains to the anterior region of the first visceral arch. The superior maxillary commonly unites with the outer, or lachrymal, division of the ophthalmic; the inferior maxillary with the anterior division of the facial.

In the higher *Vertebrata*, the trigeminal nerve usually has two very distinct roots, a dorsal sensory, provided with a ganglion (the *Casserian* ganglion), and a ventral motor, non-ganglionated. The fibres of the latter pass almost exclusively into the inferior maxillary division. In addition, the ophthalmic division may have a ganglion (*ciliary*); the superior maxillary another (*sphenopalatine* or *Meckelian*), and the inferior maxillary a third (*otic*).

The *sixth* pair (*abducentes*) issues from the inferior surface of the brain, at the junction of the myelencephalon with the metencephalon. It supplies the external straight muscles of the eye; with the muscles of the nictitating membrane, and the *retractor bulbi*, or *musculus choanoides*, when such muscles exist.

The *seventh* pair (*faciales*) supplies the superficial facial muscles, and ultimately divides into two branches, one of which is in relation with the mandibular, and the other with the hyoidean arch.

The five nerves which have just been mentioned are often intimately connected together. Thus, in the *Lepidosiren*, the three motor nerves of the eyeball are completely fused with the ophthalmic division of the fifth.* In the Myxinoid fishes there are no motor nerves of the eyeball; but, in the Lamprey, the *rectus externus* and *inferior*, and the *obliquus inferior*, are supplied by the ophthalmic, while the oculomotor and the pathetic unite into a common trunk, which gives branches to the *rectus superior* and *internus*, and *obliquus superior*. The oculomotor, the pathetic, and the

* I am greatly disposed to think that the motor nerves of the eye more nearly retain their primary relations in *Lepidosiren* than in any other vertebrated animal; and that they are really the motor

portions of the nerves of the orbito-nasal cleft, the third and fourth appertaining to the inner division of the ophthalmic, the sixth to its outer division.

abducens, are more or less confounded with the ophthalmic in the *Amphibia*; but in *Teleostei*, *Ganoidei*, *Elasmobranchii*, and in all the higher *Vertebrata*, the nerves of the muscles of the eye are distinct from the fifth pair, except where the oculomotor unites with the ophthalmic into the ciliary ganglion.

The facial and the trigeminal nerves have common roots in fishes. In *Amphibia*, though the roots are distinct, the facial may be completely united with the ganglion of the trigeminal, as in the Frog. In all abbranchiate *Vertebrata* the two nerves are quite distinct.

Whether the nerves are distinct or not, a *palatine*, or *vidian*, nerve (which, in the higher *Vertebrata*, is especially connected with the facial) runs through, or beneath, the base of the skull, parallel with its long axis; and, after uniting with the superior maxillary, and usually contributing to form the *sphenopalatine*, or *Meckelian*, ganglion, is distributed to the mucous membrane of the roof of the mouth; and the mandibular division of the seventh, or *chorda tympani*, unites with the inferior maxillary division of the fifth nerve.

The *eighth* pair (*auditorii*) is formed by the nerves of the organ of hearing.

The *ninth* pair (*glossopharyngei*) is especially distributed to the pharyngeal and lingual regions of the alimentary canal, and, primarily, supplies the boundaries of the second visceral cleft.

The *tenth* pair (*pneumogastrici* or *vagi*) consists of very remarkable nerves, which pass to the gullet and stomach, the respiratory and vocal organs, to some parts of the integument of the body, and to the heart. In the *Ichthyopsida* they give off, in addition, long *lateral* nerves to the integuments of the sides of the body. In the higher *Vertebrata*, these lateral nerves are represented only by small branches distributed chiefly to the occipital region. The ninth and tenth pairs are both motor and sensory in function, and are often so intimately connected as to form almost one nerve.

The *eleventh* pair (*accessorii*) are cerebral only by courtesy, as these nerves take their origin from the spinal cord, by roots which issue between the proper anterior and posterior roots of the spinal nerves, and, joining together, form, on each side, a nerve which passes out with the pneumogastric, partly joining it, and partly going to muscles which arise from the head and anterior vertebræ, and are inserted into the pectoral arch.

The spinal accessory exists in no Ichthyopsid vertebrate, but is found in all *Sauropsida*, with the exception of the *Ophidia*, and in the *Mammalia*.

The *twelfth* and last pair (*hypoglossi*) are the motor nerves of the tongue, and of some retractor muscles of the hyoidean apparatus.

In the *Ichthyopsida* the first cervical nerve supplies the distributional area of the hypoglossal; but in all the abran- chiate *Vertebrata* there is a hypoglossal, which traverses a foramen in the ex-occipital, though it often remains closely connected with the first cervical, and may rather be re- garded as a subdivision of that nerve, than as a proper cerebral nerve.

Thus the nerves arising from the hind-brain, in all the higher *Vertebrata*, fall into three groups: 1st, a sensori- motor, pre-auditory, set (3rd, 4th, 5th, 6th, 7th); 2nd, the purely sensory auditory nerve (8th); 3rd, the sensori-motor, post-auditory, set (9th, 10th, 12th).

The apertures by which several of these nerves leave the skull, retain a very constant relation to certain elements of the cranium on each side. Thus:

a. The filaments of the olfactory nerve always leave the cranium between the lamina perpendicularis, or body of the ethmoid, and its lateral or prefrontal portion.

b. The optic nerve constantly passes out behind the centre of the orbitosphenoid and in front of that of the alisphenoid.

c. The third division of the trigeminal, or fifth nerve, always leaves the skull behind the centre of the alisphenoid and in front of the pro-otic.

d. The glossopharyngeal and pneumogastric always make their exit behind the centre of the opisthotic, and in front of the centre of the ex-occipital.

The apertures for the exit of the cranial nerves denoted in the paragraphs, *a. b. c. d.*, when surrounded by bone, and well defined, are called respectively : *a*, the *olfactory foramen* ; *b*, the *optic foramen* ; *c*, the *foramen ovale* ; *d*, the *foramen lacerum posterius*. The adjacent bones may take equal shares in bounding these foramina, or the foramina may be altogether in one bone ; but their positions, as here defined, never change.

Another point to be especially considered respecting the general disposition of the cranial nerves, is the relation which some of them bear to the visceral arches and clefts, and which has already been incidentally mentioned. Thus, the seventh nerve is distributed to the posterior part of the first visceral arch, and to the anterior part of the second visceral arch, its two branches inclosing the first visceral cleft. In like manner, the ninth (glossopharyngeal) nerve is distributed to the hinder part of the second arch and to the front part of the third, its branches inclosing the second visceral cleft. The first branch of the pneumogastric has similar relations to the third and fourth arches and to the third cleft ; and in branchiate *Vertebrata*, the other anterior branches of the pneumogastric are similarly distributed to the successive branchial arches, the two divisions of each branch inclosing a branchial cleft.

The second and the third divisions of the trigeminal are distributed, in an analogous manner, to the anterior region of the first visceral arch, and to the posterior or outer region of the maxillo-palatine process—the gape of the mouth representing a visceral cleft between the two. The inner and outer portions of the first division of the trigeminal are similarly related to the inner, or anterior, region of the maxillo-palatine process, and the outer side of the *trabecula crani*—the orbito-nasal fissure representing the cleft between the two.

Considerations of this kind suggest that the trabeculæ

and the maxillo-palatine processes may represent pre-oral visceral arches, which are bent forward; and, in the case of the *trabeculæ*, coalesce with one another. Such an hypothesis would enable us to understand the signification of the naso-palatine canal of the Myxinoid fishes, which would be simply the interspace, or passage, between the trabeculæ (which must have originally existed if ever they were distinct visceral arches) not yet filled up; and the anomalous process of the roof of the oral cavity, which extends towards the pituitary body in the embryos of the *Vertebrata* in general, might be regarded as the remains of this passage.

On this hypothesis, six pair of inferior arches belong to the skull—namely, the trabecular and maxillo-palatine, in front of the mouth; the mandibular, the hyoidean, and two others (first and second branchial), behind it. For, as there are three cranial nerves embracing the first three visceral clefts which lie behind the mouth, there must be four post-oral, cranial, visceral arches.

Supposing that the occipital segment in the brain-case answers to the hindermost, or second branchial, cranial, visceral arch, the invariable attachment of the proximal ends of the mandibular and hyoidean arches to the auditory capsule leads me to assign the parietal and the frontal segments to the maxillo-palatine and trabecular visceral arches. And thus the ossifications of the auditory capsule, alone, are left as possible representatives of the neural arches of the three anterior post-oral visceral arches.

But these speculations upon the primitive composition of the skull, however interesting, must not, as yet, be placed upon the same footing as the doctrine of its segmentation, which is simply a generalisation of anatomical facts.

The Sympathetic.—A Sympathetic Nervous System has been observed in all the *Vertebrata* except *Amphioxus* and the *Marsipobranchii*. It consists, essentially, of two longitudinal cords, placed one upon each side of the inferior face of the cranio-spinal axis. Each cord receives communicating fibres from the spinal nerves of its own side, and,

when complete, from all the cranial nerves except those of the special senses of hearing, sight, and smell—the Vidian nerves constituting the anterior terminations of the sympathetic cords. At the points of communication ganglia are developed, and the nerves which emerge from these ganglia are distributed to the muscles of the heart and vessels, and to those of the viscera. These peripheral nerves of the sympathetic system frequently present small ganglionic enlargements.

In the *Marsipobranchii*, the place of the sympathetic appears to be taken, to a great extent, by the pneumogastric; and, in *Myxine*, the two pneumogastrics unite upon the intestine, and follow it, as a single trunk, to the anus.

The Sensory Organs.—The organs of the three higher senses—Smell, Sight, and Hearing—are situated, as has been already described, in pairs, upon each side of the skull, in all vertebrate animals except the lowest fishes; and, in their earliest condition, they are alike involutions of the integument.

The *Olfactory Apparatus* acquires no higher complication than this, being either a single sac (*Amphioxus* (?) *Marsipobranchii*), or, more commonly, two, the surfaces of which are increased by plaiting, or by the development of turbinal cartilages, or bones, from the lateral portions of the ethmoid. Upon these, nervous filaments arising from the olfactory lobe of the brain are distributed. The cavities of the olfactory sacs may be placed in communication with that of the mouth by the nasal passages; or, as in the great majority of fishes, they may have only an external aperture, or apertures.

In Reptiles, Birds, and Mammals, a peculiar *nasal gland* is frequently connected with, and pours its secretion into, each olfactory chamber.

The *foramina incisiva*, left between the premaxillaries and the palatine plates of the maxillaries in *Mammalia*, are sometimes closed by the mucous membranes of the nasal and oral cavities, and sometimes not. In the latter case they

are the *canals of Stenson*, and place these two cavities in communication. Glandular diverticula of the mucous membrane, supplied with nervous filaments from both the olfactory and the fifth pair, may open into these canals. They are called, after their discoverer, the "*organs of Jacobson*."

The *Eye* is formed by the coalescence of two sets of structures, one furnished by involution of the integument, the other by an outgrowth of the brain.

The opening of the integumentary depression which is primarily formed on each side of the head in the ocular region becomes closed, and a shut sac is the result. The outer wall of this sac becomes the transparent *cornea* of the eye; the epidermis of its floor thickens, and is metamorphosed into the *crystalline lens*; the cavity fills with the *aqueous* humour. A vascular and muscular ingrowth taking place round the circumference of the sac, and, dividing its cavity into two segments, gives rise to the *iris*. The integument around the cornea, growing out into a fold above and below, results in the formation of the eyelids, and the segregation of the integument which they inclose, as the soft and vascular *conjunctiva*. The pouch of the *conjunctiva* very generally communicates, by the *lachrymal duct*, with the cavity of the nose. It may be raised, on its inner side, into a broad fold, the *nictitating membrane*, moved by a proper muscle or muscles. Special glands—the *lachrymal* externally, and the *Harderian* on the inner side of the eyeball—may be developed in connection with, and pour their secretion on to, the conjunctival mucous membrane.

The posterior chamber of the eye has a totally distinct origin. Very early, that part of the anterior cerebral vesicle which eventually becomes the vesicle of the third ventricle, throws out a diverticulum, broad at its outer, and narrow at its inner end, which applies itself to the base of the integumentary sac. The posterior, or outer, wall of the diverticulum then becomes, as it were, thrust in, and forced towards the opposite wall, by an ingrowth of the adjacent

connective tissue; so that the primitive cavity of the diverticulum, which, of course, communicates freely with that of the anterior cerebral vesicle, is obliterated. The broad end of the diverticulum acquiring a spheroidal shape, while its pedicle narrows and elongates, the latter becomes the optic nerve, while the former, surrounding itself with a strong fibrous *sclerotic* coat, remains as the posterior chamber of the eye. The double envelope, resulting from the folding of the wall of the cerebral optic vesicle upon itself, gives rise to the *retina* and the *choroid* coat: the plug, or ingrowth of connective tissue, gelatinises and passes into the *vitreous humour*, the cleft by which it entered becoming obliterated.

Even in the higher *Vertebrata* the optic nerve is, at first, connected exclusively with the vesicle of the third ventricle, and makes no decussation with its fellow. But by degrees the roots of origin of each nerve extend over to the opposite side of the brain, and round the thalamus, to the mesencephalon on that side, and the trunks of the two nerves become intermixed below the third ventricle, in a close and complicated manner, to form a *chiasma*.

In *Amphioxus* and *Myxine*, the eyes are very imperfectly developed, appearing to consist of little more than a rudimentary lens imbedded in the pigment, which encloses the termination of the optic nerve; and in *Myxine*, this rudimentary eye is hidden by muscles and integument. It appears doubtful whether in these fishes, and in the Lampreys, the eye is developed in the same way as in other *Vertebrata*.

In all other *Vertebrata*, the eyes have the typical structure, though sometimes, as in the Blind-fish (*Amblyopsis*) and the Mole, they have no functional importance. In the *Ichthyopsida* and *Sauropsida*, but not in *Mammalia*, the sclerotic is often partially ossified, the ossification usually forming a ring around its anterior moiety. It becomes enormously thickened in the *Cetacea*.

Except in *Amphioxus* and the Myxinoid fishes, the eyeball is moved by six muscles; of these, four, proceeding from the interior of the orbit to the periphery of the eye-

ball, and surrounding the optic nerve, are termed superior, inferior, internal, and external *recti*. The other two are connected with the upper and the lower margins of the orbit respectively, and pass thence to the outer side of the bulb. These are the *superior* and the *inferior obliqui*. In many Reptiles and Mammals a continuous funnel-shaped sheet of muscle, the *musculus choanoides*, lies within the four *recti*, and is attached to the circumference of the posterior moiety of the ball of the eye. It would appear, from the distribution of the nerves, which has already been described, that the *musculus choanoides*, the external *rectus*, and the nictitating muscle, constitute a group of eye-muscles morphologically distinct from the other three *recti*, the *obliqui*, and the *levator palpebræ superioris*. In many Reptiles, and in the higher *Vertebrata*, the eyelids are closed by circular muscular fibres, constituting an *orbicularis palpebrarum*, and are separated by straight fibres proceeding from the back of the orbit, usually to the upper eyelid only, as the *levator palpebræ superioris*; but sometimes to both lids, when the lower muscle is a *depressor palpebræ inferioris*.

The Harderian and lachrymal glands are not found in fishes; but the former is met with in the *Batrachia*, and both are of common occurrence in the *Sauropsida* and *Mammalia*.

In *Lacertilia*, *Crocodylia*, *Aves*, and many Fishes, a peculiar vascular membrane, covered with pigment, like the choroid, projects from near the entrance of the optic nerve, on the outer side of the globe of the eye, into the vitreous humour, and usually becomes connected with the capsule of the lens. This is the *pecten*, or *marsupium*.

The Ear.—The first rudiment of the internal ear is an involution of the integument into a small sac, which is situated on each side of the posterior cerebral vesicle, just above the end of the second visceral cleft. The mouth of the involution soon closes, and a shut sac results. The sac enlarges, and, by a remarkable series of changes, its upper part becomes (ordinarily) converted into three *semicircular*

canals—the *anterior* and *posterior vertical*, and the *external* or *horizontal canals* of the *membranous labyrinth*. The body of the sac remains, for the most part, as the *vestibule*; but a cæcal process, which eventually becomes shut off from the vestibule, is given off downwards and inwards, towards the base of the skull, and is the rudiment of the *scala media* of the *cochlea*. This may be called the *membranous cochlea*.

In the anomalous vertebrate, *Amphioxus*, no ear has yet been discovered. The Hag (*Myxine*) has only one, and in the Lampreys (*Petromyzon*) there are only two, semicircular canals; but, in fishes in general, all three are developed, and it is a question whether the cochlea is not also represented.

In fishes, the periotic cartilage and its ossifications inclose this membranous labyrinth, externally, and present no merely membranous gaps, or *fenestræ*, towards the first visceral cleft, or the space which represents it.

But in higher *Vertebrata* (*Amphibia*, *Sauropsida*, *Mammalia*), in which the membranous labyrinth is always inclosed within a complete bony periotic capsule, the outer wall of this capsule invariably remains unossified over one or two small oval arææ, which consequently appear like windows with membranous panes, and are termed the *fenestra ovalis* and the *fenestra rotunda*.

The *fenestra ovalis* is situated in that part of the periotic mass which bounds the chamber containing the membranous vestibule externally; and it is always found that when both the pro-otic and the opisthotic bones exist, they contribute nearly equal shares to the formation of its boundaries. In fact, the *fenestra ovalis* is situated in the line of junction of these two bones. The *fenestra rotunda*, on the other hand, is below the *fenestra ovalis*, and lies altogether in the opisthotic. It forms part of the outer wall of the cavity in which the membranous cochlea is lodged.

In the *Sauropsida* and *Mammalia*, this membranous cochlea, become flattened and bandlike, and its communication with the vestibule obliterated, is lodged in a conical cavity, in such a manner as to divide that cavity into two

portions, called *scalæ*, which only communicate at their apices. The base of the one *scala*, called *scala vestibuli*, opens into the cavity which contains the membranous vestibule: that of the other, *scala tympani*, abuts against, and is as it were stopped by, the membrane of the fenestra rotunda. The cavity of the membranous cochlea stretched between, and helping to divide, these two *scalæ*, is called the *scala media*.

In Reptiles, Birds, and Ornithodelphous Mammals, the cochlea is only slightly bent or twisted upon itself. But, in the higher *Mammalia*, it becomes coiled in a flat or conical spiral of one-and-a-half (*Cetacea*, *Erinaceus*) to five (*Cælogenyx Paca*) turns.

The membranous labyrinth is filled with a clear fluid, the *endolymph*, and usually contains otolithes of various kinds. Between the membranous labyrinth and the walls of the cavity of the periotic mass in which it is contained, lies another clear fluid, the *perilymph*, which extends thence into the *scalæ vestibuli* and *tympani*.

In all animals which possess a *fenestra ovalis*, its membrane gives attachment to a disc, whence an ossified rod, or arch, proceeds. Where the former structure obtains, as in Birds, most Reptiles, and some *Amphibia*, the bone is commonly called *columella auris*; when the latter, as in most Mammals, *stapes*. But there is really no difference of importance between *stapes* and *columella*, and it is advisable to use the former name for the bone under all its forms.

In the majority of *Vertebrata* of higher organization than fishes, the first visceral cleft does not become wholly obliterated, but its upper part remains as a transversely elongated cavity, by means of which the pharynx would be placed in communication with the exterior, were it not that the opposite sides of the canal grow together into a membranous partition—the *membrana tympani*. So much of the canal as lies external to this is the external *auditory meatus*; while what lies internal to it, is the *tympanum*, or drum of the ear, and the *Eustachian tube*, which places the *tympanum* in communication with the pharynx. While the outer

wall of the tympanum is the tympanic membrane, its inner wall is the periotic mass with its *fenestræ*; and, in all *Vertebrata* below Mammals, the outer end of the *stapes* is either free, or, more commonly, is fixed to the tympanic membrane, and thus the latter and the membrane of the *fenestra ovalis* become mechanically connected. In all these animals the mandible is connected with the skull by the intermediation of an *os quadratum*.

But, in the *Mammalia*, the mandible is articulated directly with the squamosal, and the *quadratum* is converted into one of the so-called *ossicula auditûs*, and named the *malleus*. The malleus becomes attached to the *membrana tympani*, by a special process; while its other extremity, which was continuous with Meckel's cartilage in the embryo, is converted into the *processus gracilis*, or *Folianus*, and lies between the tympanic, the squamosal, and the periotic bones.

In the singular lizard *Sphenodon* (A, Fig. 24), the anterior cornu of the hyoid is continuous with the distal end of the *stapes*, and the latter sends a cartilaginous process upwards, which passes into the wall of the periotic capsule, just behind the proximal end of the *os quadratum*. Thus the *stapes* stands out at right angles to the hyoid cornu, and the latter becomes divisible into a *supra-stapedial* part, and a part which lies below the *stapes*, and answers to the styloid process, or *stylohyal*, of the *Mammalia*. The supra-stapedial part is represented by cartilage, or ligament, in other *Sauropsida*, but seems not to ossify. In the *Mammalia* (B, Fig. 24) the supra-stapedial part ossifies, becomes the *incus*, and its proximal end is usually articulated by a synovial joint with the *malleus* (= *quadratum*). A distinct ossification, the *os orbiculare*, usually arises at that part of the hyoidean cartilage in which the *stapes* and the *incus* unite. That part of the hyoidean cartilage which is converted into the styloid process is generally connected with the *orbiculare* by muscular fibres, which constitute the *stapedius* muscle. On the other hand, the posterior, or short process of the *incus*, is connected by ligament with that part of the periotic mass into which the styloid process is directly continued, and it

is hard to say whether the styloid part of the hyoid is continued into the incus by these ligaments or by the *stapedius*. But, however this may be, the *malleus* and the *incus* are the proximal ends of the mandibular and hyoidean arches respectively.

In osseous fishes (C, Fig. 24), which have no fenestra ovalis or stapes, the supra-stapedial part of the hyoid becomes a large bone—the *hyomandibular*. On the other hand, the proximal extremity of the quadrate cartilage atrophies, loses

Fig. 24.

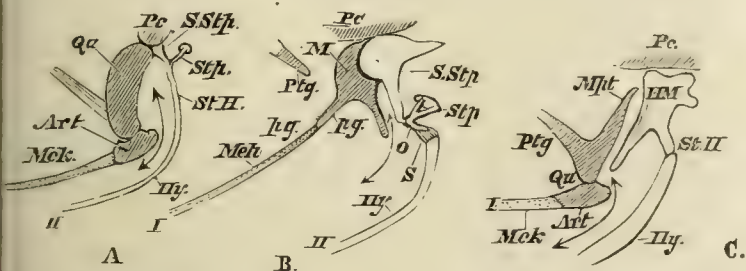


Fig. 24.—Diagram of the skeleton of the first and second visceral arches in a Lizard (A), a Mammal (B), and an Osseous Fish (C). The skeleton of the first visceral arch is shaded, that of the second is left nearly unshaded. I. First visceral arch. Mck. Meckel's cartilage. Art. Articular. Qu. Quadratum. Mpt. Metapterygoid; M. Malleus; p.g., Processus gracilis. II. Second visceral arch. Hy. Hyoidean cornu. St. H. Stylohyal. S. Stapedius. Stp. Stapes. S. Stp. Supra-stapedial. HM. Hyomandibular. The arrow indicates the first visceral cleft. Pc. The periotic capsule. Ptg. The pterygoid.

its direct connection with the periotic capsule, and becomes distinctly ossified, as the *metapterygoid*. In the Sharks, even the ascending, metapterygoid, part of the quadrate, is lost.

The quadrate and supra-stapedial portions of the first and second visceral arches coalesce in the *Chimæra*, *Dipnoi*, and many *Amphibia*, into a single cartilaginous plate.

In the *Mammalia*, and to some extent in *Aves*, osseous matter is deposited in the fibrous tissue which surrounds the sides and base of the tympanic membrane, and gives rise to a special *tympanic* bone. In most *Mammalia*, ossifi-

cation extends into the sides and floor of the tympanum and external meatus; and a process of integument, chiefly derived from the second visceral arch, is converted into a *concha*, or *external ear*.

The *Organ of Taste* is the mucous membrane which covers the tongue, especially its posterior region, and probably also a part of that lining the fauces. When the sense is well developed, the mucous membrane is raised into numerous papillæ of various forms, and is well supplied with filaments from the glossopharyngeal nerve.

The sense of *Touch* is diffused over the integument and over the mucous membrane of the buccal cavity, which is, strictly speaking, a part of the integument.

As special organs of touch in the higher *Vertebrata*, the nervous papillæ, containing "*tactile corpuscles*," and the long facial hairs, the papillæ of which are well supplied with nerves, termed *vibrissæ*, may be mentioned.

In most, if not all Fishes, the integument of the body and of the head contains a series of sacs, or canals, usually disposed symmetrically on each side of the middle line, and filled with a clear gelatinous substance. The walls of the sacs, or canals, are abundantly supplied with nerves, and the terminations of the latter enter rounded papillæ, which project into the gelatinous contents. These sensory organs are known as the "*organs of the lateral line*," or "*mucous canals*;" and they were formerly supposed to be the secretory glands of the slimy matter which coats the bodies of fishes, and which is really modified epidermis.

The Alimentary Canal.—This part of vertebrate organization always exhibits a differentiation into mouth, pharynx, œsophagus, stomach, and intestine; and the last has always a median, or nearly median, aperture on the ventral surface of the body. It may open by itself; or into a *cloaca*, or chamber common to it, the urinary, and the genital organs.

The intestine is generally distinguishable into *small* and *large*; and, at the junction of the two, one or two *cæca* are frequently developed from the former.

The stomach and intestine are invested by a peritoneal membrane, and connected, by *mesogastric* and *mesenteric* folds of that membrane, with the median dorsal wall of the abdominal cavity. Glands appertaining to the lymphatic system frequently abound in the mesenteric folds, and a highly vascular gland of this system, the *spleen*, is always (except in *Amphioxus*, *Myxine*, and the *Leptocephali*) developed in close proximity to the stomach. A *pancreatic* gland very generally pours its secretion into the anterior end of the intestine. *Salivary glands* very commonly open into the mouth; and, in the higher *Vertebrata*, *anal glands* are not unusually developed in connection with the termination of the rectum.

The structures connected with the alimentary canal of vertebrate animals, which are most characteristic and peculiar, are the liver and the teeth.

The Liver.—In invertebrate animals this organ is always ultimately resolvable into cæcal tubes, the ends of the hepatic ducts, which are lined with an epithelium, and not reticulated; and it has no receptacle for the bile. In most *Vertebrata* the ends of the hepatic ducts have not been satisfactorily traced, nor is it certain that the immense proportional mass of hepatic corpuscles is contained in tubes continuous with them: if such be the case, the tubes must be reticulated. The ducts of the vertebrate liver very frequently pour the bile, directly or indirectly, into a receptacle, the *gall-bladder*. *Amphioxus* stands alone among vertebrated animals, in having a cæcal diverticulum of the intestine for a liver.

The Teeth.—Teeth, in *Mollusca* and *Annulosa*, are always “*ecderonic*,” cuticular, or epithelial structures. In *Vertebrata* true teeth are invariably “*enderonic*,” or developed, not from the epithelium of the mucous membrane of the alimentary canal, but from a layer between this and the vascular deep substance of the enderon, which answers to the dermis in the integument. The horny “teeth” of the Lampreys, and of *Ornithorhynchus*, appear to be *ecderonic*

structures, homologous with the "*baleen*" of the *Cetacea*, with the palatal plates of the *Sirenia*, or the beaks of Birds and Reptiles, and not with true teeth.

The dense calcified tissue called *dentine*, characterised by the close-set parallel tubuli which radiate through it, branching as they go, constitutes the chief mass of true teeth; but the dentine may be coated with ordinary bony tissue, which then receives the name of *cementum*, and its crown may be capped with imperforate, prismatically fibrous, *enamel*.

The teeth are moulded upon papillæ of the mucous membrane, which may be exposed, but are more usually sunk in a fold or pit, the roof of which may close in so as to form a *dental sac*. And there may be one set of teeth, or several; the sacs of the new teeth, in the latter case, being developed either as diverticula of the old ones, or independently of them.

In the majority of the *Mammalia* the teeth are limited in number, as well as definite in their forms and their mode of succession. There are two sets of teeth, forming a first, *deciduous*, or *milk dentition*, and a second, or *permanent dentition*. The deciduous dentition, when most completely developed, consists of *incisor*, *canine*, and *molar* teeth. The incisors are distinguished from the rest by the lodgment of the upper set in the premaxillæ, and the correspondence of the lower set with the upper. Their number and form vary. The distinction between canines and molars is one of form and position in regard to the remaining teeth; the most anterior of the teeth behind the premaxillo-maxillary suture, if it is sharp and projecting, receiving the name of canine. There are never more than four canines. The other teeth are molars, and ordinarily do not exceed four upon each side, above and below. What is called a *dental formula* is a convenient combination of letters and figures for making the number and disposition of the teeth obvious. Thus, let *di*, *dc*, *dm* represent, respectively, the deciduous, or milk set of incisors, canines, and molars. Then, by placing after each of these symbols figures arranged so as to show the number of the

teeth of the kind symbolised, on each side of each jaw, we shall have the dental formula of a given animal. The dental formula of a child over two years of age is thus—
 $di. \frac{2\cdot2}{2\cdot2} \quad dc. \frac{1-1}{1-1} \quad dm. \frac{2\cdot2}{2\cdot2} = 20$: which means that the child should have two incisors, one canine, and two molars on each side of each jaw.

The neck of the sac of each deciduous tooth gives off a diverticulum, in which one of the permanent teeth is developed; as it grows, it causes the absorption of the fang of the corresponding deciduous tooth, which thus becomes shed, and is replaced from below by the permanent tooth. The same letters, but without the prefix *d*, are used for the permanent incisors and canines; but the permanent teeth, which replace the deciduous molars, are called *premolars*, and have the symbol *pm*. Furthermore, three or, it may be, four permanent grinding teeth, on each side of each jaw, are developed altogether behind the milk molars, and thus come into place without replacing any other tooth from below. These are called *molars*, and have the symbol *m*. Thus the formula of the permanent dentition in Man is written:

$$i. \frac{2\cdot2}{2\cdot2} \quad c. \frac{1-1}{1-1} \quad pm. \frac{2\cdot2}{2\cdot2} \quad m. \frac{3\cdot3}{3\cdot3} = 32$$
; there being two incisors,

one canine, two premolars, and three molars on each side above and below. It is a rule of very general application among the *Mammalia*, that the most anterior molar comes into place and use before the deciduous molars are shed. Hence, when the hindermost premolar, which immediately precedes the first molar, comes into use by the shedding of the last milk molar, the crown of the first molar is already a little ground down; and this excess of wear of the first molar over the adjacent premolar long remains obvious. The fact that, in the permanent dentition, the last premolar is less worn than the first molar which immediately follows it, is often a valuable aid in distinguishing the premolar from the molar series.

No vertebrate animal has teeth in any part of the alimentary canal save the mouth and pharynx—except a

snake (*Rachiodon*), which has a series of what must be termed teeth, formed by the projection of the inferior spinous processes of numerous anterior vertebræ into the œsophagus. And, in the highest *Vertebrata*, teeth are confined to the premaxillæ, maxillæ, and mandible.

The Circulatory Organs.—The heart of the vertebrate embryo is at first a simple tube, the anterior end of which passes into a cardiac aortic trunk, while the posterior end is continuous with the great veins which bring back blood from the umbilical vesicle—the *omphalomeseraic veins*.

The *cardiac aorta* immediately divides into two branches, each of which ascends, in the first visceral arch, in the form of a forwardly convex *aortic arch*, to the under side of the rudimentary spinal column, and then runs, parallel with its fellow, to the hinder part of the body, as a *primitive subvertebral aorta*. The two primitive aortæ very soon coalesce throughout the greater part of their length into one trunk, the *definitive subvertebral aorta*; but the aortic arches, separated by the alimentary tract, remain distinct. Additional arterial trunks, to the number of four in the higher *Vertebrata*, and more in the lower, are successively developed, behind the first, in the other visceral arches, and further connect the cardiac and subvertebral aortæ.

In the permanently branchiate *Vertebrata*, the majority of these aortic arches persist, giving off vessels to the branchial tufts, and becoming converted into afferent and efferent trunks, which carry the blood to and take it from these tufts. (Fig. 25, A, B, C, D, E.)

In the higher *Amphibia*, which, though branchiate in the young state, become entirely air-breathers in the adult condition, such as the *Batrachia* (Fig. 25, F) and *Cœcilia*, the permeable aortic arches are reduced to two (the middle pair of the three which supply the external gills, and the fourth pair of embryonic aortic arches) by the obliteration of the cavities of the dorsal ends of the others. Of the posterior arches, the remains of the fifth and sixth become the trunks which give off the pulmonary arteries, and, in the *Batrachia*,

Fig. 25.

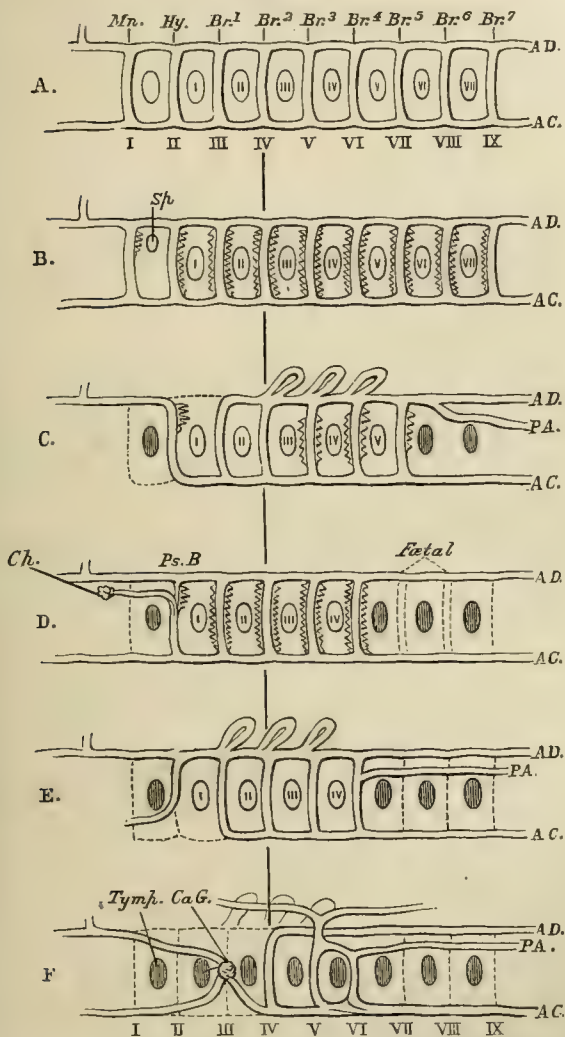


Fig. 25.—A diagram intended to show the manner in which the aortic arches become modified in the series of the *Vertebrata*.

A. A hypothetically perfect series of aortic arches, corresponding with the nine postoral visceral arches, of which evidence is to be found in some Sharks and *Marsipobranchii*. A.C. Cardiac aorta; A.D. Dorsal

or subvertebral aorta. I.—IX. the aortic arches, corresponding with *Mn.*, the mandibular; *Hy.*, the hyoidean, and *Br.* 1—*Br.* 7, the seven branchial visceral arches. I. II. III. IV. V. VI. VII., the seven branchial clefts. The first visceral cleft is left unnumbered, and one must be added to the number of each branchial cleft to give its number in the series of visceral clefts.

- B. Hypothetical diagram of the aortic arches in the Shark *Heptanchus*, which has seven branchial clefts. *Sp.* The remains of the first visceral cleft as the spiracle. Branchiæ are developed on all the arches.
- C. *Lepidosiren*.—The first arch has disappeared as such, and the first visceral cleft is obliterated. Internal branchiæ are developed in connection with the second, fifth, sixth, and seventh aortic arches; external branchiæ in connection with the fourth, fifth, and sixth. *P.A.* the pulmonary artery. The posterior two visceral clefts are obliterated.
- D. A Teleostean Fish.—The first aortic arch and first visceral cleft are obliterated, as before. The second aortic arch bears the pseudo-branchia (*Ps.B.*), whence issues the ophthalmic artery, to terminate in the choroid gland (*Ch.*) The next four arches bear gills. The seventh and eighth arches have been observed in the embryo, but not the ninth, and the included clefts are absent in the adult.
- E. The Axolotl (*Siredon*), a perennibranchiate amphibian. The third, fourth, fifth, and sixth aortic arches, and the anterior four branchial clefts, persist. The first visceral cleft is obliterated.
- F. The Frog.—The three anterior aortic arches are obliterated in the adult. The place of the third, which is connected with the anterior external gill in the Tadpole, is occupied by the common carotid and the *rete mirabile* (carotid gland, *Ca.G.*) which terminates it. The fourth pair of aortic arches persist. The fifth and sixth pair lose their connections with the subvertebral aortic trunk, and become the roots of the cutaneous and pulmonary arteries. The first visceral cleft becomes the tympanum, but all the others are obliterated in the adult.

cutaneous branches. The anterior, or third, primitive aortic arch becomes the common carotid trunk, and ends in the *carotid gland*, whence the internal and external carotids arise. In those *Vertebrata* which never possess gills, the arches become reduced either to two pair, as in some *Lacertilia*; or to one pair, as in other *Reptilia*; or to a single arch, as in *Aves* and *Mammalia*. The aortic arches thus retained are, in the Lizards in question, the third and the fourth pairs in order from before backwards; but the fourth pair only, in other Reptiles; in Birds, the right arch only of the fourth pair; and in Mammals, the left arch only of the fourth pair. The fifth pair of arches give off the pulmonary arteries, the so-called "*ductus arteriosus*" repre-

sending the remains of the primitive connection of these arches with the fourth pair and the subvertebral aorta. The dorsal ends of the first, second, and third arches become obliterated; but their cardiac ends, and the branches which they give off, become the arteries of the head and upper extremities.

The embryonic aorta gives off *omphalomeseraic* branches (Fig. 26, *o*) to the umbilical vesicle; and ends, at first, in the *hypogastric* arteries (which are distributed to the allantois in the abranchiate *Vertebrata*), and a median caudal continuation. The blood from the umbilical vesicle is brought back, as before mentioned, by the omphalomeseraic veins (Fig. 26, *o'*), which unite in a dilatation close to the head; the dilatation (*sinus venosus*) receives, on each side, a short transverse venous trunk, the *ductus Cuvieri* (Fig. 26, *DC.*), which is itself formed, upon each side, by the junction of the *anterior* and *posterior cardinal veins*, which run backwards and forwards, parallel with the spine, and bring back the blood of the head and of the trunk.

The blood of the allantois is returned by the *umbilical vein*, or veins (Fig. 26, *u'*), which are formed in the anterior wall of the abdomen, and open into the venous sinus before mentioned. The blood of the posterior extremities and kidneys is, after a while, brought to the same point by a special median vein, the *vena cava inferior* (Fig. 26, *cv.*).

The development of the liver effects the first great change in the arrangements now described. It, as it were, interrupts the course of the omphalomeseraic vein, which is not only the vein of the umbilical sac but also that of the intestine, and converts it into a meshwork of canals, which communicate, on one side, with the cardiac part of the vein, and, on the other side, with its intestinal part. The latter is thus converted into the *vena portæ* (Fig. 26, *vp.*), distributing the blood of the stomach and intestines to the liver; while the former becomes the *hepatic vein* (*vh*), carrying the hepatic blood to the inferior cava, and thence to the heart.

The umbilical vein further gives a branch to the liver; while, on the other hand, it communicates directly with the venous sinus (now almost merged in the *vena cava inferior*) by a trunk called *ductus venosus* (Fig. 26, *Dv.*).

Fig. 26.

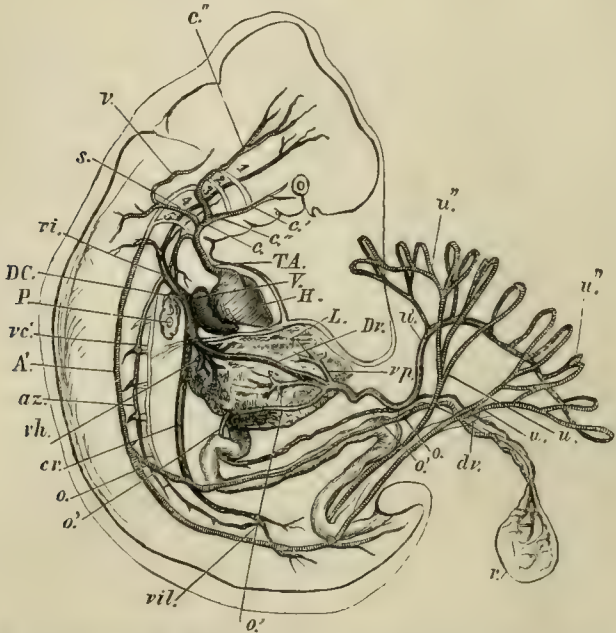


Fig. 26.—Diagram of the arrangement of the principal vessels in a human foetus. *H.* the heart; *T.A.* the aortic trunk or cardiac aorta; *c.* the common carotid; *c'* the external carotid; *c''* the internal carotid; *s.* subclavian; *v.* vertebral artery; 1, 2, 3, 4, 5, the aortic arches—the persistent *left* aortic arch is hidden; *A'* subvertebral aorta; *o.* omphalomeseraic artery, going to the umbilical vesicle *v.* with its vitelline duct *dv.*; *o.* omphalomeseraic vein; *vp.* the vena portae; *L.* the liver; *uu.* the hypogastric or umbilical arteries, with their placental ramifications, *u'u'*; *u'* the umbilical vein; *Dv.* the ductus venosus; *vh.* the hepatic vein; *vc.* the vena cava inferior; *vil.* the iliac veins; *az.* a vena azygos; *vc'* a vena cardinalis posterior; *DC.* a ductus Cuvieri; the anterior cardinal vein is seen commencing in the head and running down to the ductus Cuvieri on the under side of the numbers 1, 2, 3, 4, 5; *P.* the lungs.

When the umbilical vesicle and allantois cease to have any further import, as at birth, or before, the omphalomeseraic

arteries have become intestinal arteries, and the omphalo-meseraic vein, the vena portæ. The hypogastric arteries are obliterated, except so much of them as is converted into the common iliac arteries. The umbilical vein, or veins, also disappear, or are represented by mere ligaments.

Of the three veins which open into the venous sac—viz., the inferior cava, and the right and left *ductus Cuvieri*,—all may persist, the latter receiving the title of right and left *superior cavæ*. Or, as very often happens in the higher *Vertebrata*, the left *ductus Cuvieri* becomes more or less obliterated; the veins which properly open into it acquiring a connection with the right *ductus*, which then remains as the sole *superior cava*. The posterior cardinal veins give off anastomosing branches, which are converted into the *venæ azygos*; the anterior cardinal veins become metamorphosed into the external jugular veins and *venæ innominatæ*.

In Fishes, the *sinus venosus* and the cardinal veins persist throughout life; but the anterior cardinal veins, which bring back the blood from the head and from the anterior extremities, are called *venæ jugulares*.

The caudal veins are either directly continued into the cardinal veins, as in *Marsipobranchii* and *Elasmobranchii*, or branch out into the kidneys, as in many *Teleostei*. In either case the efferent renal veins open into the cardinal veins.

The portal veins, conveying the blood of the chylopoietic viscera, and sometimes that of other organs and of the abdominal walls, may be one or many. In *Amphioxus* and *Myxine* the vein is rhythmically contractile, and forms a portal heart.

In most *Amphibia* and *Reptilia* the *sinus venosus* persists, and is rhythmically contractile, valves being placed at its opening into the right auricle.

The anterior cardinal veins are represented by jugular veins, the posterior cardinal by vertebral veins; these, and the veins of the anterior extremities, when they are present, pour their blood into the *ductus Cuvieri*, which are now termed *anterior venæ cavæ*.

The *vena cava inferior* takes its origin chiefly by the

coalescence of the efferent veins of the kidneys and reproductive organs, and does not always receive the whole of the hepatic veins—more or fewer of the latter opening independently into the *sinus venosus*.

The blood which leaves the kidneys by its efferent veins is supplied, not only by the renal arteries, but by the veins of the caudal region, and of the hinder extremities, which branch out like a *vena portæ* in the substance of the kidneys. This renal portal system is less developed in *Reptilia* than in *Amphibia*. All the blood of the posterior extremities and caudal region does not traverse the kidneys, however, more or less of it being led away by great branches of the iliac veins, which run along the anterior wall of the abdominal cavity, either as two trunks, or united into one. These *venæ abdominales anteriores* are eventually distributed to the liver, along with the branches of the proper *vena portæ*.

In *Birds*, the *sinus venosus* is not distinct from the right auricle, and there are two anterior *venæ cavæ*. The *vena cava inferior* arises, as in Mammals, by the union of the two common iliac veins. It receives both the right and the left hepatic veins, and, in addition, the anterior abdominal vein no longer enters the portal system, but passes up the anterior wall of the abdomen and through the hepatic fissure to join the inferior cava.

The caudal and pelvic veins unite into three principal trunks, of which one is median and two are lateral. The median enters into the portal system. The lateral branches pass along and through the kidney, receiving veins from it, but giving none to it; and eventually, after receiving the ischiatic veins, unite with the crural veins to form the common iliacs. Thus there is no renal portal system in birds.

In *Mammalia*, the *sinus venosus* is not distinct from the right auricle. The *anterior cavæ* are frequently reduced to one, the right. The *vena cava inferior* commences in the caudal region, and receives all the blood of the posterior moiety of the body, except so much as is carried away by the azygous veins. The anterior abdominal veins are repre-

sented only during fœtal life, by the umbilical vein or veins. The efferent veins of the kidneys open directly into the trunk of the inferior vena cava, and the portal vein is composed exclusively of radicles proceeding from the chylopoietic viscera.

Many of the veins of *Amphioxus*, the portal vein of *Myxine*, dilatations of the caudal vein in the Eel, the venæ cavæ and the iliac and axillary veins of many *Amphibia*, the veins of the wing of Bats, possess a rhythmical contractility, which, in combination with the disposition of their valves, assists the circulation of the blood.

In *Vertebrata* of all classes, and in very diverse parts of the body, both veins and arteries occasionally break up into numerous branches of nearly equal size, which may or may not unite again into larger trunks. These are called *retia mirabilia*.

Modifications of the Heart.—Great changes go on in the structure of the heart, *pari passu* with the modifications of the rest of the circulatory system, in the development of the highest *Vertebrata*. The primitively simple tube becomes bent upon itself, and divided from before backwards into an aortic, or *ventricular*, and a venous, or *auricular*, portion. A median septum then grows inward, dividing the auricular and ventricular chambers into two, so that a right auricle and right ventricle become separated from a left auricle and left ventricle. A similar longitudinal division is effected in the cardiac aorta. The septa are so disposed in the auriculo-ventricular chamber that the right auricle communicates with the venous sac and the trunks of the visceral and body veins, while only the veins from the lungs enter into the left auricle. And the cardiac aorta is so divided that the left ventricle communicates with the chief aortic trunk, the right with the pulmonary artery. Valves are developed at the auriculo-ventricular apertures and at the origins of the aortic and pulmonary trunks, and thus the course of the circulation is determined. The septum between the auricles remains incomplete for a

much longer period than that between the ventricles—and the aperture by which the auricles communicate is called the *foramen ovale*.

In the adult state of *Aves* and *Mammalia*, the foramen ovale is closed; there is no direct communication between the arterial and venous cavities or trunks; there is only one aortic arch; and the pulmonary artery alone arises from the right ventricle. In the *Crocodylia*, the auricles and ventricles of opposite sides are completely separate; but there are two aortic arches, and one of these, the left, arises from the right ventricle along with the pulmonary artery. In all *Reptilia*, except Crocodiles, there is but one ventricular cavity, though it may be divided more or less distinctly into a *cavum venosum* and a *cavum arteriosum*. The auricles are completely separated (except in some *Chelonia*), and the blood of the left auricle flows directly into the *cavum arteriosum*, while that of the right passes immediately into the *cavum venosum*. The aortic arches and the pulmonary artery all arise from the *cavum venosum* (or a special subdivision of that cavity called the *cavum pulmonale*); the ostium of the pulmonary artery being farthest from, and that of the right aortic arch nearest to, the *cavum arteriosum*.

In all *Amphibia*, the spongy interior of the ventricle is undivided, and the heart is trilocular, though the auricular septum is sometimes small and incomplete. In all *Pisces*, except *Lepidosiren*, there is no auricular septum. In *Amphioxus* the heart remains in its primitive state of a simple, contractile, undivided tube.

In the *Ganoidei*, the *Elasmobranchii*, and the *Amphibia*, the walls of the enlarged commencement of the cardiac aorta, called the *bulbus aortæ*, contain striped muscular fibre, and are rhythmically contractile.

The *Ganoidei* and *Elasmobranchii* possess, not merely the ordinary semilunar valves, at the junction between the ventricle and the cardiac aorta, but a variable number of additional valves, set, in transverse rows, upon the inner wall of the aortic bulb.

The change of position which the heart and the great

vessels of the highest *Vertebrata* undergo during embryonic life is exceedingly remarkable, and is repeated as we ascend in the series of adult vertebrates.

At first, the heart of a mammal lies under the middle of the head, immediately behind the first visceral arches, in which the first pair of aortic arches ascend. As the other pairs of aortic arches are developed the heart moves backward; but the fourth pair of aortic arches, by the modification of one of which the persistent aorta is formed, lies, at first, no farther back than the occipital region of the skull, to which, as we have seen above, the fourth pair of visceral arches belongs. As the two pairs of cornua of the hyoid belong to the second and the third visceral arches, the larynx is probably developed within the region of the fourth and fifth visceral arches; hence, the branches of the pneumogastric, with which it is supplied, must, originally, pass directly to their destination. But, as development proceeds, the aortic arches and the heart become altogether detached from the visceral arches and move back, until, at length, they are lodged deep in the thorax. Hence the elongation of the carotid arteries; hence also, as the larynx remains relatively stationary, the singular course, in the adult, of that branch of the pneumogastric, the *recurrent laryngeal*, which primitively passed to the laryngeal region behind the fourth aortic arch, and consequently becomes drawn out into a long loop—the middle of it being, as it were, pulled back, by the retrogression of the aortic arch into the thorax.

The Blood Corpuscles.—Corpuscles are contained in the blood of all *Vertebrata*. In *Amphioxus* they are all of one kind, colourless and nucleated. The genus *Leptocephalus*, among the *Teleostei*, is said to possess the same peculiarity; but in all other known *Vertebrata*, the blood contains corpuscles of two kinds.

In *Ichthyopsida* and *Sauropsida*, both kinds are nucleated; but one set are colourless, and exhibit amœboid movements, while the others are red, and do not display

contractility. Except in the *Marsipobranchii*, which have round blood-corpuscles, the red corpuscles are oval. They attain a larger size in the perennibranchiate *Amphibia* than in any other Vertebrates.

In *Mammalia*, the blood-corpuscles are also of two kinds, colourless and red, the colourless possessing, and the red being devoid of, nuclei. It is but very rarely that a nucleated corpuscle, with a red colour especially developed about the nucleus, is seen in Mammalian blood; but such cases do occur; and, from this and other circumstances, it is probable that the Mammalian red corpuscle is a free-coloured nucleus.

The colourless corpuscles of *Mammalia* are spheroidal, and exhibit amæboid movements; the red corpuscles are flattened, usually circular, but sometimes oval (*Camelidæ*) discs, devoid of contractility.

The Lymphatic System.—This system of vessels consists, chiefly, of one or two principal trunks, the *thoracic duct*, or *ducts*, which underlie the vertebral column, and communicate, anteriorly, with the superior venæ cavæ, or with the veins which open into them.

From these trunks, branches are given off, which ramify through all parts of the body, except the bulb of the eye, the cartilages, and the bones. In the higher *Vertebrata*, the larger branches are like small veins, provided with definite coats, and with valves opening towards the larger trunks, while their terminal ramifications form a capillary network; but, in the lower Vertebrates, the lymphatic channels assume the form of large and irregular sinuses, which not unfrequently completely surround the great vessels of the blood system.

The lymphatics open into other parts of the venous system besides the affluents of the superior cavæ. In Fishes there are, usually, two caudal lymphatic sinuses which open into the commencement of the caudal vein. In the Frog, four such sinuses communicate with the veins, two in the coccygeal, and two in the scapular, region. The walls of

these sinuses are muscular, and contract rhythmically, so that they receive the name of *Lymphatic hearts*. The posterior pair of these hearts, or non-pulsating sinuses corresponding with them, are met with in *Reptilia* and *Aves*.

Accumulations of indifferent tissue in the walls of some of the lymphatic sinuses are to be met with in Fishes; but it is only in the *Crocodylia*, among *Reptilia*, that an accumulation of such tissue, traversed by lymphatic canals and bloodvessels, is apparent, as a *Lymphatic gland*, in the mesentery. Birds possess a few glands in the cervical region; and, in *Mammalia*, they are found, not only in the mesentery, but in many parts of the body.

The *Spleen* is substantially a lymphatic gland. The *Thymus*—a glandular mass with an internal cavity, but devoid of any duct—which is found in all *Vertebrata* except *Amphioxus*, appears to belong to the same category. It is developed in the neighbourhood of the primitive aortic arches, and is double in most of the lower *Vertebrata*, but single in *Mammalia*.

The nature of two other “ductless glands,” the *Thyroid gland* and the *Suprarenal capsules*, which occur very widely among the *Vertebrata*, is by no means well understood.

The thyroid gland is a single or multiple organ, formed of closed follicles, and is situated near the root of the aorta, or the great lingual, or cervical, vessels which issue from it.

The suprarenal capsules are follicular organs, often abundantly supplied with nerves, which appear to occur in Fishes, and are very constant in the higher *Vertebrata*, at the anterior ends of the true kidneys.

The *Lymph Corpuscles*, which float in the plasma of the lymphatic fluid, always resemble the colourless corpuscles of the blood.

The Respiratory Organs.—Vertebrated animals may possess either *branchiæ* for breathing the air contained in water, or *lungs* for atmospheric respiration; or they may possess both kinds of respiratory organs in combination.

Except in *Amphioxus*, the *branchiæ* are always lamellar, or filamentous, appendages of more or fewer of the visceral arches; being sometimes developed only on the proper branchial arches, sometimes extending to the hyoidean arch, or (as would appear to be the case with the spiracular *branchiæ* of some fishes) even to the mandibular arch. The *branchiæ* are always supplied with blood by the divisions of the cardiac aorta; and the different trunks which carry the aerated blood away, unite to form the subvertebral aorta, so that all vertebrated animals with exclusively branchial respiration have the heart filled with venous blood.

In the early life of many branchiated *Vertebrata*, the *branchiæ* project freely from the visceral arches to which they are attached, on the exterior of the body; and in some *Amphibia*, such as the Axolotl (*Siredon*), they retain their form of *external* plumelike appendages of the neck throughout life. But in the adult life of most Fishes, and in the more advanced condition of the Tadpoles of the higher *Amphibia*, the *branchiæ* are *internal*, being composed of shorter processes, or ridges, which do not project beyond the outer edges of the branchial clefts; and, generally, become covered by an operculum developed from the second visceral arch.

The *lungs* of vertebrated animals are sacs, capable of being filled with air, and developed from the ventral wall of the pharynx, with which they remain connected by a shorter or longer tube, the *trachea*, the division of this for each lung being a *bronchus*. Venous blood is conveyed to them directly from the heart by the pulmonary arteries, and some* or all of the blood which they receive goes back, no less directly, to the same organ by the pulmonary veins.

The vascular distribution thus described constitutes an essential part of the definition of a lung, as many fishes possess hollow sacs filled with air; and these sacs are developed, occasionally, from the ventral, though more commonly from the dorsal, wall of the pharynx, œsophagus, or

* Generally all, but in some of the blood supplied to the lungs enters the general circulation.

stomach. But such air-sacs—even when they remain permanently connected with the exterior by an open passage or *pneumatic duct*—are *air-bladders*, and not lungs, because they receive their blood from the adjacent arteries of the body, and not direct from the heart, while their efferent vessels are connected only with the veins of the general circulation.

The wall of each pulmonic air-sac is at first quite simple, but it soon becomes cellular by the sacculation of its parietes. In the lower pulmonated *Vertebrata*, the sacculation is more marked near the entrance of the bronchus; and when the lung-sac is long, as in many *Amphibia* and in Snakes, the walls of the posterior end may retain the smooth condition of the embryonic lung. In *Chelonia* and *Crocodylia*, the lung is completely cellular throughout, but the bronchi do not give off branches in the lungs. In Birds, branches are given off at right angles; and, from these, secondary branches, which lie parallel with one another, and eventually anastomose. In *Mammalia*, the bronchi divide dichotomously into finer and finer bronchial tubes, which end in sacculated air-cells.

Blind air-sacs are given off from the surfaces of the lungs in the *Chamæleonidæ*, and the principal bronchial tubes terminate in large air-sacs in *Aves*.

The Larynx and the Syrinx.—The trachea is commonly kept open by complete, or incomplete, rings of cartilage, and the uppermost of these undergo special modifications, which convert them into a *Larynx*, an organ which, under certain circumstances, becomes an instrument of voice.

When completely developed, the larynx presents a ring-like cartilage called *cricoid*, which lies at the summit of the trachea. With the anterior and dorsal edge of this, two *arytenoid* cartilages are moveably articulated, and a *thyroid* cartilage of a V-shape, open behind, is articulated moveably with its sides. Folds of the mucous membrane, containing elastic tissue, termed the *vocal cords*, stretch from the arytenoid cartilages to the re-entering angle of the thyroid cartilage, and between them lies a slit-like passage, the *glottis*. This is covered by a cartilage, the *epiglottis*, attached

to the re-entering angle of the thyroid, and to the base of the tongue. Folds of mucous membrane, extending from the epiglottis to the arytenoid cartilages, are the *aryepiglottic* ligaments. The inner surfaces of these end below in the *false vocal cords*, between which and the true *chordæ vocales*, lie recesses of the mucous membrane, the *ventricles* of the larynx.

The chief accessory cartilages are the *cartilages of Santorini*, attached to the summits of the arytenoid cartilages, and the *cartilages of Wisberg*, which lie within the aryepiglottic ligaments.

Birds possess a larynx in the ordinary position; but it is another apparatus, the *lower larynx* or *syrinx*, developed either at the end of the trachea, or at the commencement of each *bronchus*, which is their great vocal organ.

The Mechanism of Respiration.—The mechanism by which the aërating medium is renewed in these different respiratory organs is very various. Among branchiated *Vertebrata*, *Amphioxus* stands alone in having ciliated branchial organs, which form a network very similar to the perforated pharyngeal wall of the Ascidians. Most Fishes breathe by taking aërated water in at the mouth, and then shutting the oral aperture, and forcing the water through the branchial clefts, when it flows over the branchial filaments.

Pulmonated *Vertebrata* which have the thoracic skeleton incomplete (as the *Amphibia*), breathe by distending their pharyngeal cavity with air; and then, the mouth and nostrils being shut, pumping it, by the elevation of the hyoidean apparatus and floor of the pharynx, into the lungs. A Frog, therefore, cannot breathe properly if its mouth is kept wide open.

In most *Reptilia*, and in all *Aves* and *Mammalia*, the sternum and ribs are capable of moving in such a way, as alternately to increase and diminish the capacity of the thoracico-abdominal cavity, and thereby to give rise to an inspiratory and expiratory flow of air.

In the *Reptilia*, the elastic lungs dilate with the inspiratory, and contract with the expiratory, act; but in *Aves*, the air rushes through the principal bronchial passages of

the fixed and little distensible lungs, into the very dilatable and compressible air-sacs. From these the act of expiration expels it back through the principal bronchial passages to the trachea, and so out of the body.

Both in *Reptilia* (e. g. *Chelonia*) and in *Aves*, muscular fibres pass from the ribs to the surface of the lungs beneath the pleuroperitoneal membrane, and this rudimentary diaphragm acquires a very considerable development in the *Ratite*, or struthious birds. So far as the contraction of these fibres tends to remove the ventral from the dorsal walls of the lungs, they must assist inspiration. But this diaphragmatic inspiration remains far weaker than the sterno-costal inspiration.

Finally, in the *Mammalia*, there are two equally important respiratory pumps, the one sterno-costal, the other diaphragmatic. The *diaphragm*, though it makes its appearance in *Sauropsida*, only becomes a complete partition between the thorax and the abdomen in mammals; and as its form is such, that, in a state of rest, it is concave towards the abdominal cavity, and convex towards the thorax, the result of its contraction, and consequent flattening, necessarily is to increase the capacity of the thorax, and thus pump the air into the elastic lungs, which occupy a large part of the thoracic cavity. When the diaphragm ceases to contract, the elasticity of the lungs is sufficient to expel the air taken in.

Thus, mammals have two kinds of respiratory mechanism, either of which is efficient by itself, and may be carried on independently of the other.

The Renal Organs.—The higher *Vertebrata* are all provided with two sets of renal organs, the one existing only during the early foetal state, the other persisting throughout life.

The former are the *Wolffian bodies*, the latter the true *Kidneys*.

The *Wolffian bodies* make their appearance very early, on each side of the ventral aspect of the spinal region of the embryo, as small transversely-disposed tubuli, opening into

a duct which lies upon their outer side, and enters, posteriorly, into the base of the allantois, and thence into the primitive cloaca with which that structure is connected. The Wolffian duct is one of the first-formed structures in the embryo, and precedes the tubuli.

The *Kidneys* appear behind the Wolffian bodies, and, apparently, independently of them; their ducts, the *wreters*, are also distinct, but likewise terminate in the pelvic part of the allantois. Thus the urinary secretion passes into the allantois, and it is that portion of this organ which lies within the abdomen, and becomes shut off from the rest by the constriction and obliteration of the cavity of an intermediate part, and its conversion into the *urachus*, that gives rise to the *urinary bladder*. The ultimate secreting tubuli of both the Wolffian body and the kidney, are alike remarkable for ending in dilatations which embrace convoluted capillaries—the so-called *malpighian* tufts. Neither Wolffian bodies nor kidneys have been observed in *Amphioxus*. It is doubtful whether true kidneys are developed in *Ichthyopsida*, or whether the so-called kidneys of these animals are not, rather, persistent Wolffian bodies.

The Reproductive Organs.—These, in vertebrated animals, are primitively similar in both sexes, and arise on the inner side of the Wolffian bodies, and in front of the kidneys, in the abdominal cavity. In the female the organ becomes an *ovarium*. This, in some few fishes, sheds its ova as soon as they are ripened into the peritoneal cavity, whence they escape by *abdominal pores*, which place that cavity in direct communication with the exterior. In many fishes, the ovaries become tubular glands, provided with continuous ducts, which open externally, above and behind the anus. But, in all other *Vertebrata*, the ovaries are glands without continuous ducts, and which discharge their ova from sacs, the *Graafian follicles*, successively developed in their solid substance. Nevertheless, these ova do not fall into the peritoneal cavity, but are conveyed away by a special apparatus, consisting of the *Fallopian tubes*, which result from

the modification of certain embryonic structures called the *Müllerian ducts*.

The Müllerian ducts are canals which make their appearance alongside the ducts of the Wolffian bodies, but, throughout their whole extent, remain distinct from them. Their proximal ends lie close to the ovary, and become open and dilated to form the so-called *ostia*. Beyond these ostia they generally remain narrow for a space, but towards their hinder openings into the genito-urinary part of the cloaca, they commonly dilate again. In all animals but the didelphous and monodelphous *Mammalia*, the Müllerian ducts undergo no further modification of any great morphological importance; but, in the monodelphous *Mammalia*, they become united, at a short distance in front of their posterior ends; and then, the segments between the latter and the point of union, or still farther forward, coalesce into one. By this process of confluence the Müllerian ducts are primarily converted into a single *vagina* with two *uteri* opening into it; but in most of the *Monodelphia*, the two uteri also more or less completely coalesce, until both Müllerian ducts are represented by a single vagina, a single uterus, and two Fallopian tubes. The didelphous *Mammalia* have two vaginæ which may, or may not, coalesce anteriorly for a short extent; but the two uteri remain perfectly distinct. So that what takes place in them is, probably, a differentiation of each Müllerian duct into Fallopian tube, uterus, and vagina, with or without the union of the two latter, to the extent to which it is effected in the earlier stages of development in *Monodelphia*. The Wolffian ducts of the female either persist as canals, the so-called *canals of Gaertner*, which open into the vagina, or disappear altogether. Remains of the Wolffian bodies constitute the *parovaria*, observable in certain female mammals.

In the male vertebrate embryo, the *testis*, or essential reproductive organ, occupies the same position, in front of the Wolffian body, as the ovary; and, like the latter, is composed of indifferent tissue. In *Amphioxus* and in the

Marsipobranchii, this tissue appears to pass directly into spermatozoa; but, in most *Vertebrata*, it acquires a saccular

Fig. 27.

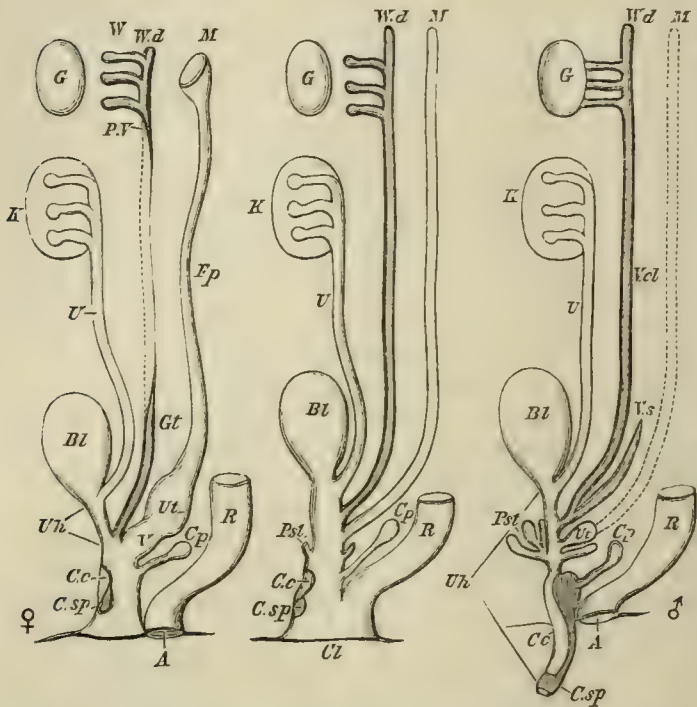


Fig. 27.—Diagram exhibiting the relations of the female (the left-hand figure, ♀), and of the male (the right-hand figure, ♂) reproductive organs to the general plan (the middle figure) of these organs in the higher *Vertebrata*.

Cl, the cloaca; *R*, the rectum; *Bl*, the urinary bladder; *U*, the ureter; *K*, the kidney; *Uh*, the urethra; *G*, the genital gland, ovary, or testis; *W*, the Wolffian body; *Wd*, the Wolffian duct; *M*, the Müllerian duct; *Pst*, prostate gland; *Cp*, Cowper's gland; *Csp*, the corpus spongiosum; *Cc*, the corpus cavernosum.

In the female, *V*, the vagina; *Ut*, the uterus; *Fp*, the Fallopian tube; *Gt*, Gaertner's duct; *P.v*, the parovarium; *A*, the anus; *Cc*, *C.sp*, the clitoris. In the male, *Csp*, *Cc*, the penis; *Ut*, the uterus masculinus; *Vs*, vesicula seminalis; *Vd*, the vas deferens.

or tubular structure, and from the epithelium of the sacs, or tubuli, the spermatozoa are developed. At first, the testis is

as completely devoid of any excretory canal as the ovary; but, in the higher vertebrates, this want is speedily supplied by the Wolffian body, certain of the tubuli of which become continuous with the *tubuli seminiferi*, and constitute the *vasa recta*, while the rest abort. The Wolffian duct thus becomes the *vas deferens*, or excretory duct of the testis; and its anterior end, coiling on itself, gives rise to the *epididymis*. A *vesicula seminalis* is a diverticulum of the *vas deferens*, near its posterior end, which serves as a receptacle for the semen.

If the Wolffian bodies, the genitalia, and the alimentary canal of a vertebrate embryo, communicated with the exterior by apertures having the same relative position as the organs themselves, the anus would be in front and lowest, the Wolffian apertures behind and highest, and the genital apertures would lie between the two. But the anal, genital, and urinary apertures are found thus related only among certain groups of fishes, such as the *Teleostei*. In all other *Vertebrata*, there is either a *cloaca*, or common chamber, into which the rectum, genital, and urinary organs open; or, the anus is a distinct posterior and superior aperture, and the opening of a genito-urinary sinus, common to the urinary and reproductive organs, lies in front of it, separated by a more or less considerable *perinæum*.

These conditions of adult *Vertebrata* repeat the states through which the embryo of the highest vertebrates pass. At a very early stage, an involution of the external integument gives rise to a *cloaca*, which receives the allantois, the ureters, the Wolffian and Müllerian ducts, in front, and the rectum behind. But, as development advances, the rectal division of the *cloaca* becomes shut off from the other, and opens by a separate aperture—the definitive *anus*, which thus appears to be distinct, morphologically, from the anus of an osseous fish. For a time, the anterior, or genito-urinary part of the *cloaca*, is, to a certain extent, distinct from the rectal division, though the two have a common termination; and this condition is repeated in *Aves*, and in ornithodelphous

Mammalia, where the bladder, the genital ducts, and the ureters, all open separately from the rectum into a genito-urinary sinus.

In the male sex, as development advances, this genito-urinary sinus becomes elongated, muscular, and surrounded, where the bladder passes into it, by a peculiar gland, the *prostate*. It thus becomes converted into what are termed the *fundus*, and *neck of the bladder*, with the *prostatic* and *membranous* portions of the urethra. Concomitantly with these changes, a process of the ventral wall of the cloaca makes its appearance, and is the rudiment of the intromittent organ, or *penis*. Peculiar erectile vascular tissue, developed within this body, gives rise to the median *corpus spongiosum* and the lateral *corpora cavernosa*. The penis gradually protrudes from the cloaca; and while the corpus spongiosum terminates the anterior end of it, as the *glans*, the corpora cavernosa attach themselves, posteriorly, to the *ischia*. The under, or posterior, surface of the penis is, at first, simply grooved; by degrees the two sides of the groove unite, and form a complete tube embraced by the corpus spongiosum. The *penial urethra* is the result.

Into the posterior part of this penial urethra, which is frequently dilated into the so-called *bulbus urethræ*, glands, called *Cowper's glands*, commonly pour their secretion; and the penial, membranous, and prostatic portions of the urethra (genito-urinary sinus) uniting into one tube, the male *definitive urethra* is finally formed.

In sundry birds and reptiles, the penis remains in the condition of a process of the ventral wall of the cloaca, grooved on one face. In ornithodelphous mammals the penial urethra is complete, but open behind, and distinct from the genito-urinary sinus. In the *Didelphia* the penial urethra and genito-urinary sinus are united into one tube, but the corpora cavernosa are not directly attached to the ischium.

Certain *Reptilia* possess a pair of eversible copulatory organs situated in integumentary sacs, one on each side of the cloaca, but it does not appear in what manner these

penes are morphologically related to those of the higher *Vertebrata*.

In the female sex, the homologue of a penis frequently makes its appearance as a *clitoris*, but rarely passes beyond the stage of a grooved process with corpora cavernosa and corpus spongiosum—the former attached to the ischium, and the latter developing a glans. But, in some few mammals (*e. g.* the *Lemuridæ*), the clitoris is traversed by an urethral canal.

In no vertebrated animal do the ovaries normally leave the abdominal cavity, though they commonly forsake their primitive position, and may descend into the pelvis. But, in many mammals, the testes pass out of the abdomen through the *inguinal* canal, between the inner and outer tendons of the external oblique muscle, and, covered by a fold of peritoneum, descend temporarily or permanently into a pouch of the integument—the *scrotum*. In their course they become invested with looped muscular fibres, which constitute the *cremaster*. The cremaster retracts the testis into the abdominal cavity, or towards it, when, as in the higher mammals, the inguinal canal becomes very much narrowed or altogether obliterated. In most mammals the scrotal sacs lie at the sides of, or behind, the root of the penis, but in the *Didelphia* the scrotum is suspended by a narrow neck in front of the root of the penis.

In most mammals the penis is inclosed in a sheath of integument, the *preputium*; and in many, the septum of the corpora cavernosa is ossified, and gives rise to an *os penis*.

In the female the so-called *labia majora* represent the scrotal, the *labia minora* the preputial, part of the male organ of copulation.

Organs not directly connected with reproduction, but in various modes accessory to it, are met with in many *Vertebrata*. Among these may be reckoned the integumentary pouches, in which the young are sheltered during their development in the male Pipefish (*Syngnathus*), in some female *Amphibia* (*Notodelphys*, *Pipa*), and *Marsupialia*; together with the mammary glands of the *Mammalia*.

CHAPTER III.

THE PROVINCES OF THE VERTEBRATA—THE CLASS PISCES.

THE *Vertebrata* are divisible into three primary groups or provinces: the *Ichthyopsida*, the *Sauropsida*, and the *Mammalia*.

I.—The *Ichthyopsida*

1. Have the epidermic exoskeleton either absent, or very slightly represented.

2. The spinal column may persist as a notochord with a membranous sheath, or it may exhibit various degrees of chondrification or ossification. When the vertebræ are distinct their centra have no epiphyses.

3. The skull may be incomplete and membranous, more or less cartilaginous, or osseous. When membrane bones are developed in connection with it, there is a large parasphenoid. The basisphenoid is always small, if it be not absent.

4. The occipital condyle may be absent, or single, or double. When there are two occipital condyles they belong to the ex-occipital region, and the basi-occipital region is unossified or very imperfectly ossified.

5. The mandible may be absent, or be represented only by cartilage. If membrane bones are developed in connection with it, there is usually more than one on each side. The articular element may be ossified or not, and may be connected with the skull by the intermediation of a quadrate and a hyomandibular element, or by a single fixed plate of cartilage representing both these and the pterygo-palatine arch. A stapes may be present or absent.

6. The alimentary canal may or may not terminate in a cloaca. When there is no cloaca the rectum opens in front of the urinary organs.

7. The blood-corpuscles are always nucleated, and the heart may be tubular, bilocular, or trilocular.

8. There are never fewer than two aortic arches in the adult.

9. Respiration takes place by branchiæ during part, or the whole, of life.

10. There is no thoracic diaphragm.

11. The urinary organs are permanent Wolffian bodies.

12. The cerebral hemispheres may be absent, and are never united by a corpus callosum.

13. The embryo has no amnion, and, at most, a rudimentary allantois.

14. There are no mammary glands.

II.—The Sauropsida

1. Almost always possess an epidermic exoskeleton in the form of scales or feathers.

2. The centra of the vertebræ are ossified, but have no terminal epiphyses.

3. The skull has a completely ossified occipital segment, and a large basisphenoid. No separate parasphenoid exists in the adult. The pro-otic is always ossified, and either remains distinct from the epiotic and opisthotic throughout life, or unites with them only after they have ankylosed with adjacent bones.

4. There is always a single, convex, occipital condyle, into which the ossified ex-occipitals and basi-occipital enter in various proportions.

5. The mandible is always present, and each ramus consists of an articular ossification, as well as of several membrane bones. The articular ossification is connected with the skull by a quadrate bone. The apparent "ankle-joint" is situated, not between the tibia and the astragalus, as in all *Mammalia*, but between the proximal and the distal divisions of the tarsus.

6. The alimentary canal terminates in a cloaca.
7. The heart is trilocular or quadrilocular. Some of the blood-corpuscles are always red, oval, and nucleated.
8. The aortic arches are usually two or more, but may be reduced to one, which then belongs to the right side.
9. Respiration is never effected by means of branchiæ, but, after birth, is performed by lungs. The bronchi do not branch dichotomously in the lungs.
10. A thoracic diaphragm may exist, but it never forms a complete partition between the thoracic and the abdominal viscera.
11. The Wolffian bodies are replaced, functionally, by permanent kidneys.
12. The cerebral hemispheres are never united by a corpus callosum.
13. The reproductive organs open into the cloaca, and the oviduct is a Fallopian tube, which presents an uterine dilatation in the lower part of its course.
14. All are oviparous, or ovoviviparous.
15. The embryo has an amnion, and a large respiratory allantois, and is developed at the expense of the massive vitellus of the egg.
16. There are no mammary glands.

III.—The **Mammalia**

1. Always possess an epidermic exoskeleton in the form of hairs.
2. The vertebræ are ossified, and (except in the *Ornithodelphia*) their centra have terminal epiphyses.
3. All the segments of the brain-case are completely ossified. No distinct parasphenoid exists in the adult. The pro-otic ossifies, and unites with the epiotic and opisthotic before these coalesce with any other bone.
4. There are always two occipital condyles, and the basi-occipital is well ossified.
5. The mandible is always present, and each ramus consists (at any rate, in the adult) of a single membrane bone, which articulates with the squamosal. The quadrate bone.

and the supra-stapedial element of the hyoidean arch, are converted into a malleus and an incus, so that, with the *stapes*, there are, at fewest, three *ossicula auditûs*.

6. The alimentary canal may, or may not, terminate in a cloaca. When it does not, the rectum opens behind the genito-urinary organs.

7. The heart is quadrilocular. Some of the blood-corpuscles are always red and non-nucleated.

8. There is only one aortic arch, which lies on the left side.

9. Respiration is never effected by means of branchiæ, but, after birth, is performed by lungs.

10. There is a complete diaphragm.

11. The Wolffian bodies are replaced by permanent kidneys.

12. The cerebral hemispheres are united by a corpus callosum.

13. The reproductive organs may, or may not, open into a cloaca. The oviduct is a Fallopian tube.

14. The embryo has an amnion and an allantois.

15. Mammary glands supply the young with nourishment.

The Ichthyopsida.—Class I.—PISCES.

The class of Fishes contains animals which vary so much in their grade of organization, and in their higher forms so closely approach the *Amphibia*, that it is difficult to draw up any definition which shall be at once characteristic and diagnostic of them. But they are the only vertebrated animals which possess median fins supported by fin-rays; and in which the limbs, when present, do not exhibit that division into brachium, antibrachium, and manus which is found in all other *Vertebrata*.

The presence of the peculiar integumentary organs constituting what is known as the system of mucous canals and the organs of the lateral line (*supra*, p. 86), is highly characteristic of Fishes, though these organs cannot be said to exist in the entire class.

The class PISCES is divisible into the following primary groups:—

- A. The notochord extends to the anterior end of the body. There are no skull, brain, auditory, or renal organs, such as exist in the

higher *Vertebrata*. The heart is a simple tube, and the liver is saccular. (LEPTOCARDIA. Haeckel).

I.—*Pharyngobranchii*.

B. The notochord ends behind the pituitary fossa. A skull, brain, auditory, and renal organs are developed. The heart is divided into auricular and ventricular chambers. The liver has the ordinary structure (PACHYCARDIA. Hck.).

a. The nasal sac is single, and has a median external aperture. Neither mandibles nor limb arches are developed (*Monorhina*. Hck.).

II.—*Marsipobranchii*.

b. There are two nasal sacs with separate apertures. Mandibles and limb arches are developed. (*Amphirhina*. Hck.).

a. The nasal passages do not communicate with the cavity of the mouth. There are no lungs, and the heart has but one auricle.

a. The skull is devoid of membrane bones.

III.—*Elasmobranchii*.

β. Membrane bones are developed in relation with the skull.

1. The optic nerves form a chiasma, and there are several rows of valves in the aortic bulb.

IV. *Ganoidei*.

2. The optic nerves simply cross, and there is only one row of valves in the aortic bulb.

V.—*Teleostei*.

b. The nasal passages communicate with the oral cavity. There are lungs, and the heart has two auricles.

VI.—*Dipnoi*.

I. The PHARYNGOBRANCHII.—This order contains but one species of fish, the remarkable Lancelet, or *Amphioxus lanceolatus*, which lives in sand, at moderate depths in the sea, in many parts of the world. It is a small semitransparent creature, pointed at both ends, as its name implies, and possessing no limbs, nor any hard epidermic or dermal covering.

The dorsal and caudal regions of the body present a low median fold of integument, which is the sole representative of the system of the median fins of other fishes. The mouth (Fig. 28, A, a) is a proportionally large oval aperture, which lies behind, as well as below, the anterior termination of the body, and has its long axis directed longitudinally. Its margins are produced into delicate ciliated tentacles, supported by semi-cartilaginous filaments, which

are attached to a hoop of the same texture placed around the margins of the mouth (Fig. 29, *f, g*). These probably represent the labial cartilages of other fishes. The oral aperture leads into a large and dilated pharynx, the walls of which are perforated by numerous clefts, and richly ciliated, so that it resembles the pharynx of an Ascidian (Fig. 28, B, *f, g*). This great pharynx is connected with a simple gastric cavity which passes into a straight intestine, ending in the anal aperture, which is situated at the root of the tail at a little to the left of the median line (Fig. 28, A, *c*). The mucous membrane of the intestine is ciliated.

Fig. 28.

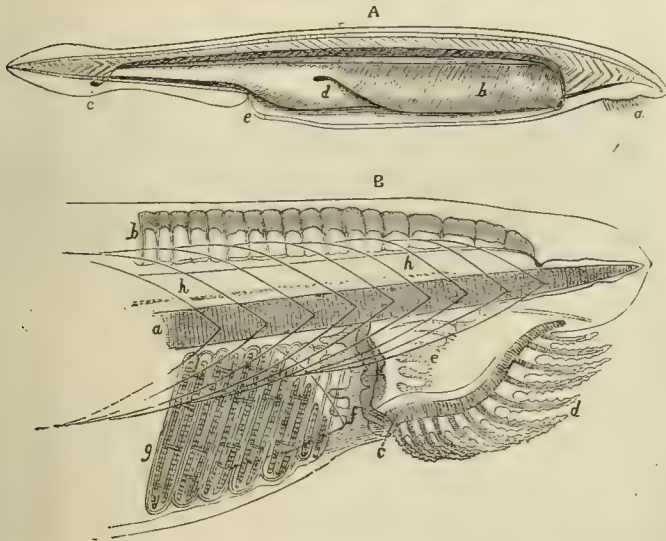


Fig. 28.—*Amphioxus lanceolatus*.—*a*, mouth; *b*, pharyngobranchial chamber; *c*, anus; *d*, liver; *e*, abdominal pore.—B, the head enlarged: *a*, the notochord; *b*, the representatives of neural spines, or fin-rays; *c*, the jointed oral ring; *d*, the filamentary appendages of the mouth; *e*, the ciliated lobes of the pharynx; *f, g*, part of the branchial sac; *h*, the spinal cord.

tine, ending in the anal aperture, which is situated at the root of the tail at a little to the left of the median line (Fig. 28, A, *c*). The mucous membrane of the intestine is ciliated.

An aperture called the abdominal pore (Fig. 28, A, *e*), placed in front of the anus, leads into a relatively spacious

cavity, which is continued forwards, on each side of the pharynx, to near the oral aperture. The water which is constantly propelled into the pharynx by its cilia, and those of the tentacles, is driven out through the branchial clefts, and makes its exit by the abdominal pore.

The liver (Fig. 28, A, *d*) is a saccular diverticulum of the intestine, the apex of which is turned forwards.

Fig. 29.

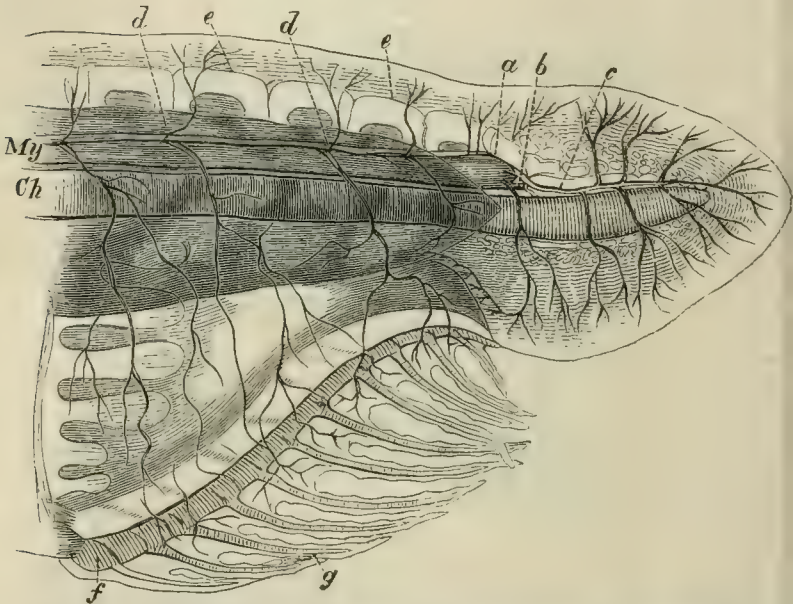


Fig. 29.—Anterior end of the body of *Amphioxus*:—*Ch*, notochord; *My*, myelon, or spinal chord; *a*, position of olfactory (?) sac; *b*, optic nerve; *c*, fifth (?) pair; *d*, spinal nerves; *e*, representatives of neural spines, or fin-rays; *f*, *g*, oral skeleton. The lighter and darker shading represents the muscular segments and their interspaces.

The existence of distinct kidneys is doubtful; and the reproductive organs are simply quadrate glandular masses, attached in a row, on each side of the walls of the visceral cavity, into which, when ripe, they pour their contents.

The heart retains the tubular condition which it possesses

in the earliest embryonic stage only, in other *Vertebrata*. The blood brought back from the body and from the alimentary canal enters a pulsatile cardiac trunk, which runs along the middle of the base of the pharynx, and sends branches up on each side. The two most anterior of these pass directly to the dorsal aorta; the others enter into the ciliated bars which separate the branchial slits, and, therefore, are so many branchial arteries. Contractile dilata-tions are placed at the bases of these branchial arteries. On the dorsal side of the pharynx the blood is poured, by the two anterior trunks, and by the branchial veins which carry away the aërated blood from the branchial bars, into a great longitudinal trunk, or dorsal aorta, by which it is distributed throughout the body.

Notwithstanding the extremely rudimentary condition of the liver, it is interesting to observe that a contractile trunk, which brings back the blood of the intestine, is distributed on the hepatic sac after the manner of a portal vein. The blood is collected again into another contractile trunk, which represents the hepatic vein, and is continued into the cardiac trunk at the base of the branchial sac. The corpuscles of the blood are all colourless and nucleated.

The skeleton is in an extremely rudimentary condition, the spinal column being represented by a notochord, which extends throughout the whole length of the body, and terminates, at each extremity, in a point (Fig. 28). The investment of the notochord is wholly membranous, as are the boundary-walls of the neural and visceral chambers, so that there is no appearance of vertebral centra, arches, or ribs. A longitudinal series of small semi-cartilaginous rodlike bodies, which lie above the neural canal, represent either neural spines or fin-rays (Fig. 28, B, *b*). Neither is there a trace of any distinct skull, jaws, or hyoidean apparatus; and, indeed, the neural chamber which occupies the place of the skull, has a somewhat smaller capacity than a segment of the spinal canal of equal length.

There are no auditory organs, and it is doubtful if a ciliated sac, which exists in the middle line, at the front

part of the cephalic region (Fig. 29, *a*), ought to be considered as an olfactory organ.

The myelon traverses the whole length of the spinal canal, and ends anteriorly without enlarging into a brain. From its rounded termination nerves are given off to the oral region, and to the rudimentary eye or eyes (Fig. 29, *b*, *c*).

According to M. Kowalewsky,* who has recently studied the development of *Amphioxus*, the vitellus undergoes complete segmentation, and is converted into a hollow sphere, the walls of which are formed of a single layer of nucleated cells. The wall of the one moiety of the sphere is next pushed in, as it were, until it comes into contact with the other, thus reducing the primitive cavity to nothing, but giving rise to a secondary cavity, surrounded by a double membrane. The operation is, in substance, just the same as that by which a double nightcap is made fit to receive the head. The blastoderm now acquires cilia, and becomes nearly spherical again, the opening into the secondary cavity being reduced to a small aperture at one pole, which eventually becomes the anus. M. Kowalewsky points out the resemblance, amounting almost to identity, of the embryo at this stage with that of many *Invertebrata*.

One face of the spheroidal blastoderm becomes flattened, and gives rise to *laminae dorsales*, which unite in the characteristically vertebrate fashion; and the notochord appears between and below them, and very early extends forwards, beyond the termination of the neural canal. The neural canal remains in communication with the exterior, for a long time, by a minute pore at its anterior extremity. The mouth arises as a circular aperture, developed upon the right side of the anterior end of the body, by the coalescence of the two layers of the blastoderm, and the subsequent perforation of the disc formed by this coalescence. The branchial apertures arise by a similar process, which takes place behind the mouth; and they are, at first, completely

* 'Mémoires de l'Académie Impériale des Sciences de St. Petersburg,' 1867.

exposed on the surface of the body. But, before long, a longitudinal fold is developed upon each side, and grows over the branchial apertures. The two folds eventually coalesce on the ventral side, leaving only the abdominal pore open. One cannot but be struck with the resemblance of these folds to the processes of integument which grow over the branchiæ of the amphibian larva; and, in like manner, inclose a cavity, which communicates with the exterior only by a single pore.

In a great many of the characters which have been enumerated—as, for example, in the entire absence of a distinct skull and brain, of auditory organs, of kidneys, of a chambered heart; in the presence of a saccular liver, of ciliated branchiæ and alimentary canal; and in the extension of the notochord forwards to the anterior end of the body—*Amphioxus* differs from every other vertebrated animal. Hence Professor Hæckel has proposed to divide the *Vertebrata* into two primary groups—the *Leptocardia*, containing *Amphioxus*; and the *Pachycardia*, comprising all other *Vertebrata*. The great peculiarities in the development of *Amphioxus*, and the many analogies with invertebrate animals, particularly the Ascidians, which it presents, lend much support to this proposition.

No fossil form allied to *Amphioxus* is known.

II. The MARSIPOBRANCHII.—In this order of the class *Pisces* the integument is devoid of scales or bony plates.

The spinal column consists of a thick persistent notochord enveloped in a sheath, but devoid of vertebral centra. The neural arches and the ribs may be represented by cartilages, and there is a distinct skull presenting cartilage at least in its base, and retaining many of the characters of the foetal cranium of the higher *Vertebrata*. The notochord terminates in a point in the base of this cartilaginous skull behind the pituitary body; and the skull is not moveable upon the spinal column. There are no jaws; but the palatopterygoid, the quadrate, the hyomandibular, and the hyoidean apparatus of higher *Vertebrata*, are imperfectly repre-

sented (Fig. 30, *f, g, h*). In some genera a basket-like cartilaginous apparatus strengthens the walls of the oral cavity; while, in others, such a framework supports the gill-sacs.

The *Marsipobranchii* possess neither the pectoral nor the

Fig. 30.

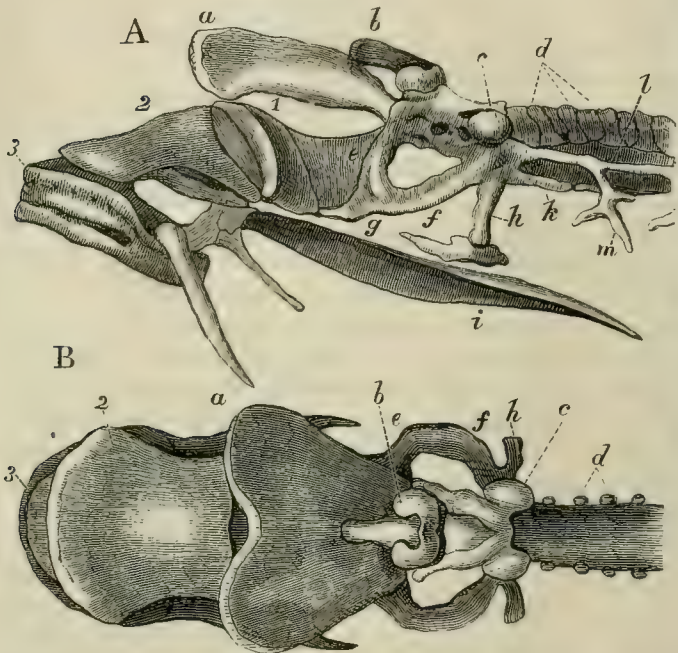


Fig. 30.—A, the skull of a Lamprey, viewed from the side; B, from above:—*a*, the ethmovomerine plate; *b*, the olfactory capsule; *c*, the auditory capsule; *d*, the neural arches of the spinal column; *e*, the palato-ptyergoid portion, *f*, probably, the metapterygoid, or superior quadrangle, portion, and *g*, the inferior quadrangle portion, of the subocular arch; *h*, stylohyal process; *i*, lingual cartilage; *k*, inferior, *l*, lateral, prolongation of the cranial cartilage; 1, 2, 3, accessory labial cartilages; *m*, branchial skeleton. The spaces on either side of *l* are closed by membrane.

pelvic pair of limbs, nor their arches. Horny teeth may be developed upon the roof of the palate, or upon the tongue, or may be supported by peculiarly developed labial carti-

lages. The alimentary canal is simple and straight, and the liver is not sac-like, but resembles that organ in other *Vertebrata*.

The heart has the usual piscine structure, consisting of a single auricle preceded by a venous sinus, a single ventricle, and an aortic bulb, all separated from one another by valves. This heart is contained in a pericardium, the cavity of which communicates with that of the peritoneum.

In *Myxine* the portal vein is rhythmically contractile.

The cardiac aorta, which is continued from the bulb, distributes its branches to the respiratory organs. These consist of antero-posteriorly flattened sacs, which communicate, directly or indirectly, on the inner side, with the pharynx, and, externally, with the surrounding medium.

In the Lamprey there are seven sacs, upon each side, which open externally by as many distinct apertures. Internally, they communicate with a long canal, which lies beneath the œsophagus and is closed behind, while anteriorly it communicates freely with the cavity of the mouth (Fig. 32, *Pr*).

The kidneys are well developed, and have the ordinary vertebrate structure, while the ureters open behind the rectum.

The brain, though very small, is quite distinct from the myelon, and presents all the great divisions found in the higher *Vertebrata*—that is to say, a fore-brain, mid-brain, and hind-brain. The fore-brain is further divided into rhinencephala, solid prosencephalic lobes, and a thalamencephalon; the hind-brain, into metencephalon and myelencephalon (Fig. 31).

The auditory organ is simpler than in other fishes, possessing only two semicircular canals and a sacculated vestibule in the Lamprey. In *Myxine* the whole organ is represented by a single circular membranous tube, without further distinction into canals and vestibule.

The *Marsipobranchii* differ remarkably, not only from the fishes which lie above them, but from all other vertebrate animals, in the characters of the olfactory organ, which consists of a sac placed in the middle line of the head, and

Fig. 31.

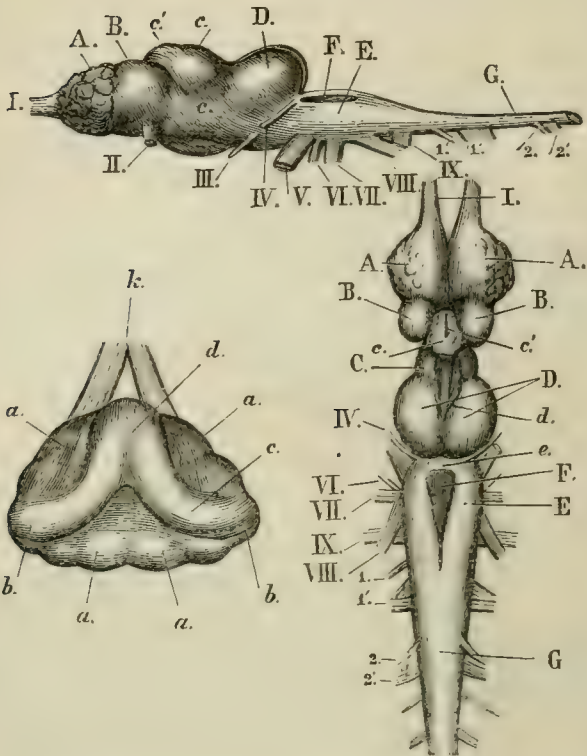


Fig. 31.—Side and upper views of the brain of *Petromyzon fluviatilis*, and an upper and inner view of the membranous labyrinth of *P. marinus*. The following letters refer to the figures of the brain:— I. the olfactory nerves, narrow anterior prolongations of the rhinencephalon (A); B, the prosencephalon; C, the thalamencephalon; D, the mesencephalon; E, the medulla oblongata; F, the fourth ventricle; *e*, the narrow band which is all that represents the cerebellum; G, the spinal cord; II. the optic; III. the oculomotorius; IV. the patheticus; V. the trigeminal; VI. the abducens; VII. the facial, and the auditory; VIII. the glossopharyngeal and pneumogastric; IX. the hypoglossal nerves; 1, 1', 2, 2', sensory and motor roots of the first two spinal nerves. In the figure of the membranous labyrinth: *k*, the auditory nerve; *a*, the vestibule; *c*, the two semicircular canals, which correspond with the anterior and posterior vertical canals of other *Vertebrata*; *d*, their union and common opening into the vestibule; *b*, the ampullæ.

having a single, median, external aperture. In all other *Vertebrata* there are two nasal sacs. In the Lampreys, the nasal sac terminates blindly below and behind, but in the Hags (*Myxine*), it opens into the pharynx. In no other fishes, except *Lepidosiren*, does the olfactory apparatus communicate with the cavity of the mouth.

The reproductive organs of the *Marsipobranchii* are solid plates suspended beneath the spinal column, and they have no ducts, but shed their contents into the abdomen, whence

Fig. 32.

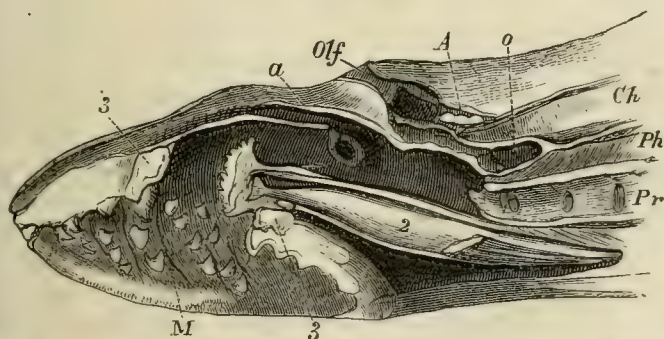


Fig. 32.--Vertical and longitudinal section of the anterior part of the body of a Lamprey (*Petromyzon marinus*):—*A*, the cranium with its contained brain; *a*, section of the edge of the cartilage marked *a*, in Fig. 30; *Olf*, entrance into the olfactory chamber, which is prolonged into the caecal pouch, *o*; *Ph*, the pharynx; *Pr*, the branchial channel, with the inner apertures of the branchial sacs; *M*, the cavity of the mouth, with its horny teeth; 2, the cartilage which supports the tongue; 3, the oral ring.

they pass out by an abdominal pore. In the early stages of their development the Lampreys present some singular resemblances to the *Amphibia*. They also undergo a metamorphosis, the young *Petromyzon* being so unlike the parent, that it was, until lately, regarded as a distinct genus—*Ammocetes*. But the young Lampreys never possess external branchial filaments or spiracula.

The *Marsipobranchii* are inhabitants of both fresh and salt water. The Myxinoids are remarkable for their parasitic habits—the Hag boring its way into the bodies of other

fishes, such as the Cod. No fossil *Marsipobranchii* are known. This circumstance may, in part, be due to the perishableness of their bodies; though horny teeth, like those of the Lampreys, might have been preserved under favourable circumstances.

III. The ELASMOBRANCHII.—This order contains the Sharks, the Rays, and the *Chimæra*.

The integument may be naked, and it never possesses scales like those of ordinary fishes; but, very commonly, it is developed into papillæ, which become calcified, and give rise to toothlike structures: these, when they are very small and close-set, constitute what is called *shagreen*. When larger and more scattered, they form dermal plates or tubercles; and when, as in many cases, they take the form of spines, these are called *dermal defences*, and, in a fossil state, *ichthyodorulites*. All these constitute what has been called a "*placoid exoskeleton*;" and, in minute structure, they precisely resemble teeth, as has been already explained. The protruded surfaces of the dermal defences are frequently ornamented with an elegant sculpturing, which ceases upon that part of the defence which is imbedded in the skin. The dermal defences are usually implanted in front of the dorsal fins, but may be attached to the tail, or, in rare cases, lie in front of the paired fins.

The spinal column exhibits a great diversity of structure: from a persistent notochord exhibiting little advance upon that of the *Marsipobranchii*, or having mere osseous rings developed in its walls, to complete vertebræ, with deep conical anterior and posterior concavities in their centra, and having the primitive cartilage more or less completely replaced by concentric, or radiating, lamellæ of bone. In the Rays, indeed, the ossification goes so far as to convert the anterior part of the vertebral column into one continuous bony mass.

The neural arches are sometimes twice as numerous as the centra of the vertebræ, in which case the added arches are termed *intercrural* cartilages.

The terminal part of the notochord is never enclosed within a continuous bony sheath, or *urostyle*. The extremity of the vertebral column is generally bent up, and the median fin-rays which lie below it are, usually, much longer than those which lie above it, causing the lower lobe of the tail to be much larger than the upper. Elasmobranchs with tails of this conformation are truly *heterocercal*, while those in which the fin-rays of the tail are equally divided by the spinal column, or nearly so, are *diphycercal* (p. 16). The Monkfish (*Squatina*) and many other *Elasmobranchii* are more *diphycercal* than *heterocercal*.

The ribs are always small, and may be quite rudimentary.

The skull is composed of cartilage, in which superficial pavement-like deposits of osseous tissue may take place, but it is always devoid of membrane bone. When moveable upon the spinal column, it articulates therewith by two condyles.

In its general form and structure, the cartilaginous skull of an *Elasmobranch* corresponds with the skull of the vertebrate foetus in its cartilaginous state, and there are usually more or less extensive membranous fontanelles in its upper walls. The ethmoidal region sends horizontal plates over the nasal sacs, the apertures of which retain their embryonic situation upon the under-surface of the skull.

Neither premaxillæ nor maxillæ are present, the "jaws" of an Elasmobranch consisting, exclusively, of cartilaginous representatives of the primary palato-quadrate arch and of Meckel's cartilage.

The former of these, the so-called upper jaw, may either be represented, as in the *Chimæra* (Fig. 33), by the anterior portion (*B, D*) of a triangular cartilaginous lamella, which stretches out from the sides of the base of the skull, and is continuous with the representative of the hyomandibular suspensorium; or there may be, on each side, a cartilaginous bar moveably articulated in front with the fore part of the skull; and, posteriorly, furnishing a condyle, with which the ramus of the lower jaw, representing Meckel's cartilage, articulates.

In the latter case, which is that met with in the Sharks and Rays (Figs. 34 & 35), a single cartilaginous rod (*g*) is moveably articulated with the skull, in the region of the periotic capsule, upon each side; and, by its opposite extremity, is connected by ligamentous fibres both with the palato-quadrate (*h*), and with the mandibular or Meckelian cartilage (*Mn*). This cartilaginous *suspensorium* represents

Fig. 33.

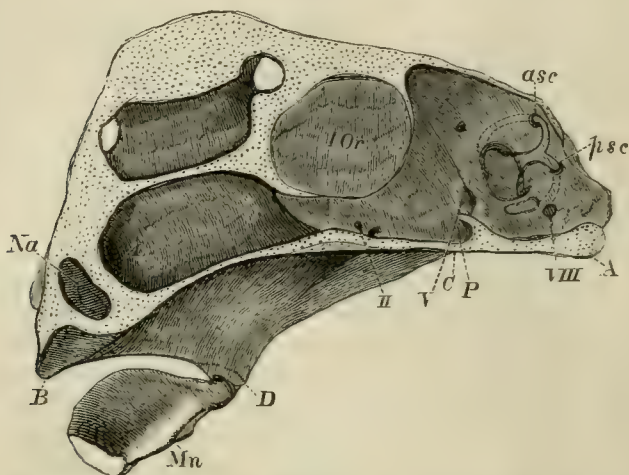


Fig. 33.—Vertical section of the skull of *Chimæra monstrosa*, without the labial and nasal cartilages:—*A*, the basi-occipital region; *P*, the pituitary fossa; *Na*, partition between the olfactory sacs; *B*, alveolus for the anterior upper jaw tooth; *C*, *D*, the region of the triangular cartilage which answers to the hyomandibular and quadrate; *D*, *B*, that which answers to the quadrate, pterygoid, and palatine; *Mn*, the mandible; *IOr*, the interorbital septum; *asc* and *psc*, the anterior and posterior semicircular canals; *I*, *II*, *V*, *VIII*, exits of the olfactory, optic, fifth and eighth pairs of nerves.

the hyomandibular and the symplectic bones of the *Teleostei*, and gives attachment to the hyoidean apparatus (*Hy*). The latter consists of a lateral arch upon each side, united with its fellow, and with the branchial arches, by the intermeditation of medial basal elements below; and it is succeeded by a variable number of similar arches, which support the branchial apparatus.

From the hyoidean and from the branchial arches cartilaginous filaments pass directly outwards, and support the walls of the branchial sacs. Superficial cartilages, which lie parallel with the branchial arches, are sometimes superimposed upon these. There are no opercular bones, though cartilaginous filaments which take their place (Fig. 34, *Op*) may be connected with the hyomandibular cartilage; and, in the great majority of the *Elasmobranchii*, the apertures of the gill-sacs are completely exposed. But in one group, the *Chimæra*, a great fold of membrane extends back from the suspensorial apparatus, and hides the external gill-apertures.

Large accessory cartilages, called *labial*, are developed at the sides of the gape in many *Elasmobranchii*. (Figs. 34 & 35, *i, k, l*.)

The pectoral arch consists of a single cartilage on each side. The two become closely united together in the ventral median line, and are not directly connected with the skull. The pelvis is also represented by a pair of cartilages, which may coalesce, and are invariably abdominal in position.

There are always two pairs of lateral fins corresponding with the anterior and posterior limbs of the higher *Vertebrata*. The pectoral fins, the structure of which has already been described, are always the larger, and sometimes attain an enormous size relatively to the body.

In these fishes, teeth are developed only upon the mucous membrane which covers the palato-quadrate cartilage and the mandible. They are never implanted in sockets, and they vary greatly in form and in number.

In the Sharks they are always numerous, and their crowns are usually triangular and sharp, with or without serrations and lateral cusps. As a rule, the anterior teeth on each side have more acute, the posterior more obtuse crowns. In the Port Jackson shark (*Cestracion*), however, the anterior teeth are not more acute than the most obtuse teeth of the others, while the middle teeth acquire broad, nearly flat, ridged crowns, and the hindermost teeth are similar but smaller.

Fig. 34.

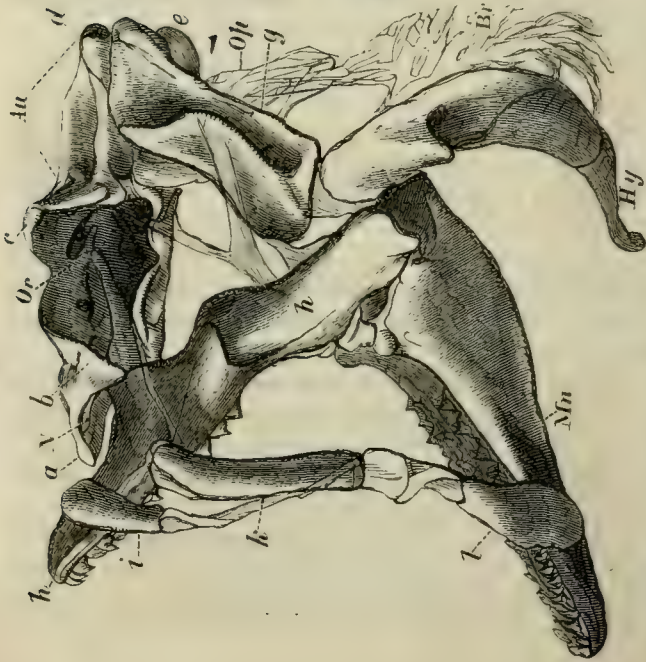
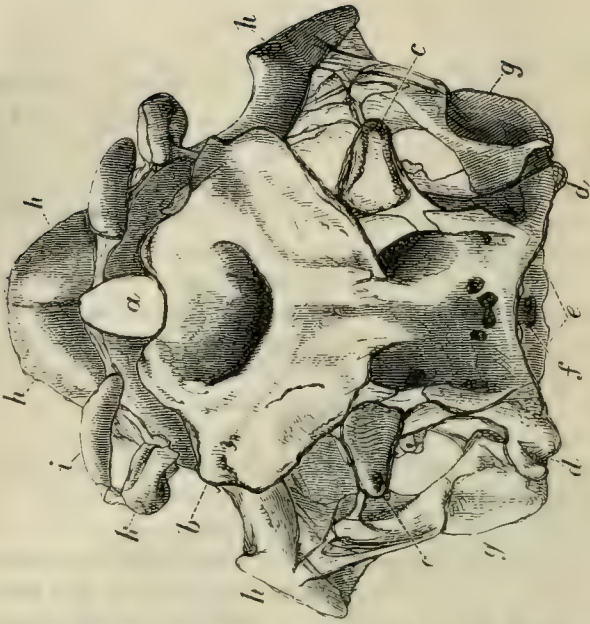


Fig. 35.



Figs. 34 & 35. — The skull of *Squatina*, viewed from the side (Fig. 34), and from above (Fig. 35): — *a*, ethmoidal region; *b*, prefrontal; *c*, postorbital; *d*, postauditory processes; *e*, occipital condyles; *f*, occipital foramen; *g*, suspensorium; *h*, upper dentigerous arch; *i*, *k*, *l*, labial cartilages; *Mn*, mandible; *Au*, auditory chamber; *Or*, orbit; *N*, nasal chamber; *Op*, opercular cartilaginous filaments; *Br*, branchiostegal rays; *Hy*, hyoidean arch.

The Rays usually have somewhat obtusely-pointed teeth, but in *Myliobates*, the middle teeth have transversely elongated, and the lateral ones hexagonal, flat crowns, and the various teeth are fitted closely by their edges into a pavement. In *Aetobatis* only the middle transversely elongated teeth remain. In the Sharks and Rays the teeth are developed from papillæ, or ridges, situated at the bottom of a deep fold within the mucous membrane of the jaw. The teeth come to the edge of the jaw, and, as they are torn away or worn down by use, they are replaced by others, developed, in successive rows, from the bottom of the groove. No such successive development takes place in the *Chimæra*.

As in other fishes, there are no salivary glands. The wide œsophagus leads into a stomach which is usually spacious and sac-like, but sometimes, as in *Chimæra*, may be hardly distinct from the rest of the alimentary canal. No diverticulum filled with air, and constituting a swimming-bladder, as in Ganoid and many Teleostean fishes, is connected with either the œsophagus, or the stomach, though a rudiment of this structure has lately been discovered in some Elasmobranchs.

The intestine is short, and usually commences by a dilatation separated from the stomach by a pyloric valve. This duodenal segment of the intestine is usually known as the *Bursa Entiana*. It receives the hepatic and pancreatic ducts, and, in the fœtus, the vitelline duct. Beyond this part, the absorptive area of the mucous membrane of the small intestines is increased by the production of that membrane into a fold, the so-called *spiral valve*, the fixed edge of which usually runs spirally along the wall of the intestine. In some sharks (*Carcharias*, *Galeocerdo*) the fixed edge of the fold runs straight and parallel with the axis of the intestine, and the fold is rolled up upon itself into a cylindrical spiral.

The short rectum terminates in the front part of a cloaca, which is common to it and the ducts of the renal and the reproductive organs. The peritoneal cavity communicates with that of the pericardium in front, and, behind, opens

externally by two *abdominal pores*. The heart presents a single auricle, receiving the venous blood of the body from a *sinus venosus*. There is a single ventricle, and the walls of the aortic bulb contain striped muscular fibres, and are rhythmically contractile, pulsating as regularly as those of the auricle and ventricle.

The interior of the bulb exhibits not merely a single row of valves at the ventriculo-bulbous aperture, but several other

Fig. 36.

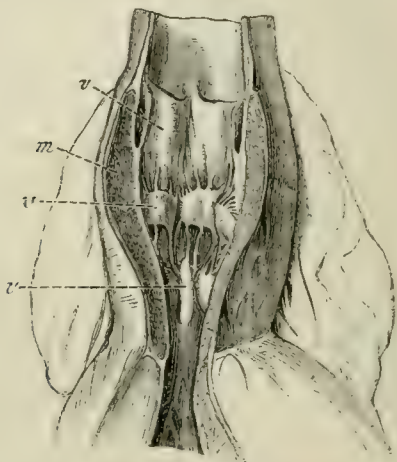


Fig. 36.—The aortic bulb of a Shark (*Lamna*), laid open to show the three rows of valves, *v, v, v*, and the thick muscular wall, *m*.

transverse rows of semilunar valves, which are attached to the walls of the bulb itself, and at its junction with the aorta. These valves must be of great importance in giving full effect to the propulsive force exerted by the muscular wall of the bulb.

In a good many *Elasmobranchii* there is a *spiracle*, or aperture leading into the cavity of the mouth, on the upper side of the head, in front of the suspensorium. From this aperture (which, according to the observations of Professor Wyman, is the remains of the first visceral cleft of the

embryo), as well as from the proper branchial clefts, long branchial filaments protrude, in the fœtal state. These disappear in the adult, the respiratory organs of which are flattened pouches, with transversely-plaited walls, from five to seven in number. They open by external clefts upon the sides (Sharks and *Chimæra*), or under-surface (Rays), of the neck, and, by internal apertures, into the pharynx.

The anterior wall of the anterior sac is supported by the hyoidean arch. Between the posterior wall of the first, and the anterior wall of the second sac, and between the adjacent walls of the other sacs, a branchial arch with its radiating cartilages is interposed. Hence the hyoidean arch supports one series of branchial plates or laminæ: while the succeeding branchial arches, except the last, bear two series, separated by a septum, consisting of the adjacent walls of two sacs with the interposed branchial skeleton.

The cardiac aorta, a trunk which is the continuation of the bulb of the aorta, distributes the blood to the vessels of these sacs; and it is there aërated by the water which is taken in at the mouth and forced through the pharyngeal apertures, outwards.

The kidneys of the *Elasmobranchii* do not extend so far forward as those of most other fishes. The ureters generally become dilated near their terminations, and open by a common urinary canal into the cloaca behind the rectum.

The brain is well developed. It usually presents a large cerebellum overlying the fourth ventricle, the side-walls of which (*corpora restiformia*) are singularly folded (Fig. 37, A., a); and moderate-sized optic lobes, which are quite distinct from the conspicuous thalamencephalon, or vesicle of the third ventricle. The third ventricle itself is a relatively wide and short cavity, which sends a prolongation forwards, on each side, into a large, single, transversely-elongated mass (Fig. 37, a), which is usually regarded as the result of the coalescence of the cerebral hemispheres, but is, perhaps,

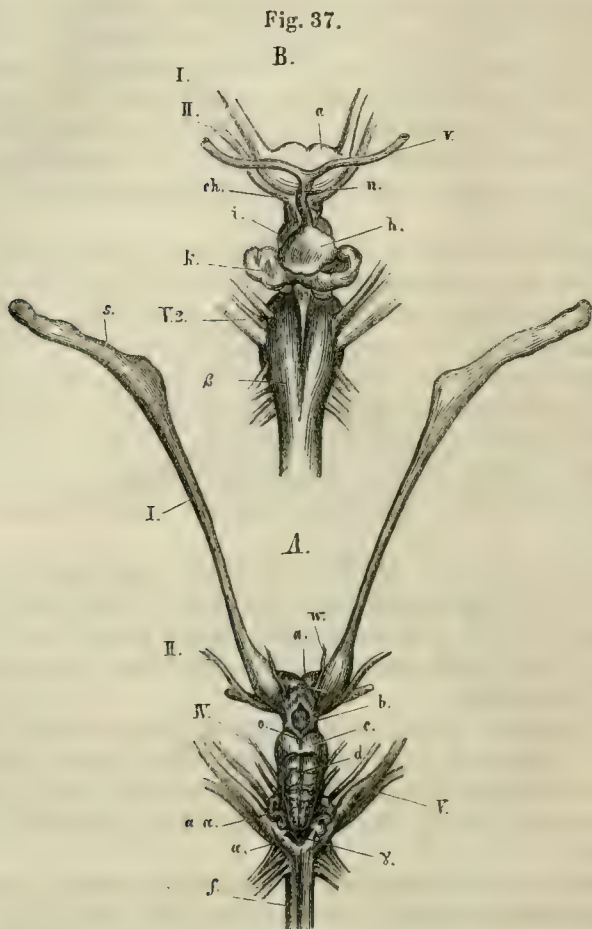


Fig. 37. — The brain of the Skate (*Raia batis*). *A.* From above; *B.* A portion of the ventral aspect enlarged:—*s*, the olfactory bulbs; *a*, the cerebral hemispheres which are united in the middle line; *b*, the thalamencephalon; *c*, the mesencephalon; *d*, the cerebellum; *a a*, the plaited bands formed by the corpora restiformia; *I*, *II*, *IV*, *V*, the cerebral nerves of the corresponding pairs; *f*, the medulla oblongata; *w*, a bloodvessel. In *B.*: *ch*, the chiasma of the optic nerves; *h*, the pituitary body; *n* and *v*, vessels connected with it; *k*, the *saccus vasculosus*; β , the pyramids of the medulla oblongata.

more properly, to be considered as the thickened termination of the primitive encephalon, in which the *lamina terminalis* and the hemispheres are hardly differentiated. The large olfactory lobes are usually prolonged into pedicles, which dilate into great ganglionic masses where they come into contact with the olfactory sacs (Fig. 37, A., s). The latter always open upon the under-surface of the head. A cleft, which extends from each nasal aperture to the margin of the gape, is the remains of the embryonic separation between the naso-frontal process and the maxillo-palatine process, and represents the naso-palatine passage of the higher *Vertebrata*. The optic nerves fuse into a complete chiasma (Fig. 37, B., ch), as in the higher *Vertebrata*. In some Sharks, the eye is provided with a third eyelid or nictitating membrane, moved by a single muscle, or by two muscles, arranged in a manner somewhat similar to that observed in birds. In both Sharks and Rays, the posterior surface of the sclerotic presents an eminence which articulates with the extremity of a cartilaginous stem proceeding from the bottom of the orbit.

Except in *Chimæra*, the labyrinth is completely inclosed in cartilage. In the Rays the anterior and posterior "semicircular" canals are circular, and open by distinct narrow ducts into the vestibular sac. In the other *Elasmobranchii* they are arranged in the ordinary way. A passage leading from the vestibular sac to the top of the skull, and opening there by a valvular aperture, represents the canal by which, in the vertebrate embryo, the auditory involution of the integument is, at first, connected with the exterior.

The testes are oval, and are provided with an epididymis and vas deferens, as in the higher *Vertebrata*. The vas deferens of each side opens into the dilated part of the ureter. Attached to the ventral fins of the male are peculiar appendages, termed *claspers*.

The ovaria are rounded, solid organs. There are usually two, but in some cases, as in the Dogfishes and nictitating Sharks, the ovary is single and symmetrical. The oviducts

are true Fallopian tubes, which communicate freely with the abdominal cavity at their proximal ends. Distally, they dilate into uterine chambers, which unite and open into the cloaca.

The eggs are very large, and comparatively few.

The Dogfishes, the Rays, and the *Chimæra* are oviparous, and lay eggs enclosed in hard leathery cases; the others are viviparous, and in certain species of *Mustelus* (*lævis*) and *Carcharias*, a rudimentary placenta is formed, the vascular walls of the umbilical sac becoming plaited, and interdigitating with similar folds of the wall of the uterus.

The embryos of most Elasmobranchs are, at first, provided with long external branchial filaments, which proceed from the periphery of the spiracle, as well as from most of the branchial arches. These disappear, and are functionally replaced by internal gills as development advances.

The *Elasmobranchii* are divided into two groups, the *Holocephali* and the *Plagiostomi*.

In the *Holocephali* the palato-quadrate and suspensorial cartilages are united with one another and with the skull into a continuous cartilaginous plate; the branchial clefts are covered by an opercular membrane. The teeth are very few in number (not more than six, four of which are in the upper, and two in the lower jaw, in the living species) and differ in structure from those of the *Plagiostomi*. This suborder contains the living *Chimæra* and *Callorhynchus*, the extinct Mesozoic *Edaphodon* and *Passalodon*; and, very probably, some of the more ancient Elasmobranchs, the teeth of which are so abundant in the Carboniferous limestones.

In the *Plagiostomi*, the palato-quadrate and suspensorial cartilages are distinct from one another, and are moveable upon the skull. The branchial clefts are not covered by any opercular membrane. The teeth are usually numerous.

The *Plagiostomi* are again subdivided into the Sharks (*Selachii* or *Squali*), with the branchial apertures at the sides

of the body, the anterior ends of the pectoral fins not connected with the skull by cartilages, and the skull with a median facet for the first vertebra; and the Rays (*Rajæ*), with the branchial clefts on the under-surface of the body, the pectoral fins united by cartilages to the skull, and no median articular facet upon the occiput for the first vertebra.

The *Elasmobranchii* are essentially marine in their habits; though Sharks are said to occur very high up in some of the great rivers of South America.

Both divisions of the *Plagiostomi* occur in the Mesozoic rocks. In the Palæozoic epoch, dermal defences and teeth of *Elasmobranchii* abound in the Permian and Carboniferous formations, and are met with in the Upper Silurian rocks. But, except in the case of *Pleuracanthus* (a Selachian), it is impossible to be certain to what special divisions they belong.

IV. The GANOIDEI.—In former periods of the world's history this was one of the largest and most important of the orders of fishes; but, at present, it comprises only the seven genera—*Lepidosteus*, *Polypterus*, *Calamoichthys*, *Amia*, *Accipenser*, *Scapirhynchus*, and *Spatularia*, which are either partially, or wholly, confined to fresh water, and are found only in the northern hemisphere. These fishes differ very widely from one another in many points of their organization, but agree in the following characters, some of which they possess in common with the *Elasmobranchii*, and others with the *Teleostei*. Thus:—

a. The *bulbus aortæ* is rhythmically contractile, and provided with several rows of valves, as in the *Elasmobranchii*.

b. The optic nerves unite in a chiasma, as in the *Elasmobranchii*.

c. There is a well-developed spiral valve in the intestine, as in the *Elasmobranchii*, in all but *Lepidosteus*, which possesses only a rudiment of such a valve.

On the other hand—

a. The branchial processes are not fixed throughout their extent to the wall of a branchial sac, which extends beyond

them, as in the *Elasmobranchii*; but their extremities project freely beyond the edge of the septum which separates each pair of branchial clefts, as in the *Teleostei*; and, as in the *Teleostei*, they are covered by a bony operculum.

b. There is a large air-bladder connected by a permanently open *pneumatic duct* with the œsophagus, as in many *Teleostei*.

c. As in the *Teleostei*, there is no cloaca.

The ventral fins are always abdominal in position. The tail is diphycercal, or heterocercal, and the terminal portion of the notochord is not ossified. The cavity of the abdomen

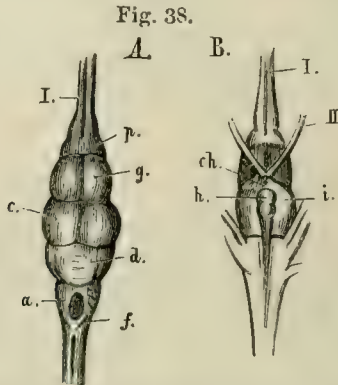


Fig. 38.—The brain of *Lepidosteus semiradiatus*. *A.* From above; *B.* From below:—*f.* the medulla oblongata; *d.* the cerebellum; *c.* the optic lobes of the mesencephalon; *g.* the cerebral hemispheres; *h.* the pituitary body; *i.* the lobi inferiores. *Ch.* the chiasma; *I.*, olfactory; *II.*, optic nerves.

is placed in communication with the exterior by abdominal pores. Finally, the ducts of the reproductive organs communicate with those of the permanent urinary apparatus, which is, in part, an Elasmobranch, in part, an Amphibian, character.

The exoskeleton presents the most extreme variations in the *Ganoidei*. *Spatularia* is naked; *Accipenser* and *Scaphirhynchus* develop numerous dermal plates composed of true bone; *Amia* is covered with overlapping cycloid scales; *Lepidosteus* and *Polypterus* have solid, rhomboidal, enamelled

scales, which not only overlap, but are fitted together by pegs and sockets, where their anterior and posterior edges come into contact.

The endoskeleton is not less diversely modified; and it is worthy of remark that no sort of relation, either direct or inverse, is traceable between the completeness of the endoskeleton and that of the exoskeleton. Thus *Spatularia*, *Scapirhynchus*, and *Accipenser* have a persistent notochord, in the sheath of which mere cartilaginous rudiments of the arches of vertebræ appear. The ribs, when present, are partially ossified. *Polypterus* and *Amia* have fully ossified vertebræ, the centra of which are amphicæulous. *Lepidosteus* also has fully ossified vertebræ; but their centra are opisthocæulous, having a convexity in front and a concavity behind, as in some *Amphibia*.

More or fewer of the anterior vertebræ, or their cartilaginous representatives, are united with one another, and with the posterior part of the skull. And the cranium may consist principally of cartilage, membrane bones being super-added; or the primordial cartilage may be largely superseded by bone, as in the *Teleostei*.

Spatularia, *Scapirhynchus*, and *Accipenser* have skulls of the former description. The cranium is one mass of cartilage, continuous behind with the coalesced anterior spinal cartilages, so as to be immoveably connected with the spinal column. The notochord enters its base, and terminates in a point behind the pituitary fossa. In front, the cartilage is produced into a beak, which, in *Spatularia*, is very long, flattened, and spatulate. In the perichondium of the base of the skull, median bones, answering to the vomer and to the parasphenoid of Teleostean fishes, are developed; and, in that of its roof, ossifications, which represent the parietals, frontals, and other membrane bones of the *Teleostei*, appear.

The framework of the jaws in *Spatularia* is very similar to that in the *Elasmobranchii*. There is a partly cartilaginous, and partly ossified, suspensorial cartilage (*A, B*, Fig. 39), which gives attachment below, directly, to the

hyoidean arch (*Hy*) and, indirectly, to the jaws. The latter consist of a palato-quadrato cartilage (*D*) united by ligament with its fellow, and with the prefrontal region of the skull at *F*.; and presenting, at its posterior end, a convex articular head to the cartilage of the mandible, or Meckelian cartilage, *Mn*. It is obvious that *A*, *B* corresponds with the hyomandibular, or suspensorial, cartilage in the Sharks and Rays; *D*, with the palato-quadrato carti-

Fig. 39.

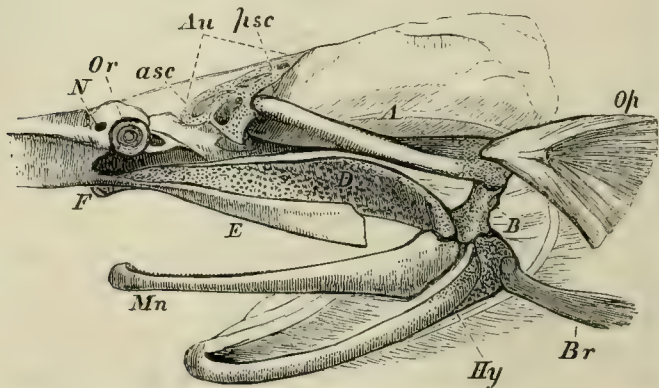


Fig. 39.—Side-view of the skull of *Spatularia*, with the beak cut away, and the anterior (*asc*), and posterior (*psc*), semicircular canals exposed:—*Au*, auditory chamber; *Or*, the orbit with the eye; *N*, the nasal sac; *Hy*, the hyoidean apparatus; *Br*, the representatives of the branchiostegal rays; *Op*, operculum; *Mn*, mandible; *A*, *B*, suspensorium; *D*, palato-quadrato cartilage; *E*, maxilla.

lage, or so-called “upper jaw,” and the cartilage of the mandible with the lower jaw in these animals. But, in the Ganoid fish, an osseous operculum (*Op*) is attached to the hyomandibular; and a branchiostegal ray (*Br*) to the more strictly hyoidean part of the skeleton of the second visceral arch; while a membrane bone (*E*) representing the maxilla, and another (*Mn*) the dentary, of the lower jaw in *Teleostei*, are developed in connection with the palato-quadrato and mandibular cartilages.

In the Sturgeon (Fig. 40), the membrane bones of the roof of the skull are more numerous and distinct than in *Spatularia*, and large dermal bones (*I, K, L*) are united with them, to form the great cephalic shield.

Fig. 40.

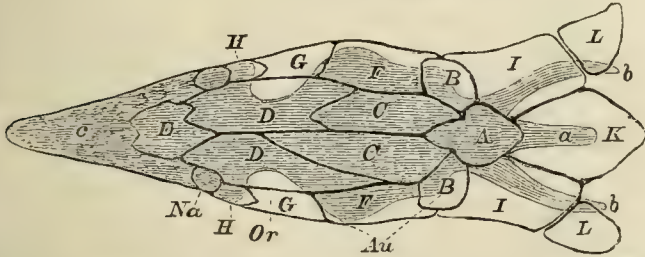


Fig. 40.—The cartilaginous skull of a Sturgeon, with the cranial bones. The former is shaded, and supposed to be seen through the latter, which are left unshaded:—*a*, ridge formed by the spinous processes of the anterior vertebræ; *b, b*, lateral winglike processes; *c*, rostrum; *Au*, position of the auditory organ; *Na*, position of the nasal sacs; *Or*, that of orbit. The membrane bones of the upper surface are: *A*, the analogue of the supra-occipital; *B, B*, of the epiotics; *E*, of the ethmoid; *G, G*, of the postfrontals; *H, H*, of the prefrontals; *C, C*, the parietals; *D, D* are the frontals, and *F, F* the squamosals; *K*, the anterior dermal scute; *I, I* and *L, L*, dermal ossifications connecting the pectoral arch with the skull.

Fig. 41.

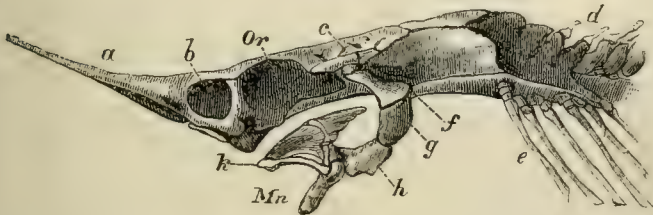


Fig. 41.—Side-view of the cartilaginous cranium of *Accipenser*:—*a*, rostrum; *b*, nasal chamber; *Or*, orbit; *c*, auditory region; *d*, coalesced anterior vertebræ; *e*, ribs; *f, g, h*, suspensorium; *k*, palato-maxillary apparatus; *Mn*, mandible.

sorium (*f, g, h*, Fig. 41) is divided into two portions, to the lower of which (at *h*) the proper hyoid is attached; and the palato-quadrate cartilages, with their subsidiary ossifications,

are so loosely connected with the floor of the skull, that the jaws can be protruded and retracted to a considerable extent.

In *Lepidosteus*, *Polypterus*, and *Amia*, the skull presents not only membrane bones, but, in addition, basi-occipital, ex-occipital, and pro-otic ossifications of the primordial cartilage, to which others may be added. The vomers are double, as in the *Amphibia* (? *Polypterus*). The apparatus of the jaws has become modified in accordance with the Teleostean type of structure. The suspensorium consists of two ossifications united by a cartilaginous intermediate portion. The upper—broad, and moveably articulated with the periotic capsule—is the *hyomandibular*; the lower answers to the *symplectic* of osseous fishes. The cartilaginous palatoquadrate arcade is, in part, replaced by a series of bones: the palatine lies in front, and is connected with the prefrontal region of the skull; behind it, lie representatives of the pterygoid, the metapterygoid, the ectopterygoid; and, most posteriorly, of the quadrate bone. The last furnishes a condyle to the articular element of the mandible. The symplectic is either loosely connected with the quadrate, as in *Lepidosteus*, or more closely united with it, as in the other genera.

In *Lepidosteus* and *Amia*, a strong and long membrane bone, the *preoperculum*, is developed on the outer side of the hyomandibular and quadrate bones, and connects them still more firmly together.

The maxilla is represented by a series of small separate ossifications in *Lepidosteus*. The proximal end of the mandibular cartilage ossifies, and becomes a distinct *articulare*. A *dentary* element is added on the outer, and a *splénial* one upon the inner side of the cartilage; and in *Lepidosteus*, *angular*, *supra-angular*, and *coronary* elements are added, so that the components of the mandible are as numerous as in reptiles. *Lepidosteus* and *Amia* have branchiostegal rays, but *Polypterus* has none—at any rate, of the ordinary kind. A single *jugular* plate is developed between the rami of the mandible in *Amia*, and there are two such

plates in *Polypterus*, which may possibly represent branchiostegal rays.

In *Accipenser*, *Spatularia*, and *Amia*, the pectoral arch presents two constituents: one, internal and cartilaginous, answers to the cartilaginous pectoral arch of the *Elasmobranchii*, and to the scapula and coracoid of the higher *Vertebrata*; the other, external, consists of membrane bones representing the clavicular, supra-clavicular, and post-clavicular bones of the *Teleostei*. In *Lepidosteus* one centre of ossification appears in the cartilage; in *Polypterus*, two. The upper represents the scapula, and the lower the coracoid.

It has been already stated (p. 39) that *Polypterus* comes nearest to the *Elasmobranchii* in the structure of the rest of the limb. The numerous dermal fin-rays, all nearly equal in size, are connected with the rounded periphery of the broad and elongated disc formed by the skeleton of the fin; and the scaly integument is continued to the bases of the fin-rays, which thus seem to fringe a lobe of the integument. Hence the fin is said to be *lobate*. In the other genera, only two of the basal cartilages are present, and some of the *radialia* come into contact with the shoulder-girdle between them. In addition, the anterior dermal fin-ray is much larger than the others, and becomes directly connected with the anterior basal cartilage. Thus, in the structure of their fins, as in so many other characters, the *Ganoidei* are intermediate between the *Elasmobranchii* and the *Teleostei*.

In certain Ganoids, as *Lepidosteus*, *Accipenser*, and many fossil genera, the anterior margins of the anterior fin-rays of the dorsal fins, bear a single or a double series of small scales, or spines, called *fulcra*.

In *Accipenser* and *Polypterus*, *spiracula*, or openings which communicate with the mouth, lie on the top of the head, in front of the suspensorium, as in many *Elasmobranchs*.

Lepidosteus, *Accipenser*, and *Scapirhynchus*, have branchiæ attached to the hyoidean arch, as in the *Elasmobranchii*. They are now called *opercular gills*.

In *Polypterus* the air-bladder is double and sacculated.

and the pneumatic duct opens upon the ventral aspect of the œsophagus. The air-bladder thus becomes exceedingly like a lung; but its vessels are in communication with those of the adjacent parts of the body—not with the heart, as in a true lung.

In *Lepidosteus*, the ducts of the male and female reproductive organs are continuous with those bodies, and each duct opens into the dilated ureter of its side. In the other

Fig. 42.

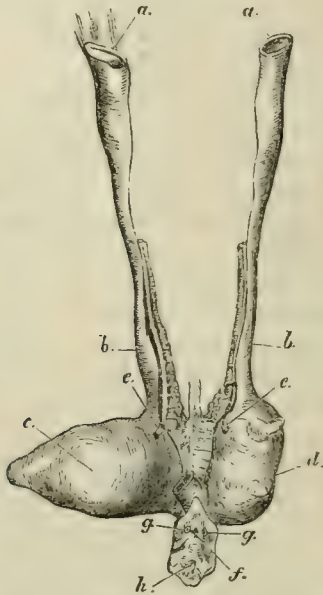


Fig. 42.—The female reproductive organs of *Amia calva*:—*a, a*, the open ends of the genital ducts; *b, b*, oviducts; *c, d*, the right and left divisions of the urinary bladder; *e, e*, the openings of the ureters into the bladder; *f*, the anus; *g, g*, the abdominal pores; *h*, the urogenital aperture.

Ganoids the proximal ends of the genital ducts, in both sexes, open widely into the abdominal cavity. In *Polypterus* the united ureters open into the cavity of the confluent oviducts, while, in the other Ganoids, the oviducts open into the dilated ureters. (Fig. 42.)

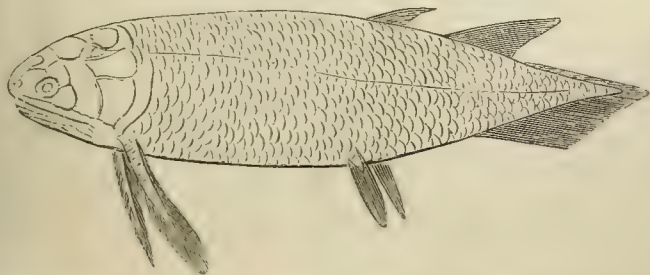When the fossil, as well as the existing *Ganoidei*, are taken into account, they form a large order, divisible into the following suborders:—1. *Amiadæ*, 2. *Lepidosteidæ*, 3. *Crossopterygidæ*, 4. *Chondrosteidæ*, all of which have living representatives; while the other three—viz., 5. *Cephalaspidæ*, 6. *Placodermi*, and 7. *Acanthodidæ*—have been extinct since the Palæozoic epoch, and are only ranged among the Ganoids provisionally, inasmuch as we have no knowledge of their internal anatomy.

1. The *Amiadæ* have a single living representative in the rivers of North America—*Amia calva*; and it is not certain that any member of the group occurs in the fossil state. The cycloid scales, preoperculum, single median jugular plate, branchiostegal rays, non-lobate paired fins, and heterocercal tail, diagnose the suborder.

2. The *Lepidosteidæ* have rhomboidal enamelled scales, a preoperculum, branchiostegal rays, non-lobate paired fins, and heterocercal tail. These are represented in the rivers of North America at the present day, and in tertiary formations, by *Lepidosteus*; in the Mesozoic rocks, by a great variety of genera—*Lepidotus*, *Echmodus*, *Dapedius*, &c.; and, in the Palæozoic epoch, by *Paleoniscus* in the Carboniferous, and probably by *Cheirolepis*, in the Devonian, formation.

3. In the *Crossopterygidæ* the scales vary in thickness and ornamentation, and may be thin and cycloid, or thick and

Fig. 43.—Restoration of *Holoptychius*.



rhomboid. The dorsal fins are either two in number, or, if single, very long, or multifid. The pectoral fins, and usually the ventrals, are lobate; they are sometimes rounded, as

in *Polypterus*—sometimes greatly elongated and almost filiform, as in *Holoptychius* (Fig. 43). There are no branchiostegal rays, but two principal, and sometimes many smaller lateral, jugular plates. The tail may be either diphyccercal or heterocercal.

The only living representatives of this suborder are *Polypterus* and *Calamoichthys*, which inhabit the rivers of North Africa. Neither of these are known to occur in the fossil state. The only family of the suborder at present known among Mesozoic fossils is that of the *Cælacanthini*, a remarkable group of fishes with a persistent notochord, rudimentary ribs, an air-bladder with ossified walls, and a single interspinous bone for each of the two dorsal fins. The *Cælacanthini* also occur in the Carboniferous formation; and the great majority of the *Crossopterygida* are found in this and the Devonian formations (*Osteolepis*, *Diplopterus*, *Glyptolæmus*, *Megalichthys*, *Holoptychius*, *Rhizodus*, *Dipterus*, *Phaneropleuron*, &c.). *Megulichthys*, *Dipterus*, and probably a few other of these fishes, have partially ossified vertebral centra; the rest possessed a persistent notochord. It is by the *Crossopterygida* that the Ganoids are especially connected with the *Dipnoi*, and, through them, with the *Amphibia*,

4. The *Chondrosteida* are either naked, or have dermal plates of bone in the place of scales. Neither the pectoral nor the ventral fins are lobate. The branchiostegal rays are few or absent, the tail is heterocercal. There are no cartilage bones in the brain-case. The teeth are very small, or absent.

The Sturgeons (*Accipenser*)—which inhabit the northern rivers of Europe, Asia, and America, occasionally migrating to the sea—*Spatularia*, and *Scapirhynchus* (found in the rivers of North America), are the recent members of this group, which is represented, in the older Mesozoic rocks, by *Chondrosteus*.

5. The *Cephalaspidæ* are remarkable fishes, probably allied to the *Chondrosteida*, which occur only in the Lower Devonian and the Upper Silurian rocks, and are some of

the oldest fish at present known. The head is covered by a continuous shield, which has the structure of true bone, in *Cephalaspis*, but more resembles certain piscine scales, in *Pterapsis*. The shield is prolonged into two horns at its posterolateral angles, and a median dorsal backward prolongation usually bears a spine, in *Cephalaspis*; the body is covered with flat bony scales or plates, and possesses two large pectoral fins. The characters of the body and fins of *Pterapsis* are unknown. Notwithstanding the excellent preservation of many of the specimens of these fishes, they have, as yet, yielded no evidence of jaws or teeth. Should jaws be absent, the *Cephalaspidæ* would approach the *Marsipobranchii* more nearly than any of the other amphyrhine fishes do.

6. The *Placodermi*, comprising the genera *Coccosteus*, *Pterichthys*, *Asterolepis*, and some others, are known to occur only in the Devonian and Carboniferous formations. In these fishes the pectoral region of the body is incased in great bony plates, which, like those of the skull, are ornamented with dots of enamel. The caudal region was covered with small scales in *Pterichthys*, while in *Coccosteus* it appears to have been naked. The pectoral member of *Pterichthys* is exceedingly long, covered with suturally-united bony plates, and united with the thoracic plates by a regular joint. In *Coccosteus* the pectoral member seems to have had the ordinary construction. The bones of the head and thorax of *Coccosteus* nearly resemble those of certain Siluroid fishes (e.g. *Clarias*) in their form and arrangement, and it seems probable that the *Placodermi* were annectent forms between the physostome *Teleostei* and the *Ganoidei*.

7. The *Acanthodidæ*, on the other hand, seem to have connected the *Ganoidei* with the *Elasmobranchii*. The scales of these fishes of the Devonian and Carboniferous formations are very small, and similar to shagreen; spines, resembling the dermal defences of the *Elasmobranchii*, are placed in front of more, or fewer, of the median and of the paired fins. The skull appears to have been unossified, and the pectoral arch seems to have consisted of a single bony hoop.

The *Pycnodontidæ*, which are commonly grouped among the Ganoids, are fishes with much-compressed bodies, like the John Dory or the Filefishes, covered with large rhomboidal enamelled scales, from which bony ridges projected internally, and were imbedded in the integument. The notochord is persistent, but the neural arches and the ribs are ossified. The proximal ends of the ribs, imbedded in the sheath of the notochord, are but little expanded in the more ancient members of the group, while, in the more modern species, they enlarge, and at length unite by serrated sutures, giving rise to spurious vertebræ. The skull is high and narrow, as in *Balistes*; the premaxillæ are small, and there are no teeth in the maxillæ, but several longitudinal series of crushing teeth (the vomer and parasphenoid?) are attached to the base of the skull. These bite between the rami of the mandible, which are also armed with several rows of similar teeth. The teeth of the Pycnodonts have no vertical successors. The pectoral fins are small, the ventral, obsolete. The Pycnodonts are all extinct, but existed, formerly, for a very long period of time—their fossil remains occurring in rocks from the Carboniferous to the older Tertiary formations, inclusively. They present curious features of resemblance to the plectognath *Teleostei*.

The remains of Ganoid fishes began to appear in the Upper Silurian rocks at the same time as those of the *Elasmobranchii*, with which they constitute the oldest Vertebrate Fauna; they abound in the Devonian formation, and constitute, with the *Elasmobranchii*, the whole of the Palæozoic Fish Fauna. We are in ignorance of the true affinities of *Tharsis* and *Thrissops*, and of the *Hoplopleuridæ*; but unless some, or all, of these are Teleosteans, Ganoids and Elasmobranchs, alone, constitute the Fish Fauna of the Mesozoic formations, as far as the bottom of the Cretaceous series.

V. The TELEOSTEI.—The osseous fishes are occasionally devoid of any exoskeleton. Sometimes they present scattered dermal plates of true bone; or, as in the Trunkfishes

(*Ostracion*), the body may be incased in a complete cuirass, which is calcified, but has not the structure of bone. Again, as in the Filefishes (*Balistes*), the skin may be beset with innumerable small spines, somewhat like those which form the shagreen of the Elasmobranchs in appearance, though they differ from them in structure. But, usually, the exoskeleton of the Teleosteans takes the form of overlapping scales, which rarely exhibit the lacunæ characteristic of true bone. The free portions of the scales are sometimes smooth, and rounded at the edge, when they are termed *cycloid*; or they are roughened with ridges and minute spines, when they are called *ctenoid*.

The spinal column always presents ossified vertebral centra, and the primordial cartilage of the skull is more or less replaced by bone. The centra of the vertebræ are usually biconcave, each face presenting a deep conical hollow. In certain Eels (*Symbranchus*), the centra of most of the vertebræ are flat in front and concave behind, the most anterior possessing a convexity in front. In many Siluroid fishes a certain number of the anterior vertebræ are ankylosed together, and with the skull, into one mass, as in the Ganoids.

The vertebræ are distinguishable only into those of the trunk and those of the tail. The latter are provided with complete inferior arches, traversed by the caudal artery and vein. The former usually possess ribs, but these do not unite with one another, nor with any sternum, in the ventral median line, and they enclose the thoracico-abdominal viscera. The vertebræ are commonly united by zygapophyses, or oblique processes, placed above the centra; in addition to which, the lower margins of the centra are, not unfrequently, united by additional articular processes. Transverse processes commonly exist, but the ribs are articulated with the bodies of the vertebræ, or with the bases of the transverse processes, not with their extremities.

When a dorsal fin exists in the trunk, its rays are articulated with, and supported by, elongated and pointed bones—the *interspinous bones*, which are developed around pre-

existing cartilages, and lie between, and are connected with, the spines of the vertebræ. The fin-rays may be entire and completely ossified, or they may be transversely jointed and longitudinally subdivided at their extremities. Not unfrequently, the articulation between the fin-rays and the interspinous bone is effected by the interlocking of two rings—one belonging to the base of the fin-ray and its included dermal cartilage, and the other to the summit of the interspinous bone—like the adjacent links of a chain.

In all Teleostean fishes the extremity of the spinal column bends up, and a far greater number of the caudal fin-rays lie below than above it. These fishes are, therefore, strictly speaking, heterocercal. Nevertheless, in the great majority of them (as has been already mentioned, p. 16), the tail seems, upon a superficial view, to be symmetrical, the spinal column appearing to terminate in the centre of a wedge-shaped hypural bone, to the free edges of which the caudal fin-rays are attached, so as to form an upper and a lower lobe, which are equal, or subequal. This characteristically Teleostean structure of the tail-fin has been termed homocercal—a name which may be retained, though it originated in a misconception of the relation of this structure to the heterocercal condition.

In no Teleostean fish is the bent-up termination of the notochord replaced by vertebræ. Sometimes, as in the Salmon (Fig. 6, p. 17), it becomes ensheathed in cartilage, and persists throughout life. But, more usually, its sheath becomes calcified, and the urostyle thus formed coalesces with the dorsal edge of the upper part of the wedge-shaped hypural bone, formed by the ankylosis of a series of ossicles, which are developed in connection with the ventral face of the sheath of the notochord.

In the caudal region of the body, interspinous bones are developed between the spines of the inferior arches of the vertebræ, and bear the fin-rays of the anal and, in part, of the caudal fin.

The *Teleostei* differ very much in the extent to which the primordial cranium persists throughout life. Sometimes,

as in the Pike (Figs. 44 & 45), it grows with the growth of the fish, and only becomes partially ossified; in other cases it almost disappears. A basi-occipital (*B.O.*), ex-occipital (*E.O.*), and supra-occipital (*S.O.*) bone are developed in it,

Fig. 44.

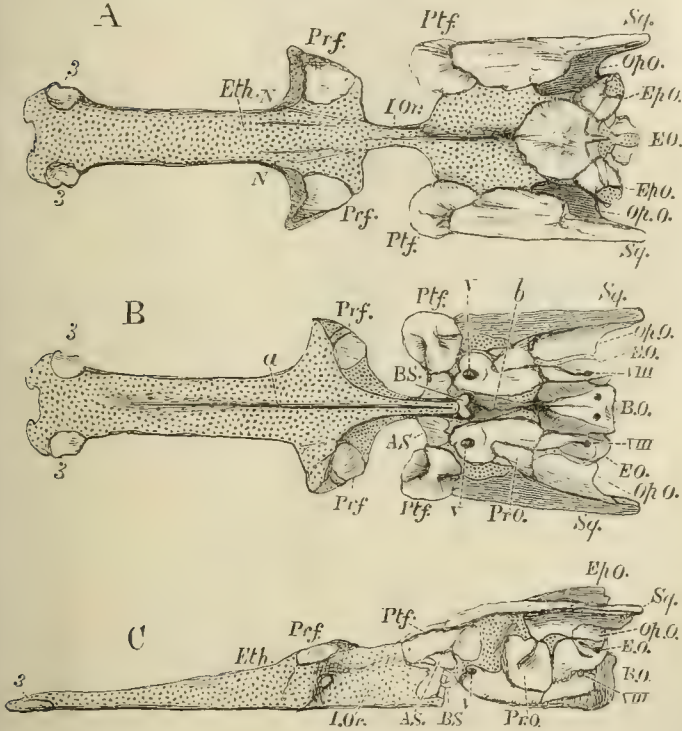


Fig 44.—The cartilaginous cranium of the Pike (*Esox lucius*), with its intrinsic ossifications; viewed, A, from above; B, from below; C, from the left side:—*N, N*, nasal fossæ; *I. Or*, interorbital septum; *a*, groove for the median ridge of the parasphenoid; *b*, canal for the orbital muscles. *Sq.*, wrongly so marked, is the Pterotic. *V* and *VIII*. mark the exits of the fifth and pneumogastric nerves; 3, 3, small ossifications of the rostrum.

and form a complete occipital segment. The proper basi-sphenoid (*BS*) bone is always a very small, and usually somewhat Y-shaped, bone. The alisphenoids (*AS.*) some-

times are and sometimes are not developed. The pre-

Fig. 45.

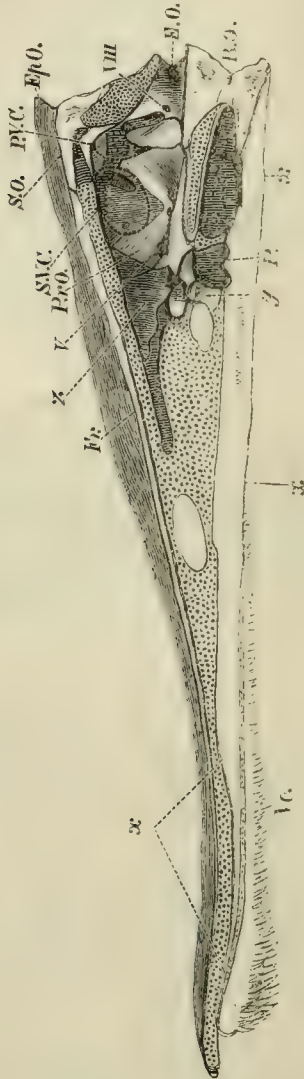


Fig. 45.—Longitudinal and vertical section of a fresh Pike's skull.—
The cut surface of cartilage is dotted. For S.V.C., and P.V.C.,

read *a.s.c.*, anterior, and *p.s.c.*, posterior semicircular canal; *x*, the parasphenoid; *y*, the basisphenoid; *Vo*, the vomer; *P.*, the pituitary fossa.

sphenoidal and orbitosphenoidal regions commonly, but not always, remain unossified.

In most osseous fishes, the base of the skull in front of the basisphenoid is greatly compressed from side to side, and forms an interorbital septum (*I. Or.*). The anterior moiety of the cranial cavity is consequently reduced to a comparatively narrow passage above the septum (Fig. 45). In the Siluroid and Cyprinoid fishes, however, this septum is not formed, and the cranial cavity is of nearly equal size throughout, or gradually diminishes forwards. The ethmoidal cartilage usually remains unossified, but sometimes, as in the Pike, ossification may take place in it. (Fig. 44, 3, 3.) The antorbital, or lateral ethmoidal, processes of the primordial cranium ossify, and give rise to the prefrontal bones (*Prf.*). The postorbital processes also ossify as postfrontals (*Ptf.*). The upper and posterior part of the primordial cranium exhibits five processes—one postero-median, two postero-lateral, and two postero-external. The postero-median ossifies as part of the supra-occipital (*S.O.*) The postero-lateral ossifies as part of the epiotic (*Ep.O.*), which lies upon the summit of the superior vertical semicircular canal. The postero-external closely corresponds with the squamosal of the higher *Vertebrata* in position; but, as a cartilage bone, it corresponds with an ossification of the capsule of the ear, called *pterotie* in the higher *Vertebrata*. Not unfrequently, as in the Cod, for example, the opisthotic (*Op.O.*) is a distinct bone, and enters into the formation of the postero-external process. The pro-otic (*Pr.O.*) is always a well-developed bone, and occupies its regular place, in front of the anterior vertical semicircular canal, and behind the exit of the trigeminal nerve.

In addition to these cartilage bones, the brain-case of osseous fishes is additionally defended by numerous membrane bones. These are, on the roof of the skull—

1. The parietal bones (*Pa.*), which sometimes meet in a

sagittal suture, as in most of the higher *Vertebrata*, but are very generally separated by the junction of the *frontals* with the supra-occipital.

2. The large frontals (*Fr.*), which may or may not unite into one.

3. The nasal bones (*Na.*), apparently replaced in the Pike by the bones 1 and 2.

Fig. 46.

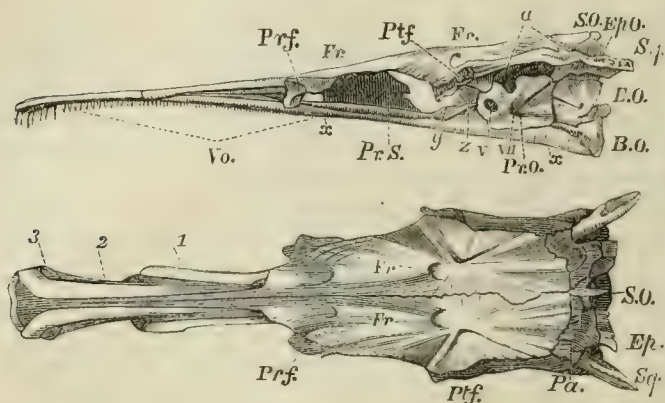


Fig. 46.—Side and upper views of the skull of a Pike (*Esox lucius*), without the facial or supra-orbital bones:—*y*, the basisphenoid; *z*, the alisphenoid; *a*, the articular facet for the hyomandibular bone.

The under-surface of the skull possesses two membrane bones: in front the *vomer* (*Vo.*), and, behind, the huge parasphenoid (*x, x*), which ensheathes all the *basis cranii*, from the basi-occipital to the vomer.

A supra-orbital bone (*S.Or.*) is the only membrane bone attached to the sides of the brain-case. Two premaxillary bones (*Pmx.*) are attached, sometimes closely, sometimes loosely, to the anterior extremity of the cranium; and behind these are the maxillæ (*Mx.*), which are sometimes large and single, as in the Cyprinoid fishes, but may become subdivided, or be reduced to mere styliform supports for cirri, as in many Siluroid fishes. In most osseous fishes the maxillæ

take little or no share in the formation of the gape, which is bounded above by the backwardly extended premaxillæ.

Fig. 47.

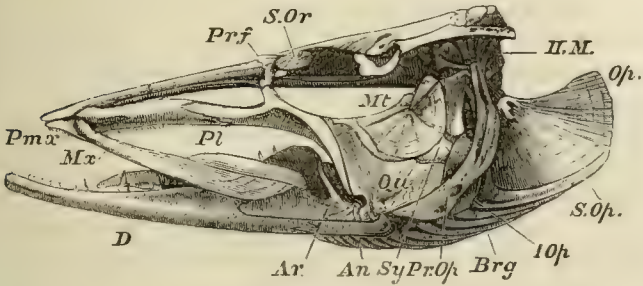


Fig. 47.—Side-view of the skull of a Pike (*Esor lucius*):—*Prf*, prefrontal; *H.M.*, hyomandibular bone; *Op.*, operculum; *S.Op.*, suboperculum; *I.Op.*, interoperculum; *Pr.Op.*, preoperculum; *Brg.*, branchiostegal rays; *Sy*, symplectic; *Mt.*, metapterygoid; *Pl.*, palato-ptyergoid arch; *Qu.*, quadrate bone; *Ar.*, articular; *An.*, angular; *D.*, dentary; *S.Or.*, suborbital bone.

Fig. 48.

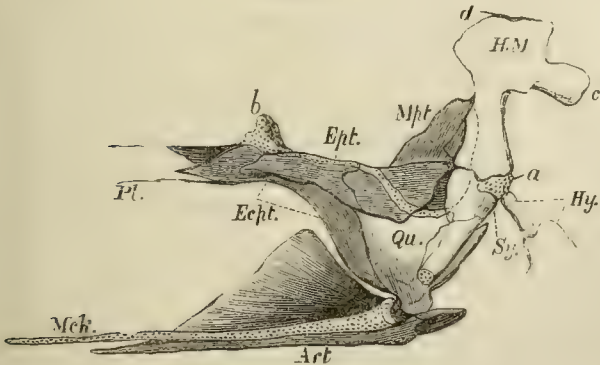


Fig. 48.—Palato-quadrate arch, with the hyomandibular and symplectic of the Pike, viewed from the inner side; the articular piece (*Art.*) of the lower jaw, and Meckel's cartilage (*Mch.*) of the Pike; seen from the inner side:—*a*, the cartilage interposed between the hyomandibular (*H.M.*), and the symplectic (*Sy.*); *b*, that which serves as a pedicle to the pterygo-palatine arch; *c*, process of the hyomandibular with which the operculum articulates; *d*, head of the hyomandibular which articulates with the skull.

The palato-quadrate and hyomandibular have essentially the same structure and arrangement as in *Lepidosteus* and *Amia*. The homologue of the suspensorium of the *Elasmobranchii* is articulated with a surface furnished to it by the postfrontal, pterotic, and pro-otic bones. Usually it moves freely upon that surface, but, in the *Plectognathi*, it may be fixed. It ossifies so as to give rise to two bones: an upper broad *hyomandibular* (*H.M.*), with which the operculum articulates; and a lower styliform *symplectic* (*Sy.*), which fits into a groove on the inner and posterior surface of the quadrate, and is firmly held there.

The palato-quadrate arch is represented by several bones, of which the most constant are the palatine (*Pl.*) in front, and the quadrate (*Qu.*) behind and below. Besides these there may be three others: an external, *ectopterygoid* (*Ecpt.*), an internal, *entopterygoid* (*Ept.*), and a *metapterygoid* (*Mpt.*). The last envelopes the upper and posterior portion of the primitive quadrate cartilage; and, fixing itself against the hyomandibular, contributes to the firmness of the union already effected by the symplectic.

Meckel's cartilage (*Mck.*) persists throughout life, but the ossification of its proximal end gives rise to an *os articulare* in the lower jaw. To these an angular (*An.*) and a dentary (*D.*) membrane bone are commonly added (Fig. 47).

The hyoidean arch is usually composed of two large cornua—connected with the cartilaginous interval between the hyomandibular and the symplectic by a *stylohyal* ossification, and abutting, in the middle line below, upon one or more median pieces, the anterior of which (*entoglossal*) supports the tongue, while the posterior (*urohyal*) extends back to join the median elements of the branchial apparatus. The cornua themselves are usually ossified into four pieces: an upper (*epihyal*) and a lower (*ceratohyal*) large ossification, and two small ones (*basihyals*) connected with the ventral ends of the lower large ossification.

There are usually five pair of branchial arches connected by median ventral ossifications. The posterior pair are single bones, which underlie the floor of the pharynx, bear

no branchial filaments, but commonly support teeth, and are called *hypopharyngeal* bones. In certain osseous fishes, thence called *Pharyngognathi*, they ankylose together into one bone. The anterior four pair are composed of several joints, and the uppermost articulations of more or fewer of them usually expand, bear teeth, and form the *epipharyngeal* bones. Sundry important membrane bones are connected with the mandibular and hyoidean arches. The *preoperculum* (*P.Op.*), *operculum* (*Op.*), and *branchiostegal* rays (*Br.*), already met with among the *Ganoidei*, are the most constant of these. Beneath the operculum, lies a *suboperculum* (*S.Op.*), and below this an *interoperculum* (*I.Op.*), which is connected by ligament with the angular piece of the lower jaw, and is also united to the outer face of the hyoidean arch. It may be altogether ligamentous, as in the Siluroids.

The branchiostegal rays are attached partly to the inner, and partly to the outer, surface of the hyoidean arch. They support a membrane, the *branchiostegal membrane*, which serves as a sort of inner gill-cover.

Most *Teleostei* possess two pair of limbs, the pectoral and the ventral fins. But the latter are often absent, and the former are occasionally wanting. When the pectoral fins are absent, the pectoral arch usually remains, though it may be reduced to little more than a filament, as in *Muraenophis*. The ventral fins are frequently situated in their normal position beneath the posterior part of the trunk; but in considerable groups of these fishes they are immediately behind the pectoral fins (*thoracic*), or even in front of them (*jugular*). In the asymmetrical *Pleuronectidæ* one pectoral fin may be larger than the other, or may alone remain, as in *Monochirus*.

The pectoral arch always consists of a primarily cartilaginous *coraco-scapular* portion—which usually ossifies in two pieces, a coracoid below, and a scapula above—and of sundry membrane bones. The chief of these membrane bones is the *clavicula* (*Cl.*), which meets its fellow in the middle line, and is usually joined to it by ligament, but sometimes, as

in the Siluroids, by sutural union. By its inner surface it gives attachment to the coraco-scapular—and sometimes above them, to a styliform bone which extends back among the lateral muscles—the *post-clavicula* (*p.cl.*).

Attached to the dorsal end of the clavicle, there is usually a second much smaller bone, the *supra-clavicula*

Fig. 49.

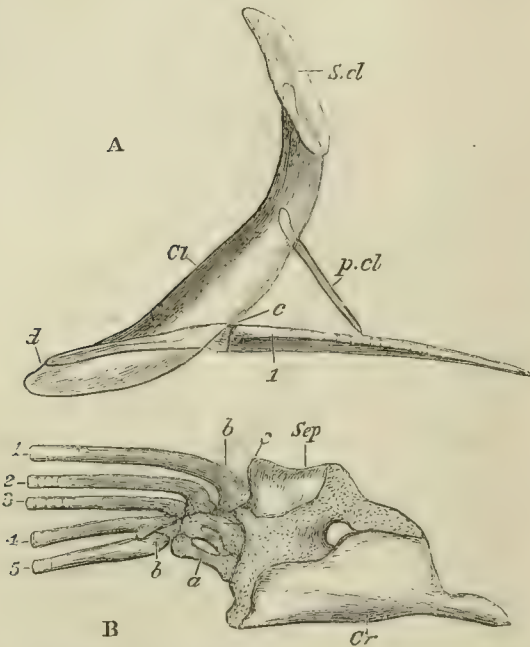


Fig. 49.—The bones of the pectoral arch and fore-limb of the Pike (*Esox lucius*). A, a semi-diagrammatic view of these bones, to show their relative natural position. The clavicle (*Cl*) is supposed to be transparent. *S.cl.*, supra-clavicula; *p.cl.*, post-clavicula; *c, d*, the posterior and anterior ends of the outer margin of the scapulo-coracoid.—B, the scapulo-coracoid and limb separate and on a larger scale; *Sep*, scapula; *Cr*, coracoid; *a*, basal cartilages; *b*, fin-rays; *c* corresponds with *c* in the foregoing figure.

(*S.cl.*), and this is very generally connected with the skull by a superficial membrane bone, the *post-temporal*, which, in front, becomes forked, and attaches itself by one prong

to the epiotic bone, by the other to the pterotic, or lower down to the side of the cranium. The base of the fin contains a series of not more than five, more or less ossified, cartilages, which are placed side by side and articulate with the coraco-scapular; to these succeed one or more rows of small cartilages, partially hidden by the bases of the exoskeletal fin-rays. The most anterior of these basal cartilages (the mesopterygial basale) is inclosed by the base of the anterior fin-ray, and effects that articulation with the shoulder-girdle which is so remarkable in many Siluroid fishes. The posterior cartilage, or bone, is the metapterygial basale, and the intermediate three are radialia (p. 40).

Most *Teleostei* possess teeth, and, in the majority of these fishes, teeth are very widely distributed over the surface of the walls of the oral and pharyngeal cavities. The teeth vary very much in structure; ordinarily, they consist of dentine, capped with structureless enamel. The parietes of the tooth are not unfrequently longitudinally folded towards the base, but this folding never goes so far as in the Ganoids. The different kinds and modes of arrangement of the teeth may be classified as follows:—

1. Isolated, more or less pointed teeth, developed from papillæ of the mucous membrane, which do not become inclosed in sacs—frequently ankylosed to the subjacent bone, but not imbedded in alveoli, nor replaced vertically.

The great majority of ordinary osseous fishes have teeth of this kind.

2. Isolated teeth, which become imbedded in sockets, and are replaced vertically.

Such teeth are seen in the premaxillæ of *Sargus*, where they curiously simulate the form of human incisors; and, imbedded in the coalesced hypopharyngeal bones, in *Labrus*.

3. Isolated teeth, imbedded in the substance of the bone which supports them. The teeth and the supporting bone wear away in front, and are replaced by new teeth developed behind the others. This structure is seen in the coalesced hypopharyngeal bones of the Parrotfish (*Scarus*).

4. Beak-like compound teeth, attached to the premaxillæ and dentary bones of the mandible.

These are of two kinds. In the Parrotfish (*Scarus*) the beak is formed by the union of numerous separately developed teeth into one mass. But in the Gymnodonts (*Tetrodon* and *Diodon*) the beak is produced by the coalescence of broad calcified horizontal lamellæ thrown off from a subjacent pulp.

5. In the Carp and its allies the basi-occipital sends down a median process, which expands at the end, and supports a broad, thick, horny tooth.

The stomach is usually wide and sac-like, but sometimes (in *Scomberesoces*, *Cyprinoids*, and others) is not wider than the intestine. Occasionally, as in *Mugil*, it acquires thick walls and becomes gizzard-like. The commencement of the small intestine is very generally marked by the presence of more or less numerous cæcal diverticula, the *pyloric cæca*. The small intestine has no spiral valve, though the mucous membrane may be raised into large transverse folds. The rectum does not terminate in a cloaca, and almost always opens quite separately from the urinary and genital ducts, and in front of them.

In many Teleostean fishes an *air-bladder* underlies the vertebral column, and is connected by an open pneumatic duct with the dorsal wall of the œsophagus, or even with the stomach, as in the Herring. In other *Teleostei*, the air-bladder occupies the same position, but is closed, the duct by which the air-bladder is primitively connected with the alimentary canal becoming obliterated. In a comparatively small number of the *Teleostei*—the *Blennii*, the *Pleuronectidæ* or Flatfishes, the Sand-eel (*Ammodytes*), the *Loricarini*, and *Symbranchii*, and some members of other families—there is no air-bladder. In those *Teleostei* in which it is present, it may be divided into two parts by a constriction; or it may be prolonged into diverticula; or *retia mirabilia* may be developed in its walls. Sometimes the air-bladder is brought into direct relation with the membranous labyrinth, as in *Myripristis* and *Sparus*, and the Herring, Shad,

and Anchovy—prolongations of the one organ being separated from the other only by a membranous fenestra in the wall of the skull. In the *Siluroidei*, *Cyprinoidei*, and *Characini*, and in the *Gymnotini*, the anterior end of the air-bladder is connected with the membranous vestibule by the intermediation of a series of bones attached to the vertebral column, some of which are moveable.

The vessels of the air-bladder are derived from, and empty themselves into, those of the adjacent parts of the body, in which respect, and in the dorsal position of the œsophageal aperture of the pneumatic duct, this structure differs from a lung.

The heart consists of a single auricle, receiving its blood from a venous sinus; and of a single ventricle, separated by a single row of valves from the *bulbus aortæ*, which is not rhythmically contractile.

The cardiac aorta divides into trunks to form the branchial arteries, which run upon the outer, or convex, side of the branchial arches, and are distributed to the branchial filaments. The blood is collected thence into a branchial vein, which also lies on the convex side of the arch; and, increasing towards its dorsal end, opens into one of the trunks of the original dorsal aorta. Of these there are two, a right and a left, which pass backwards and meet in the trunk of the dorsal aorta under the spinal column.

The anterior branchial vein gives off, at its dorsal termination, a considerable carotid trunk, which passes forwards under the base of the skull; and this is united with its fellow by a transverse branch—so that a complete arterial circle, the *circulus cephalicus*, is formed beneath the base of the skull. Below, the anterior branchial vein gives off the hyoidean artery, which ascends along the hyoidean arch, and very generally terminates by one branch in the cephalic circle, and by another enters a *rete mirabile*, which lies in the inner side of the hyomandibular bone, and sometimes has the form of a gill. This is the *pseudobranchia*. The branches of the *rete mirabile* unite again into the

ophthalmic artery, which pierces the sclerotic, and breaks up into another *rete mirabile*, the *choroid gland*, before being finally distributed.

In the Lamprey, as has been seen, the respiratory organs are pouches, the anterior and posterior walls of which are raised into vascular folds. The walls of adjacent pouches are distinct and but loosely connected together; and considerable spaces of integument separate their rounded outer apertures.

In the ordinary *Elasmobranchii*, the branchial pouches are more flattened from before backwards, and their outer apertures are more slitlike. The integumentary spaces between the slits are correspondingly narrower, and the adjacent walls of successive pouches are more closely approximated, so that they are divided only by septa; but the vascular plaits of the surface of the respiratory mucous membrane do not reach the outer edges of these septa.

In *Chimæra*, the free edges of the septa are exceedingly narrow, and the apices of the branchial processes extend outwards to them.

In the Sturgeon, the septum is not more than three-fourths as long as the branchial processes, the apices of which are consequently free.

The process of reduction is carried still further in the *Teleostei*—the septum not attaining to more than one-third the length of the branchial processes; and, as in the Ganoids, each process is supported by an osseous or cartilaginous skeleton.

The *Teleostei* have no functional hyoidean, or opercular, gill; and, as a general rule, each of their four branchial arches possesses a double series of branchial processes, making eight in all. Not unfrequently (*Cottus*, *Cyclopterus*, *Zeus*, &c.), the number is reduced to seven; the fourth branchial arch having only one series, the anterior. In this case, the gill-cleft, which should lie between this arch and the fifth, is closed. Sometimes there are only six series of branchial processes, the fourth arch being devoid of any

(e.g., *Lophius*, *Diodon*). In *Malthæa* the number is reduced to five, only the anterior series of the third arch being developed; and in *Amphipnous cuchia* only the second branchial arch possesses branchial filaments, the first, third, and fourth being devoid of them.

Many Teleostean fishes possess accessory respiratory organs. These may take the form of arborescent appendages to the upper ends of some of the branchial arches, as in *Clarias*, *Heterobranchus*, and *Heterotis*; or, as in the Climbing Perch (*Anabas*) and its allies, the epipharyngeal bones may enlarge and acquire a labyrinthic honeycombed structure, and support a large surface of vascular mucous membrane; or, as in the Clupeoid (*Lutodeira chanos*), an accessory gill may be developed in a curved cæcal prolongation of the branchial cavity. Finally, in *Saccobranchus singio* and in *Amphipnous cuchia*, the membrane lining the branchial chamber is prolonged into sacs, which lie at the sides of the body, and receive the blood from the divisions of the cardiac aorta which supply the branchiæ, while they return it into the dorsal aorta.

All these fishes (except *Lutodeira*) are remarkable for their power of sustaining life out of the water. Many inhabit the marshes of hot countries, which become more or less desiccated in the dry season.

The kidneys of Teleostean fishes receive a great part of their blood from the caudal vein, which ramifies in them. They vary greatly in length, sometimes extending along the whole under-surface of the vertebral column, from the head to the termination of the abdomen. The ureters pass into an urinary bladder which opens behind the rectum.

The brain in the *Teleostei* has solid cerebral hemispheres, and, when viewed from above, the thalamencephalon is hidden by the approximation to the hemispheres of the large and hollow optic lobes of the mesencephalon, which has a pair of inferior enlargements, *lobi inferiores*. There is a peculiarity about the structure of the optic lobes, which has given rise to much diversity of interpretation of the parts

of the brain in osseous fishes. The posterior wall of these lobes, where it passes into the cerebellum, or in the region which nearly answers to the valve of Vieussens in mammals, is thrown forwards into a deep fold which lies above the *crura cerebri*, and divides the *iter a tertio ad quartum ventriculum* from the ventricle of the optic lobes throughout almost the whole extent of the latter. This fold is the "fornix" of Gottsche. On each side of it the floor

Fig. 50.

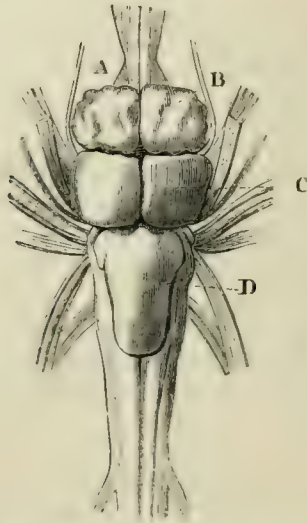


Fig. 50.—Brain of the Pike, viewed from above:—*A*, the olfactory nerves or lobes, and beneath them the optic nerves; *B*, the cerebral hemispheres; *C*, the optic lobes; *D*, the cerebellum.

of the ventricle of the optic lobes is raised up into one or more eminences, which have the same relation to the optic lobes as the *corpora striata* have to the prosencephalic vesicle.

The optic nerves simply cross one another, and form no chiasma. The cerebellum is usually large.

The cephalic part of the sympathetic nerve is present, as in the higher *Vertebrata*.

Each of the nasal sacs usually opens externally by two apertures. In some Gymnodonts a solid tentacle is said to take the place of a nasal sac.

The eyes are abortive in the Blind-fish of the caves of Kentucky (*Amblyopsis spelæus*). A fibrous band often passes from the back of the orbit to the sclerotic, and represents the cartilaginous pedicle of the Elasmobranchs. There is no nictitating membrane, but immoveable external eyelids may be developed. The choroidal gland, mentioned above, surrounds the optic nerve between the sclerotic and the choroid. Very generally, a *falciform process* of the latter membrane traverses the retina and vitreous humour to the crystalline lens. This represents the *pecten* of higher *Vertebrata*. As in other fishes, the lens is spheroidal, and the cornea flat. The sacculus of the auditory organ contains large solid otoliths, which are usually two in number—the larger, anterior one, is termed *Sagitta*; the smaller, posterior, *Asteriscus*. There are always three large semi-circular canals.

The reproductive organs are either solid glands which burst into the abdominal cavity, whence their reproductive elements are conveyed away by abdominal pores; or, as is more usual, they are hollow organs, and are continued backwards into ducts which open beside, or behind, the urinary aperture.

Some few *Teleostei* are ovoviviparous (e.g., *Zoarces viviparus*), the eggs being retained in the interior of the ovary, and hatched there. In the male *Syngnathus*, and other *Lophobranchii*, integumentary folds of the abdomen grow down and form a pouch, into which the eggs are received, and in which they remain until they are hatched.

The young of osseous fishes are not known to undergo any metamorphosis, nor are they provided with external gills, nor with spiracula.

The classification of the *Teleostei* is not yet in a thoroughly satisfactory state, and the following arrangement must be regarded as provisional:—

1. The *Physostomi*.—This group contains the *Siluroidei*, the *Cyprinoidei*, the *Characini*, the *Cyprinodontes*, the *Salmonidæ*, the *Scopelini*, the *Esocini*, the *Mormyri*, the *Galaxiæ*, the *Clupeidæ*, the *Heteropygii*, the *Murænoidei*, *Symbranchii*, and *Gymnotini*. The air-bladder is almost always present, and, when it exists, has an open pneumatic duct. The skin is either naked, or provided with bony plates, or cycloid scales; the ventral fins, when present, are abdominal in position. The fin-rays (except in the pectoral and dorsal fins of sundry *Siluroidei*) are all soft and jointed. The inferior pharyngeal bones are always distinct.

In all other Teleostean fishes the air-bladder is either absent, or devoid of an open pneumatic duct. Hence they are termed, collectively, *Physoclisti* by Haeckel.

2. The *Anacanthini*.—The body has cycloid or ctenoid scales, or is naked. The ventral fins, if present, are jugular in position. The fin-rays are all articulated. The inferior pharyngeal bones are distinct. (*Ophidini*, *Gadoidei*, *Pleuronectidæ*.)

The *Pleuronectidæ* are the most aberrant of all Teleostean fishes, on account of the disturbance in the bilateral symmetry of the body, skull, and fins, to which reference has already been made (p. 30).

3. The *Acanthopteri* have generally ctenoid scales, thoracic or jugular ventral fins, entire fin-rays in some of the fins, and distinct inferior pharyngeal bones. The *Percoidei*, *Cataphracti*, *Sparoidei*, *Sciænoidei*, *Labyrinthici*, *Mugiloidei*, *Notacanthini*, *Scomberoidei*, *Squamipennes*, *Tænioidei*, *Gobioidei*, *Blennioidei*, *Pediculati*, *Theuthyes*, and *Fistulares*, belong to this great group.

4. The *Pharyngognathi* is the name given by Müller to a somewhat artificial assemblage of fishes, the only common characters of which are the ankylosis of the inferior pharyngeal bones and the closed pneumatic duct. They have either cycloid, or ctenoid, scales. The ventral fins may be abdominal or thoracic. The anterior dorsal and ventral fin-rays may be either unjointed, as in the *Labroidei*, *Pomacentridæ*, *Chromidæ*; or articulated, as in the *Scomberesoces*.

The two remaining groups are very peculiar; but I confess I do not see upon what ground they can be regarded as of ordinal value.

5. The *Lophobranchii*.—The body is covered with bony plates. The ventral fins are almost always absent. The inferior pharyngeal bones are distinct. The branchial processes have a clavate form, being larger at the free than at the attached ends, and are in this respect unlike those of any other fishes. (*Pegasidæ*, *Syngnathidæ*.)

6. The *Plectognathi*.—The body is covered with plates or spines. The ventral fins are absent, or represented only by spines. The inferior pharyngeal bones are distinct. The premaxillæ and, usually, the hyomandibular, are immovably united with the skull—a character of rare occurrence among other fishes. (*Gymnodontidæ*, *Ostraciontidæ*, *Balistidæ*.)

The greater number of *Teleostei* are marine. No *Anacanthini*, *Plectognathi*, or *Lophobranchii*, and only one family of *Pharyngognathi* (the *Chromidæ*), inhabit completely fresh water. Comparatively few *Acanthopteri* are fluviatile. On the other hand, by far the greater number of the *Physostomi* are, either temporarily or permanently, freshwater fish.

If the *Leptolepidæ* (*Thrissops*, *Leptolepis*, *Tharsis*) are Ganoids, the *Teleostei* are not known before the Cretaceous epoch, when both *Physostomi* and *Acanthopteri* make their appearance, under forms, some of which (e.g., *Beryx*) are generically identical with fish living at the present day.

VI. The DIPNOI.—The “Mudfishes” of the rivers of the east and west coasts of Africa and of eastern South America are nearly transitional forms between the *Pisces* and the *Amphibia*.

The eel-like body, covered with overlapping cycloid scales, tapers to a point at its caudal extremity, and is provided with two pairs of long, ribbon-like, pointed extremities, and with a caudal fin.

The spinal column consists of a thick notochord, invested by a cartilaginous sheath, without any osseous or cartila-

ginous vertebral centra. The proximal ends of ossified neural arches, of ribs, and, in the caudal region, of inferior arches, are imbedded in the sheath of the notochord.

Fig. 51.




Fig. 51.—The Mudfish (*Lepidosiren*).

Fig. 52.

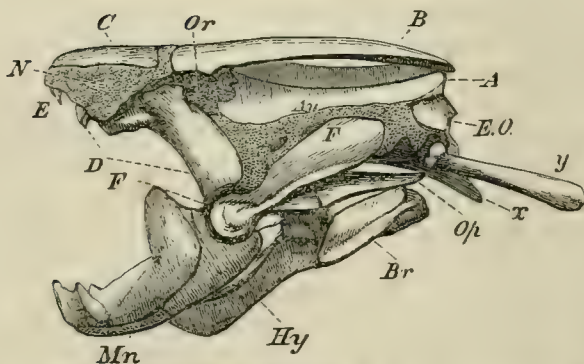


Fig. 52.—Skull of *Lepidosiren annectens*:—*A*, the parieto-frontal bone; *B*, the supra-orbital; *C*, the nasal; *D*, the palato-pterygoid; *E*, the vomarine teeth; *E. O.*, the ex-occipital; *Mn*, the mandible; *Hy*, the hyoid; *Br*, the branchiostegal rays; *Op*, the opercular plate; *x*, the parasphenoid; *y*, the pharyngo-branchial; *Or*, the orbit; *Au*, the auditory chamber; *N*, the nasal sac.

Fin-rays support the median fin. The skull, the palatoquadrate, and suspensorial apparatus, form, as in *Chimæra*,

one continuous cartilaginous mass, into the base of which the notochord penetrates, terminating in a point behind the pituitary fossa.

No cartilage bone is developed in the place of the basi-occipital, supra-occipital, basisphenoid, or presphenoid; and there are only two such ossifications, which represent the ex-occipitals (*E. O.*) in the side-walls of the cranium. A large parasphenoid (*x*) underlies the base of the skull. Upon its roof a great single bone (*A*), answering to the parietals and frontals, extends from the occipital to the ethmoidal regions. In front of this are two nasal bones (*C*).

Fig. 53.

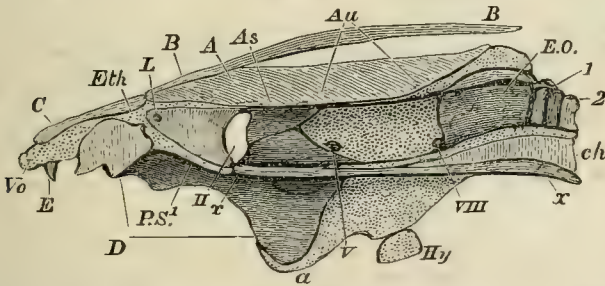


Fig. 53.—Longitudinal and vertical section of the skull of *Lepidosiren*. The cartilage is dotted; the membranous and bony constituents are shaded with lines. *A*, *B*, *C*, *D*, *E*, *Hy*, as in the preceding figure; *x*, *x*, the parasphenoid; *P.S.*¹, cartilaginous presphenoidal region; *ch*, notochord; *Au*, situation of auditory chamber; 1, 2, first and second vertebræ; *II*, *V*, *VIII*, exits of optic, trigeminal, and vagus nerves; *a*, quadrato-mandibular articulation.

There is no alisphenoid, but the fronto-parietal and parasphenoid send processes towards one another, which unite in front of the exit of the third division of the fifth nerve. There is no interorbital septum, and the cavity of the skull remains of tolerably even diameter throughout. In front of the exit of the optic nerves, however, it is longitudinally divided by a membranous septum.

The ethmovomerine cartilage is continued to the anterior extremity of the skull. It bears teeth, but no distinct vomer.

A great palato-pterygoid osseous arch (*D*) extends from the middle line along the upper and the under surface of the palato-quadrate arch on each side to near the articular surface of the mandible. In the middle of the roof of the mouth, divergent, cutting, dentary plates are developed upon it. An osseous nodule lies in the articular head of the palato-quadrate cartilage, and is continuous with the bone *F*.

The mandible presents dentary plates corresponding with those of the palate, and biting between the latter. The hyoidean arch is attached to the posterior and lower edge of the suspensorium—which bears a bony ray representing an operculum—while the hyoidean arch itself carries a single branchiostegal ray (*Br*, Fig. 52).

The pectoral arch is composed of a median cartilaginous part, with two lateral portions of cartilage, at once separated from, and connected with, the median cartilage by bone. The bone is separated from the cartilage by a layer of connective tissue, and seems to represent the clavicle, while the cartilage answers to the coalescent coraco-scapular cartilages of other fishes.

The filiform fin is supported by a many-jointed cartilaginous rod, articulated proximally with the coraco-scapular. Upon this are disposed fine fin-rays like those of the Elasmobranchs, which support the marginal fringe of the fin. The ventral fin has the same structure as the pectoral.

The intestine possesses a spiral valve, and the rectum opens into a cloaca. The lungs have remarkably stiff walls, and extend through the greater part of the body, beneath the spine. The glottis, opening upon the ventral wall of the gullet, places them in communication with the cavity of the mouth, into which the nasal sacs open by posterior apertures, which lie inside the upper lip and constitute true posterior nares. The heart has a small, but distinct, left auricle, into which the blood which has been aerated in the lungs is returned. In addition to lungs, *Lepidosiren* possesses both internal and external gills, but the latter are rudimentary in the adult.

The different species seem to differ in the manner in which

the primitive aortic arches are metamorphosed : but it may be said, generally, that the first has disappeared ; the second supplies an internal branchia developed upon the hyoidean arch ; the third gives off the anterior carotid artery, and supplies neither internal nor external branchia ; the fourth supplies only the first external branchia ; the fifth and sixth supply both internal and external branchiæ ; while the seventh is connected only with an internal branchia. The pulmonary artery seems originally to have been given off from an eighth aortic arch.

It is a remarkable circumstance, that while the *Dipnoi* present, in so many respects, a transition between the piscine and the amphibian types of structure, the spinal column and the limbs should be not only piscine, but more nearly related to those of the most ancient Crossopterygian Ganoids than to those of any other fishes.

CHAPTER IV.

THE CLASS AMPHIBIA.

The ICHTHYOPSIDA.—Class II.—AMPHIBIA.

The only clearly diagnostic characters of this class as compared with Fishes are the following:—

1. *Amphibia* have no fin-rays.
2. When limbs are present they contain the same skeletal elements as those of the higher *Vertebrata*.

Certain other structural peculiarities are common to the whole of the *Amphibia*, and are very characteristic of them without being diagnostic. Thus:—

1. The body is usually devoid of any exoskeleton, and when scales, or scutes, are present in recent *Amphibia*, they are concealed within the skin (*Cæcilia*, *Ephippifer*). In the extinct *Labyrinthodonta*, the dermal armour is confined to the ventral region of the body.

2. The vertebral centra are always represented by bone.

3. The sacrum rarely consists of more than one vertebra, though there are individual exceptions to this rule, as in *Menopoma*.

4. The suspensorial apparatus of the mandible is continuous with the skull, which has two occipital condyles, and no completely ossified basi-occipital.

5. There are no sternal ribs.

The *Amphibia* are divisible into the following groups:—

- A. A distinct and often long tail; the vertebræ amphicæulous or opisthocæulous; the proximal elements of the tarsus not elongated.

- A. Two or four limbs; no scutes or scales.

- I. *Sauvobatrachia* or *Urodela*.

- a. External branchiæ or gill-clefts persistent, or disap-

pearing only in advanced age; no eyelids; vertebræ amphi-cœlous; carpus and tarsus cartilaginous.

1. *Proteidea*.

- b. No branchiæ or branchial clefts in the adult; eyelids present; carpus and tarsus more or less ossified; vertebræ commonly opisthocœlous.

2. *Salamandridea*.

- B. Limbs absent, or all four present. Three large pectoral osseous plates and an armour of small scutes on the ventral surface of the body; vertebræ amphi-cœlous; walls of the teeth more or less folded.

II. *Labyrinthodonta*.

- B. Tail obsolete in the adult.

- A. Limbs absent; numerous minute dermal scutes imbedded in the integument of the serpentiform body.

III. *Gymnophiona*.

- B. All four limbs present, and the proximal elements of the tarsus much elongated; the body short, and the integument devoid of small scutes, though dermal osseous plates are sometimes developed in it.

IV. *Batrachia* or *Anura*.

The integument in most *Amphibia* is soft and moist, as in the Frog, where numerous glands open upon its surface. The *Gymnophiona* are exceptional, among existing *Amphibia*, in possessing small, rounded, flexible scales, like the cycloid scales of fishes, imbedded within the wrinkled integument.

In certain *Batrachia* (*Ceratophrys dorsata*, *Ephippifer aurantiacus*), flat dermal bony plates are developed in the dorsal integument, and become united with some of the subjacent vertebræ. Many of the extinct *Labyrinthodonta*, and probably the whole of the members of that group, possessed an exoskeleton which appears to have been confined to the ventral surface of the body. Under the anterior part of the thorax there is a sort of plastron composed of one median and two lateral plates. The median plate is rhomboidal. The lateral ones are somewhat triangular, and unite with the anterolateral margins of the median plate by one side, sending a process upwards and backwards from their outer angles. The outer surfaces of all these plates exhibit a sculpture, which radiates from the centre of the median plate and from the outer angles of the lateral plates. These

plates are in close relation with the pectoral arch, and probably represent the interclavicle and clavicles.

Minute bony plates cover the surface of the throat in a small African Labyrinthodont, *Micropholis*. I have not met with dermal ossicles in this position in other Labyrinthodonts. But in *Archegosaurus*, *Pholidogaster*, *Urocordylus*, *Keraterpeton*, *Ophiderpeton*, *Ichthyerpeton*, the integument between the thoracic plates and the pelvis presents regularly-disposed rows of small elongated ossicles, which, for the most part, converge from without, forwards and inwards, towards the middle line. No trace of these appears upon the tail, nor in any part of the dorsal region of the body, nor on the limbs.

The endoskeleton of the *Amphibia* is least complete in *Archegosaurus*, where the centra of the vertebræ are represented only by bony rings, the ribs and the neural arches being well ossified. In other Labyrinthodonts of the same (Carboniferous) epoch, however, such as *Anthracosaurus*, the centra of the vertebræ are completely ossified biconcave discs, very like the centra of the vertebræ of *Ichthyosaurus*.

In the existing *Proteidea*, and in the *Gymnophiona*, the vertebral centra are amphicæulous. In the *Salamandridea* they are opisthocæulous. In *Pipa* and *Bombinator* they are also opisthocæulous, but in other Batrachia they are, for the most part, proocæulous, but vary in different regions, some being biconvex and some biconcave.

The first vertebra, or atlas, presents two articular cups to the condyles of the skull, but there is no specially modified axis vertebra.

The transverse processes may be simple, but in the Labyrinthodonts, and in the existing Salamanders, they are divided into two processes—an upper *tubercular*, and a lower *capitular*, process. When the transverse process is thus divided, the proximal end of the rib is correspondingly split into a capitular and a tubercular process.

In the *Gymnophiona*, the *Sauvobatrachia*, and the *Labyrinthodonta*, the number of the vertebræ in the trunk is considerable, and the members of the two latter groups have

long tails. But in the *Batrachia*, the total number of vertebræ does not exceed eleven, of which eight belong to the presacral region, one to the sacrum, and two (modified vertebræ) to the coccygeal region. The transverse processes of some of the presacral vertebræ are usually very long, but there are no separately ossified ribs. The transverse processes of the sacral vertebra are very large and expanded, and its centrum has usually a single concavity in front and a double convexity behind.

The coccyx consists of a long, cylindroidal, basal bone proceeding from the ossification of the sheath of the termination of the notochord, and corresponding with the urostyle of the *Teleostei*; and of two neural arches, which lie over its anterior end, and become ankylosed with it. The anterior face of the coccyx usually presents two concave facets for articulation with the posterior convexities of the sacrum.

The cavity of the cranium is not narrowed anteriorly by the development of an interorbital septum in any Amphibian. All existing *Amphibia* have ex-occipitals developed in the walls of the cartilaginous cranium; but it is not certain that any such ossifications existed in *Archegosaurus*, though they are present in other Labyrinthodonts.

No Amphibian possesses a complete basi-occipital, supra-occipital, basisphenoid, alisphenoid, or presphenoid cartilage bone. In existing *Amphibia*, a pro-otic ossification appears to be very constant. The constant existence of distinct opisthotic and epiotic elements is doubtful.

The Frog's skull is characterised by the development of a very singular cartilage bone, called by Cuvier the "*os en ceinture*," or girdle-bone. This is an ossification which invades the whole circumference of the cranium in the presphenoidal and ethmoidal regions, and eventually assumes somewhat the form of a dice-box, with one-half of its cavity divided by a longitudinal partition. The latter, corresponding with the front part of the bone, extends into the prefrontal processes in some frogs, protects the hinder ends of the olfactory sacs, and is perforated by the nasal division of the fifth nerve. The septum, therefore, answers

Fig. 54.

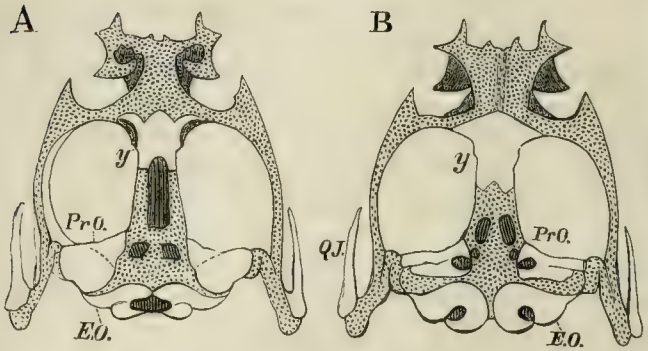


Fig. 54.—The cartilaginous cranium of *Rana esculenta*. A, from above; B, from below:—*y*, the “os en ceinture” or girdle-bone.

Fig. 55.

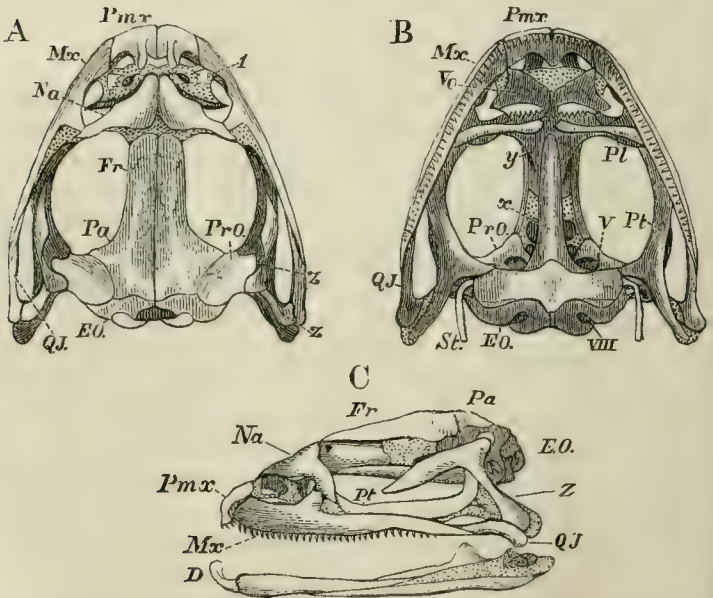


Fig. 55.—Skull of *Rana esculenta*. A, from above; B, from below; C, from the left side:—*x*, parasphenoid; *y*, girdle-bone; *Z*, the “temporo-mastoid.”

to the ethmoid, the anterior half of the girdle-bone to the prefrontals, or part of them, and the posterior half of the girdle-bone to the orbitosphenoids of other *Vertebrata*. Turbinal ossifications are developed in the cartilage bounding the nasal capsules in some *Amphibia*.

The membrane bones of the Amphibian skull are:—
 1. Frontals and parietals, which, in the *Batrachia*, may be fused together into one bone. 2. Nasals are generally present. 3. The vomers, always present, are two in number, one for each side, in all *Amphibia* but *Pipa*, *Dactylethra*, and *Pelobates*. 4. A great parasphenoid covers the base of the skull from the occipital to the ethmoidal region, as in *Teleostei* and *Ganoidei*. 5. A membrane bone (*Z*), called “temporomastoid” by Dugés, lies on the outer side of the suspensorium, extending from the side-walls of the skull to the articular head for the lower jaw. The relations of this bone in its upper part are similar to those of the squamosal of the higher *Vertebrata*, in its lower part to those of the bone *F* in *Lepidosiren*, to the preoperculum of fishes, and to the tympanic of the higher *Vertebrata*.

Two premaxillæ are always developed. The maxillæ are usually present, and may be connected, as in most *Batrachia*, by quadrato-jugal ossifications with the outer side of the end of the suspensorium, in which an ossification representing the quadrate bone is often developed. But the quadrato-jugals (and even the maxillæ) may be represented simply by more or less ligamentous fibrous tissue, as is the case in the *Urodela*. Pterygoid bones are developed in all *Amphibia*, and distinct palatine bones in most, but not all, of the *Batrachia*. The suspensorium, which is inclined downwards and forwards in the lower *Urodela*, passes almost directly downwards, or a little backwards, in the higher, and in the *Batrachia* slopes greatly backwards; and it undergoes the same modifications in direction, during the progress of any of the *Batrachia* from the larval to the adult state.

In the mandible, the proximal end of Meckel’s cartilage is rarely, if ever, completely converted into a bony articular element, but the distal moiety is ossified in some *Batrachia*.

The membrane bones of the mandible are a dentary and a splenial piece, with, perhaps, an angular element.

The hyoidean arch is, in most *Amphibia*, connected with the suspensorial cartilage—sometimes quite close to its origin, sometimes near its distal end, in the *Urodela*. Its cornua are stout and well ossified in the *Proteidea*. In the *Batrachia* they are slender, and their proximal ends may be free. Distally, they are connected with a broad lamellar body, from the posterior margin of which two processes which embrace the larynx are usually given off. In the perenibranchiate *Proteidea*, the hyoidean arches are united by narrow median entoglossal and urohyal pieces, as in Fishes.

In the *Batrachia*, the branchial arches disappear in the adult; but in the *Gymnophiona* and in the *Urodela*, more or fewer of the larval branchial arches persist throughout life.

In the *Proteidea* there are three or four branchial arches, each usually consisting of two cartilaginous, or ossified, pieces on each side. In the *Salamandridea*, there are, primitively, four branchial arches, but of these, portions of only the two anterior remain in the adult. Four are developed in the *Cæcilia*, and three of these are permanent.

Some peculiarities exhibited by the skulls of the *Gymnophiona*, and by the *Labyrinthodonta*, are worthy of especial notice.

In the former, e.g. in *Ichthyophis glutinosa*, the skull is covered by a complete bony roof, formed, mainly, by the ex-occipitals, parietals, frontals, prefrontals, nasals, and ascending processes of the premaxillaries. Between the ex-occipitals, the parietal, and the frontal, above, the maxilla, in front, and the quadrate, behind and below, lies a bone which appears to answer to the bone (*z*) of the Frog, and to its quadrato-jugal. Between the nostril and the maxilla, the nasal bone and the premaxilla, there is a bone which seems to be an ossification of the cartilaginous *ala nasi*. Another bone nearly encircles the orbit, and, as a supra- and postorbital bone, has no analogue among existing *Amphibia*. The palatine bones surround the posterior and

outer margins of the posterior nares, and then extend back on the inner side of the maxilla, in a manner unlike anything observed among other existing *Amphibia*. But in the *Labyrinthodonta*, both this disposition of the palatine and the complete roofing over of the skull by bone are repeated, and there is a postorbital bone.

Fig. 56.

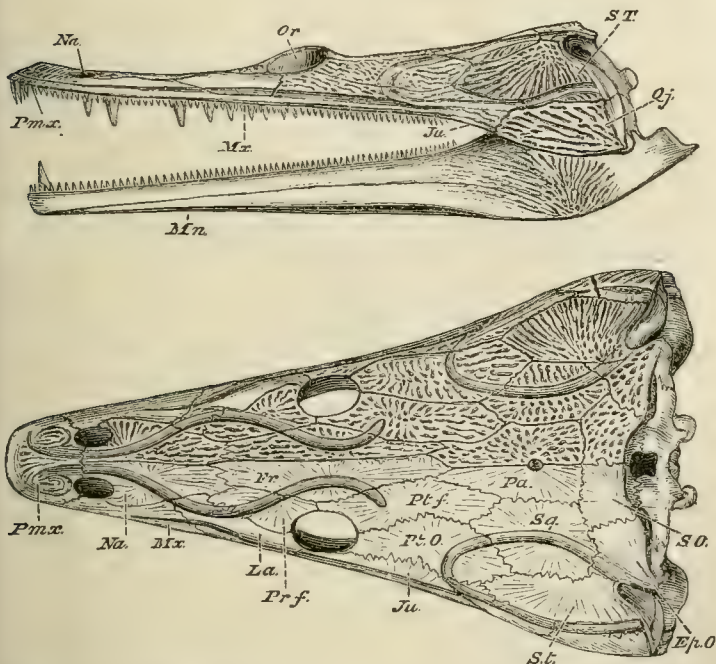


Fig. 56.—Side and upper views of the skull of *Trematosaurus*. The sculpture of the cranial bones is not represented in the lower half of the upper view of the skull, in order to show the sutures more distinctly.

The Labyrinthodont skull is further characterised by the development of distinct pointed epiotics, like those of fishes, and of paired ossifications, which take the place of the supra-occipital, as in many *Ganoidei*. In many Labyrinthodont

thodonts the articular element of the lower jaw is completely ossified.

Archegosaurus possessed branchial arches when young, and there can be little doubt that the other Labyrinthodonts resembled it in this respect.

The limbs and their arches are completely absent in the *Gymnophiona*, and, apparently, in the extinct *Ophiderpeton* of the Carboniferous formation. In all other *Amphibia* the pectoral arch and limbs are present, and, in all but *Siren*, the pelvic arch and limbs. The anterior and posterior limb arches consist of a continuous cartilage on each side, divided by an articular surface into a smaller dorsal moiety, and a more expanded ventral portion. The dorsal moieties are, respectively, the scapula and the ilium. The ventral moieties are divided by notches, or fontanelles, into two portions—an anterior, precoracoidal, or pubic part, and a posterior, coracoidal, or ischial part.

In the *Urodela* the scapula ossifies, and its ossification may be prolonged into the coracoid and precoracoid, but there is never more than one osseous mass. The clavicle is not developed. In *Siredon*, the *Derotremata*, and *Salamandridea*, the coracoids are received into grooves of the anterolateral edges of a cartilaginous sternum.

The pectoral arch of the Labyrinthodonts seems to have possessed representatives of clavicles in the lateral thoracic shields. The structure of the rest of the arch is not clear, but ossified coraco-scapular pieces seem to have existed.

In the *Batrachia*, the coraco-scapular cartilages are sometimes, as in the common Frog, firmly united in the middle line, and send forwards a median process, which becomes ossified, and is the *omosternum* (Fig. 57, *o.st.*). Behind, the coracoids articulate with a well-developed sternum (*st.*). Distinct ossifications arising on either side of the glenoidal cavity represent the scapula (*sc.*) and the coracoid (*cr.*), and the upper moiety of the scapula may be distinctly ossified as a supra-scapula (*s.sc.*). The coracoid is divided by a large membranous space or *fontanelle* into a proper coracoid (*cr.*), which lies behind the fontanelle; a persistently

cartilaginous *epicoracoid* (*e.cr.*), which bounds it internally; and a *precoracoid*, which limits it in front. Closely applied to the precoracoid is an ossification in membrane, which represents the clavicle.

The pelvic arch is attached (except in *Proteus*) to the extremity of the sacral rib. An iliac ossification is always developed; an ischial, in all but *Proteus*. The pubis does not

Fig. 57.

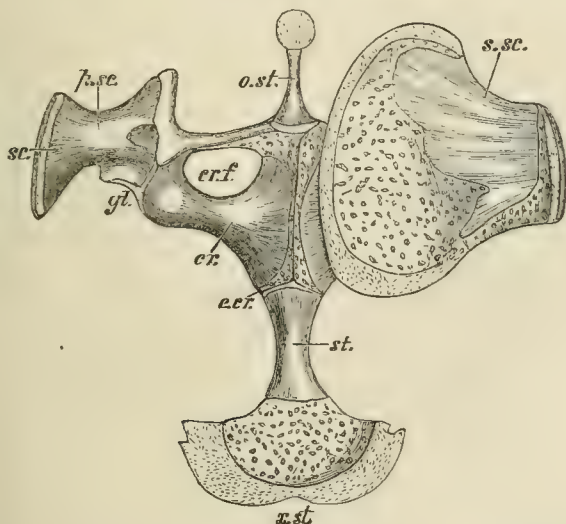


Fig. 57.—The sternum and pectoral arches of a Frog, seen from above. The left supra-scapula is removed:—*sc.* scapula; *s.sc.* supra-scapula; *p.sc.* precapular process; *cr.* coracoid; *e.cr.* epicoracoid; *cr.f.* coracoid fontanelle. The bar which bounds this in front is the precoracoid, and bears the clavicle: *o.st.* omosternum; *st.* sternum; *x.st.* xiphisternum.

appear to be regularly represented by a distinct ossification. In the *Batrachia* the applied flat faces of the expanded ventral divisions of the pelvic arch coalesce into a disc.

In the genus *Amphiuma*, the limbs have each either two or three digits. In *Siren*, the anterior limbs, which alone exist, are three or four-toed. In *Proteus*, the anterior

limbs are tridactyle, the posterior didactyle. *Menobranchus* has tetradactyle feet, while in the other *Urodela* the anterior limbs are tetradactyle, the posterior pentadactyle. The *Batrachia* have four digits, with or without a rudiment of another, in the fore-limb, and five in the hind-limb. In the perennibranchiate *Urodela*, the cartilages of the carpus and tarsus, which, except in *Proteus*, present little deviation from the typical number and arrangement (Fig. 11, p. 32), remain unossified; in the other *Urodela*, and in the *Batrachia*, they are for the most part ossified.

In the *Batrachia*, the posterior limbs are much longer than the anterior. The radius and the ulna in the fore-limb, and the tibia and fibula in the hind-limb, are fused together into one bone. The carpal bones no longer present the typical arrangement; and, in the tarsus, there are two proximal, greatly elongated, cylindrical bones, which take the place of a calcaneum and an astragalus, while the distal series is reduced.

The limbs of the Labyrinthodonts were feeble in comparison with the size of the body. In the genera *Archegosaurus*, *Keraterpeton*, *Urocordylus*, *Lepterpeton*, each foot possessed five digits, and the carpus and tarsus were unossified.

The *Amphibia* usually possess teeth on the vomers, premaxillæ, maxillæ, and dentary pieces of the mandible, but rarely on the palatine and pterygoid bones. The premaxillary and vomerine teeth are disposed in concentric semicircles, an arrangement which is very characteristic of the group. In the larvæ of the *Batrachia*, and in *Siren*, the premaxillæ and mandibles are ensheathed in horny beaks, as in the *Chelonia* and *Aves*. In addition, *Siren* has teeth in the vomers, and on the splenial piece of the mandible; *Menobranchus* and *Siredon* have pterygoid teeth. Many of the Labyrinthodonts possess palatine teeth. In some *Gymnophiona* the mandible has a double row of teeth, and there is an approximation to this structure in the Labyrinthodonts.

The teeth usually become ankylosed with the adjacent

bones. In existing *Amphibia* their structure is simple, but in the Labyrinthodonts, the parietes of the teeth, at a certain distance below the summit, become longitudinally folded, and each fold may be again longitudinally plaited, so that the transverse section of the tooth acquires a very complicated structure, the pulp-cavity being subdivided into a great many radiating and branching segments. The structure is similar in principle to that exhibited by the teeth of many of the *Ganoidei*. In many of the Labyrinthodonts, again, two of the anterior mandibular teeth take on the form of long tusks, which are received into fossæ, or foramina, of the upper jaw, as in most existing *Crocodylia*. The tongue is fixed to the floor of the mouth in *Urodela* and *Gymnophiona*, and remains undeveloped in the genera *Pipa* and *Dactylethra*, which have thence been termed *Aglossa*. In other *Batrachia*, the tongue, which is usually long, and fixed by its anterior end to the symphysis of the mandible, can be rapidly protruded and used as an organ of prehension. No distinct salivary glands have been observed in the *Amphibia*. Many male *Batrachia* have the mucous membrane of the floor of the mouth produced into pouches which can be distended with air.

The simple alimentary canal is usually short, and much longer in the larvæ (which are vegetable feeders) than in the adults. A gall-bladder is always present.

The heart presents two auricles, a single ventricle and a *bulbus arteriosus*. A venous sinus, the walls of which are rhythmically contractile, receives the venous blood from the body, and opens into the right auricle. In *Proteus*, *Menobranchus*, and *Siren*, the septum of the auricles is less complete than in the other *Amphibia*. The left auricle is much smaller than the right, and a single pulmonary vein opens into it. The interior of the ventricle is more like a sponge than a chamber with well-defined parietes. The walls of the long *bulbus arteriosus* contain striated muscular fibres, and are rhythmically contractile. Valves are sometimes placed at each end of it, and it may be imperfectly divided into two

cavities by an incomplete longitudinal partition. It terminates, upon each side, in either three, or four, trunks, which ascend upon the branchial arches. The most anterior of these trunks give off the carotid arteries, the most posterior the pulmonary arteries, and arteries to the integument; the middle trunks form the principal roots of the dorsal aorta.

In *Proteus*, where there are three branchial arches, the bulb of the aorta splits into two trunks; each of these divides, at first, into two branches, and then the posterior branch, on each side, again subdivides into two others. Thus, three pairs of aortic trunks are formed, which ascend upon the branchial arches. The two anterior pairs of aortic trunks pass directly into the roots of the dorsal aorta, but each gives off a vessel which enters one of the external gills, the blood from which is brought by an efferent canal into a higher part of the same aortic arch. The third aortic trunk, on each side, is interrupted, its lower part becoming the branchial artery of a gill-tuft. The blood is carried out of this branchia by a venous trunk, which opens into the root of the dorsal aorta, and is, in reality, merely the upper part of the third aortic trunk. The facts may be expressed in another way, by saying that the bases of the branchial artery and vein anastomose in the first two gills, but not in the third.

The adult *Axolotl* (*Siredon*) has four pairs of aortic trunks (Fig. 25, E, p. 91); the hindermost pair (VI.) gives off the pulmonary arteries, the three next (V., IV., III.) supply the external branchiæ; and the anterior trunk passes, above, into an artery which divides into hyoidean and carotid branches.

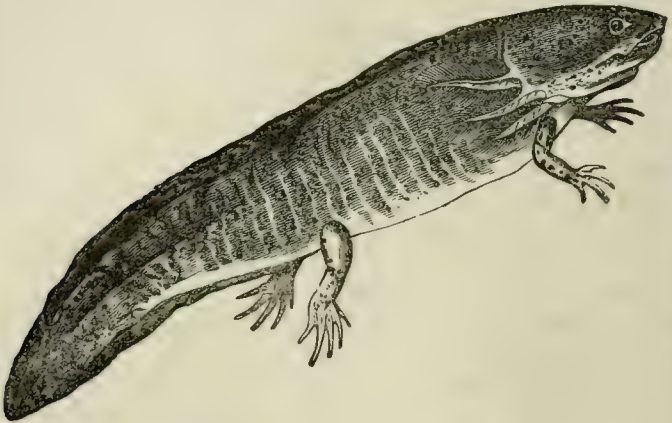
In *Salamandra* there are four pairs of aortic trunks in the adult, but the upper moiety of the first, on each side, is obliterated, and remains as a mere *ductus Botalli*. The fourth trunk gives off the pulmonary artery; some twigs for the œsophagus, and a few cardiac branches, next arise from it; and it then unites with the second and third to form the root of the dorsal aorta. The basal moiety of the first

trunk enlarges at its extremity, close to the angle of the mandible, into a spongy organ, the *carotid gland*, from which the carotid artery, and that for the supply of the hyoidean and oral regions, are given off.

In the adult Frog, the aortic bulb is separated by an incomplete longitudinal septum into two passages; and, at its extremity, divides into two trunks, each of which is partitioned internally into three passages. The middle, or *systemic*, passage passes directly into a trunk, which unites with its fellow beneath the spinal column into the dorsal aorta. The anterior, or *carotid*, passage ends, as in *Salamandra*, in a carotid gland and *ductus Botalli*; carotid, hyoidean, and oral branches being given off from the former. The hindermost, or *pulmo-cutaneous*, passage ends in the pulmonary and the cutaneous arteries, the anastomoses of these with the roots of the dorsal aorta being obliterated. The middle pair of aortic trunks thus exclusively constitute the origins of the dorsal aorta, and are the *permanent aortic arches*. The right aortic arch is wider than the left, especially towards their junction; as the left gives off, just before this point, a large cœliaco-mesenteric artery to the abdominal viscera. Each aortic arch gives off the subclavian and vertebral arteries of its side. Only venous blood passes into the pulmonary arteries of a Frog; while mixed blood enters the aortic arches, and is of a brighter arterial hue at the end, than at the beginning, of the systole. The blood in the carotid passages is always bright. The mechanical arrangements by which this is brought about have been beautifully analysed by Brücke, who shows:—first, that the spongy interior of the ventricle contains, in its base, a transversely elongated cavity, into which the auricles open, and which, by its right extremity, communicates with the ventricular opening of the aortic bulb; secondly, that the aortic bulb is imperfectly divided by a longitudinal septum, the upper left edge of which is attached, while its lower right edge is free; thirdly, that, of the two passages into which the aortic bulb is thus divided, the one on the right side of the septum ends in a chamber, in

which the carotid and systemic passages commence, while that on the left side similarly leads to the entrance to the pulmo-cutaneous passages; fourthly, that the carotid gland, in which the carotid passage ends, presents a mechanical obstacle to the flow of the blood through it; fifthly, that there is a valvular fold open towards the heart, in each systemic passage, which also offers a certain amount of mechanical resistance to the blood; and, sixthly, that after the blood has begun to flow through the bulb, it will gradually force the

Fig. 58.

Fig. 58.—The Axolotl (*Siredon*).

septum over to the left side, and so impede the flow into the pulmo-cutaneous passage.

Thus, when the auricular systole takes place, the right auricle sends its venous blood into that division of the ventricular cavity which lies nearest the opening of the bulb; and, when the ventricle contracts, the blood first driven into the bulb is wholly venous. This blood fills the passages on both sides of the septum, but finds a very much greater resistance to its exit on the right than on the left side. It therefore flows, at first, exclusively into the left division, and makes its way through the short pulmonary arteries into the lungs.

But, as the pulmonary vessels fill, the pressure on the two sides of the septum becomes equalized, and the systemic passages, which offer the next least resistance, fill with blood, which is now mixed, as it comes from the middle of the ventricle. Next, the septum, being driven over to the left side, prevents any more blood from going into the pulmo-cutaneous passage. At the end of the systole, the blood driven out by the ventricle is almost wholly that of the left auricle; and, by this time, the resistance in the systemic is as great as that in the carotid passages. Hence the latter fill, and send arterialized blood to the head.

The organs of respiration of the *Amphibia*, in the adult state, are either external branchiæ, combined with lungs, as in the perennibranchiate *Urodela*; or lungs only, as in the other *Urodela*, the *Batrachia*, the *Gymnophiona*, and, probably, the majority of the *Labyrinthodonta*.

In the perennibranchiate *Urodela*, the branchial arches (or some of them) are separated by open clefts (the number of which varies from four to two), throughout life, and three, branched, gills are continued by single stems into the integument, at the dorsal ends of the branchial arches. An opercular fold of the integument, in front of the gill-clefts, attains a considerable size in *Siredon* (Fig. 58), but does not cover the gills. The branchial arches themselves bear no branchial filaments. Other *Urodela* are devoid of external gills, but (as is the case in *Menopoma* and *Amphiuma*) present one or two small gill-clefts on each side of the neck, and are thence called *Derotremata*. The rest of the *Urodela*, and all the *Batrachia* and *Gymnophiona*, are devoid of both external gills and gill-clefts, in the adult state.

In all the *Amphibia*, a glottis, placed on the ventral wall of the œsophagus, opens into a short laryngo-tracheal chamber with which two pulmonary sacs are connected, either directly, or by the intermediation of bronchi (as in the *Aglossa*), or by a trachea (as in the *Gymnophiona*). The walls of the pulmonary sacs are more or less sacculated. In most *Amphibia* the lungs are equal in size; but in the

snake-like *Gymnophiona*, the right is much smaller than the left. In *Proteus*, the pulmonary blood is not all returned to the heart, some of it entering the veins of the trunk. Aërial respiration is effected, in the *Amphibia*, by pumping the air from the oral cavity into the lungs. To this end the mouth is kept shut, and ingress and egress to the air is given by the nasal passages, which always open immediately behind the vomers, at the anterior part of the roof of the mouth. These passages being open, and the hyoidean

Fig. 59.

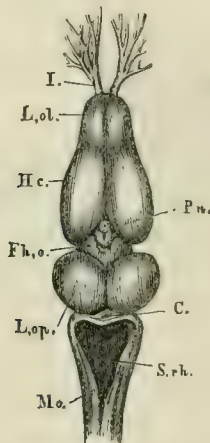


Fig 59.—The brain of *Rana esculenta*, from above, magnified four times:—*L. ol.*, the rhinencephalon, or olfactory lobes, with, *I.*, the olfactory nerves; *Hc.*, the cerebral hemispheres; *Fh. o.*, the thalamencephalon with the pineal gland, *Pn.*; *L. op.*, optic lobes; *C.*, cerebellum; *S. rh.*, the fourth ventricle; *Mo.*, medulla oblongata.

apparatus depressed, the air fills the cavity of the mouth. The external nostrils are then shut, and the hyoidean apparatus being raised, the air is forced, through the open glottis, into the lungs.

All *Amphibia* possess an urinary bladder, which opens into the cloaca, and does not receive the ureters. The kidneys of the *Amphibia* appear, like those of fishes, to be persistent Wolffian bodies.

In the brain of the *Amphibia* the cerebellum is always very small, and represented by a mere band; the cerebral hemispheres are elongated, and contain ventricles. In *Proteus* the mesencephalon is very indistinctly marked. The optic nerves form a chiasma.

As in fishes, the pneumogastric gives off a lateral nerve, which runs along the sides of the body.

The eyes are very small, and covered by the integument, in *Proteus*, the *Gymnophiona*, and the genus *Pipa*. The perennibranchiate and derotreme *Urodela* have no eyelids; but most *Batrachia* have not only a well-developed upper eyelid, but a nictitating membrane, moved by special muscles.

All *Amphibia* possess a fenestra ovalis with a cartilaginous, or osseous, columelliform stapes, the expanded proximal end of which is fixed to the membrane of the fenestra. In many *Batrachia*, if not in all, there is a fenestra rotunda, though the presence of a distinct cochlea has not been ascertained. The *Urodela*, the *Gymnophiona*, and the *Pelobatidea*, among the *Batrachia*, have no tympanic cavity, nor membrane. In the other *Batrachia* there are tympanic cavities communicating freely with the throat. Each is closed externally by a tympanic membrane, with which the outer extremity of the stem of the stapes is connected. In the *Aglossa*, the two tympanic cavities communicate with the mouth by a single Eustachian aperture; and the outer end of the stapes expands into a great cartilaginous plate coextensive with the tympanic membrane.

The ducts of the reproductive organs of the *Amphibia*, like those of the *Ganoidei*, always communicate directly with the urinary ducts: and, as in most *Ganoidei* and all *Elasmobranchii*, the proximal end of the oviduct is open, and communicates with the peritoneal cavity. The male has no penis, unless a papillary elevation of the wall of the cloaca may represent such an organ. The testes of the male *Amphibia* are composed of tubules, and *vasa efferentia* convey the contents of these away. In the *Urodela*, the *vasa efferentia* of each testis enter the inner side of the corresponding kidney, and traverse it, leaving its outer side to enter a *genito-*

urinary duct, which lies on the outer side of the kidney, ends blindly in front, and opens behind into the cloaca. The uriniferous tubuli also pass directly from the outer margin of the kidneys into the genito-urinary duct. In the *Batrachia* there is likewise a genito-urinary duct, and the *vasa efferentia* run to the inner edge of the kidney and enter it. In *Bombinator igneus* and *Discoglossus pictus*, the genito-urinary duct receives the urinary products and the spermatozoa, in the same way as in the *Urodela*. But, in the Frogs and Toads, the urinary tubuli are gathered together into a special small canal which opens into the genito-urinary duct near its termination in the cloaca, and the *vasa efferentia* pour their contents into this canal. Under these circumstances, the part of the genito-urinary duct which lies beyond the renal canal may become obliterated, as in the Frogs; or may persist, and play the part of a *vesicula seminalis*, as in the Toads.

In the female *Amphibia*, the kidneys have, as in the male Frogs and Toads, a renal canal which opens into the lower part of the oviduct.

It would appear from these facts that the oviduct in the female, and the genito-urinary ducts in the male, *Amphibia* represent both the Wolffian and the Müllerian ducts of the higher *Vertebrata*.

In most *Amphibia* the ova are impregnated and hatched outside the body, but internal impregnation and incubation occur in some of the *Urodela*. In *Pipa* the eggs are hatched in pouches of the dorsal integument, while the male *Alytes* carries them twisted in strings round his legs.

When hatched, the young are devoid of respiratory organs and of limbs, and are provided with a long tail, by means of which they swim about. Branchial clefts soon make their appearance; and ciliated external branchial plumes, like those of the perennibranchiate *Urodela*, are developed. A pair of suckers are sometimes formed upon the under-surface of the mandibular region, and the jaws acquire horny sheaths.

A broad opercular membrane is developed in front of the

branchial aperture, and, in the *Batrachia*, extends over and eventually covers the gills, a rounded aperture persisting for a certain time only on the left side. The anterior pair of limbs is developed before the posterior, but in the Frog they are not so soon visible, being hidden by the opercular membrane.

The lungs make their appearance as diverticula of the ventral wall of the œsophagus. The nasal sacs are at first mere

Fig 60.

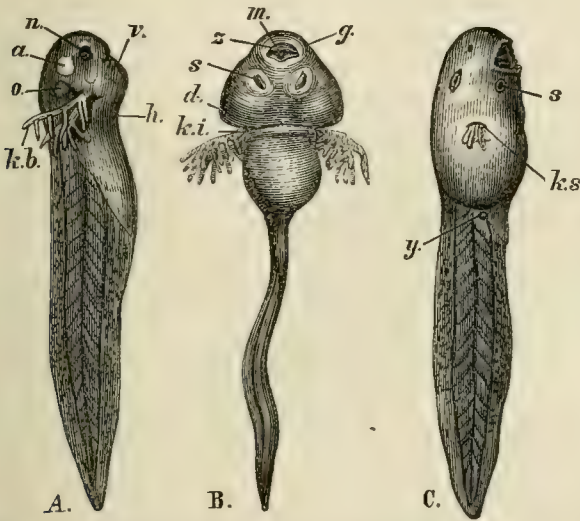


Fig. 60.—A. B., Tadpoles with external branchiæ: *n*, nasal sacs; *a*, eye; *o*, ear; *kb*, branchiæ; *m*, mouth; *z*, horny jaws; *s*, suckers; *d*, opercular fold.
C., a more advanced Frog's larva: *y*, the rudiment of the hind limb; *ks*, the single branchial aperture. The figure has not been reversed, so that this aperture appears to lie on the right side instead of the left.

cæcal involutions of the integument, but nasal passages communicating with the mouth are soon formed, and both aërial and aquatic respiration are completely established.

In the *Batrachia*, as development proceeds, the external branchiæ disappear, and are succeeded, functionally, by short branchial filaments developed upon the whole length of each of the branchial arches, of which there are four.

Before the development of the lungs the heart has only a single auricle; afterwards, the auricle becomes divided into two. The aortic arches, at first, pass along the visceral and branchial arches to the dorsal aorta, as in other vertebrate embryos. When external gills are developed, each receives a loop from the corresponding arch, much as in *Proteus*.

When the internal gills of the *Batrachia* appear, each aortic arch which belongs to a branchial arch splits into two trunks, —one which remains directly connected with the cardiac aorta, and another which opens into the dorsal aorta. The vessels of the branchial filaments constitute loops between these afferent and efferent trunks, which always remain united by anastomoses. When branchial respiration ceases, and the branchial processes and their vessels disappear, the anastomoses dilate; the direct communication between the afferent and efferent trunks of the second pair of internal branchiæ is re-established; and they become the permanent arches of the aorta. The anterior branchiæ are replaced by the carotid glands, and their afferent vessel is the carotid passage of the adult. The afferent and efferent trunks of the third pair of branchiæ are converted into the stem of the cutaneous artery, and the afferent trunk of the fourth pair of branchiæ into that of the pulmonary artery. The diagram (Fig. 25, p. 91) is intended to make these changes, and the relations of the various trunks to the embryonic aortic arches, intelligible.

The alimentary canal of the Tadpole is, at first, long, and coiled up into a close spire, like a watch-spring, in the abdomen, but its length becomes relatively less as age advances. At the same time, the diet changes from vegetable to animal—the young tadpole being chiefly herbivorous, the adult, insectivorous.

In the *Urodela* the tail persists, and develops complete vertebræ; but, in the *Batrachia*, the caudal part of the spinal column disappears, for the most part, together with the rest of the tail, and only the basal portion of the notochord becomes converted into the urostyle, which eventually ankyloses with the two hindermost neural arches.

CHAPTER V.

THE CLASSIFICATION AND THE OSTEOLOGY OF THE
REPTILIA.

The province **Sauropsida** is divisible into the two classes, *Reptilia* and *Aves*.

All **Reptilia**, so far as their organization is known to us, are distinguished from *Aves* by the following characters:—

1. The exoskeleton is composed of horny plates (scales), or bony plates (scutes), never of feathers.

2. The centra of the vertebræ may be amphicœlous, proœlous, opisthocœlous, or may have nearly flat articular faces; but these faces are spheroidal or oval, and are never cylindroidal, even in the cervical region.*

3. When reptiles possess a sacrum, the sacral vertebræ have large expanded ribs, with the ends of which the ilia articulate.

4. The sternum is rhomboidal; and, when many ribs are connected with it, the hindermost of these are attached to a single, or double, median backward prolongation (except, perhaps, in the *Pterosauria*). The sternum may be converted into cartilage bone, but (with the possible exception of the *Pterosauria*) is never replaced by membrane bone, and does not ossify from two, or more, definite centres.

5. When an interclavicle exists, it remains distinct from the clavicles.

6. The manus contains more than three digits (? *Dinosauria*), and the three radial digits, at fewest, have claws.

* The articular faces of the vertebræ of some *Pterosauria* are very much elongated transversely.

7. In all existing reptiles, the ilia are prolonged further behind the acetabulum, than in front of it; and the inner wall of the acetabulum is wholly, or almost completely, ossified. The pubes are directed downwards and forwards, and, like the ischia, meet in a ventral symphysis. In the extinct *Dinosauria*, the pelvis exhibits forms transitional between the reptilian and the ornithic arrangement.

8. The digits of the pes are not fewer than three; and the metatarsal bones are not ankylosed together, or with the distal tarsal bones.

9. In existing reptiles not fewer than two aortic arches (a right and a left) persist. Two arterial trunks are given off from the right ventricle, or the part of the single ventricle which answers to it. The venous and arterial currents of the blood are connected, either in the heart itself, or at the origins of the aortic arches.

10. The blood is cold. There are usually two semilunar valves at the origins of the aortic and pulmonary trunks.

11. The *corpora bigemina* lie upon the upper surface of the brain.

In *Aves*, on the contrary:—

1. The exoskeleton consists of feathers. Ossifications of the dermis are rare, and never take the form of scutes.

2. In all recent birds, the centra of the cervical vertebræ, at least, have subcylindrical articular faces. If, as in some birds, the faces of the centra of the other vertebræ are spheroidal, they are opisthocœlous, which is the rarest arrangement among reptiles.

3. The proper sacral vertebræ of birds—that is to say, those between, or through, the arches of which the roots of the sacral plexus pass—have no expanded ribs abutting on the ilia.

4. The sternum has no costiferous median backward prolongation, all the ribs being attached to its sides. The cartilaginous sternum is replaced, in the adult, by membrane bone, and ossifies from two, to five or more, centres.

5 When an interclavicle exists it is confluent with the clavicles.

6. The manus does not contain more than three digits, and not more than the two radial digits have claws.

7. The ilia are greatly prolonged in front of the acetabulum, the inner wall of which is membranous. The pubes and ischia are directed backwards, more or less parallel with one another, and the ischia never meet in a ventral symphysis.

8. The astragalus sends up a process on to the front face of the tibia, and early ankyloses with the latter bone. In this character, Birds differ from all existing Reptiles. The foot contains not more than four digits. The first metatarsal is, almost always, free, shorter than the rest, and incomplete above. The other three are ankylosed together, and with the distal tarsal bone, to form a tarso-metatarsus.

Some of the extinct *Dinosauria* closely resembled birds in the form of the tibia and astragalus, the immoveable union of the two bones, and the reduction of the number of the digits.

9. Only one aortic arch, the right, is present. Only one arterial trunk, the pulmonic, is given off from the right ventricle. The arterial and venous currents communicate only by the capillaries.

10. The blood is hot. There are three semilunar valves at the origins of the aortic and pulmonary trunks. In all existing birds the extremities of the chief pulmonary passages terminate in air-sacs. There is a rudiment of this structure in the Chamæleons, and the extinct Pterodactyles very probably possessed such sacs.

11. The *corpora bigemina* are thrown down to the sides and base of the brain.

The **Reptilia**.—This class is divisible, by well-defined characters, into the following groups:—

A. The dorsal vertebræ (which, like all the other vertebræ, are devoid of transverse processes) are not moveable upon one another, nor are the ribs moveable upon the vertebræ (*Pleurospondylia*). Most

of the dorsal vertebræ and ribs are restrained from motion by the union of superficial bony plates, into which they pass, to form a *carapace*.

Dermal bones, usually nine in number, one of which is median and symmetrical, and the others lateral and paired, are developed in the ventral walls of the thorax and abdomen, forming a *plastron*.

I.—*Chelonïa*.

B. The dorsal vertebræ (which have either complete, or rudimentary, transverse processes), are moveable upon one another, and the ribs upon them. There is no *plastron*.

a. The dorsal vertebræ have transverse processes, which are either entire, or only very imperfectly divided into terminal facets (*Erpetospondylia*).

a. The transverse processes are long; the limbs well developed, with the digits united by the integument into a paddle; the sternum and sternal ribs are absent or rudimentary.

II.—*Plesiosauria*.

b. The transverse processes are short, and sometimes rudimentary; the limbs present or absent; when they are fully developed, the digits are free, and there is a well-developed sternum with sternal ribs.

a. A pectoral arch and urinary bladder.

III.—*Lacertilia*.

b. No pectoral arch, and no urinary bladder.

IV.—*Ophidia*.

b. The dorsal vertebræ have double tubercles in the place of transverse processes (*Perospondylia*). The limbs are paddle-like.

V.—*Ichthyosauria*.

c. The anterior dorsal vertebræ have elongated and divided transverse processes, the tubercular being longer than the capitular division (*Suchospondylia*).

a. With only two vertebræ in the sacrum.

VI.—*Crocodylia*.

b. With more than two vertebræ in the sacrum.

a. The manus without a prolonged ulnar digit.

1. The hind limb saurian.

VII.—*Dicynodontia*.

2. The hind limb ornithic.

VIII.—*Ornithoscelida*.

b. The manus having an extremely prolonged ulnar digit.

IX.—*Pterosauria*.

I shall describe the exoskeletal, endoskeletal, and dental systems of the chief groups of the *Reptilia*, under the several heads here enumerated, and I shall then give an

account of these systems in *Aves*. But modifications in the myology, neurology, splanchnology, and development of the two classes may be conveniently considered together, under those several heads, in another chapter.

I. The CHELONIA.—The Tortoises and Turtles are those reptiles which most nearly approach the *Amphibia*, though they depart very widely not merely from the amphibian, but from the ordinary vertebrate type, in some respects.

A horny epidermic exoskeleton is absent in the soft Tortoises (*Trionyx*), the bodies of which are covered by a soft integument; but, in the other *Chelonia*, the epidermis is modified into horny plates, which constitute the so-called "Tortoiseshell," and have in general a very definite arrangement. The dorsal surface of the body presents three series of *central* plates, of which five are in the middle and four upon each side (4, 5, 4). The margins of the dorsal shield are guarded by twenty-four or twenty-five plates: one on the middle line in front, called *nuchal*; one or two behind, *pygal*; and eleven on each side, *marginal*. The ventral shield sometimes presents an anterior median scale; but, more usually, there are six pairs, disposed symmetrically. It will be seen, presently, that these epidermic plates by no means correspond with the bony dermal ossifications. In addition to these principal plates, smaller scale-like patches of horny epidermis are developed on other parts of the body, and on the limbs.

The dermal ossifications may best be described in connection with the endoskeleton.

The presacral vertebræ are few in number. In the Green Turtle (*Chelone midas*) there are eight cervical, and ten dorsal, in front of the sacrum, which is composed of two vertebræ. In all the cervical vertebræ the neurocentral sutures persist; there are no transverse processes, or ribs, and the spines are low or obsolete. The first vertebra, or atlas, is a ringlike bone, composed of three pieces, one basal and two superolateral. The second is a true axis vertebra, the central part of the centrum of the atlas ossify-

ing apart, as an odontoid bone, and attaching itself to the front face of the centrum of the second vertebra.

The other cervical vertebræ are remarkable for the singular variety in the disposition of their articular cups and balls.

Fig 61.

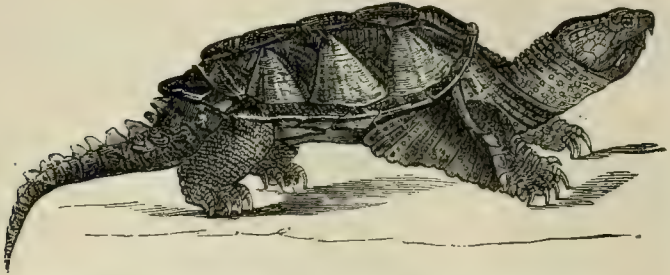


Fig. 61.—The Alligator Terrapene (*Chelydra Serpentina*).

Thus, the third is opisthocœlous; the fourth, biconvex; the fifth, procœlous; the sixth, also procœlous, but the posterior face is nearly flat, and very broad; in the seventh, both the anterior and the posterior faces are very broad and flattened, the posterior being the more convex. The eighth cervical vertebra is procœlous, and differs from the rest by the expansion of its neural spine, and by the arching backwards of its postzygapophyses over the convex prezygapophyses of the first dorsal vertebra, upon which the former play backwards and forwards.

All the cervical vertebræ are very freely moveable upon one another, and confer great flexibility on the neck. In striking contrast with this arrangement, the ten following vertebræ have flattened faces, firmly united by cartilage. If any one of these vertebræ, from the second to the ninth, be examined, it will be found that the elongated centrum is only loosely united with the neural arch, and that the summit of the neural arch is continuous with a broad flat plate of bone, which forms one of the eight median elements of the carapace, or *neural plates* (Fig. 62, V).

There are no transverse processes, but a rib is articulated

between the centrum and the neural arch. At a short distance from its attachment, this rib passes into a broad plate of bone, which extends upwards to unite suturally with the neural plate; and, in front and behind, becomes similarly connected with preceding and succeeding *costal plates*. The rib may be traced along the under-surface of the costal plate, beyond the outer margin of which it protrudes; and its free extremity is received into a pit in an elongated prismatic dermal ossification, which forms one of a series of *marginal plates* (Fig. 62, *M*).

The first dorsal vertebra differs from the others in many respects. The anterior face of its centrum is concave, and looks downwards and forwards, while its prezygapophyses

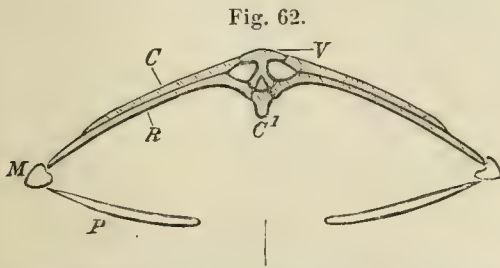


Fig. 62.—Transverse section of the skeleton of *Chelone midus* in the dorsal region:—*C'*, centrum; *V*, expanded neural plate; *C*, costal plate; *R*, rib; *M*, marginal plate; *P*, lateral element of the plastron.

are much prolonged, in order to articulate with the convex posterior face of the centrum and prolonged postzygapophyses of the last cervical vertebra. The spinous process of this vertebra does not pass into the bony *nuchal* plate of the carapace, which lies above it (Fig. 63, *Nu*), and its rib does not expand into a costal plate, but becomes connected with the costal plate of the second dorsal vertebra. The neural arch of this vertebra is shorter, from before backwards, than its centrum; and the neural arch of the second dorsal vertebra extends forwards and overlaps the centrum of the first, for the space thus left unoccupied. The rib of the second vertebra is also carried forward, and articulates

not only with its own centrum and neural arch, but with the posterior edge of the centrum of the first vertebra.

These arrangements are repeated by the other dorsal vertebræ and ribs, up to the ninth inclusive; but, in the tenth, the neural arch occupies only the anterior half of the centrum of its own vertebra, and the rib is very small, and has no costal plate.

The union of the neural and costal plates of the eight

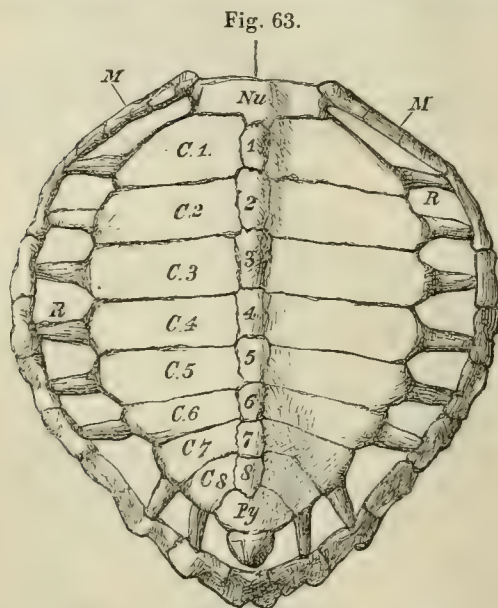


Fig. 63.—Dorsal view of the carapace of *Chelone midas*:—*Nu*, nuchal plate; *M*, marginal plates; *R*, ribs; 1—8, neural plates; *C.1*—*C.8*, costal plates; *Py*, pygal plates.

dorsal vertebræ, from the second to the ninth inclusively, gives rise to the principal part of the *carapace*, or dorsal moiety of the bony shell of the Chelonian. The first and the tenth dorsal vertebræ contribute nothing to the *carapace*, their small ribs merely becoming attached to the costal plates behind and before them.

In front of the first neural plate, and joined with it by a

serrated suture, lies a large *nuchal* plate (Fig. 63, *Nu*), which forms the anterior median boundary of the carapace. This nuchal plate sends down from its under-surface a median process, which is joined by ligament with the expanded neural spine of the eighth cervical vertebra. Behind the eighth neural plate, three other median *pygal* plates (Fig. 63, *Py*) succeed one another. The anterior two of these are united by sutures with the eighth neural and costals, and with one another; but the third is connected externally only with the marginal plates. All three are perfectly distinct from the subjacent vertebræ.

The sides of the carapace are completed, between the nuchal and pygal plates, by eleven marginal plates (Fig. 63, *M*) on each side. Eight of these receive the ends of the ribs of the second to the ninth dorsal vertebræ, in the way already described.

There is no doubt that the nuchal, the pygal, and the marginal plates of the carapace are membrane bones, developed in the integument, quite independently of either the vertebræ or the ribs. But it appears that the neural plates and the costal plates exist, as expansions of the cartilages of the neural spines and ribs of the primitive vertebræ, before ossification takes place. This being the case, the neural and costal plates are vertebral and not dermal elements, however similar they may seem to be to the nuchal, pygal, and marginal plates. But this ultimate similarity of bones of totally distinct origin is not more remarkable here, than in the case of the skull, where the parietal and frontal bones stand in the same relation to the supra-occipital bone, as the nuchal and pygal plates do to the neural plates of the carapace.

There are no sternal ribs, and no trace of a true sternum has yet been discovered in the *Chelonia*. The plastron is wholly composed of membrane bones, which are developed in the integument, and lie, in part, in front of, and, in part, behind, the umbilicus of the fœtus. The latter, at least, therefore belong to the abdomen, and the plastron is a thoracico-abdominal structure.

In the Turtle the plastron consists of nine pieces—one median and anterior, four lateral and paired (Fig. 64). These pieces may be named—the median, *entoplastron*; the first lateral, *epiplastron*; the second, *hyoplastron*; the third, *hypoplastron*; and the fourth, *xiphiplastron*.* The *entoplastron* and the two *epiplastra* correspond with the median and lateral thoracic plates of the Labyrinthodont *Amphibia*,

Fig. 64.

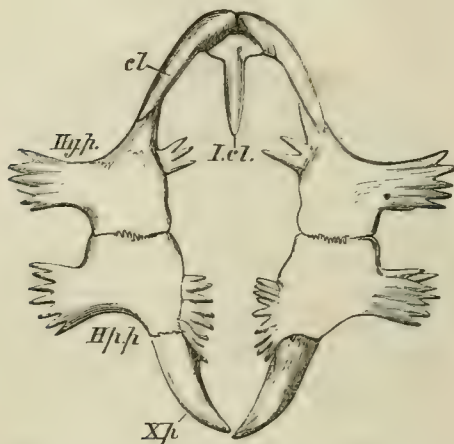


Fig. 64.—The plastron of the Green Turtle (*Chelone midas*):—*I.cl.*, interclavicle; *cl.*, clavicles; *Hy.p.*, hyoplastron; *Hp.p.*, hypoplastron; *Xp.*, xiphiplastron.

and very probably answer to the interclavicle and clavicles of other *Vertebrata*.

The sacrum consists of two vertebræ. The expanded sacral ribs are not ankylosed with the centra and arches of their vertebræ.

The tail is flexible, and consists of procœlous vertebræ. The anterior caudal vertebræ have no transverse processes,

* Believing the plastron to answer to the sternum of other *Vertebrata*, anatomists have termed these elements of the

plastron *entosternum*, *episternum*, *hyosternum*, *hyposternum*, and *xiphisternum*.

but possess ribs which may not become ankylosed with the centra. Thus the tail and the neck are the only regions of the spinal column of a Chelonian which are flexible.

In the skulls of the *Chelonia* all the bones, except the mandible and the hyoidean arch, are immoveably united together.

In the occipital segment of the adult, the supra-occipital is united with the epiotic, but the ex-occipital usually remains perfectly distinct from the opisthotic. The basi-

Fig. 65.

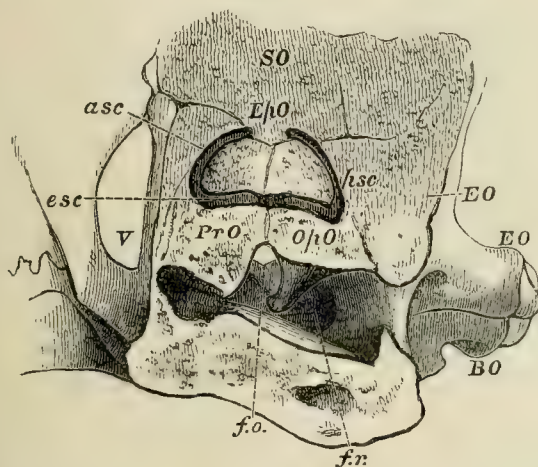


Fig. 65.—External view of a section of the auditory region of the skull in a Turtle (*Chelone midas*):—*f.o.*, fenestra ovalis; *f.r.*, fenestra rotunda; *esc*, *asc*, *psc*, external, anterior, and posterior semicircular canals.

sphenoid is large and distinct. The alisphenoidal region remains unossified; but the large parietals send down a prolongation on each side, which plays the part of an alisphenoid. Neither the presphenoid nor the orbitosphenoids are represented by bone, but there are large frontals. In the periotic capsule the large pro-otic and the opisthotic (Cuvier's *occipitale externe*) remain distinct bones, but the epiotic unites with the supra-occipital.

The naso-ethmoidal cartilage largely persists; but it

becomes covered above and at the sides by a large bone, which meets with its fellow in the middle line, and occupies the position of the lachrymal, prefrontal, and nasal.

Fig. 66.

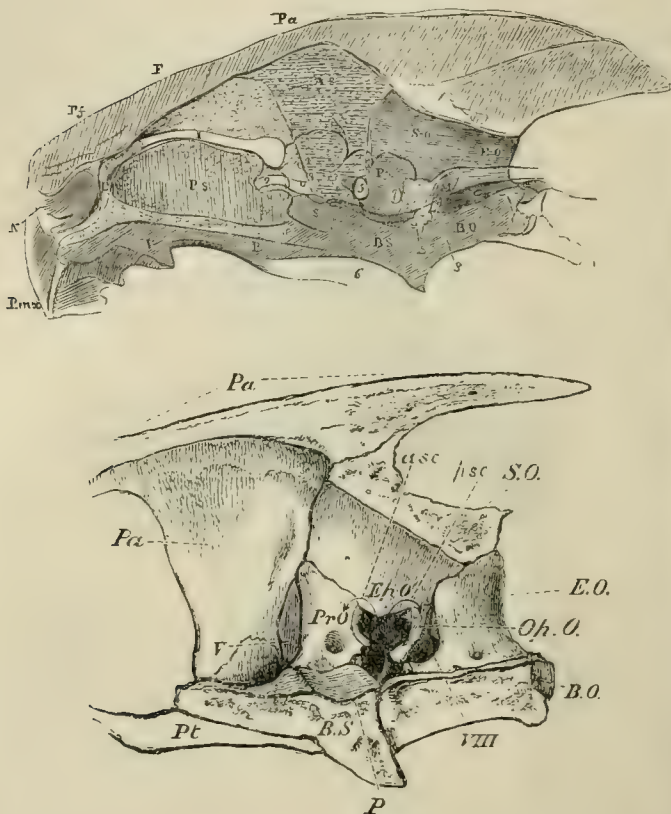


Fig. 66.—Longitudinal sections of the skull of the Turtle. The upper figure represents the entire skull with the outline of the brain *in situ*; the lower gives a larger view of the inner face of the bones of the posterior moiety of the skull.

The premaxillæ are small, and usually united together. There is a single vomer, produced downwards into a median

internasal plate, which expands below, and joins the palatine plate of the palatine bone.

Above the posterior and upper part of the orbit lies a postfrontal, and, behind this, a squamosal is placed at the sides of the periotic capsule, and above the large quadrate bone. The postfrontal and squamosal occupy the upper part of the temporal region of the skull. Below these, a quadrato-jugal and a jugal connect the quadrate bone with the large maxilla.

In some genera, as *Chelone* and *Chelydra*, the skull possesses a sort of false roof, formed by the expansion of a median ridge, developed from the parietal bones, into a broad plate, which becomes suturally united with the postfrontals and squamosals.

The quadrate bone is firmly fixed to the sides of the periotic region of the skull, and ends below in a strong condyle for the mandibles. The long and broad pterygoid bones unite with one another in the middle line, and are firmly fixed to the base of the skull, as in *Plesiosauria* and *Crocodylia*. They unite only with the upper part of the quadrate bone, as in the latter reptiles.

The palatines are firmly united with the pterygoids, behind, and with the vomer above and in front. They are prolonged downwards, and develop a short palatine plate, which unites with the produced and expanded lower edge of the vomer, to bound the posterior nares. (Fig. 67. *Vo*, *N¹*.)

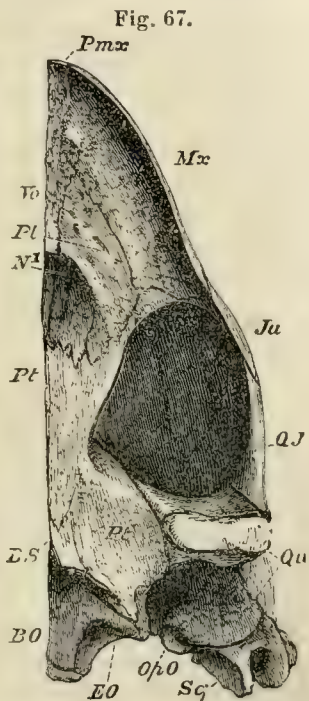


Fig. 67.—The left half of the underside of the skull of a Turtle: *N¹*, posterior nares.

The dentary pieces of the two rami of the mandible are represented by one bone, as in Birds.

The hyoidean apparatus consists of a broad plate of cartilage with two longer anterior, and two shorter posterior, ossified cornua. The cornua have no direct connection with the skull.

The pectoral and pelvic arches appear, at first sight, to have a very anomalous position in the *Chelonia*, inasmuch as they seem to be situated inside, and not outside, the skeleton of the trunk. But since the plastron does not answer to the sternum of other *Vertebrata*, but to part of the dermal skeleton, the anomaly does not really exist on the ventral side. And, as to the dorsal side, the pectoral and pelvic arches of the fœtal Chelonian are at first situated in front of, or behind, and external to, the ribs, as in other *Vertebrata*. It is only as development advances, that the first costal plate extends over the scapula, and the hinder costal plates over the ilium.

The pectoral arch is ossified in such a manner that the scapula and precoracoid form one bone, while the coracoid remains distinct. The free ends of the coracoid and precoracoid are usually connected together by a fibro-cartilaginous band, representing the epicoracoidal cartilage in *Lacertilia*. There is no clavicle, unless the epiplastra and entoplastron represent that bone.

The carpus of the *Chelonia* contains nine primary ossicles, as in the *Urodela*—three in the proximal row, one central, and five distal—and these almost always remain distinct.

There are five digits, the numbers of the phalanges of which present no constancy.

The pelvis contains the usual bones. The pubes (which are very large) and the ischia meet respectively in a long symphysis; and, sometimes, the *foramina obturatoria* are completed, internally, by the meeting of the bony pubes and ischium of each side in the middle line.

The pelvis is not usually united with either the carapace or the plastron, but in *Chelys*, *Chelodina*, and some other

genera, the ilia unite by synchondrosis, or ankylosis, with the last costal plate, and the pubis and ischium with the xiphisternal plates, so that the pelvis becomes firmly fixed between the carapace and plastron.

The proximal row of the tarsal bones consists usually of an *astragalus*, formed by the union of the *tibiale* and *intermedium*, and of a *fibulare* or *calcaneum*. In *Chelydra* there is a *centrale*. In *Chelone*, *Emys*, *Testudo*, and *Trionyx*, the *centrale* is united with the *astragalus*; and in *Emys*, the *calcaneum* coalesces into the *astragalus*, so that the proximal portion of the tarsus consists of one bone. In the distal series the two fibular tarsals are united into a cuboid bone. There are five digits, and the fifth metatarsal has a peculiar form, as if bent upon itself at right angles, in the middle of its length.

In the *Testudinea* there are only two phalanges in each digit of the pes.

The *Chelonia* are divisible into the *Testudinea*, the *Emydea*, the *Trionychoidea*, and the *Euereta*.

1. The *Testudinea* have the horny jaws naked and cutting, or denticulated. The eyes are lateral, the tympanic membrane is exposed, the short and thick limbs have the toes (all of which have nails) bound together by the integument. The horny plates of the carapace and plastron are well developed.

The Land Tortoises belong to this division. The carapace is usually very convex, and sometimes (as in the genus *Pyxis*) the anterior part of the plastron is moveable, and can be shut up like a lid. In *Cinyxis*, the hinder part of the carapace is similarly mobile.

2. The *Emydea* have, usually, horny cutting jaws, uncovered by lips; the tympanum exposed, and the limbs more slender than in the *Testudinea*, with five-clawed digits, which are only united by a web. The horny plates of the carapace and plastron are well developed.

These are the River and Marsh Tortoises. They are further divisible into two groups, in the one of which, the *Terrapenes*,

the pelvis is free, the neck bends in a vertical plane, and the head is almost completely hidden by the carapace when retracted (*Emys*, *Cistudo*, *Chelydra*). In *Cistudo*, *Cinosternum*, and *Staurotypus*, the hinder part of the plastron is mobile. In the other division, the *Chelodines*, the pelvis is fixed to the carapace and plastron, the neck bends sideways, and the head cannot be completely retracted under the carapace (*Chelys*, *Chelodina*).

3. In the *Trionychoidea* (Mud or Soft Tortoises), the jaws have an external cutaneous lip; the nasal organ is prolonged into a kind of snout, and the head is covered by a soft skin without any visible tympanic membrane. The limbs are flattened, somewhat finlike, and pentadactyle; but only three digits have nails. The integument develops no horny plates, but is quite soft. The costal plates are shorter than in other *Chelonia*, and the marginal ossicles are either rudimentary or absent.

The genera *Gymnopus*, *Cryptopus*, and *Cycloderma*, constitute this division; they all inhabit the fresh waters of hot latitudes.

The *Euereta*, or Turtles, have an exposed, hooked, horny beak, with a blunt snout. The tympanum is hidden by the integument. The limbs, of which the anterior pair are much the longer, are converted into paddles, the digits being much flattened and elongated, and immoveably united together by the integument; only one or two nails are developed. The skin of the body is either rugose (*Sphargis*), or covered with thick epidermic plates (*Chelone*).

The two genera composing this group inhabit the seas of warm climates.

The *Chelonia* are first known to occur, with certainty, in the Lias. The older forms are, in many respects, intermediate between the *Euereta* and the *Trionychoidea*, but present no approximation to any other order of *Reptilia*.

II. The PLESIOSAURIA.—In some of the *Plesiosauria*, the head, not more than one-twelfth or one-thirteenth of the length of the body, is mounted upon a neck as long, in

proportion, as that of a Swan; but in others, the head is large and massive, and the neck much shorter. The hind limbs are longer than the fore limbs, and there is a comparatively short tail. The integument was certainly devoid of any scutes; and was, probably, smooth and possessed no scales.

The cervical vertebræ may exceed forty in number, though they are generally fewer; and as none of the ribs appear to have been connected with the sternum, or if such connection existed it cannot now be traced, it becomes difficult to distinguish between cervical and dorsal vertebræ, and one is obliged to have recourse to some method of separating the two, differing from that already adopted. Now, in these animals, the neurocentral suture persists for a considerable period, if not throughout life; and the surfaces for the articulation of the cervical ribs, which are at first altogether below the neurocentral sutures, gradually rise, in the posterior parts of the neck, until they first are cut by, and then rise above, the suture. It is very convenient, and harmonizes very well with some facts to be mentioned by-and-by in the structure of the *Crocodylia*, to take the last of the vertebræ in which the costal articular surface is cut by the neurocentral suture, as the last of the cervical series.

The two anterior cervical vertebræ, as thus defined, constitute the atlas and axis, and are frequently ankylosed together. The centra of the other cervical vertebræ have slightly concave anterior and posterior surfaces; well-developed neural arches; anterior and posterior oblique processes, or zygapophyses, of the ordinary character; and stout, but somewhat short, spinous processes. The centrum presents, upon each side, an oval rugose pit, sometimes more or less divided into two facets. This is the costal articular surface, which has been already adverted to. Into it fits the thickened head of a costal rib, which may have corresponding facets, but is otherwise undivided. The rib is continued backwards into a short and straight body, and the angle, or the part at which the neck and the body of

Fig 68.

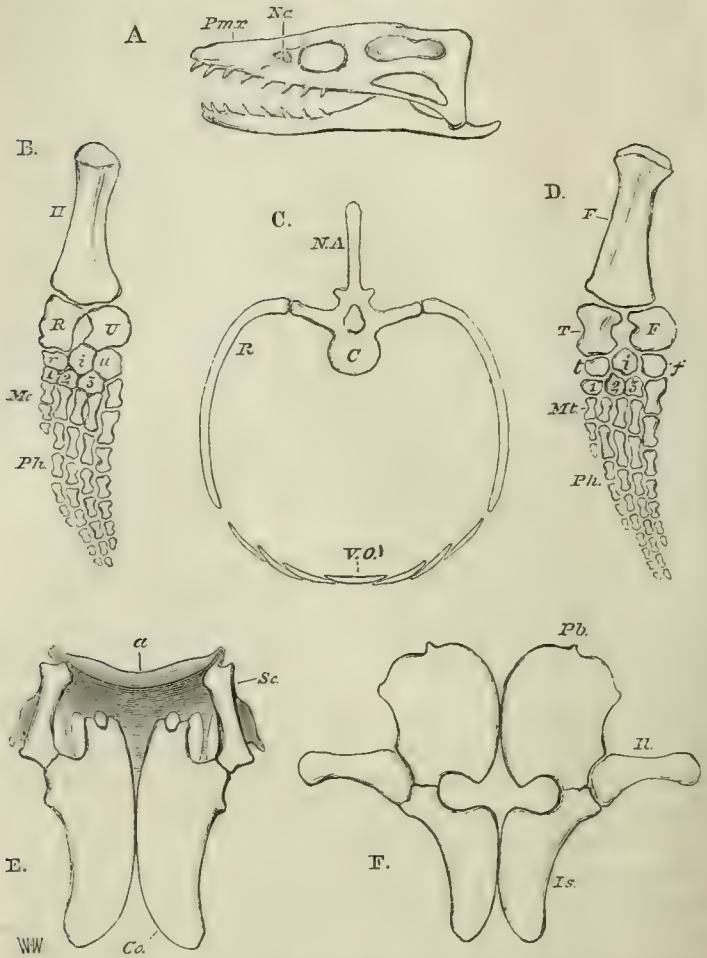


Fig. 68.—Diagram showing the structure of the most important parts of the skeleton of *Plesiosaurus*.—A, the skull: *Na*, nasal aperture.—B, the left fore limb: *H*, humerus; *U*, ulna; *R*, radius; *r. i. u.*, radiale, intermedium, and ulnare, in the proximal row of carpal bones 1, 2, 3, distal carpal bones; *Mc*, metacarpus; *Ph*, phalanges.—C, a dorsal vertebra with ribs (*R.*), and ventral ossifications (*V.o.*).—D, the left hind limb: *F*, femur; *T*, tibia; *F*, fibula; *t. i. f.*, tibiale,

intermedium, and fibulare, in the proximal row of tarsal bones; 1, 2, 3, distal tarsal bones; *Mt.* metatarsus; *Ph*, phalanges.—E, the pectoral arch: *Sc*, scapula; *Co*, coracoid; *a*, clavicles and interclavicle (?).—F, the pelvic arch: *Pb*, pubis; *Il*, ilium; *Is*, ischium.

the rib join, is produced forwards, so that the cervical ribs of the *Plesiosauria* have a strong general resemblance to those of the *Crocodylia*. In the posterior part of the neck and the anterior part of the dorsal region, the ribs become somewhat longer, and lose their anterior processes, gradually acquiring the rounded and curved form of ordinary ribs. Their proximal ends remain simple, and the facets, with which they articulate, become raised, and thrown outwards, as transverse processes, developed from the arches of the vertebræ. (Fig. 68, C.)

In the anterior dorsal vertebræ, these transverse processes rapidly acquire their full length; and they are continued under this form, descending somewhat lower upon the arches of the vertebræ towards the sacrum, to the end of the dorsal region. The neural spines acquire greater length, the zygapophyses are well developed, and the articular surfaces of the centra retain the form which they possessed in the cervical region. There are usually between twenty and twenty-five dorsal vertebræ. The sacral vertebræ are two, and resemble the others, except that the sacral ribs are large and broad for the attachment of the ilium. The caudal vertebræ, usually between thirty and forty in number, become, as usual, reduced to little more than centra at the end of the tail; but, in the fore part of the tail, they have well-developed spines and articular processes, with ribs which become ankylosed to the bodies of the vertebræ, only late in life. Well-developed chevron bones are attached between the ventral margins of successive centra of the caudal vertebræ.

As has been mentioned, there appear to be no sternal ribs, but there is a well-developed system of ossifications of the wall of the abdomen, arranged in transverse rows from before backwards; each row consists of a median bone, slightly bent upon itself, thick in the middle, and thin at

each end—and of six other bones, three on each side, which are elongated and pointed at each end, and so disposed that their pointed ends overlap one another. (Fig. 68, C.)

In some *Plesiosauria*, as already stated, the skull (Fig. 68, A) is very small in proportion to the body, not having more than a twelfth, or a thirteenth, of the length of the latter; but, in other species, the skull is much larger. The snout is tapering and depressed, and the nasal apertures are situated, not at its extremities, but just in front of the orbits—the latter, like the supra-temporal fossæ, being wide. The occipital condyle is almost wholly developed from the stout basi-occipital. The ex-occipitals give off elongated parotic processes, and the basisphenoid is a thick bone, which ends in front in a long rostrum.

There is a well-marked parietal foramen, and the parietals send off comparatively short processes backwards, which become connected with the large squamosals. The latter unite with the postfrontals, which separate the orbits from the temporal fossa, and the orbit is completed behind by the junction of the postfrontal with the jugal. The jugal bone is continued backwards into a slender bar, which extends as far back as the lower end of the quadrate, and probably contains a quadrato-jugal, so that there is a distinct infra-temporal fossa. The most obvious circumstance in which the skull of *Plesiosaurus* differs from that of most *Reptilia* is in the great size of the premaxillaries, which constitute a large proportion of the snout.

The under-surface of the skull is rarely well exposed in its anterior part; posteriorly, it exhibits a broad and long expansion, formed by the pterygoid bones, which unite in the middle line, and send processes outwards and backwards to the quadrate bone. On each side of the middle line of this region of the skull, is seen an ovoidal fossa or depression. The pterygoids are continued forwards, and are united externally with transverse bones, and more anteriorly with flattened palatine bones. When the forepart of the under-surface of the skull is exposed, two other fossæ are visible, one on each side of the middle line, bounded

behind by the palatine bones, and separated by what appear to be the vomers. I conceive that these are the true posterior nares, and that the posterior apertures are simply spaces left between the pterygoid bones and the *basis cranii*.

At the sides of the base of the skull, specimens of *Plesiosaurus* occasionally exhibit two styliform bones, which lie parallel with the axis of the skull; these may be parts of the hyoidean apparatus. No trace of any sclerotic ring has been found.

The teeth of the *Plesiosauria* are sharp-pointed, curved, and the outer surfaces of their crowns striated. Each tooth is lodged in a distinct alveolus, with which, as in the *Crocodylia*, it does not become ankylosed.

The pectoral arch (Fig. 68, E) is one of the most remarkable parts of the organization of the *Plesiosauria*. It consists, in the first place, of two very large coracoids, the long axes of which are parallel with one another, while their inner edges meet, without overlapping, throughout the greater part of their extent. In this respect they differ from any of the *Lacertilia*, which are provided with well-developed limbs. In these the long axes of the coracoids always cut one another at a large angle, open posteriorly—a circumstance which results from the manner in which the coracoids are received into grooves in the anterolateral edges of the rhomboidal part of the sternum. Hence it would appear that the *Plesiosauria*, like the *Chelonia*, did not possess anything corresponding to this rhomboidal part of the sternum, but that the intercoracoid part of the sternum was either absent, or reduced to a mere band, as in some *Batrachia*.

The scapulæ are unlike the corresponding organs in any other reptile. The glenoidal end, stout and strong, is continued horizontally forwards and inwards, as a bony prism, with a somewhat concave inner edge, and flat inferior surface. The outer surface, rising up at right angles to the ventral surface, gives rise to a well-defined edge; at a short distance from the glenoidal end, the part of the bone which bears this surface is produced upwards and

backwards, into a low recurved plate. This part appears to represent the proper body of the scapula in other Reptiles, while the horizontal prolongation answers to that pre-glenoidal process of the scapula, which extends forwards and inwards as a free bony bar in many *Lacertilia*—for example, *Iguana*.

In well-preserved specimens, a broad hoop of substance (Fig. 68, E, *a*), which seems to have been but imperfectly ossified, extends across the middle line of the body, from the pre-glenoidal process of one scapula to that of the other, and is continued backwards in the middle line, to the junction of the two coracoids. This corresponds very nearly in form and position to the epicoracoidal ossifications of the *Lacertilia*, combined with the clavicles and interclavicles; but I have never been able to detect any distinct clavicular, or interclavicular, elements in any *Plesiosaurus*, though they appear to have been well developed in *Nothosaurus*.

The humerus is a stout bone—prismatic, and with a rounded head at its proximal end, flattened and broad distally. (Fig. 68, B.) Its anterior margin is nearly straight, or even slightly convex, while the posterior is concave. Distally, it presents two facets, meeting at an angle, with which the broad and short radius and ulna articulate. The ulna differs in shape from the radius, being convex posteriorly, and concave in front. The two bones are of equal length, and much shorter than the humerus. There are six rounded carpal bones,* arranged in two rows; and to these succeed five digits, composed of metacarpals and phalanges, which are elongated and constricted in the middle. The middle digits have numerous phalanges.

The pelvic arch has very large dimensions, in correspondence with the size of the hind limb, which is usually longer than the fore limb. (Fig. 68, F and D.) The ilium is a

* It may be a question whether the fourth distal bone in the carpus and tarsus (Fig. 68, B and D) belongs to carpus and

tarsus, or to metacarpus and metatarsus; or whether it is formed by the confluence of elements belonging to both regions.

vertically elongated bone, narrower below than above, where it becomes connected with the sacral ribs. Inferiorly, it unites with the pubis and with the ischium, to form the acetabulum. The pubes are very broad quadrate bones, much larger than the ischia, and they meet in a median symphysis. The ischia, triangular and expanded, also unite in a ventral symphysis. The femur resembles the humerus in its general form, although both its sides are straighter, and the other bones of the hind limb are so like those of the fore limb, as to need no special description.

There can be little doubt that all the bones of the limbs were, like those of the *Cetacea*, enclosed within a common sheath of integument, so as to form a paddle.

Such is the general organization of the skeleton of the *Plesiosauria*, which are long extinct animals, entirely confined to the Mesozoic Rocks, from the Trias to the Chalk, inclusive. They may be divided into two groups, according as they are Triassic, or Post-Triassic, in age.

The Post-Triassic group contains the genera *Plesiosaurus* and *Pliosaurus*, the different species of which appear to differ in little more than the proportions of the head to the trunk, and the relative length and degree of excavation of the centra of the vertebræ. In the species which have been named *Pliosaurus*, the vertebræ are wide in proportion to their length, and deeply excavated in front and behind. *Pliosaurus* attained gigantic dimensions, paddles of some individuals reaching a length of not less than six feet.

The Triassic genera, *Nothosaurus*, *Simosaurus*, *Pistosaurus* (for a knowledge of the organization of which we are chiefly indebted to the labours of Hermann Von Meyer), appear to have differed from *Plesiosaurus* principally in the following respects:—

The connection of the neural arches with the centra of the vertebræ seems to have been looser. The supra-temporal fossæ in the skull appear to have been larger in proportion. In these animals, the under-surface of the skull has the same structure as in *Plesiosaurus*, but apparently lacks the posterior fossæ; while there is no doubt

whatsoever that the true posterior nares are situated far forwards, in the position assigned to them in *Plesiosaurus*.

The pectoral arch of *Nothosaurus*, again, presents a very interesting deviation from the Plesiosaurian type. The coracoids, indeed, are greatly expanded, and meet by their inner edges, so that the rhomboidal part of the sternum seems to have been wholly absent, and the scapulæ have a horizontal prolongation, not quite so long as in *Plesiosaurus*, with an upstanding proper scapular part of corresponding shape. But then the ends of these preglenoidal processes are connected together by, and indeed suturally united with, a stout, curved, transverse bar of bone, consisting of three pieces, one small and median, and two very large and lateral, all united firmly together by sutures. There can be little doubt that the constituents of this bony bar correspond with the interclavicles and clavicles of *Lacertilia* and *Ichthyosauria*.

III. The LACERTILIA.—Some few *Lacertilia*, like the Chamæleons and the *Amphisbæncæ*, are covered by a soft integument; but, in the majority, there is an epidermic exoskeleton composed of horny plates, tubercles, or spines, or overlapping scales. In some forms (e.g. *Scincus*, *Cyclodus*) the dermi beneath the horny scales is ossified, and the body has a complete armour of bony scutes, corresponding in form with the scales. The dermal ossifications of the head may coalesce with the subjacent bones, but this union of dermal bones with subjacent parts does not occur in other parts of the body.

The spinal column always contains a considerable number of vertebræ; and, except in the *Amphisbæncæ* and some few other Lizards, the tail is long. Those Lizards which possess hind limbs have a sacrum, into which not more than three vertebræ, and rarely more than two, enter. The presacral vertebræ are distinguishable, when sternal ribs are present, into cervical and dorsal. All those vertebræ which lie in front of the first sternal rib are cervical; and if, as sometimes happens, the last two or three dorsal vertebræ are devoid of

ribs, they become lumbar. Not more than nine vertebræ are met with in the cervical region of existing *Lacertilia*, and this number is rare. The number was greater in some extinct *Lacertilia*.

The atlas is composed of three pieces, one inferior and two superolateral. The odontoid bone is closely united with the second vertebra, and its anterior face may be cylindrical. A separate ossification is sometimes formed on the under-surface of the spinal column at the junction of each pair of vertebræ. Such a separate ossification, or *sub-vertebral wedge-bone*, is commonly developed beneath and between the odontoid bone and the body of the second vertebra.

The centra of the vertebræ are either procœlous, or amphicœlous; the former being by far the more common condition in existing *Lacertilia*, all of which, except the Geckos and *Sphenodon*, have procœlous vertebræ. The cups and balls are usually ellipsoidal, the long axis of the ellipsoid being transverse. In the Geckos, the centra of the vertebræ are conically excavated at each end; and, except in the centre of each vertebra, where it is ossified, the notochord persists throughout the spinal column.

The sacral vertebræ of existing *Lacertilia* are not ankylosed together, nor are their articular faces modified, the two being connected by a free cup-and-ball articulation. The movements of the two vertebræ, however, are restrained by the strong ligaments which connect their neural spines and arches, and by the fibro-cartilage which connects and covers the free ends of their expanded ribs.

In the anterior part of the tail of the *Lacertilia* there are usually well-developed subvertebral chevron bones, which are commonly attached to the bodies of the several vertebræ, and not in the intervals between adjacent vertebræ. In many *Lacertilia* (*Lacertæ*, *Iguanæ*, *Geckos*) the caudal vertebræ have a very singular structure, the middle of each being traversed by a thin, unossified, transverse septum. The vertebra naturally breaks with great readiness through the plane of the septum, and when such Lizards are seized by

the tail, that appendage is pretty certain to part at one of these weak points.

The arches of the vertebræ of the *Lacertilia* are articulated together by the ordinary oblique processes, or zygapophyses. In the *Iguanae* they are additionally connected by a process of the front part of each arch (*zygosphene*), which fits into a fossa on the posterior face of the preceding arch (*zygantrum*). These Lacertilian vertebræ thus nearly approach the vertebræ of the *Ophidia*.

The transverse processes of the vertebræ are very short, and are, at most, divided into two indistinct facets, with which corresponding facets on the proximal ends of the ribs articulate.

Ribs may be developed in all the cervical vertebræ except the atlas, and they usually increase in length towards the dorsal region, where more or fewer of them become connected with the sternum. The dorsal moiety of the primitive cartilage of the rib becomes ossified, and the primitive cartilage bone is finally replaced by membrane bone. The ventral moiety becomes converted only into cartilage bone, and may pass directly and without articulation, on the one hand into the sternum, and on the other into the vertebral rib. Processes are sometimes developed from the posterior margins of certain of the ribs, which are termed *processus uncinati*. The sternum, when fully formed, consists of a rhomboidal anterior portion, from the posterior angle of which a single, or double, backward prolongation is continued into the wall of the abdomen. Two or three pairs of the sternal ribs are connected with the posterolateral edges of the rhomboid, while the rest may be attached to the abdominal prolongations; or, behind these, they may be continued into one another, to form complete hoops across the wall of the abdomen (Geckos, Chamæleons, Scincoids).

The Flying Lizard (*Draco volans*) is remarkable for the elongation of many of its posterior ribs, which are continued into, and support, the parachute-like expression of the integument by which it is enabled to perform its flights.

The skull of the *Lacertilia* resembles that of the *Chelonina* in the development of an interorbital septum (except in the *Amphisbænae*), and in the absence of alisphenoids, or of any complete ossification of the presphenoidal or orbitosphenoidal regions. The premaxillæ and maxillæ are firmly united with one another and with the skull, and there are two vomers. An unossified space, the *parietal foramen*, usually remains in the roof of the skull in the course of the sagittal suture, or between the parietals and the frontals.

Fig. 69.

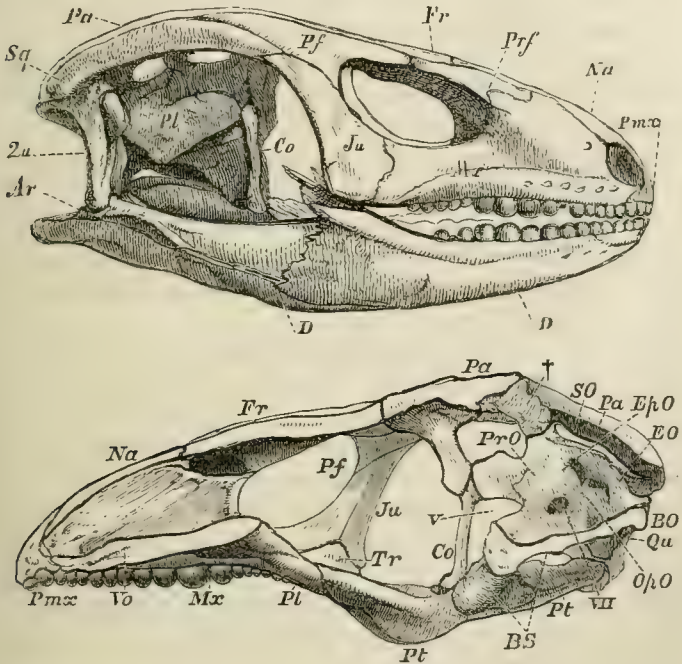


Fig. 69.—The skull of *Cyclodus*, entire and longitudinally bisected.

In the principal group of the *Lacertilia*, a column-like membrane bone, called the *columella* (but which is not to be, by any means, confounded with the *stapes*, to which the same name is often applied in Reptiles), extends from the

parietal to the pterygoid on each side, in close contact with the membranous or cartilaginous wall of the skull. Hence they have been called "*Kionocrania*," or "column skulls." This *columella* (Fig. 69, *Co*) appears to correspond with a small independent ossification, which is connected with the descending process of the parietal and with the pterygoid, in some *Chelonia*.

In the great majority of the *Lacertilia* (as in the *Chelonia*), the side-walls of the skull, in the region of the ear, are produced into two broad and long *parotic* processes, into the composition of which the opisthotic, ex-occipital, and pro-otic bones enter. Each quadrate bone is articulated with the outer end of one of these processes (in which a small separate *ptero-otic* ossification sometimes appears), and is usually moveable. The parietal bones do not unite suturally with the occipital segment of the skull, or with the pro-otic bones, but are connected with them only by fibrous tissue. And as the presphenoidal region remains unossified, or incompletely ossified, it follows that the fronto-parietal portion of the skull is, in most Lizards, slightly moveable upon the occipito-sphenoidal part.

Each parietal bone is prolonged backwards into a process which articulates with the upper part of the parotic prolongation of the skull; and to the outer side of the posterior extremity of the parietal process the squamosal is attached. The squamosal may be continued forward to the post-frontal, which is sometimes subdivided into two. The post-frontal may unite below with the jugal, and thus bound the orbit. Only in *Sphenodon*, among recent Lizards, is the jugal connected with the distal end of the quadrate by bone. As a general rule the quadrato-jugal is represented only by a ligament.

In consequence of the structure which has been described, the posterior region of the ordinary Lacertilian skull presents a number of distinct fossæ in the dry state. A *supra-temporal* fossa lies between the parietal, the postfrontal, and the squamosal, on the upper face of the skull; a *post-temporal*, between the parietal, the occipital, and the parotic

apophysis on the posterior face; a *lateral-temporal*, between the squamosal and postfrontal above, the jugal and quadrate in front and behind, and the quadrato-jugal ligament below.

The palatine and pterygoid bones are firmly connected both with the facial bones, and with the floor of the skull. Thus the basisphenoid gives off two *basipterygoid* processes, the outer ends of which articulate with the inner sides of the pterygoid. The posterior ends of the pterygoids are usually connected with the inner surfaces of the distal ends of the quadrate bones. Their anterior ends are firmly united with the palatines; and, from the junction of the two, a *transverse* bone (Fig. 70, *Tr*) usually passes, to unite the palatine and pterygoid with the maxilla.

The anterior ends of the palatines unite with the maxillæ and the vomers; but, in existing *Lacertilia*, they do not meet one another, or come into contact with the basisphenoid or presphenoid in the middle line. The palatine apertures of the nostrils are placed between the palatine bones, on the outer side, and the vomer, on the inner. In only a few *Lacertilia* do the palatine bones send down processes which bend towards one another in the middle line, and so form a posterior nasal passage, partially separated from the oral cavity.

The two rami of the lower jaw are usually, though not invariably, firmly connected at the symphysis—and each is composed of five ossifications in addition to the *articulare*.

The hyoidean apparatus consists of an elongated median rod, the anterior part of which supports the base of the

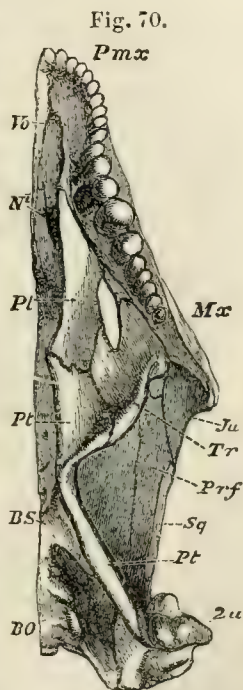


Fig. 70.—Under-view of the skull of *Cyclodus*: *N'*, posterior nasal aperture.

tongue; and, usually, of two long cornua on each side of this. The cephalic ends of the anterior cornua may be perfectly free, and lie upon the sides of the neck, as in *Psamosaurus*; or they may be traceable to, and be connected with, the stapes and the parotic processes, as in *Sphenodon*.

The limbs may be completely developed; or only one pair (either the anterior or the posterior) may be present; or they may be entirely absent. When present, they may be mere styliform rudiments, or may possess any number of digits from two to five. Even when the limbs are altogether absent, the pectoral arch remains, though the pelvic arch seems to vanish. When the pectoral arch is complete, it consists of a suprascapula, scapula, coracoid (with precoracoid and epicoracoid elements), and two clavicles, united by an interclavicle, which lies in a groove of the sternum. (Figs. 12 & 13, pp. 35 & 36.)

The coracoids articulate with grooves in the anterolateral edges of the sternum, and usually more or less cross and overlap one another, in front.

In the genus *Lialis*, in which not a trace of a fore-limb is discernible, there is a small sternum, consisting of a flat, somewhat pentagonal, plate of cartilage, in which there is a little coarsely granular calcareous deposit; but this sternum is connected with no ribs, nor, though it lies between the coracoids, does it articulate with them. Each coraco-scapular arch is a continuous cartilage, narrow in the middle, but expanded at its dorsal, and still more at its sternal, end, where the right overlaps the left, and both are connected by fibrous tissue with the sternum. The narrow middle part of the coracoid is invested, and in part replaced, by a sheath of membrane bone, which expands above and below, and represents both scapula and coracoid, though it presents no trace either of division, or of a glenoidal cavity. Beyond the extremities of this central ossification the cartilage merely presents scattered granular calcification. Along the front edge of each coraco-scapular arch, and closely connected with its ossified part, is a long curved clavicle, entirely composed of membrane bone, and united with its fellow

in the ventral median line, by ligamentous fibres. There is no interclavicle. The pectoral arch in other snakelike Lizards, such as the Blind Worm (*Anguis*) and the Sheltopusik (*Pseudopus*), is in much the same condition as in *Lialis*.

When the hind limbs are well developed there is a complete pelvis. The ilia are moveably articulated with the fibro-cartilages which cover the ends of the sacral ribs. The pubes and the ischia meet in median symphyses, and the anterior margin of the pubis usually, as in the *Chelonia*, gives off a strong curved process. In many *Lacertilia* a partially ossified or cartilaginous rod (*os cloacæ*) is continued back from the symphysis of the ischia, and supports the front wall of the cloaca.

In most *Lacertilia* the manus possesses five digits; and, when this is the case, there are usually eight bones in the carpus—one for each metacarpal on the distal side, one radial, one ulnar, and one central. As a very general rule, the pollex has two phalanges, the second digit three, the third four, the fourth five, and the fifth three (2, 3, 4, 5, 3). The pes, also, generally possesses five digits, which increase in length to the fourth, the fifth being smaller than the rest, and divergent in direction. Two large bones, very closely united, or completely fixed together, represent the calcaneum and the astragalus, and are articulated, in a manner which allows of very little motion, with the tibia and fibula. In the distal row there is usually a large bone, representing the cuboid. The fifth metatarsal* is bent, as in the *Chelonia*, and may articulate with the calcaneum as well as with the cuboid. One or two of the cuneiform bones may be present, or the inner ones may be represented merely by fibrous membrane, or by cartilage; in which latter case the inner metatarsals appear to articulate directly with the astragalus in the skeleton. The number of the phalanges is very generally the same as in the manus for the four tibial toes, but one more for the fibular (2, 3, 4, 5, 4).

* The bone thus named may perhaps contain a tarsal element, and represent not only the fifth

metatarsal, but the corresponding distal *tarsale*.

The *Lacertilia* all possess teeth, which may be confined to the premaxillæ, maxillæ, and dentary piece of the mandibles; or may, in addition, be developed on the palatine and pterygoid bones. These teeth are simple in structure, and their crowns have very various forms, being sometimes sharp and conical (*Monitor*); or bladelike, with serrated edges (*Iguana*); or with broad, crushing, and spheroidal crowns (*Cyclodus*). As a general rule, the teeth become ankylosed to the adjacent bone with age; and in the upper and lower jaws they thus become attached, either by their sides to the parapet of the jaw, when the dentition is said to be *pleurodont*; or by their bases to the summit of the parapet, when the dentition is *acrodont*. The extinct *Protorosauria* are said to be *thecodont*, or to have the teeth lodged in alveoli. New teeth are usually developed at the bases of the old ones.

The *Lacertilia* are divisible into numerous groups, the leading distinctive characters of which are exhibited in the following table:—

I.—The pterygoid and quadrate bones united.

A. A columella and an interorbital septum in the skull.

Kionocrania (Stannius).

a. Amphicœlous vertebræ (*K. Amphicœlia*.)

a. Dentition acrodont or pleurodont.

1. *Ascalabota*.

2. *Rhynchocephala*.

3. *Homoœsauria*.*

b. Dentition thecodont (?).

4. *Protorosauria*.*

b. Procœlous vertebræ (*K. procœlia*.)

a. Not more than nine cervical vertebræ.

a. The nasal bone, single.

5. *Platynota*.

b. The nasal bones, two.

1. The integument of the head not covered with epidermic plates.

6. *Eunota*.

2. The integument of the head covered with epidermic plates.

7. *Lacertina*.

8. *Chalcidea*.

9. *Scincoidea*.

b. More than nine cervical vertebræ.

10. *Dolichosauria*.*

11. *Mosasauria*.

* The columella has not been observed in these groups.

B. No columella ; no interorbital septum.

12. *Amphisbænoida*.

II.—The pterygoid and quadrate bones disunited.

13. *Chamæleonida*.

1. *The Ascalabota*.—The Geckos, which constitute this group, are Lizards of small size, which inhabit the hotter parts of both the Old and the New Worlds, and have always attracted attention by their habit of running with exceeding swiftness along the walls and ceilings of rooms. They are enabled to maintain their hold under these circumstances, in part by the sharpness of their curved, and, in some cases, retractile claws ; and, in part, by laminated expansions of the integument of the under-surfaces of their digits, which appear to act in somewhat the same fashion as the sucker of the *Remora*, or Sucking-fish.

The most important and distinctive characters of these Lizards are:—

Their vertebræ are amphicœlous.

Neither the upper nor the lower temporal arcades are ossified, the postfrontal being connected with the squamosal, and the maxilla with the quadrate, by ligament.

The jugal is rudimentary, and the squamosal very small.

There are no eyelids, but the integument becomes transparent as it is continued over the eyes. The integument is soft, or coriaceous, not scaly.

2. *The Rhynchocephala*.—This division contains only the very remarkable genus *Sphenodon* (otherwise *Hatteria*, or *Rhynchocephalus*). The vertebræ are biconcave. Some of the ribs have recurrent “uncinate” processes, as in Birds and Crocodiles. The sternal and vertebral ribs are connected by an articulation, and there is a very peculiar system of abdominal ribs. The infra-temporal arcade is completely osseous in this, but in no other recent, lizard. The quadrate bone is immoveably fixed, not merely by ankylosis with the squamosal, quadrato-jugal, and pterygoid, but by the ossification of the strong membrane, which, in Lizards in general, extends between the quadrate, the ptery-

goid, and the skull, and bounds the front walls of the tympanum. The dentary pieces of the mandible are not suturally united. The premaxillæ are not ankylosed together, and, as in some other Lizards (e. g. *Uromastix*), have a beak-like form, the large premaxillary teeth becoming completely fused with the bony substance of the premaxillæ. There is a longitudinal series of teeth upon the palatine bone running parallel with those on the maxilla, and the mandibular teeth are received into the deep longitudinal groove which lies between the maxillary and the palatine teeth. By mutual attrition, the three series of teeth wear one another down to the bone in such a way, that the mandibular teeth are ground to an edge, while the maxillary and palatine teeth are worn upon their inner and outer faces respectively.

The extinct Lizards of the Triassic age, *Rhynchosaurus* and *Hyperodapedon*, appear to have been very closely allied to *Sphenodon*.

3. *The Homæosauria*.—The remains of Lizards of small size, and agreeing in the most important points of their osteology with the ordinary *Lacertilia*, but having amphicæalous vertebræ, have been found in the older Mesozoic rocks, from the Solenhofen slates to the Trias inclusively. They cannot be identified with either the *Rhynchocephala*, or the *Ascalabota*, and may be provisionally grouped as *Homæosauria*. The genera *Homæosaurus*, *Saphæosaurus*, and *Telerpeton* belong to this group.

4. *The Protorosauria*.—These are the oldest known *Sauropsida*, their remains occurring in the Kupferschiefer of Thuringia, which is a part of the Permian formation, and in rocks of corresponding age in this country; but no more modern representatives of this group are known.

The Thuringian Lizard (*Protorosaurus*) does not appear to have attained a length of more than six or seven feet. The neck is remarkably long, the cervical region being equal to the dorsal in length, and it bears a skull of mode-

rate size. The tail is long and slender, and the limbs well developed, as in the existing Monitors. Notwithstanding the length of the neck, it contained not more than nine, possibly not more than seven, vertebræ, which, except the atlas, are remarkably stout and strong. There are about eighteen or nineteen dorsal, two (or not more than three) sacral, and more than thirty caudal vertebræ. In all these vertebræ the neurocentral suture is completely obliterated, and the centra are slightly concave at each end. The side of each cervical vertebra, after the atlas, presents, near its anterior edge, a small tubercle, with which the head of a slender styliform rib articulates. The transverse processes of the dorsal vertebræ are very short, antero-posteriorly flattened, plates, and the strong ribs are articulated with them by undivided heads. The sternum has not been preserved. In the abdominal region of some specimens, numerous short and filiform bones appear to represent, and correspond with, the abdominal ribs of *Plesiosauria* and *Crocodylia*.

The spinous processes of the caudal vertebræ, up to near the middle of the tail, have the ordinary structure; but beyond this point they bifurcate, so that each vertebra seems to have two spinous processes, a peculiarity unknown in other *Lacertilia*.

The large chevron bones are articulated between the bodies of the caudal vertebræ, as in the *Crocodylia*, but also as in some *Lacertilia*, such as the Geckos. The skull is preserved in one specimen only, and in that it is in such an imperfect condition that the details of its structure cannot be made out. The teeth, however, are nearly straight, conical, and sharply pointed, and seem to have been implanted in distinct sockets, though there may be some doubt upon this point.

The pectoral and pelvic arches are large and strong. The fore limbs are shorter than the hind limbs, and each limb bears five digits. The manus contains certainly eight, possibly nine, carpal bones, five of which correspond with the metacarpals. The number of phalanges is exactly the same

as in most existing *Lacertilia* (2, 3, 4, 5, 3). In the pes, again, the number of the phalanges is characteristically Lacertilian (2, 3, 4, 5, 4), and so is the form of the fifth metatarsal; but the two proximal tarsal bones appear to have been less closely connected together than in existing *Lacertilia*, and there were, at fewest, three distal tarsal bones with which the metatarsals articulated, and by which they were completely separated from the proximal tarsals. Among existing *Lacertilia* an arrangement similar to this is met with only in the *Ascalabota*.

5—9. The great majority of existing *Lacertilia* belong to the procœlous *Kionocrania*, with not more than nine cervical vertebræ, and they deviate but little in their osteology from the general type of organization which has been described.

The skull in the *Platynota*, or Monitors of the Old World, with the American genus *Heloderma*, differs from that of any other *Lacertilia* in the circumstance that the nasal bones are represented by a single narrow ossification.

In the genus *Lacerta* the bones of the roof of the skull become continued into dermal ossifications, which roof over the supra-temporal fossæ. In the *Chalcidea* and *Scincoidea*, in which the body sometimes becomes elongated and snakelike, and the limbs rudimentary, the supra- and infra-temporal arcades are apt to be ligamentous, and the post-frontals and squamosals small.

10. *The Dolichosauria*.—A very singular Lacertilian found in the Chalk, and resembling an eel in form and size, has been described by Professor Owen under the name of *Dolichosaurus*. It possesses an exceedingly elongated body, but is provided with limbs and with a distinct sacrum, consisting of two vertebræ. Its most remarkable peculiarity, however, lies in the number of its cervical vertebræ, which were not fewer than seventeen.

11. *The Mosasauria*.—The cretaceous rocks of Europe and America have yielded another remarkable long-bodied

marine Lacertilian, which attained a great size. This is the genus *Mosasaurus*, remains of which were first obtained from the Chalk near Maestricht.

Eighty-seven vertebræ belonging to one individual of this genus have been discovered, and when put together had a length of thirteen-and-a-half feet. But there were certainly many more vertebræ than these, as those of the end of the tail are wanting, and there are gaps in the series of the rest. The centres of all these vertebræ are concave in front and convex behind; but the concavities and convexities are less marked in the posterior, than in the anterior, vertebræ. The atlas and axis are not well preserved in this series of vertebræ, but the nine following all have inferior spinous processes, which become shorter in the posterior vertebræ, and, in the last two, are represented only by a pair of low elevations. They have short transverse processes, each terminated by a simple costal facet. It is probable that these are cervical vertebræ. In the dorsal vertebræ, of which there must have been at fewest twenty-four, the transverse processes, which are strong in the anterior, gradually diminish in size in the posterior, vertebræ. There are no inferior processes. All the vertebræ which have been mentioned hitherto have the circumference of the centrum rounded, and are articulated to one another by zygapophyses. But a series of eleven, which follow them, have no zygapophyses, and the centra assume a more or less triangular prismatic form. The transverse processes of these are long, thin, and bent a little downwards and backwards. These seem to have been lumbar vertebræ. No sacrum has been discovered, but there are numerous caudal vertebræ with transverse processes, pentagonally prismatic centres, and chevron bones attached to the middle of the under-surface of each. In the nine posterior of these caudal vertebræ the bodies are cylindrical, the transverse processes are obsolete, and the chevron bones, ankylosed to the undersides of the centra, are long, inclined backwards, and overlap one another. And, in the hindermost caudals, the spinous processes and the chevron bones disappear.

There were strong ribs, but nothing is known with certainty of the sternum, limb-arches, or other bones.

The very complete specimens of the skull that have been discovered prove that its structure was very similar to that of the Old World Monitors in the large size of the nasal apertures, and the fusion of the nasals into a narrow bone. But sharp recurved teeth are ankylosed by their bases, not only to the premaxillary, maxillary, and dentary bones, but also to the pterygoid bones; and these pterygoid bones are unlike those of other *Lacertilia*, not only in form, but because they articulate together in the middle line for a considerable distance behind the posterior nasal aperture.

12. *The Amphisbænoida*.—These lizards have completely snakelike bodies; one genus of the group (*Chirotes*) has a pair of small pectoral members, but the rest are apodal. The integument of the body is not scaly, but its surface is divided into small rectangular areas arranged in transverse rows. The tail is exceedingly short, so that the vent is close to the end of the body:

The numerous procœlous vertebræ have less elliptical articular faces than those of the typical *Lacertilia*. There is no sacrum, and all the precaudal vertebræ, except the one or two of the most anterior, have ribs. The representatives of the chevron bones in the tail are firmly united with the centra of the vertebræ. The vertebræ have no zygantrum nor zygosphene. *Amphisbæna* has no sternum. *Chirotes* has a sternum, but it is not united with the ribs.

The skull, unlike that of *Lacertilia* in general, develops no interorbital septum. In this respect, and in the complete closure of its anterolateral walls by bone, it resembles the Ophidian cranium. There is no columella. Postfrontals are absent, and the squamosal is very small. The quadrate bone is small, and inclined not only downwards, but forwards, in a manner unknown in other *Lacertilia*. The two rami of the mandible are firmly united by suture.

In *Amphisbæna* the premaxillæ bear two rows of teeth,

one behind the other, and one tooth lies upon the symphysis of the premaxillæ.

13. *The Chamæleonida*.—The Chamæleons are distinguished from the *Kionocrania* not only by the negative character of the absence of the columella, which they share with the preceding group, but by a number of very important positive features. Among these I may mention the soft and tuberculated skin, with its changing hues; the absence of any tympanum; the prehensile tail; and the very peculiarly modified feet. The digits are arranged in bundles of two and three, the manus having the pollex, the index, and the medius, syndactylous and turned inwards; while, in the foot, it is the hallux and index only which are thus united and turned inwards, the three other toes being similarly connected together by integument, as far as the unguis phalanges, and directed outwards. To these characters may be added the remarkable tongue, capable of protrusion and retraction with almost lightning rapidity.

The vertebræ of the Chamæleons are similar in their characters to those of the procœlous *Kionocrania*. The sacrum is composed of only two vertebræ. Only a few of the anterior ribs are united with the sternum. A large number of the posterior ribs, as we have already seen to be the case in the Gecko, unite together in the mid-line, and form continuous hoops across the ventral wall of the abdomen.

But it is in the structure of the cranium that the *Chamæleonida* depart most completely from the ordinary Lacertilian type. The parietal bone is not moveable upon the occipital, the supra-occipital sending up a median ridge, which unites with the base of a corresponding crest or process extending backwards for a considerable distance from the middle line of the parietal bone. The summit of this sagittal crest is joined by two curved prolongations of the squamosal, the three giving the occipital region of the Chamæleon its remarkable casque-like form. The frontal bone is comparatively small and single, and the nasals are very narrow, and do not bound any part of

the anterior nasal apertures. These apertures, in fact, are situated upon the sides of the forepart of the skull, and are separated from the nasal bones, in part, by a membrane which stretches outwards from the nasal bones; and external to this by a prolongation forwards of the prefrontal bone, which unites with the maxilla, and in some specimens of Chamæleons is prolonged forwards into a great osseous horn, projecting from the sides of the front part of the snout.

The orbit is closed behind by the ascending process of the jugal bone, but there is no quadrato-jugal. The quadrate bone itself is not, as in most other *Lacertilia*, moveable upon the sides of the skull, but is firmly ankylosed with the bones which lie adjacent to its upper end. The pterygoid bones are produced downwards; and, by a very exceptional peculiarity, do not articulate with the quadrate bones, but are connected with them only by fibrous tissue. In the lower jaw, the dentary piece takes up a very much larger proportion of the ramus than is the case in other *Lacertilia*. The basal portion of the hyoid is represented by a long median cylindrical entoglossal bone, and its posterior cornua are much stronger and longer than the anterior pair. In the pectoral arch the scapula and coracoid are remarkably longer and narrower than in other *Lacertilia*. There are no clavicles, and the interclavicle is wanting, the sternum being represented only by its rhomboidal ossified cartilage. Again, in the pelvic arch, the ilium is long and narrow, and its long axis is directed nearly vertically to that of the trunk—in which respect the Chamæleons differ very much from the ordinary *Lacertilia*. There is no *os cloacæ*.

The carpus and the tarsus have a very singular structure. In the carpus there are two proximal bones, articulated with the radius and the ulna respectively. A single spheroidal bone is articulated with these, and with the five proximal constituents of the digits. Besides these, there is an ossicle representing the pisiform. In the tarsus there are also four bones, two articulated with the tibia and fibula respectively, a third below and between them, and a fourth distal bone

articulating with the five proximal bones of the digits. In both manus and pes the number of the phalanges, counting from the preaxial to the postaxial side, is 2, 3, 4, 4, 3.

IV. The OPHIDIA.—This order of Reptiles has been divided as follows:—

- A. The palatine bones widely separated, and their long axes longitudinal; a transverse bone; the pterygoids united with the quadrate bones.
 - a. None of the maxillary teeth grooved or canaliculated.
 - 1. *Aglyphodontia*.
 - b. Some of the posterior maxillary teeth grooved.
 - 2. *Opisthoglyphia*.
 - c. Grooved anterior maxillary teeth succeeded by solid teeth.
 - 3. *Proteroglyphia*.
 - d. Maxillary teeth few, canaliculated, and fanglike.
 - 4. *Solenoglyphia*.
- B. The palatine bones meet, or nearly meet, in the base of the skull, and their long axes are transverse; no transverse bone; the pterygoids are not connected with the quadrate bone.
 - 5. *Typhlopidae*.

All the Snakes possess a scaly epidermic investment, which is usually shed in one piece, and reproduced at definite intervals. As a general rule these scales are flat, and overlap one another; but sometimes, as in *Acrochordus*, they become more tubercle-like, and do not overlap. In the Rattlesnakes (*Crotalus*) the body is terminated by several loosely-conjoined rings of horny matter, which consist of the modified epidermis of the end of the tail.

The derm does not become ossified in the *Ophidia*.

The number of the vertebræ in the snakes is always considerable, and in some cases becomes very great, amounting to more than four hundred in some of the large Pythons. The spinal column is divisible only into caudal and pre-caudal regions, as there is no sacrum, nor any distinction between cervical, dorsal, and lumbar vertebræ. The atlas

and the odontoid vertebra are similar to those of the Lizards, and the atlas is the only precaudal vertebra which is devoid of ribs. The centra have nearly hemispherical articular surfaces, and thus differ from those of ordinary *Lacertilia*, while the superadded articular processes found only in certain Lizards attain a great development in the Snakes. The zygapophyses are broad and flattened, and the outer surfaces of the anterior pair are commonly prolonged into a process. The anterior surface of the arch above the

Fig. 71.

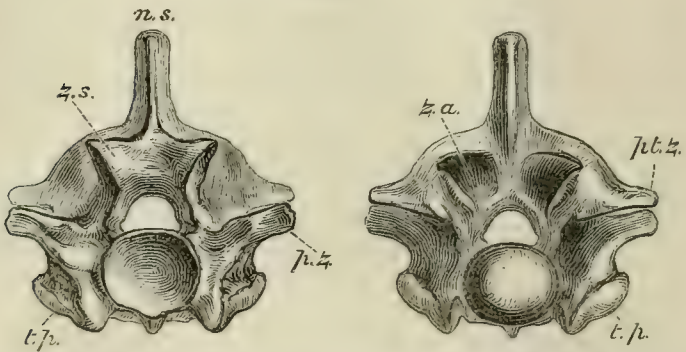


Fig. 71.—Anterior and posterior views of the dorsal vertebra of a Python:—*z. s.*, zygosphene; *z. a.*, zygantrum; *p. z.*, prezygapophyses; *pt. z.*, postzygapophyses; *t. p.*, transverse processes.

neural canal is produced into a strong wedge-shaped zygosphene, which fits into a corresponding zygantrum of the next preceding vertebra; and, on the posterior surface of the arch, there is a zygantrum for the zygosphene of the next preceding vertebra. (Fig. 71.)

The transverse processes are short and tubercle-like, and the heads of the ribs which articulate with them are simple. Each rib usually gives off a short upward process at a little distance from its head; it is curved, usually hollow, and terminates, inferiorly, in a cartilage which is always free, no trace of a sternum existing. Strong descending processes are given off from the undersides of many of the presacral

vertebræ. In the caudal region, elongated transverse processes take the place of the ribs. Chevron bones, like those of the *Lacertilia*, do not exist, but the caudal vertebræ possess bifurcated descending processes, which bear similar relations to the caudal vessels.

The skull differs from the ordinary Lacertilian cranium in the following points:—

1. That vertical elevation and lateral compression of the presphenoidal region, which give rise to the interorbital septum, is wanting; the floor of the cranium being nearly flat, and the vertical height of its cavity diminishing gradually in front, so that it remains spacious between the eyes, and in the frontal region generally. The periotic region is not produced into parotic processes.

2. The boundary-walls of the front half of the cranial cavity are as well ossified as those of its posterior moiety, and the bones which constitute the brain-case are firmly united together.

3. On the other hand, the nasal segment is less completely ossified, and may be moveable. The premaxillæ are usually represented by a single small bone, which very rarely bears teeth. It is connected with the maxillæ only by fibrous tissue.

4. The palatine bones never unite directly with the vomer, or with the base of the skull, but they are usually connected with the maxillæ by transverse bones; and, by the pterygoids, with the mobile quadrate bones. Hence the connection of the palato-maxillary apparatus with the other bones of the skull is always less close in *Ophidia* than in *Lacertilia*, and sometimes it is exceedingly lax.

5. The two rami of the mandible are united at the symphysis only by ligamentous fibres, which are often extremely elastic.

6. The hyoidean apparatus is very rudimentary, consisting only of a pair of cartilaginous filaments, which are united together in front, and lie parallel with one another beneath the trachea. They have no connection with the skull.

These are the most apparent differences between the Ophidian and the Lacertilian skull. But there are others, of a less obvious but more remarkable character, by which the skulls of the Ophidian depart not only from that of the Lizard, but from that of other *Vertebrata*. Thus the basisphenoid passes in front of the *sella turcica*, into a great rostrum, which extends forwards to the ethmoidal region, and probably results from a parasphenoidal ossification. In many adult *Ophidia* two cartilaginous rods lie in grooves on

Fig. 72.

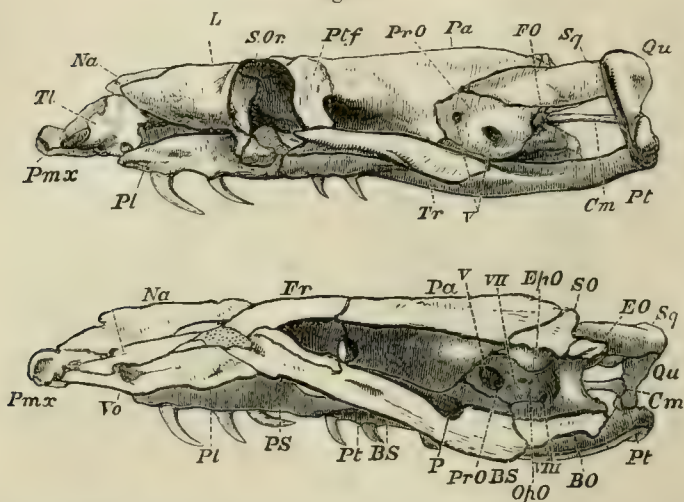


Fig. 72.—The skull of a Python, viewed from the left side, and in longitudinal section: *Cm*, stapes; *Tl*, turbinal bone.

the upper face of this rostrum, and pass behind into the basisphenoid, while in front they are continued into the cartilaginous ethmoidal septum. These rods are the *trabeculae cranii* of the foetus, which do not become united in Snakes, as they do in all the other abbranchiate *Vertebrata*. The roof and side-walls of the Ophidian skull are completed in front of the occipital segment, by two pairs of bones, which appear to be parietals and frontals. The "frontal" bones not only completely wall in the sides of

the frontal region, but extend inwards below, and meet in the middle line, above the basisphenoidal rostrum and the persistent trabeculæ. The "parietals" unite suturally with the basisphenoid. These relations are not usual in true frontals or parietals (though the latter unite with the basisphenoid in *Chelonia*, and the frontals unite in the middle line of the floor of the skull in some Mammals); and as there are only two bones in the place of four in this region of the skull, it becomes a matter for inquiry whether the two bones, on each side, respectively represent orbitosphenoids + frontals, and alisphenoids + parietals; or whether they represent overgrown frontals and parietals only; or whether, lastly, they are the result of an excessive development of the orbitosphenoids and alisphenoids, true frontals and parietals being absent. According to Rathke's elaborate investigation into the development of the skull in *Coleuber natrix*, the two bones on each side are formed from single centres of ossification, which appear in patches of "cartilage," which are situated, at first, in the superolateral regions of the skull, in the place normally occupied by orbitosphenoids and alisphenoids, and that these grow up and meet in the middle line. In this case the bones in question are orbitosphenoids and alisphenoids, and *Ophidia* have no true frontals or parietals; but the existence of so remarkable a deviation from the ordinary construction of the vertebrate skull cannot be admitted until the development of the Snake's skull has been carefully re-examined.

The *Ophidia* usually possess well-developed postfrontals, and they have large membrane bones in front of the orbit, which lie upon the cartilaginous nasal chambers, and are ordinarily regarded as lachrymals. Large nasals lie upon the upper surface of the nasal capsule between the lachrymals; and, forming the floor of the front part of the nasal chamber, on each side, is a large concavo-convex bone (*Tl*, Fig. 72), which extends from the ethmoidal septum to the maxilla, protects the nasal gland, and is commonly termed a turbinal, though, if it be a membrane bone, it does not

truly correspond with the turbinals of the higher *Vertebrata*. The squamosals are usually well developed. There is no jugal, or quadrato-jugal.

Though the general conformation of the skull in the *Ophidia* is that which has now been described, it presents remarkable modifications in different members of the order, especially in the form and disposition of the bones of the jaws. In the great majority of the *Ophidia*, the elongated palatine bones have their long axes longitudinal, lie on the outer sides of the internal nasal apertures, and do not enter into the formation of the posterior boundaries of those apertures. Each is connected by a transverse bone with the maxilla, which lies at the side of the oral cavity; and the pterygoids diverge posteriorly towards the quadrate bones, with which they are connected by ligaments.

But, in the remarkable group of the *Typhlopidae*, the slender palatine bones meet upon the base of the skull in the middle line, and are directed transversely, in such a manner as to bound the posterior nasal apertures behind, as in the *Batrachia*. There is no transverse bone. The pterygoids lie parallel with one another under the base of the skull, and are not connected with the quadrate bones. The maxillæ are short plates of bone which are connected with the outer extremities of the palatine bones, and are directed obliquely towards the middle line of the oral cavity, into which their free edges, armed with teeth, depend.

Again, the first-mentioned, or typical, form of Ophidian skull exhibits two extreme modifications, between which lie all intermediate gradations. At the one end of the scale are the non-venomous Snakes, and especially *Python* and *Tortrix* (which belong to the division *Aglyphodontia*); at the other the poisonous Snakes, and especially *Crotalus* (*Solenoglyphia*).

Thus, *Python* (Figs. 72 & 73) has well-marked premaxillæ. large maxillary bones, palatine bones which are firmly united with the pterygoids, and transverse bones which bind the maxillaries and palato-pterygoid bars into one solid framework.

The maxillaries give attachment to a long series of recurved teeth, which are not very unequal in size. And *Python* (like *Tortrix*, but unlike all other *Ophidia*) possesses teeth in the premaxillæ.

The squamosal bones are very long, and adhere to the skull, upon which they are slightly moveable, only by their anterior ends; and the quadrate bones are borne upon the posterior ends of the squamosals, and are thus, as it were, thrust away from the walls of the skull. The rami of the mandible are loosely connected by an elastic symphysial ligament. Thus, not only can these rami be widely separated from one another, but the squamosal and quadrate bones constitute a kind of jointed lever, the straightening of which permits of the separation of the mandibles from the base of the skull. And all these arrangements, taken together, allow of that immense distension of the throat which is requisite for the passage of the large and undivided prey of the serpent.

In *Tortrix*, this mechanism does not exist, the short quadrate bone being directly articulated with the skull, while the squamosal, like the postfrontal, is rudimentary. The maxillary bones are also almost fixed to the skull.

In the Rattlesnakes (*Crotalus*, Fig. 74), the premaxillæ are very small and toothless. The maxillary bone has no longer the form of an elongated bar, but is short, subcylindrical, and hollow; its cavity lodges the fossa formed by the integument in front of the eye, which is so

Fig. 73.

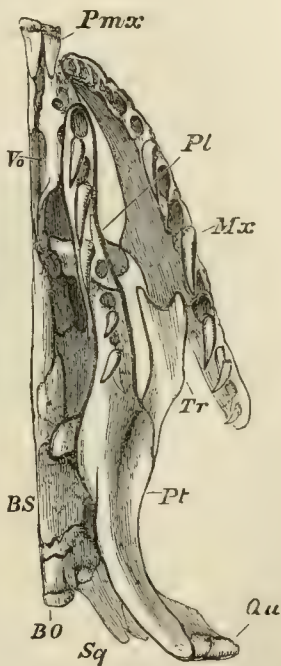


Fig. 73. — Under-view of the left half of the skull and facial bones of *Python*.

conspicuous in these, and sundry other, poisonous Snakes. The upper and inner part of the maxilla articulates with a pulleylike surface furnished to it by the lachrymal, so that the maxilla plays freely backwards and forwards upon that bone. The lachrymal, again, has a certain amount of motion upon the frontal. The upper edge of the posterior wall of the maxilla is articulated by a hingelike joint with the anterior end of the transverse bone, which has the form of an extremely elongated and flattened bar connected posteriorly with the pterygoid.

Fig. 74.

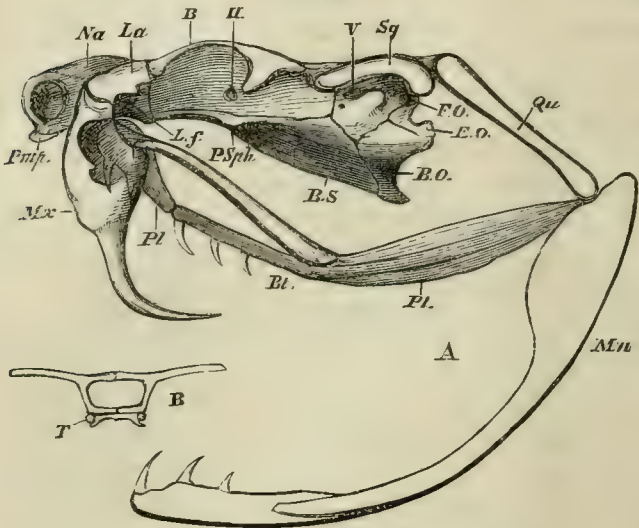


Fig. 74.—A, the skull of *Crotalus*, viewed from the left side; B, a transverse section taken at the point B in Fig. A, showing T, the persistent cartilaginous trabeculae. The maxilla is supposed to be transparent, and the anterior half of the palatine bone is seen through it.

The latter is long and stout, and, as usual, is united, behind, with the distal end of the quadrate bone. In front of, and internal to, its union with the transverse it is prolonged forwards, and becomes united, by a moveable joint, with the short palatine bone, which is flattened from side to side,

and lies on the outer side of the posterior nasal aperture. Its anterior end is connected only by fibrous tissue with the base of the skull. The inferior edge of the palatine bears a few small teeth, and other sharp, recurved, solid teeth are attached to the under-surface of the anterior moiety of the pterygoid.

When the mouth is shut, the axis of the quadrate bone is inclined downwards and backwards. The pterygoid, thrown as far back as it can go, straightens the pterygo-palatine joint, and causes the axes of the palatine and pterygoid bones to coincide. The transverse, also carried back by the pterygoid, similarly pulls the posterior part of the maxilla, and causes its proper palatine face, to which the great channeled poison-fangs are attached, to look backwards. Hence these fangs lie along the roof of the mouth, concealed between folds of the mucous membrane. But, when the animal opens its mouth for the purpose of striking its prey, the digastric muscle, pulling up the angle of the mandible, at the same time thrusts the distal end of the quadrate bone forwards. This necessitates the pushing forward of the pterygoid, the result of which is twofold: firstly, the bending of the pterygo-palatine joint; secondly, the partial rotation of the maxillary upon its lachrymal joint, the hinder edge of the maxillary being thrust downwards and forwards. In virtue of this rotation of the maxillary, through about a quarter of a circle, the dentigerous face of the maxilla looks downwards, and even a little forwards, instead of backwards, and the fangs are erected into a vertical position. The snake "strikes;" by the simultaneous contraction of the crotaphite muscle, part of which extends over the poison-gland, the poison is injected into the wound through the canal of the fang; and, this being withdrawn, the mouth is shut, all the previous movements are reversed, and the parts return to their first position.

No Ophidian possesses any trace of anterior extremities, but the *Typhlopidæ*, the Pythons, Boas, and *Tortrices*, have

rudiments of a pelvis, and the latter Snakes even possess very short representatives of hind limbs terminated by claws.

The teeth of the *Ophidia* are short and conical, and become ankylosed to the bones by which they are supported. They may be developed in the premaxillaries, maxillaries, palatines, pterygoids, and the dentary piece of the mandible, but their presence in the premaxillaries is exceptional. In *Uropeltis* and some other genera, there are no palatine teeth; and in the egg-eating African snake, *Rachiodon*, the teeth are small and rudimentary upon all the bones which usually bear them. But the inferior spines of eight or nine of the anterior vertebræ are long, and tipped, at their apices, with a dense enamel-like substance. These project through the dorsal wall of the œsophagus into its cavity, and the eggs, which are swallowed whole, are thus broken in a position in which all their contents must necessarily be saved.

In the majority of the non-venomous Snakes the teeth are simply conical, but in the others, and in all the poisonous Snakes, some of the maxillary teeth (which are usually longer than the rest) become grooved in front. In the *Solenoglyphia*, or Vipers and Rattlesnakes, the maxillary teeth are reduced to two or three long fangs, the groove in the front of which is converted into a canal open at each end, by the meeting of its edges. The teeth of the Snakes are replaced by others which are developed close to the bases of the old ones.

Ophidia are not known in the fossil state before the older tertiaries.

V. The ICHTHYOSAURIA.—In its general form *Ichthyosaurus* presents a good deal of resemblance to a Cetacean. The head is enormous, and passes at once into the trunk, so that there is no more appearance of a neck than in a Porpoise, and the body tapers off behind, much as would happen in the latter animal were it devoid of a caudal fin. Indeed, there is some reason to suspect that the tail of

Ichthyosaurus may have been provided with a sort of finlike expansion of the integument. This fishlike body was propelled, like that of the *Plesiosaurus*, by four paddles; but the anterior paddles were placed close behind the head, and were, generally, very much larger than the posterior ones.

Fig. 75.




Fig. 75.—A restoration of *Ichthyosaurus*. The existence of the caudal fin is doubtful.

The spinal column is only distinguished into two regions, caudal and precaudal, inasmuch as the ribs, beginning at the anterior part of the neck, are continued, without being connected with the sternum, to the posterior end of the body; and there is no sacrum. The caudal region, however, is distinguished by the chevron bones which are attached beneath its vertebræ. The vertebræ of *Ichthyosauria* in general have certain characters by which they differ from those of all other *Vertebrata*. (Fig. 76, C.) Not only are the centra flattened discs, very much broader and higher than they are long, and deeply biconcave (circumstances in which they resemble the vertebræ of some Labyrinthodonts and Fishes), but the only transverse processes they possess are tubercles, developed from the sides of these centra; and the neural arches are connected with two flat surfaces, one on each side of the middle line of the upper surface of the vertebræ, by mere synchondroses. The neural arches themselves are forked bones, with only rudiments of zygapophyses, and in the greater part of the body do not become articulated with one another at all.

In the cervical region, if one may call "neck" the most anterior part of the vertebral column, the front part of the lateral surface of each vertebra presents two separate

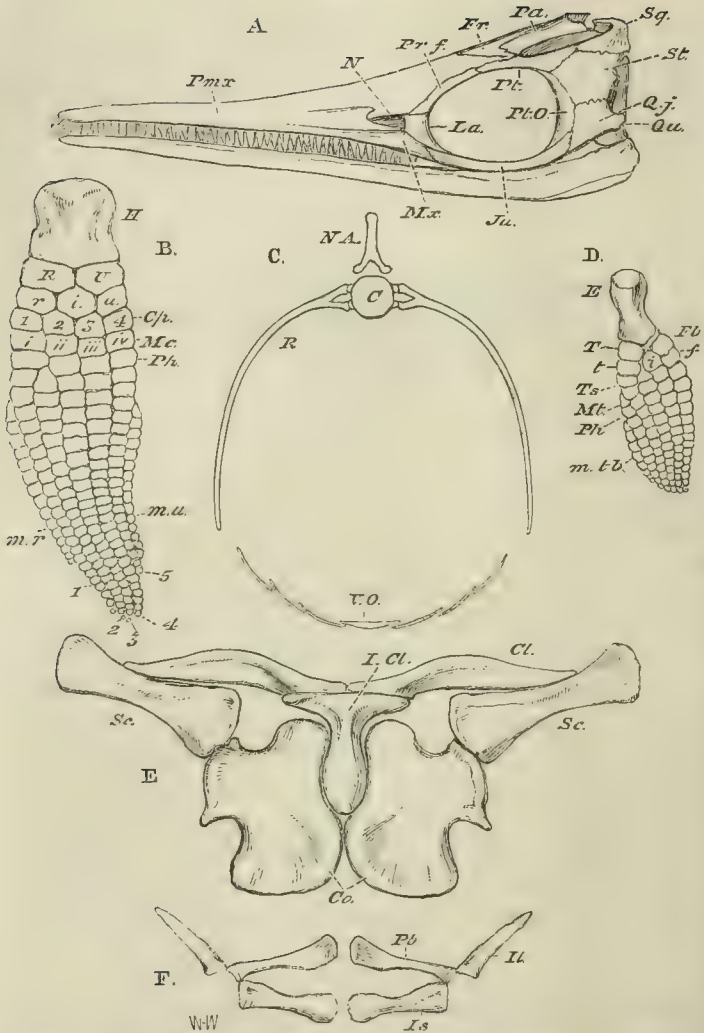


Fig. 76.—Different parts of the skeleton of *Ichthyosaurus intermedius*, drawn to the same scale. A, the skull; B, the fore limb:—*H*, humerus; *R*, radius; *U*, ulna; *r. i. u.*, radiale, intermedium, ulnare; *Cp*, carpalia; 1, 2, 3, 4, 5, digits; *m.r. m.u.* radial and ulnar marginal ossicles.—C, a dorsal vertebra, with the ribs (*R*) and ventral ossifications (*V.O.*).—D, the hind limb: *F*, femur; *T*, tibia; *Fb*, fibula; *t, i, f*, tibiale, intermedium, fibulare; *Ts*, tarsalia; *Mt*, metatarsalia; *Ph*, phalanges; *m, tb*, tibial marginal ossicles.—E, the pectoral arch, seen from the ventral side; F, the same aspect of the pelvic arch.

elevations, or articular surfaces, which are at first situated in the upper half of the lateral surface. Towards the posterior half of the dorsal region they descend, and, gradually approaching one another, coalesce into one in the caudal vertebræ. The form of the proximal ends of the ribs corresponds with the arrangement of these tubercles; for, where they are separate, the proximal end of the rib is forked. The lower fork, or capitulum, goes to the capitular, or lower, tubercle, and the upper branch, or tuberculum, to the upper, or tubercular, elevation. In the caudal region, where the articular surface is single, the proximal end of the rib is also undivided. In the caudal region the ribs are short and straight, but in the precaudal region they are stout and curved, and much longer in the middle than at either end of the series. The atlas and axis resemble the other vertebræ in their general form: but a wedge-shaped bone is, as it were, let in between their opposed lower edges; and a similar bone, attached to the under-part of the concave face of the centrum of the atlas, serves to complete the cup for the occipital condyle.

The skull of *Ichthyosaurus* (Fig. 76, A) is remarkable for the great elongation and tapering form of the snout, the huge orbits, the great supra-temporal fossæ, and the closing over of the infra-temporal fossæ by plates of bone. Again, the two rami of the mandible are united in a symphysis, which, for length, is comparable to that observed in the modern Gavials and in the ancient *Teleosauria*. The basi-occipital bone furnishes the rounded articular condyle to the first vertebra, and becomes very stout and thick in front. It appears to have been ankylosed neither with the basisphenoid nor with the basi-occipital. The latter bones are adapted to its sides, and, together with the supra-occipital, which is interposed between them above, circumscribe the occipital foramen. The basisphenoid, a deep and stout bone, is produced in front into a long and slender parasphenoidal rostrum. There do not appear to have been any ossified alisphenoids. The parietals remain separate throughout life; and, in some species, not merely present

a great parietal foramen close to the coronal suture, but are completely divided by a median fissure. Ossified pre-sphenoids and orbitosphenoids appear to have been altogether absent, and the frontal bones are relatively small. The pro-otic bones are, as usual, situated in front of the ex-occipitals; and between the latter and them there may sometimes be discerned a conical bone with a broad base, which appears to be fitted in between the ex-occipital and the pro-otic. If this bone were not so large, it might well be regarded as a stapes, but it is possible that, as Cuvier suggests, it answers to the separate opisthotic of the *Chelonia*.

In the naso-premaxillary segment, the nasal bones, continuing the direction of the frontals, attain considerable size, but the premaxillæ make up by far the greater part of the snout. The maxillæ are reduced, as in birds, to comparatively small and slender rodlike bones, bounding only a fraction of the gape. The vomers are elongated, and situated in the middle line on the underside of the snout.

The nostrils are small apertures close to the orbits, bounded by the nasal, lachrymal, and premaxillary bones.

On each side of the frontal there is a large prefrontal, which passes back above to meet the postfrontal, and thus bound the orbit. Below, the maxilla is connected with a jugal. From the postfrontal to the jugal, the posterior margin of the orbit is constituted by a distinct, curved, postorbital bone (Fig. 76, A, *Pt.O*). A broad and flat quadrato-jugal (*Q.j.*) passes from the end of the jugal to the lower end of the quadrate, and covers in the lower and posterior part of the infra-temporal fossa. The space between this bone, the postorbital, the postfrontal, and the squamosal is occupied by another flattened bone (Fig. 76, A, *St.*), which Cuvier calls the temporal, but which does not appear to have any precise homologue among other *Reptilia*. The squamosal bone is very large and stout, and forms the postero-external angle of the skull. From this point it sends a process forwards to meet the

postfrontal, inwards to unite with the parietal, and downwards to become connected with the pterygoid. A strong and stout quadrate bone is connected with the exterior of the skull, and presents a pulley-like surface to the articular piece of the mandible.

On the under-surface of the skull the long and slender palatine bones are seen, bounding the posterior nares, which are situated far forwards. Behind, and separated by an interval traversed by the rostrum of the basisphenoid bone, the very large pterygoids commence, by slender and pointed ends, which lie on the inner side of the palatine bones at the level of the posterior nares. They then widen, and passing backwards with a slight outward curvature, on each side of the sphenoidal rostrum, end in three processes—one of which connects itself with the basisphenoid, another passes outwards and backwards to the quadrate, while the third runs upwards to the squamosal bone.

The lower jaw is composed of two rami, which unite, anteriorly, in a very long symphysis. Each ramus is composed of the normal six pieces, the splenial being remarkably long, and entering extensively into the symphysis.

We have no very clear knowledge of the structure of the hyoidean apparatus in this reptile.

The pectoral arch (Fig. 76, E) consists, upon each side, of a narrow scapula (*Sc.*), having the direction usual in *Lacertilia*, and a broad coracoid (*Co.*), the inner edge of which does not overlap its fellow, but meets it throughout in the middle line, as in *Plesiosaurus*; so that, in this genus also, the rhomboidal part of the sternum appears to have been absent or very small.

But there is a very distinct T-shaped interclavicle (*I.Cl.*), the backward prolongation of which is received between the anterior ends of the coracoids, while its horizontal bar is very closely united with the inner ends of two stout curved clavicles (*Cl.*), the outer extremities of which abut against, and are no less closely connected with, the upper part of the anterior edge of each scapula. This arrangement of the clavicles and interclavicle presents interesting

conditions intermediate between those observed in *Nothosaurus*, on the one hand, and those common in the *Lacertilia*, on the other.

The scapula and coracoid give rise by their junction to a glenoidal cavity, into which the thick head of the very short prismatic humerus (Fig. 76, B, *H*) is received. The distal end of the humerus presents two facets, which articulate with a couple of short flattened polygonal bones, which represent the radius and the ulna (*R, U*). To these succeed two rows of smaller polygonal ossicles in the place of a carpus: three, representing the *radiale*, *intermedium*, and *ulnare* (*r. i. u.*), lie in the proximal row, and three or four *carpalia* (*Cp.*) in the distal row. With the distal carpal bones are connected, by means of the metacarpal ossicles (*Mc.*), longitudinal series of very numerous polygonal bones, adapted together by their edges, and becoming gradually smaller towards the distal extremity of each series. The number of complete series does not exceed five, and may be reduced to three—so that the paddle may be pentadactyle, tetradactyle, or tridactyle. An apparent multiplication of the number of digits arises from two causes: first, the occasional bifurcation of some of the digits; secondly, the superaddition of *marginal bones** to the radial and to the ulnar edges of the manus (*m.u., m.r.*). There is thus formed a paddle, which is unlike either that of a Cetacean, or that of a *Plesiosaurus*, or that of a Turtle—departing more than any of these structures from the ordinary form of vertebrate limb.

There is no trace of any sternum behind the pectoral arch, but the abdominal walls were strengthened by a number of transverse arcuated bones, similar to those observed in the *Plesiosauria*, though not so strong. Each is composed of a median piece with pointed ends, and of some three, or more, lateral pieces, overlapping each other's ends, on each side. (Fig. 76, C, *V.O.*)

* I leave open the question whether these series of marginal ossicles are remains of the digits

of a polydactyle manus, such as exists in the Elasmobranch fishes.

The pelvis (Fig. 76, F) is not connected by bone with the vertebral column. It consists of an ilium (*Il.*), an ischium (*Is.*), and a pubis (*Pb.*), uniting together to form an acetabulum, while the pubis and ischium of each side meet in the middle line. The ischium is a narrow and almost rod-like bone, the pubis is somewhat broader, especially at its symphysial end.

The hind limb (Fig. 76, D) has substantially the same structure as the fore limb, but is always smaller, and generally of much less size.

The only other bony structure appertaining to *Ichthyosaurus* that need be noticed, is a circle of plates developed in the sclerotic of the enormous eye, which is frequently met with in a very perfect state of preservation.

It is possible that the *Ichthyosauria* occur in the Trias; they abound in the Lias and in other rocks of Mesozoic date, up to, and including, the Chalk.

Some attain gigantic dimensions, and many species have been founded by the differences in form and proportion of the body and of the teeth; but no one form is sufficiently different from the rest to justify its separation as a distinct genus. They may be roughly grouped into such as have relatively short snouts and short paddles, with four *carpalia* (*I. intermedius, communis, &c.*); and such as have longer snouts, long paddles, and three *carpalia* (*I. longirostris, tenuirostris, platyodon*).

VI. The CROCODILIA.—Crocodiles, the highest living *Reptilia*, are Lacertilian in form, with long tails and four well-developed limbs, the anterior pair being the shorter, and possessing five complete digits, while the hind feet are four-toed. With a single exception, the living species have nails on the three preaxial (radial and tibial) digits, so that two digits are without nails on the forefoot, and one on the hind-foot. The feet are webbed, but the degree to which the web is developed varies greatly. The nostrils are situated at the end of the long snout, and can be closed. The tympanic membranes are exposed, but a cutaneous

valve, or earlid, lies above each, and can be shut down over it. All are partially aquatic in habit, and some (the Gavials) are completely so. None of the existing genera are marine, though many ancient *Crocodylia* inhabited the sea.

The dermal armour is composed of scutes covered by epidermic scales of corresponding form. When the armour is complete—as in *Caiman* and *Jacare* alone among existing *Crocodylia*, in *Teleosaurus* and *Stagonolepis* among extinct forms—it consists of transverse rows of quadrate bony plates, disposed so as to form a distinct dorsal and ventral shield, separated by soft integument, in the trunk, but united into continuous rings on the tail. The scutes of the same row are united suturally; those of each row overlap their successors, which present smooth facets to receive their undersurfaces. In existing *Crocodylia*, in the extinct *Crocodylus Hastingsiæ*, and in *Stagonolepis*, each ventral scute consists of two pieces, a small anterior and a large posterior, united by a suture. The scutes always exhibit a pitted sculpture, and those of the dorsal region are ridged longitudinally, while the ventral scales are always flat. More or fewer dorsal scutes exist in all crocodiles, and those upon the neck sometimes form distinct “nuchal” and “cervical” groups, distinct from the dorsal shield. The dorsal scutes do not always overlap, and the ventral scutes are absent, or incompletely ossified, in most existing *Crocodylia*.

In these reptiles the vertebral column is always thoroughly ossified, and marked out into distinct cervical, dorsal, lumbar, sacral, and caudal regions. The number of the presacral vertebræ is twenty-four; that of the sacral, two, in all the recent forms, and probably in the extinct genera also. The number of the caudal vertebræ varies, but is not less than thirty-five. The number of the cervical, dorsal, and lumbar vertebræ varies; but there are usually nine of the first, eleven or twelve of the second, and four, or three, of the third description.

In existing *Crocodylia* all the vertebræ, except the atlas and axis, the two sacrals, and the first caudal, are procelous,

The majority of the pre-cretaceous *Crocodylia* have the corresponding vertebræ amphicœlous, the concavities of the centra being very shallow. One genus, *Streptospondylus*, which is perhaps Crocodylian, has the anterior vertebræ opisthocœlous. It is characteristic of the *Crocodylia*, that the centra of the vertebræ are united by fibro-cartilages, and that the neurocentral sutures persist for a long time, or throughout life.

The atlas is composed of four pieces, an upper median piece—which is sometimes divided into two, and is developed in membrane apart from the rest—being added to the three pieces found in *Lacertilia* and *Chelonia*. A large odontoid bone is closely united to, but not ankylosed with, the anterior flat face of the second vertebra. A pair of elongated, single-headed ribs are attached to the inferior piece of the atlas, and another similar pair to the os odontoidum and to the second vertebra, by distinct capitular and tubercular processes. The other cervical vertebræ all possess ribs with distinct and long capitula and tubercula—the latter attached above the neurocentral suture to the neural arch, the former to the centrum below the neurocentral suture. The body of each cervical rib, after the second, and as far as the seventh or eighth, is short, and prolonged in front of, as well as behind, the junction of the capitulum with the tuberculum; and the several ribs lie nearly parallel with the vertebral column, and overlap one another. The ribs of the eighth and ninth cervical vertebræ are longer, and take on more the character of the dorsal ribs, the ninth having a terminal cartilage.

The points to which the capitula and tubercula of the ribs are attached are raised into tubercles; and, by degrees, these become elongated into distinct capitular and tubercular processes, between which, in the third to the ninth vertebræ, the neurocentral suture passes. But in the tenth and in the eleventh vertebræ, the capitular process, which lies nearer the neurocentral suture in the posterior than in the anterior cervical vertebræ, rises upon the body of the vertebra to the level of the neurocentral suture, by

which it is traversed, and the tubercular process becomes longer than it. (See Fig. 5, p. 15.) The terminal cartilage is united with the sternum by a sternal rib, which may become more or less completely converted into a cartilage bone, and is articulated with the vertebral rib.

In the twelfth vertebra a sudden change in the character of the transverse processes takes place. There is no longer a capitular, distinct from a tubercular, process, but one long "transverse process" takes the place of both. A sort of step in the base of this process bears the capitulum of the rib, and answers to the capitular process of the cervical vertebræ, while the outer end of the process articulates with the tuberculum of the rib, and represents the tubercular process. The neurocentral suture, in this and the succeeding dorsal vertebræ, lies below the root of the transverse process, which, therefore, is wholly a product of the neural arch. Neither the capitular processes, nor that part of the dorsal transverse process which represents them, have distinct centres of ossification.*

In the succeeding dorsal vertebræ the "step" of the transverse process gradually moves outwards, until at length it becomes confounded with the tubercular facet, and a corresponding change takes place in the proximal ends of the ribs, in the hindermost of which the distinction between capitulum and tuberculum is lost.

The lumbar vertebræ have long transverse processes which arise from the neural arches, *i.e.*, above the neurocentral suture.

The centra of the two sacral vertebræ have their applied and firmly united faces flat, their free faces concave; consequently, the first has the anterior face concave and the posterior flat, while the second has the anterior surface flat and the posterior concave. Each sacral vertebra has a strong rib expanded at its distal end; and wedged in, at its

* Thus, if it be a part of the definition of a "*parapophysis*," that it is antogenous, there are no parapophyses in the vertebræ of the *Crocodylia*; and, if it be

part of the definition of a "*parapophysis*" that it arises from the centrum, the dorsal vertebræ of the *Crocodylia* have no parapophyses.

proximal end, between rough sutural surfaces furnished by the neural arch above and the centrum below.

The first caudal vertebra is biconvex, but all the others are procœlous; those of the anterior moiety of the tail have long ribs fixed in between the neural arches and centra, as in the sacrum, and becoming ankylosed in that position. Chevron bones are attached to the posterior edges of the centra of the vertebræ, except that of the first, and those of the posterior part of the tail.

From seven to nine of the anterior dorsal ribs are united with the sternum by sternal ribs, the form of which varies a good deal in different *Crocodylia*, being sometimes narrow, sometimes broad and flattened. An elongated plate of cartilage, which may be partially converted into cartilage bone, is attached to the hinder margin of several of the most anterior ribs, above the junction between the ossified and the cartilaginous part of the vertebral rib. (Fig. 5, *P.u.*) These are the so-called "uncinate processes," which also exist in *Hatteria*, and reappear in Birds.

The sternum consists of a rhomboidal plate of cartilage bone, with the posterolateral edges of which two pairs of sternal ribs articulate. The posterior angle of the plate is continued into a median prolongation, which, at length, divides into two curved divergent cornua. From five to seven pairs of sternal ribs are united with the prolongation and its cornua. A long and slender interclavicle lies in a groove of the middle of the ventral face of the rhomboidal part of the sternum.

In the ventral wall of the abdomen, superficial to the *recti* muscles, lie seven transverse series of membrane bones, which are termed "abdominal ribs;" though it must be recollected that they are quite distinct from true ribs, and rather correspond with the dermal ossicles of the *Labyrinthodonta*. Each series is composed of four elongated and more or less curved ossicles, pointed at each end, and so disposed that inner ends of the inner pair meet at an angle, open backwards in the middle line, while their outer ends overlap the inner ends of the outer pair. The most

posterior of these ossicles are stronger than the others, and are closely connected with the pubic cartilages.

In the Crocodilian skull the following are the chief peculiarities which are worthy of especial notice:—

1. There is an interorbital septum, and the presphenoidal

Fig. 77.

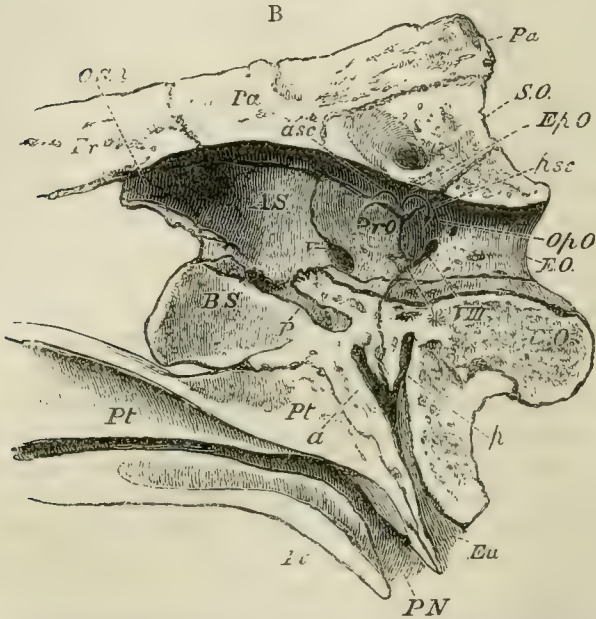


Fig. 77.—Longitudinal and vertical section of the hinder part of the skull of a Crocodile:—*Eu*, Eustachian tube; *P N*, posterior nares *P*, pituitary fossa.

and orbitosphenoidal regions remain cartilaginous, or very incompletely ossified.

2. All the bones of the skull (except the mandible, stapes, and hyoid) are firmly united by sutures, which persist throughout life.

3. There are large parotic processes. Both the upper and the lower temporal arcades are completely ossified, and formed by postfrontal, squamosal, jugal, and quadrato-jugal

bones; supra-temporal, lateral-temporal, and post-temporal fossæ are formed, as in the *Lacertilia*, though their relative sizes are very different.

4. The maxillary and the palatine bones develop palatine plates, which unite suturally in the middle line, and separate the nasal passages from the cavity of the mouth, as in *Mammalia*; and in all existing Crocodiles, but not in *Teleosaurus* or *Belodon*, the pterygoids are also modified in the same way (as in *Mymercophaga* among Mammals), so that the posterior nares are situated very far back beneath the base of the skull.

5. In consequence of the development of these palatine plates of the maxillary and palatine bones, the two vomers are, in most Crocodiles, invisible upon the under-surface of the bony roof of the mouth.

6. There are large alisphenoids, but the orbitosphenoids are absent or rudimentary.

7. There is no parietal foramen.

8. The quadrate bone is very large, and fixed immoveably to the walls of the skull, as in the *Chelonia*; and, as in the latter, the pterygoid bone is firmly connected with the base of the skull, and united only with the upper and inner surface of the quadrate bone.

9. The pterygoid sends down a large free process, against the broad outer edge of which the inner surface of the mandible plays.

10. The tympanic cavity is completely bounded by bone. The pro-otic and opisthotic (which is united with the ex-occipital) form its inner walls, the quadrate its outer wall, the squamosal and postfrontal its roof, and the quadrate, the basi-occipital, and basisphenoid its floor. The two tympana are placed in communication with the cavity of the mouth by three canals—one large, opening in the middle line; and two smaller ones at the sides, on the base of the skull, behind the posterior nares. The large canal passes up between the basisphenoid and basi-occipital, and divides between those bones into a right and left lateral canal. Each lateral canal subdivides into an anterior

branch, which traverses the basisphenoid, and a posterior, which passes up in the basi-occipital. The posterior branch receives the narrow lateral canal of its side (which runs vertically up to it), and then opens into the posterior part of the floor of the tympanum. The anterior branch opens into its anterior wall.

The tympanic cavities of embryonic Crocodiles communicate with the mouth by wide and simple apertures, and the complicated arrangement of canals just described results from the great downward development of the basisphenoid and basi-occipital, and their encroachment upon these apertures on the inner side, while the quadrate bone narrows them on the outer.

In adult *Crocodylia*, air-passages extend from each tympanum to that of the opposite side, through the bones which form the roof of the posterior region of the skull. On the other hand, they excavate the quadrate bone, from whence the air passes through a membranous tube into the hollow articular piece of the mandible. The hyoidean apparatus is greatly simplified, consisting only of a broad plate of cartilage, which may become partially ossified, and of two ossified cornua which are not directly connected with the skull. A minute styloform cartilage, which lies in close proximity with the *portio dura*, on the upper part of the posterior face of the quadrate bone, represents the *stylohyal*, or proximal end of the hyoidean arch.

The pectoral arch has no clavicle, and the coracoid has no distinct epicoracoidal element, nor any fontanelle. The carpus consists proximally of two elongated and somewhat hourglass-shaped bones, articulated respectively with the radius and the ulna. The radial is the larger, and is partially articulated with the ulna. Behind these, and directed transversely, lies another curved ossification, the upper concave face of which articulates with the ulna. It is united with the latter bone on the one hand, and with the fifth metacarpal, on the other, by strong ligaments, and represents a pisiform bone. Distally, there lies on the ulnar side the so-called *lenticular* bone, an oval ossicle interposed between

the ulnar proximal carpal and the second, third, fourth, and fifth metacarpals, the three last of which it supports altogether. On the radial side, a disk of cartilage, which never becomes completely ossified, is connected by ligament with the *lenticulare*, and is interposed between the radial proximal bone and the head of the metacarpal of the pollex. From the ulnar side of the head of this bone a cartilaginous ligamentous band proceeds, over the head of the second metacarpal, to the radial side of the *lenticulare*.

The three radial digits are much stronger than the two ulnar, and the numbers of the phalanges are 2, 3, 4, 4, 3, counting from the radial to the ulnar side.

The pelvis (Fig. 78, C) possesses large ilia, which are firmly united with the expanded ends of the strong ribs of the sacrum. The ischium unites with its fellow in a median ventral symphysis, and, with the ilium, forms almost the whole of the acetabulum.

The pubes take hardly any share in the formation of the latter cavity in the adult. Their axes are directed forwards and inwards, and they coalesce in the middle line; but as the inner, or median, moiety of each pubis remains cartilaginous, or imperfectly ossified, the bones, in imperfectly prepared skeletons, appear as if they formed no symphysis.

The tarsus presents, proximally, an astragalo-navicular bone and a calcaneum, which are less closely united than in the Lizards. The latter bone has a large calcaneal process on its posterior face, the Crocodile being the only Sauropsid vertebrate in which such a process is developed (Fig. 78, C. *Ca.*)

Two rounded distal tarsal bones, of which the fibular is much the larger, lie between the calcaneum and the third, fourth, and rudimentary fifth, metatarsals. A thin plate of cartilage is interposed between the distal end of the astragalo-navicular and the second metatarsal, and unites with the head of the first metatarsal.

As in the manus, the three, pre-axial, clawed, digits are stronger than the others. The fifth is represented only by an imperfect metatarsal. The numbers of the phalanges are 2, 3, 4, 4, counting from the tibial to the fibular side.

In the *Crocodylia* the teeth are confined to the premaxillæ, maxillæ, and dentary part of the mandible. They are simple in structure, have large pulp cavities, are lodged in distinct alveoli, and are replaced by others developed upon their inner sides. The development of the new tooth causes absorption of the inner wall of the base of the old one, and the replacing tooth thus comes to lie within the pulp cavity of its predecessor. The teeth vary much in shape, having either long, curved, and acute, or short and obtuse, or almost globular and straight, crowns. Very often they possess sharp anterior and posterior edges, which may be finely serrated.

The *Crocodylia* are to be found in the rivers of all continents and the larger islands in the hotter parts of the world. None of the existing species are truly marine, though many of the extinct species were. They are first known to occur in strata of Triassic age, and abound, under forms which differ but little from some of those which now exist, in the Mesozoic and Cainozoic formations.

They may be divided into the following groups:—

- A. With procœlous presacral vertebræ, and posterior nares bounded below by the pterygoids. (All existing *Crocodylia*, and the fossil forms of cretaceous and later formations, are included in this division.)
 - a. The nasals enter into the formation of the nasal aperture.
 - a. The head short and broad. The teeth very unequal; the first and fourth of the mandibles biting into pits of the upper jaw. The premaxillo-maxillary suture straight or convex forwards. The mandibular symphysis not extending beyond the fifth tooth, and the splenial element not entering into it. The cervical scutes distinct from the tergal.
 1. *Alligatoridæ*.
Alligator. Caiman. Jacare.
 - b. The head longer. The teeth unequal. The first mandibular tooth biting into a fossa; the fourth, into a groove, at the side of the upper jaw. The premaxillo-maxillary suture straight or convex backwards. The mandibular symphysis not extending beyond the eighth tooth, and not involving the splenial elements. The cervical scutes sometimes distinct from the tergal, sometimes united with them.
 2. *Crocodylidæ*.
Crocodylus. Mecistops.

- b. The nasals are excluded from the external nasal aperture. The head very long; the teeth subequal. Both the first and the fourth mandibular teeth bite into grooves in the margin of the upper jaw. The premaxillo maxillary suture acutely angulated backwards. The mandibular symphysis extends to at least the fourteenth tooth, and the splenials enter into it. The cervical and tergal scutes form a continuous series.

3. *Gavialidæ*.

Rhynchosuchus. Gavialis.

- B. With the presacral vertebræ amphicœlous (the anterior vertebræ sometimes opisthocœlous (?)); and the posterior nares bounded by the palatines, the pterygoids not being united below. (All these Crocodiles are extinct and pre-cretaceous.)

- a. With the external nares terminal.

4. *Teleosauridæ*.

Teleosaurus. Goniopholis.

Streptospondylus. Stagonolepis. Galesaurus (?).

- b. With the external nares on the upper part of the base of the snout near the orbits.

5. *Belodontidæ*.

Belodon.

There is a large number of extinct *Reptilia* which resemble the *Crocodylia* in the characters of their pre-sacral vertebræ, but differ from them, and resemble *Lacertilia Chelonia*, or Birds, in other respects.

These are the *Dicynodontia*, the *Ornithoscelida*, and the *Pterosauria*.

VII. The DICYNODONTIA.—*Dicynodon* and *Oudenodon* are lacertiform animals, sometimes of large size, with crocodilian vertebræ, four or five of which are ankylosed together to form a strong sacrum. The skull is massive and lacertilian in most of its characters; but the jaws are like those of the *Chelonia*, and were doubtless cased in a horny beak. Nevertheless, most of the species possess two great tusks, which grow from persistent pulps, lodged in a deep alveolus of either maxilla. The limbs appear to have been subequal and massive, with short and stout feet. The scapula and coracoid are simple and expanded, and there seems to have been no clavicle. The pelvis is very strong, with widely expanded ilia, ischia, and pubes. The two latter meet in a median ventral symphysis, and the pubis and ischium of each side meet and obliterate the

obturator foramen. The limb-bones are lacertilian in character.

Fig. 78.

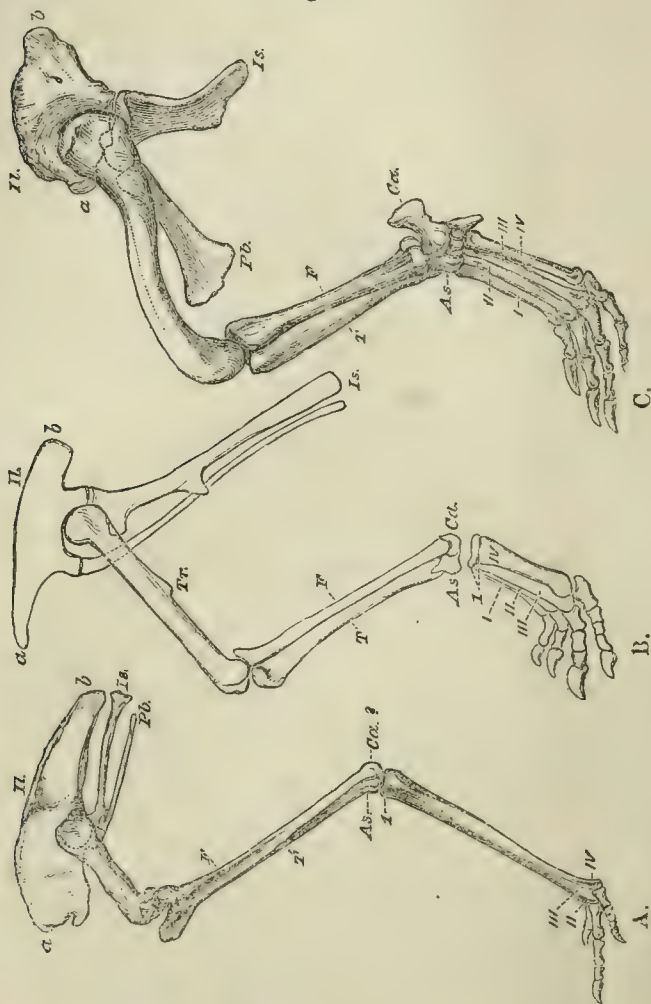


Fig. 78.—The pelvis and hind limb of, A., *Dromæus*; B., an ornithoscelid reptile, such as *Iguanodon*, or *Hypsilophodon*; and C., a Crocodile. The bird's limb is in its natural position, as is that of the Ornithoscelid, though the metatarsus of the latter may not, in nature,

have been so much raised. The Crocodile's limb is purposely represented in an unnatural position. In nature, the femur would be turned out nearly at right angles to the middle vertical plane of the body, and the metatarsus would be horizontal. The letters are the same throughout. *Il*, ilium; *Is*, ischium; *Pb*, pubis; *a*, anterior process, *b*, posterior process, of the ilium; *Tr*, inner trochanter of the femur; *T*, tibia; *F*, fibula; *As*, astragalus; *Ca*, calcaneum. *I*, *II*, *III*, *IV*, the digits.

Remains of these Reptiles have hitherto been found only in strata, which probably belong to the Triassic formation, in India and South Africa, and the Ural mountains.

VIII. The ORNITHOSCELIDA.—The very remarkable extinct reptiles which constitute this group, present a large series of modifications intermediate in structure between existing *Reptilia* and *Aves*.

This transitional character of the Ornithoscelidan skeleton is most marked in the pelvis and hind limbs.

If the pelvis of any existing reptile be compared with that of any existing bird, the following points of difference will be observed:—

1. In the reptile (Fig. 78, C.), the ilium is not prolonged in front of the acetabulum; and the acetabulum is either wholly closed by bone, or presents only a moderate-sized fontanelle, as in the *Crocodylia*.

In the bird (Fig. 78, A.), the ilium is greatly prolonged in front of the acetabulum, and the roof of the acetabular cavity is a wide arch, the inner wall of that cavity remaining membranous. The anterior pier of the arch, or præ-acetabular process, extends further downwards than the posterior pier, or post-acetabular process.

But, in all the *Ornithoscelida*, the ilium extends far in front of the acetabulum, and furnishes only a widely arched roof to that cavity, as in birds. It retains a reptilian character in the further proportional extension of the post-acetabular process downwards (Fig. 78, B.).

2. The ischium, in the reptile (Fig. 78, C.) is a moderately elongated bone, which becomes connected with the pubis in the acetabulum, and extends downwards, inwards, and some-

what backwards, to unite with its fellow in a median ventral symphysis. The obturator space is not interrupted by any forward process of the outer and anterior half of the ischium.

In all birds (Fig. 78, A.), the ischium is elongated and inclined backwards, the backward direction being least marked in *Apteryx*, and most in *Rhea*. The ischia never come together directly in a median ventral symphysis, though they unite dorsally in *Rhea*. The anterior edge of the external, or acetabular, half of the ischium very generally sends off a process which unites with the pubis, thus dividing the obturator space.

In all the *Ornithoscelida* (Fig. 78, B.), in which I have been able to identify the bone (*Thecodontosaurus*, *Teratosaurus*, *Megalosaurus*, *Iguanodon*, *Stenopelyx*, *Hadrosaurus*, *Hypsilophodon*), the ischium is greatly elongated. In *Iguanodon* it has the *obturator* process characteristic of the same bone in Birds; and I imagine that the same process is seen in *Compsognathus*. In *Hypsilophodon* there can be no mistake about the matter, and the remarkable slenderness and prolongation of the ischium give it a wonderfully ornithic character. In *Iguanodon* the slenderness and prolongation are even carried beyond what is to be seen in Birds. I am disposed to think, however, that, as was certainly the case in *Hypsilophodon*, the ischia united in a median ventral symphysis in all the *Ornithoscelida*.

3. In all reptiles the pubis is inclined forwards, as well as downwards, towards the ventral median line. In all, except the Crocodile, it takes a considerable share in the formation of the acetabulum; and the ossified pubis unites directly with its fellow in the middle line.

The pubes of *Compsognathus* are, unfortunately, obscured by the femora. They seem to have been very slender; and to have been directed forwards and downwards, like those of lizards. Some lizards, in fact, have pubes which, if the animal were fossilized in the same position as *Compsognathus*, would be very similar in form and direction. *Hypsilophodon*, however, affords unequivocal evidences of a further

step towards the bird. The pubes are not only as slender and elongated as in the most typical bird, but they are directed downwards and backwards parallel with the ischia, thus leaving only a very narrow and elongated obturator foramen, which is divided by the obturator process.

It remains to be seen how far the hypsilophodont modification extended among the *Ornithoscelida*. The remains of *Compsognathus* and of *Stenopelyx* tend to shew that it was by no means universal.

As to the hind limb, in existing reptiles:—

1. The proximal end of the tibia has but a very small, or quite rudimentary, cnemial crest, and it presents no ridge for the fibula on its outer side.

2. The flattened sides of the distal end of the tibia look, the one directly forwards, or forwards and inwards; and the other backwards, or backwards and outwards. And when the posterior edges of the two condyles of the proximal end of the tibia rest on a flat surface which looks forwards, the long axis of the distal end is either nearly parallel with that surface, or is inclined obliquely from in front and without, backwards and inwards.

3. There is no depression on the anterior face of the tibia for the reception of an ascending process of the astragalus.

4. The distal end of the fibula is as large as, or larger than, the proximal end, and articulates largely with a facet on the outer part of the astragalus.

5. The astragalus is not depressed and flattened from above downwards, nor does it send a process upwards in front of the tibia.

6. The astragalus remains quite free from the tibia.

In all these respects the leg of any existing bird (see Fig. 78), is very strikingly contrasted with that of the reptile.

1. The proximal end of the tibia is produced forwards and outwards into an enormous cnemial crest, in all walking and swimming birds (Fig. 78, A.); and, on the outer side, there is a strong ridge for the fibula.

2. When the posterior edges of the condyles of the tibia rest upon a flat surface, the one flat face of the distal end

of the bone looks outwards as well as forwards, and the other inwards as well as backwards. Further, the long axis of the distal end is inclined, at an angle of 45° to the flat surface, from within and in front, backwards and outwards, thus exactly reversing the direction in the reptile.

3. There is a deep longitudinal depression on the anterior face of the distal end of the tibia, which receives an ascending process of the astragalus.

4. The distal end of the fibula is a mere style, and does not articulate with the astragalus.

5. The astragalus is a much-depressed bone, with a concave proximal, and a convex, pulley-like, distal, surface. A process ascends from its front margin in the groove on the front face of the tibia. This process is comparatively short, and perforated by two canals for the *tibialis anticus* and *extensor communis*, in the Fowl; while in the Ostrich and Emeu it is extremely long and not so perforated.

6. The astragalus becomes ankylosed with the tibia (though it remains distinct for a long time in the Ostrich and *Rhea*, and in some breeds of fowls).

In the *Ornithoscelida* :—

1. There is a great cnemial crest and a ridge for the fibula.

2. The disposition of the distal end of the tibia is literally that observed in the Bird.

3. There is a fossa for the reception of the ascending process of the astragalus.

4. The distal end of the fibula is much smaller than the proximal, though not so slender as in *Aves*.

5. The astragalus is altogether similar to that of a bird, with a short ascending process.

6. The astragalus appears to have remained distinct from the tibia throughout life in *Iguanodon*, *Megalosaurus*, and many other genera; but it seems to have become ankylosed in *Compsognathus*, *Ornithotarsus*, and *Euskelosaurus*.

The reptiles belonging to this group are for the most part of very large size, and some of them, as the *Iguanodon*, are among the largest of known terrestrial animals. They

occur throughout the whole range of the Mesozoic formations, being represented by *Thecodontosaurus*, *Palæosaurus*, *Teratosaurus*, *Plataeosaurus*, and other genera in the Trias; by *Scelidosaurus* in the Lias: by *Megalosaurus*, *Poikilopleuron*, *Euskelosaurus*, *Hylæosaurus*, *Polacanthus*, *Acanthopholis*, *Iguanodon*, *Hadrosaurus*, *Trachodon*, and *Laelaps* in the middle and upper Mesozoic strata.

There is no evidence that *Megalosaurus*, or *Iguanodon*, possessed any dermal armour; but several genera (*e.g.*, *Scelidosaurus*, *Hylæosaurus*, and *Acanthopholis*) had osseous dermal scutes, sometimes produced into prodigious spines.

The faces of the centra of the vertebræ are slightly amphicœlous, or nearly flat; but those of the anterior dorsal and cervical regions seem, in some cases, to have been opisthocœlous. The sacrum seems to have consisted of at fewest four vertebræ, which in some (*Scelidosaurus*) are crocodilian, in others (*Megalosaurus*) take on a somewhat ornithic character. The caudal region had many and long vertebræ, between which the chevron bones are attached. The rami of the chevron bones have their vertebral ends united by bone.

The thoracic vertebral ribs are very strong; but the sternal ribs and sternum are unknown. However, there is some reason to think that the sternum was broad and expanded. Abdominal dermal ribs are developed in some species, if not in all.

The structure of the skull seems to have been intermediate, in many respects, between the crocodilian and the lacertilian types. In *Iguanodon* and *Hypsilophodon*, the extremities of the premaxillæ appear to have been edentulous and beak-like; and the symphysis of the mandible is excavated to receive the beak, almost as in the mandible of a Parrot.

The teeth vary extremely, from the sharp, recurved, serrated fangs of *Megalosaurus*, to the broad grinders, wearing down by mutual attrition, of *Iguanodon*. Their mode of implantation varies, but they are not ankylosed to the jaws.

The scapula is vertically elongated, narrow, and devoid of

any acromial process; the coracoid rounded and without fontanelles or processes.

No *Ornithoscelidan* is known to have possessed a clavicle.

The fore-limb is shorter, and often much shorter, than the hind-limb. The structure of the manus is not certainly known.

The femur usually has a strong inner trochanter; and its distal end is particularly bird-like, in the development of a strong ridge, which plays between the tibia and the fibula.

The metatarsals are elongated, and fit together in such a way that they can hardly, if at all, move on one another. The inner and outer digits are either shorter than the rest, or quite rudimentary; and the third digit is the longest, as in birds in general.

The *Ornithoscelida* are divisible into two sub-orders, the *Dinosauria* and the *Compsognatha*. The type of the latter division is the wonderful little extinct reptile, *Compsognathus*, which differs from the *Dinosauria* in the great length of the centra of the cervical vertebræ, and in the femur being shorter than the tibia. It has a light bird-like head (provided with numerous teeth), a very long neck, small anterior limbs, and very long posterior limbs. The astragalus appears to have been ankylosed with the tibia, as in birds. A single specimen only of this reptile has been obtained, in the Solenhofen slates.

IX. The PTEROSAURIA.—The flying Reptiles, which belong to this group, and are commonly known as Pterodactyls, are, and long have been, extinct, their remains occurring only in Mesozoic rocks, from the Lias to the Chalk inclusively.

They are all remarkable for their proportionally long heads and necks, and for the great size of the anterior limb, the ulnar finger of which, enormously elongated and devoid of a claw, appears to have supported the outer edge of an expansion of the integument, like the patagium of a Bat (Fig. 79).

The vertebral column is distinctly divided into cervical,

dorsal, sacral, and caudal regions, the cervical vertebræ being, as in Birds, the stoutest of all. The atlas and axis

Fig. 79.

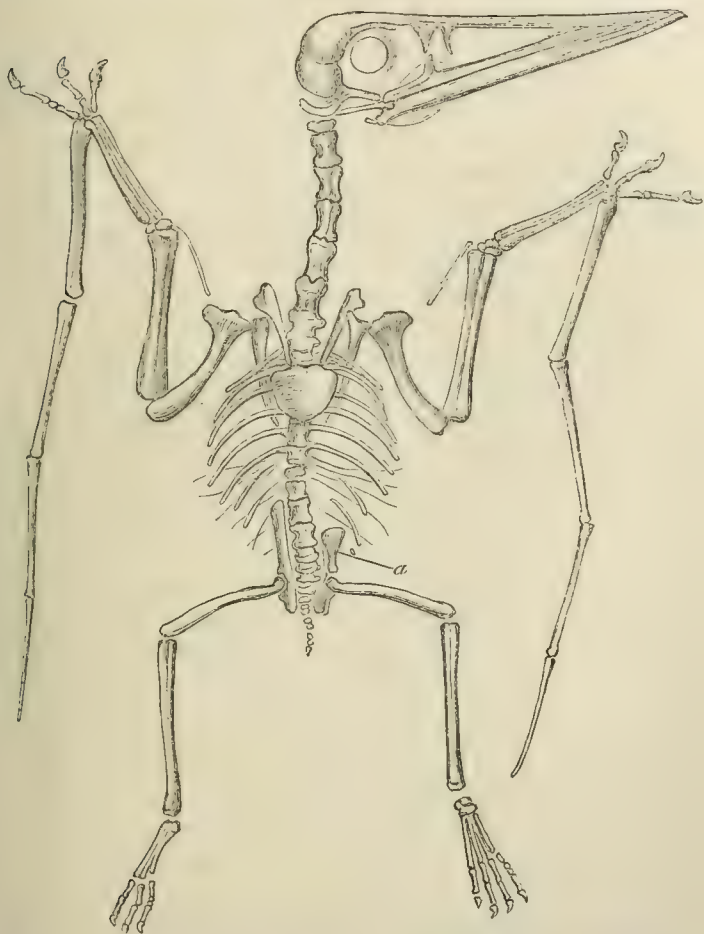


Fig. 79.—The nearly entire skeleton of *Pterodactylus spectabilis* (Von Meyer) as shown by the two halves of a split block of lithographic slate. *a*, the left pre-pubic bone: on the right side this bone is not shown and the ilium is exposed.

are ankylosed together, at least in the cretaceous species. The other cervical vertebræ, apparently not more than six

or seven in number, have low, or obsolete, spinous processes; and, like the vertebræ of the rest of the spine, are procœlous, and have the neuro-central suture obliterated. The existence of cervical ribs is doubtful. From fourteen to sixteen vertebræ intervene between the cervical and the sacral regions; and not more than one or two of the hindermost of them, if any, are devoid of ribs. The number of vertebræ ankylosed together to form the sacrum, is not fewer than three, nor more than six.

The tail is very short in *Pterodactylus*, and, in this genus, all the vertebræ are moveable upon one another; but, in *Rhamphorhynchus*, it is extremely long, and the vertebræ are immoveably fixed by what appear to be ossified ligamentous fibres.

The vertebral ribs are slender, and the anterior ones, at any rate, have distinct capitula and tubercula. There are ossified sternal ribs, and splint-like abdominal ribs. The sternum is broad, and, unlike that of other *Reptilia*, is very completely ossified, and bears a strong median crest on the anterior part of its ventral surface. No median posterior prolongation has been observed in connection with it.

The brain case is more rounded and bird-like than in the other *Reptilia*, and, in many other respects, the skull approaches that of birds. Thus, the occipital condyle is on the base of the skull, not on its posterior face; the cranial bones ankylosed very early; the orbits are very large, and the external nares are situated close to them. The premaxillæ are very large, the maxillæ slender, and the dentary pieces of the mandible are fused together into one bony mass, without any trace of a symphyseal suture.

The resemblance to birds is still further increased, in some species, by the presence of wide lachrymo-nasal fossæ between the orbits and the nasal cavities, and by the prolongation of the extremities of the premaxillæ and of the symphyseal part of the mandible into sharp, beak-like processes, which appear to have been covered with horny sheaths. But the reptilian type is kept up by the presence of a distinct postfrontal, which unites with the squamosal,

and thus gives rise to a supra-temporal fossa. The post-frontal and the jugal unite behind the orbit, in Lacertilian fashion; and both the upper and the lower jaws contain teeth. The sclerotic is supported by a ring of bones, as in many other *Sauropsida*.

The scapula and the coracoid are wholly unlike these structures in any other *Sauropsida*, but are extremely similar to the same parts in birds, and indeed to the shoulder girdle of the less reptilian *Carinatae*. The scapula is slender and blade-like, and its long axis is inclined, at less than a right angle, to that of the coracoid. The glenoidal surface is cylindroidal, concave from above downwards, convex from side to side. The coracoid, elongated and comparatively narrow, is devoid of fontanelle, epicoracoid, or procoracoid.

No trace of any clavicle has been discovered.

The humerus has a great deltoid ridge or process. The radius and ulna are equal in size and separate. There are four distinct metacarpal bones, that on the ulnar side being very much stronger, though not longer, than the others. Another styloform bone attached to the carpus does not appear to have belonged to the metacarpal series. The radial metacarpal bears two phalanges; the second, three; the third, four, so that these represent the pollex and the succeeding digits of the Lizard's manus. The terminal phalanx of each of these digits is strong and curved, and was doubtless ensheathed in a horny claw. The fourth, like the corresponding digit in the Crocodile, has four phalanges, the last of which is straight and bears no nail. But these phalanges are enormously elongated and of great relative strength. A strong process projects from the dorsal side of the proximal end of the first phalanx, and doubtless gave attachment to the tendon of a correspondingly powerful extensor muscle. The articular surface below and behind it, is concave, and plays over the convex distal pulley of the fourth metacarpal.

The pelvis is remarkably small. The ilia are elongated bones, produced both anteriorly and posteriorly, as in Birds;

but the rest of the pelvis is not at all ornithic. The flat and broad ischia appear to be united with the pubes into wide bony plates, which pass, at right angles with the ilia, to their median ventral symphysis. A large spatulate bone articulates with each pubis near the symphysis, and seems to be an exaggeration of the pre-pubic process of *Lacertilia* and *Chelonia*. Or it may be (though I do not think this very probable) that the broad flat plates correspond almost altogether to the ischia, and that the spatulate ossifications are the pubes; in which case the structure of the pelvis would be a sort of extreme exaggeration of that observed in the *Crocodilia*.

The hind limb is small compared with the fore limb. The fibula is imperfect, and appears to coalesce with the tibia at its distal end. The structure of the tarsus requires further elucidation. In some *Pterosauria* there seem to be only four digits, with, perhaps, a rudiment of a fifth, in the pes; but others, such as *Rhamphorhynchus Gemmingi*, have five digits in the foot. Where there are only four, each digit is terminated by a curved and pointed unguis phalanx, and the number of the phalanges from the tibial to the fibular side is 2, 3, 4, 5. These digits, therefore, are the hallux, and the three which immediately follow it; and the rudimentary digit is the fifth.

The long bones of the *Pterosauria* have thin walls, inclosing a large cavity, which appears to have contained air, as in many birds; and pneumatic foramina are visible on the sides of the vertebræ.

The remains of more than twenty species of *Pterosauria* have been discovered. Some of them are exquisitely preserved in the fine matrix of the lithographic stone of Solenhofen.

They are thus grouped into genera:—

A. With two joints in the ulnar digit of the manus.

Ornithopterus.

B. With four joints in the ulnar digit.

a. The jaws strong, pointed, and toothed to their anterior extremities. The tail very short. The metacarpus usually longer than half the length of the antebrachium.

Pterodactylus.

b. The extremities of the jaws produced into toothless beaks, probably ensheathed in horn. The tail very long. The metacarpus shorter than half the length of the antibrachium.

a. All the mandibular teeth similar.

Rhamphorhynchus.

b. The posterior teeth for the most part very short. The anterior long.

Dimorphodon.

I am much inclined to suspect that the fossil upon which the genus *Ornithopterus* has been founded, appertains to a true Bird.

CHAPTER VI.

THE CLASSIFICATION AND THE OSTEOLOGY OF BIRDS.

THE class *Aves*.—Though this class contains a great number of specific forms, the structural modifications which they present are of comparatively little importance; any two birds which can be selected differing from one another far less than the extreme types of the *Lacertilia*, and hardly more than the extreme forms of the *Chelonia*, do. Hence the characters by which the following groups are separated appear almost insignificant when compared with those by which the divisions of the *Reptilia* are indicated.

A. The metacarpals not ankylosed together. The tail longer than the body.

I.—SAURURÆ.

1. *Archæopterygida*.

B. The metacarpals ankylosed together. The tail considerably shorter than the body.

A. The sternum devoid of a keel.

II.—RATITÆ.

a. The wing with a rudimentary, or very short, humerus and with not more than one unguis phalanx.

α. A hallux.

2. *Apterygida* (The Kiwis).

β. No hallux.

3. *Dinornithida* (The Moas).

4. *Casuarida* (The Cassowaries).

b. The wing with a long humerus and with two unguis phalanges.

α. The ischia uniting immediately beneath the sacrum, and the pubes free.

5. *Rheida* (The American Ostriches).

β. The ischia free and the pubes uniting in a ventral symphysis.

6. *Struthionida* (The Ostriches).

B. The sternum provided with a keel.*

* The keel is rudimentary in the singular Parrot *Strigops*.

III. CARINATÆ.

a. The vomer broad behind, and interposing between the pterygoids, the palatines, and the basisphenoidal rostrum.

(*Dromæognathæ.*)

7. *Tinamomorphæ* (The Tinamous).

b. The vomer narrow behind: the pterygoids and palatines articulating largely with the basisphenoidal rostrum.

a. The maxillo-palatines free.*

i. The vomer pointed in front.

(*Schizognathæ.*)

8. *Charadriomorphæ* (The Plovers).

9. *Cecomorphæ* (The Gulls).

10. *Spheniscomorphæ* (The Penguins).

11. *Geranomorphæ* (The Cranes).

12. *Turnicimorphæ* (The Hemipods).

13. *Alectoromorphæ* (The Fowls).

14. *Pteroclomorphæ* (The Sand-grouse).

15. *Peristeromorphæ* (The Pigeons).

16. *Heteromorphæ* (The Hoazin).

ii. The vomer truncated in front.

(*Ægithognathæ.*)

17. *Coracomorphæ* (The Passerines).

18. *Cypselomorphæ* (The Swifts).

19. *Celeomorphæ* (The Woodpeckers).

β. The maxillo-palatines united.

(*Desmognathæ.*)

20. *Aetomorphæ* (The Birds of Prey).

21. *Psittacomorphæ* (The Parrots).

22. *Coccygomorphæ* (The Cuckoos, Kingfishers, Trogons).

23. *Chenomorphæ* (The Anserine Birds).

24. *Amphimorphæ* (The Flamingoes).

25. *Pelargomorphæ* (The Storks).

26. *Dysporomorphæ* (The Cormorants).†

* With the exception of *Dicholophus* and some species of *Crax*.

† The subjoined Table, which shows with which of the above groups the old orders of Birds correspond, may be useful to the student:—

I.—ACCIPITRES OF RAPTORES	}	= <i>Aetomorphæ</i> .	
II.—SCANSORES		= <i>Psittacomorphæ</i> ,	<i>Coccygomorphæ</i> (in part).
III.—PASSERES OF INSESSORES	}	= {	<i>Coracomorphæ</i> , <i>Cypselomorphæ</i> , <i>Celeomorphæ</i> , <i>Coccygomorphæ</i> . (in part).

The exoskeleton of Birds consists almost entirely of epidermic structures in the form of horny sheaths, scales, plates, or feathers. No bird possesses dermal ossifications, unless the spurs which are developed upon the legs and wings of some species may be regarded as such.

The feathers are of various kinds. Those which exhibit the most complicated structure are called *pennæ*, or *contour feathers*, because they lie on the surface and determine the contour of the body. In every penna the following parts are to be distinguished:—1. A main stem (*scapus*) forming the axis of the feather, and divided into a proximal hollow cylinder, partly embedded in a sac of the derm, called the *calamus*, or quill; and a distal *vexillum*, or vane, consisting of a four-sided solid shaft, the *rachis*, which extends to the extremity of the feather, and bears a number of lateral processes, the *barbs*. The calamus has an inferior aperture (*umbilicus inferior*), into which the vascular pulp penetrates; and a superior aperture (*umbilicus superior*), situated on the under surface of the feather at the junction of the calamus with the scapus. The barbs are narrow plates, tapering to points at their free ends, and attached by their bases on each side of the rachis. The edges of these barbs are directed upwards and downwards, when the *vexillum* of the feather is horizontal. The interstices between the barbs are filled up by the *barbules*; pointed processes, which stand in the same relation to the barbs, as the barbs do to the rachis. The barbules themselves may be laterally serrated and terminated by little hooks, which interlock with the hooks of the opposed barbules. In very many birds each quill bears two vexilla; the second, called the *aftershaft* (*hyporachis*), being attached on the under side of the first

IV.—GALLINÆ (with COLUMBÆ) = *Alectoromorpha*, *Peristeromorpha*,
Pterocloromorpha, *Turnicimorpha*.

V.—CURSORES = *Ratitæ*.

VI.—GRALLÆ = *Charadriomorpha*, *Geranomorpha*,
Amphimorpha, *Pelargomorpha*.

VII.—PALMIPEDES = *Cecomorpha*, *Spheniscomorpha*,
Chenomorpha, *Dysporomorpha*.

close to the superior umbilicus. The aftershaft is generally much smaller than the chief vexillum; but in some birds, as the *Casuaridæ*, the two are of equal size, or nearly so. Muscles pass from the adjacent integument to the feather sac, and by their contraction erect the feather. The other kinds of feathers differ from the pennæ, in having the barbs soft and free from one another, when they constitute *penno-plumæ*, or *plumulæ* (down), according as the scapus is much or little developed. When the scapus is very long, and the vexillum very small or rudimentary, the feather is termed a *filopluma*.

The contour feathers are distributed evenly over the body only in a few birds, as the *Ratitæ*, the Penguins, and some others. Generally, the pennæ are arranged in definitely circumscribed patches or bands, between which the integument is either bare, or covered only with down. These series of contour feathers are termed *pterylæ*, and their interspaces, *apteria*.

In some birds, such as the Herons, plumulæ of a peculiar kind, the summits of which break off into a fine dust, or powder, as fast as they are formed, are developed upon certain portions of the integument, which are termed *powder down patches*.

The integument of birds is, for the most part, devoid of glands; but many birds have a peculiar sebaceous gland developed in the integument which covers the coccyx. This *uropygial gland* secretes an oily fluid, which the bird spreads over its feathers by the operation of "preening." The excretion passes out by one or two apertures, commonly situated upon an elevation, which may or may not be provided with a special circlet of feathers.

In various birds (*e.g.*, the Turkey) the integument about the head and neck develops highly vascular and sometimes erectile processes (*combs, wattles*).

The spinal column of birds contains numerous and well ossified vertebræ, a considerable number of which (more than six) are ankylosed together to form a sacrum. Of

the vertebræ which enter into the composition of this complex bone, however, not more than from three to five can be regarded as the homologues of the sacral vertebræ of a Crocodilian or Lacertilian reptile. The rest are borrowed, in front, from the lumbar and dorsal regions; behind, from the tail. The cervical region of the spine is always long, and its vertebræ, which are never fewer than eight, and may be as many as twenty-three, are, for the most part, large in proportion to those of the rest of the body.

The atlas is a relatively small, ring-like, bone; and the transverse ligament may become ossified and divide its aperture into two—an upper, for the spinal cord, and a lower, for the odontoid process of the axis vertebra. The *os odontoideum* is always ankylosed with the second vertebra, and constitutes a peg-like odontoid process.

The spines of the succeeding cervical vertebræ are often obsolete, and are never very prominent in the middle region of the neck. The anterior faces of their elongated vertebral centra are cylindroidal, slightly excavated from above downwards, and convex from side to side; while the posterior faces are convex from above downwards, and concave from side to side. Hence, in vertical section, the centra appear procœlous; in horizontal section, opisthocœlous; and this structure is exceedingly characteristic of birds. The under surfaces of the centra frequently give off median inferior processes. In the *Ratitæ*, it is obvious that the cervical vertebræ have short transverse processes and ribs, disposed very much as in the *Crocodylia*. For, in young birds, the anterior end of the lateral face of each vertebra bears two small processes, an upper and a lower; and the expanded head of a styliiform rib is articulated with these by two facets which represent the capitulum and the tuberculum. With age, the cervical ribs may become completely ankylosed; and then they appear like transverse processes, perforated at the base by a canal, which, as in the *Crocodylia*, contains the vertebral artery and vein, and the main trunk of the sympathetic nerve. The cervical ribs and transverse processes are similarly disposed in very young *Carinata*; but in these

birds their form frequently becomes much modified in the adult; and they develop prolongations, which extend downwards and inwards, and protect the carotid artery or arteries.

The neural arches have well developed pre- and post-zygapophyses. The ribs of one or two of the posterior cervical vertebræ become elongated and freely moveable in the *Carinatae*, as in the *Ratitæ*.

The first dorsal vertebra is defined as such, by the union of its ribs with the sternum by means of a sternal rib; which not only, as in the *Crocodylia*, becomes articulated with the vertebral rib, but is converted into complete bone, and is connected by a true articulation with the margin of the sternum.

The number of the dorsal vertebræ (reckoning under that head all the vertebræ, after the first dorsal, which possess distinct ribs, whether they be fixed or free) varies. The centra of the dorsal vertebræ either possess cylindroidal articular faces, like those of the neck, as is usually the case; or, more or fewer of them may have these faces spheroidal, as in the Penguins. In this case, the convex face is anterior, the concave, posterior. They may, or may not, develop inferior median processes. They usually possess well marked spinous processes. Sometimes they are slightly moveable upon one another; sometimes they become ankylosed together into a solid mass.

It is characteristic of the dorsal vertebræ of Birds that the posterior, no less than the anterior, vertebræ present a facet, or small process, on the body, or the lower part of the arch, of the vertebra for the capitulum of the rib, while the upper part of the neural arch gives off a more elongated transverse process for the tuberculum. Thus the transverse processes of all the dorsal vertebræ of a bird resemble those of the two anterior dorsals of a crocodile, and no part of the vertebral column of a bird presents transverse processes with a step for head of the rib, like those of the great majority of the vertebræ of *Crocodylia*, *Dinosauria*, *Dicynodontia*, and *Pterosauria*.

The discrimination of the proper lumbar, sacral and anterior caudal vertebræ, in the ankylosed mass which constitutes the so-called "sacrum" of a bird, is a matter of consider-

Fig. 80.

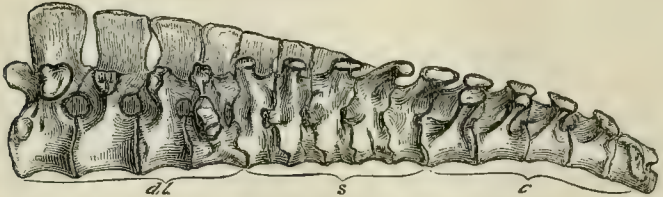

Fig. 80.—The "Sacrum" of a Chick. *dl.*, dorso-lumbar; *s.*, sacral; *c.*, caudal vertebræ.

able difficulty. The general arrangement is as follows:—The most anterior lumbar vertebra has a broad transverse process, which corresponds in form and position with the tubercular transverse process of the last dorsal. In the succeeding lumbar vertebræ this process extends downwards; and, in the hindermost, it is continued from the centrum, as well as from the arch of the vertebra, and forms a broad mass which abuts against the ilium.* This process might well be taken for a sacral rib, and its vertebra for the proper sacral vertebra. But, in the first place, I find no distinct ossification in it; and, secondly, the nerves which issue from the intervertebral foramina in front of and behind this vertebra enter into the lumbar plexus, which gives origin to the crural and obturator nerves, and not into the sacral plexus, which is the product of the nerves which issue from the intervertebral foramina of the proper sacral vertebræ in other *Vertebrata*. Behind the last lumbar vertebra follow, at most, five vertebræ, which have no ribs, but their arches give off horizontal, lamellar, transverse processes, which unite with the ilia. The nerves which issue from the intervertebral foramina of these vertebræ

* It would be more proper to say that ossification extends into it from the centrum as well as from the neural arch. The pro-

cess, like other processes, exists before the centrum is differentiated from the arch by ossification.

unite to form the sacral plexus, whence the great sciatic nerve is given off; and I take them to be the homologues of the sacral vertebræ of *Reptilia*. The deep fossæ between the centra of these vertebræ, their transverse processes, and the ilia, are occupied by the middle lobes of the kidneys.

If these be the true sacral vertebræ, it follows that their successors are anterior caudal. They have expanded upper transverse processes, like the proper sacral vertebræ; but, in addition, three or four of the most anterior of these vertebræ possess ribs which, like the proper sacral ribs of reptiles, are suturally united, or ankylosed, proximally, with both the neural arches and the centra of their vertebræ, while, distally, they expand and abut against the ilium. The ankylosed caudal vertebræ may be distinguished as *uro-sacral*. The caudal vertebræ which succeed these may be numerous and all distinct from one another, as in *Archæopteryx* and *Rhea*; but, more generally, only the anterior caudal vertebræ are distinct and moveable, the rest being ankylosed into a ploughshare-shaped bone, or *pygostyle*, which supports the tail feathers and the uropygial gland, and sometimes, as in the Woodpeckers and many other birds, expands below into a broad polygonal disc.

The centra of the moveable presacral vertebræ of Birds are connected together by fibro-cartilaginous rings, which extend from the circumference of one to that of the next. Each ring is continued inwards into a disc with free anterior and posterior faces—the *meniscus*. The meniscus thins towards its centre, which is always perforated. The synovial space between any two centra is, therefore, divided by the meniscus, into two very narrow chambers, which communicate by the aperture of the meniscus. Sometimes the meniscus is reduced to a rudiment; while, in other cases, it may be united, more or less extensively, with the faces of the centra of the vertebræ. In the caudal region, the union is complete and the meniscus altogether resembles an ordinary intervertebral cartilage.

A ligament traverses the centre of the aperture in the meniscus; and, in the chick, contains the intervertebral por-

tion of the notochord. As Jäger* has shewn, it is the homologue of the odontoid ligament in the cranio-spinal articulation; and of the pulpy central part of the intervertebral fibro-cartilages in *Mammalia*.

All the vertebral ribs in the dorsal region, except, perhaps, the very last free ribs, have widely separated capitula and tubercula. More or fewer have well ossified uncinatæ processes attached to their posterior margins, as in the *Crocodylia*. The vertebral ribs are completely ossified up to their junction with the sternal ribs. The sternum in birds, is a broad plate of cartilage, which is always more or less completely replaced in the adult by membrane bone.† It begins to ossify by, at fewest, two centres, one on each side, as in the *Ratitæ*. In the *Carinatae* it usually begins to ossify by five centres, of which one is median for the keel, and two are in pairs, for the lateral parts of the sternum. Thus the sternum of a chicken is at one time separable into five distinct bones, of which the central keel-bearing ossification (*r. to m. x.* in Fig. 81) is termed the *lophosteon*, the antero-lateral piece which articulates with the ribs, *pleurosteon* (*pl. o.*), and the posterolateral bifurcated piece, *metosteon*.

Though the sternum, in most birds, seems to differ very much in form from that of the *Reptilia*, it is rhomboidal in the *Casuaridæ*, where it differs from the reptilian sternum chiefly in the greater proportional length of its posterior sides, the absence of median backward prolongations, and the convexity of its ventral surface. But in other birds, and notably in many *Carinatae*, the antero-lateral edges, which are grooved to receive the coracoids, form a much more open angle than in the *Reptilia*, while the postero-lateral edges become parallel, or diverge; and a wide, straight or convex, transverse edge takes the place of the posterior angle. Two, or four, membranous fontanelles may remain

* "Das Wirbelkörpergelenk der Vögel." Sitzungsberichte der Wiener Akademie, 1858.

† These statements respecting the vertebral column, ribs, and

sternum, like those further on touching the skull, do not apply to *Archæpteryx*, in which all these parts are unknown or imperfectly known.

in the posterior moiety of the sternum when ossification takes place, and give rise to as many holes, or deep notches, separating slender processes in the dry skeleton. All these correspond with so many divisions of the xiphoid process of the sternum in *Mammalia*, and hence are called *middle*,

Fig. 81.

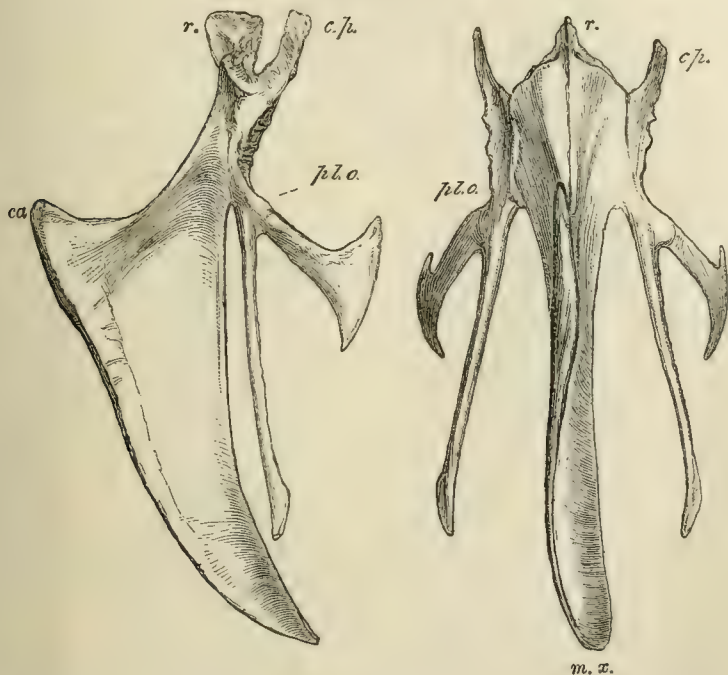


Fig. 81.—Front and side views of the sternum of a Fowl. *r.*, rostrum, or manubrium; *c. p.*, costal process; *pl. o.*, pleurosteon (the line from the letter goes to the point of junction between the pleurosteon and the metosteon); *m. x.*, the middle xiphoid process; *ca.*, the carina or keel.

internal, and *external xiphoid processes*. Sometimes, a median process, *rostrum* or *manubrium* (*r.*, Fig. 81), is developed from the anterior angle of the sternum, and its antero-lateral angles are frequently produced into *costal processes* (*c. p.*, Fig. 81), which may bear the articular surfaces for more or

fewer of the ribs. The two last-named structures are very distinct in the *Coracomorphæ*, or Passerine Birds.

The extent to which the keel of the lophosteon is developed in the carinate birds varies very much. In *Strigops* it is rudimentary; in birds of powerful flight, as well as in those which use their wings for swimming, it is exceedingly large.

In the bird's skull (Fig. 82), the brain-case is more arched and spacious, and is larger, in proportion to the face, than in any *Reptilia*, with the exception of the *Pterosauria*. There is a well-marked interorbital septum, but the extent to which it is ossified varies greatly. As a general rule, the superior temporal bar is incomplete, and there is no distinct post-frontal bone. The inferior temporal bar, formed by the jugal and quadrato-jugal, on the other hand, is always complete. There are no long parotic processes, nor any post-temporal fossæ, the whole of each parietal bone being, as it were, absorbed in the roof of the skull.

The nasal apertures are almost always situated far back near the base of the beak. In the dry skull (above *Mx.* in Fig. 82), there is a lachrymo-nasal fossa, or interval unoccupied by bone, between the nasal, lachrymal, and maxillary bones, such as exists in some *Teleosauria*, *Dinosauria*, and *Pterosauria*.

The posterior nares lie between the palatines and the vomer; and the nasal passage is never separated from the cavity of the mouth by the union of palatine plates of the palatine or pterygoid bones.

The Eustachian tubes generally traverse the basisphenoid, and have a common aperture upon the middle of the under surface of the skull.

The bones of the brain-case, and most of those of the face, very early become ankylosed together into an indistinguishable whole in most birds, but the sutures remain distinguishable longer in the *Chenomorphæ* and *Spheniscomorphæ*; and especially in the *Ratitæ*.

All the constituents of the occipital and parietal segments of the skull are represented by distinct bones, but

the frontal segment varies a good deal in this respect. The basisphenoid has a long rostrum, which represents part of the parasphenoid of the *Ichthyopsida*. Large frontal

Fig. 82.

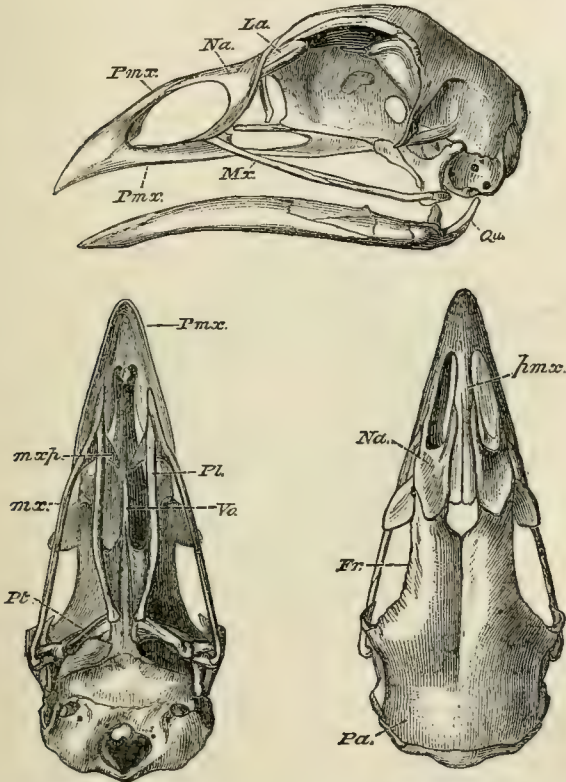


Fig. 82.—Lateral, upper, and under views of the skull of a common Fowl (*Phasianus gallus*). *m.x.p.*, the maxillo-palatine process. *Qu.*, the quadrate bone. The dotted line accidentally stops at the angular process of the mandible.

bones always exist, but the pre-sphenoidal and orbito-sphenoidal regions are not so regularly ossified.

The ethmoid is ossified, and frequently appears upon the surface of the skull, between the nasal and the frontal

bones; and the internasal septum, in front of the ethmoid, may present very various degrees of ossification. Very frequently, the interspace between the ethmoidal and the internasal ossifications is simply membranous in the adult, and the beak is held to the skull only by the ascending processes of the premaxillary bones, and by the nasal bones, which are thin and flexible. By this means a sort of elastic joint is established, conferring upon the beak a certain range of vertical motion. In the Parrots, and some other birds, this joint is converted into a true articulation.

Fig. 83.

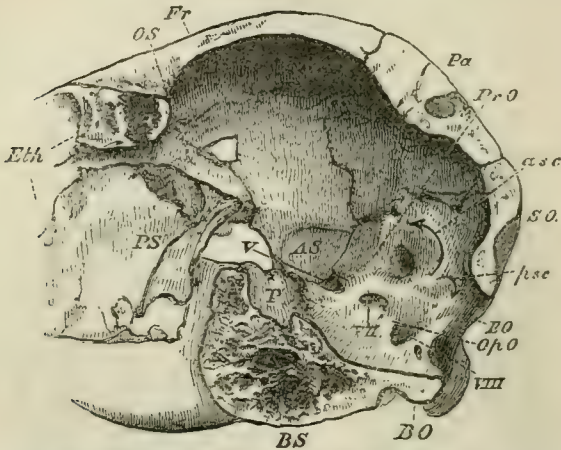


Fig. 83.—A longitudinal and vertical section of the posterior half of the skull of an Ostrich. *P.*, the pituitary fossa; *asc.*, *psc.*, anterior and posterior vertical semicircular canals of the ear.

and the range of motion of the upper beak becomes very extensive.

The periotic capsule is completely ossified, and, as in other *Sauropsida*, the epiotic and the opisthotic are ankylosed with the occipital segment before they unite with the pro-otic. In the primordial skull of the bird the olfactory organs are surrounded by cartilaginous capsules, the lateral walls of which send in *turbinal* processes of very various degrees of complexity. When the posterior wall of this

capsule is ossified, the bone thus formed represents the prefrontal, or lateral mass of the ethmoid, of the mammal. It is largely developed in the *Apteryx*, in the *Casuaridæ*, and many other birds, but is absent in the *Struthionidæ*; and, in other birds, is often represented by a mere bar of bone standing out from the ethmoidal ossification.

The lachrymal is, usually, a distinct and large bone articulated with the nasal and frontal above, with the prefrontal internally, and with the maxilla, below; but sometimes it becomes undistinguishably fused with the prefrontal. Sometimes, on the contrary, as in the Parrots, it acquires a large size, and sends a process backwards beneath the orbit, which may join with a post-orbital process of the frontal, and so circumscribe the orbital cavity. *Opisthocomus* exhibits the peculiarity of the complete ankylosis of the nasal with the lachrymal, which is quite free from the frontal and moves with the hinged beak. A supra-orbital bone, or chain of bones, may be developed in connection with the orbital margin of the frontal bone; and, occasionally, infra-orbital bones, appear below the orbit, parallel with the jugal arch. A post-orbital process may be developed from the frontal, or from the alisphenoid; and, in the latter case, may be separately ossified.

The squamosal is closely applied to the skull, and is, usually, ankylosed with the other bones. It often sends a process downwards over the quadrate bone, and it may be united by bone with the post-orbital process of the frontal, as in the Fowl.

The frame of the tympanic membrane not unfrequently contains distinct ossifications, which represent the tympanic bone of the *Mammalia*.

The premaxillæ are modified in a manner which finds a partial parallel only among the *Reptilia*. They are tri-radiate bones of great size, which, usually, give off three processes; an ascending process to the frontal; a palatine process, along the middle of the palate, to the palatine bones; and an external, or maxillary process, which forms the greater part of the margin of the beak,

and unites with the maxilla. The two bones are very early represented by one continuous ossification.

The vomers vary more than almost any other bones of the skull. They underlie and embrace the inferior edge of the ethmo-presphenoidal region of the basis cranii, and, in all birds in which they are distinctly developed, except the Ostrich, they are connected behind with the palatine bones. In most birds, they early unite into a single bone; but they remain long distinct in some *Coracomorphæ*, and seem to be always separate in the Woodpeckers. The coalesced vomers constitute a very large and broad bone in most *Ratitæ*, and in the *Tinamomorphæ*; a narrow elongated bone pointed in front in *Schizognathæ*; a broad bone deeply cleft behind, and abruptly truncated in front, in *Coracomorphæ*. In most *Desmognathæ* the vomer is small; and, sometimes, it appears to be obsolete.

The maxillæ of birds are usually slender, rod-like bones, articulating by squamous suture, in front, with the premaxillæ, and, behind, with the equally slender jugals. In the great majority of birds the maxilla sends inwards a *maxillo-palatine* process (Fig. 82, *mxp.*), which, sometimes, is mere thin lamella of bone, sometimes, becomes swollen and spongy. In the *Ratitæ* and the *Desmognathæ* (Fig. 84), the maxillo-palatine processes unite with the vomer, or with one another, and form a complete bony roof across the palate. In the *Schizognathæ* (Fig. 82), and *Ægithognathæ*, the maxillo-palatines remain quite distinct both from one another and from the vomer.

The quadrato-jugal is usually a slender rod of bone, the hinder extremity of which presents, on its inner side, an articular head which fits into a fossa in the outer face of the distal end of the quadrate bone.

The palatine bones are generally long and concave on their palatine faces. In front, they pass beneath (*i.e.*, on the ventral side of) the maxillo-palatines and unite with the premaxillæ, sometimes by a squamous suture, sometimes by ankylosis, rarely, as in the Parrots, by a flexible joint. Posteriorly, they always unite with the ptery-

goids. In most birds, the palatines converge, posteriorly, towards the basi-sphenoidal rostrum, and unite with it by an articular surface, which allows of a sliding motion of the palatines upon the rostrum. Such an articulation does not exist in *Ratitæ*, or in the Tinamous, among the *Carinatae*. In these, (with the exception of *Struthio*), the palatines are, as it were, borne off from the rostrum by the divergent ends of the great vomer, and the disposition of the parts

Fig. 84.

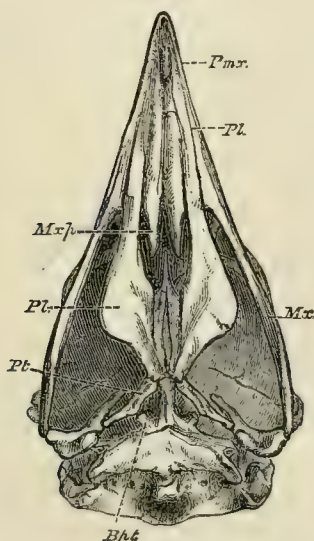


Fig. 84.—The under surface of the cranium of the Secretary bird (*Gypogogeranus*), as an example of the Desmognathous arrangement. *Mxp.*, maxillo-palatine process; *Bpt.*, basi-ptyergoid processes.

is more lacertillian than in other birds. The outer, or posterior, end of the pterygoid bone presents a fossa for an articular head, which is developed upon the inner side of the distal end of the quadrate. The inner, or anterior, ends of the pterygoids meet in almost all birds, and may become articulated with the basi-sphenoidal rostrum. In all embryonic birds, in all the *Ratitæ*, and in many *Carinatae*, such as the *Tinamomorphæ*, *Charadriomorphæ*, *Alectoromorphæ*,

Peristeromorphæ, *Chenomorphæ*, longer or shorter processes extend from the basi-sphenoid, and present terminal articular facets to corresponding facets upon the inner sides of the pterygoids. These are *basi-pterygoid* processes, similar to those which occur in *Lacertilia* and some *Ophidia*.

The quadrate bone is almost always moveable upon the skull, articulating with the pro-otic, alisphenoid, and squamosal, by a single, or double, head. The distal head articulates with the mandible below, the quadrato-jugal on the outer, and the pterygoid on the inner, side. Hence, when the ethmo-nasal joint is developed, any forward movement of the distal end of the quadrate, such as must take place when the mandible is depressed by the digastric muscle, causes the maxillo-jugal bar to thrust the pre-maxilla upwards and forwards; the palatine and pterygoid bones, at the same time, sliding forward upon the rostrum of the basisphenoid. Thus it comes about that the upper jaw of such a bird as a Parrot rises, when, in opening the mouth, the mandible is depressed. Each ramus of the mandible consists primitively of six pieces, as in other *Sauropsida*, but the dentary pieces of each side are, as in the *Chelonia*, very early united, if indeed they are not ossified from one centre. Very often, a fontanelle remains between the dentary and the other elements, as in *Crocodylia*; and the dentary long remains readily separable from the rest; or, as in the Goatsuckers, is united with the others only by fibrous tissue, so that it is moveable. The angle of the mandible may be truncated or produced backwards into a long curved process, as in Fowls (Fig. 82), Ducks, and Geese.

The hyoid is composed of basal elements, the anterior of which, usually composed of two portions, lies in the tongue; and of two short, anterior, and two long, posterior, cornua, which are never united with the periotic region of the skull, and commonly remain quite free. In some of the Woodpeckers, however, the long posterior cornua are immensely elongated, and curve upwards and backwards over

the skull (the frontal bones being grooved to receive them), and their free ends are inserted between the ascending and maxillary processes of the right premaxilla.

Fig. 84.*

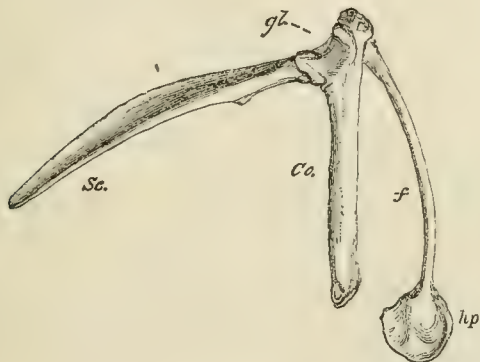


Fig. 84.—The right scapula (*Sc.*), and coracoid (*Co.*) of a Fowl; *gl*, the glenoidal cavity; *f*, the right clavicle, or right half of the furculum; *hp*, the hypocleidium.

The pectoral arch presents a long, narrow, and recurved scapula (*Sc.* Fig. 84*), without any supracapula; and a coracoid (*Co.*), fitted by its proximal end into the groove in the anterolateral edge of the sternum. The inner ends of the coracoids occasionally overlap, as in *Lacertilia*; otherwise, the shoulder girdle is unlike that of any of the *Reptilia*, except the *Pterosauria*. The coracoid is usually completely ossified, and presents no fontanelle. There is no distinct epicoracoid. The two bones take nearly equal shares in the formation of the glenoidal cavity, and usually remain unankylosed and distinct in this region.

In the *Ratitæ* the long axis of that part of the scapula which lies near the glenoid cavity is parallel or coincident with that of the coracoid, and the two bones become completely ankylosed. But, in all the *Carinatae*, the long axis of the scapula forms an acute, or only slightly obtuse angle (*Ocydromus*, *Didus*) with that of the coracoid. A small bone, the *scapula accessoria*, is developed on the outer

side of the shoulder-joint in most *Coracomorphæ* and *Celeomorphæ*.

In the *Carinatae*, the glenoidal end of the scapula is divided into two portions; a *glenoidal* process, which expands to form the upper part of the glenoidal cavity, and to unite with the coracoid—and an *acromial* process, which gives attachment to the outer end of the clavicle. The glenoidal end of the coracoid is in like manner divided into two portions; a *glenoidal* process, which unites with the scapula, and a *clavicular* process, which articulates with the outer surface of the clavicle, near its outer end.

The clavicular process of the coracoid probably represents the procoracoid of *Lacertilia*. In the *Ratitæ* there is no distinct clavicular process, but the anterior part of the coracoid, near the glenoid cavity, may be produced and separated by a notch, or fontanelle, from the rest, as a lacertilian procoracoid. There is no trace of clavicles in the *Apteryx* and in some Parrots. In the *Emeu*, and in sundry *Carinatae* (some Parrots and Owls), the clavicles remain distinct from one another, or connected only by fibrous tissue; but, in the majority of birds, they are very early ankylosed together, and with the representative of the interclavicle, in the middle line, into a single bone, the *furculum*, the strength of which bears a pretty close relation to the exertion required of the wings in flight, or in natation. In the passerine birds the scapular end of the clavicle is usually expanded, and ossifies separately, as an *epicleidium*. A median process (*hypocleidium*) is frequently developed from the interclavicular part of the furculum, and this may be united with the carina of the sternum by strong fibrous tissue, or even by continuous ossification. In *Opisthocomus*, the furculum is ankylosed with the manubrial part of the sternum, on the one hand, and with the coracoids on the other. Ankylosis of the furculum with the coracoids has also been observed in *Didus*.

The fore limb of a bird, when in a state of rest, exhibits a great change of position if it be compared with that of an ordinary reptile; and this change is of a character similar to,

but in some respects greater than, that which the arm of a man presents, when compared with the fore-limb of a quadrupedal mammal. The humerus lies parallel with the axis of the body, its proper ventral surface looking outwards. The fore arm is in a position midway between pronation and supination, and the manus is bent back upon the ulnar side of the fore arm, in a position, not of flexion, but of abduction.

In ordinary birds, the proximal end of the humerus is expanded, and its articular head transversely elongated; its ventral face is convex, and provided with a strong preaxial ridge, which gives attachment to the pectoral muscle. The proper dorsal face is concave from side to side, especially towards the postaxial margin, where the pneumatic aperture occurs in those birds which have the humerus hollow. The distal end is expanded, and the articular surface for the radius is a convex facet, directed obliquely inwards, on its ventral face. In this respect the bird's humerus exaggerates a feature of that of the Lizards.

In the *Ratitæ* these peculiarities are very feebly, or not at all, marked, the humerus being a slender, cylindrical, slightly curved, bone. In the *Casuaridæ*, *Dinornithidæ*, and *Apterygidæ*, the fore-limb is extraordinarily reduced, and may become rudimentary. In the Penguins and, to a less degree, in the great Auk, the humerus becomes flattened from side to side; the proximal end is singularly modified, and, at the narrow distal end, the articular surface for the radius lies completely in front of, and rather above, that for the ulna.

The ulna, which often presents a series of tubercles, indicating the attachment of the secondary quill feathers, is usually a stronger, and a longer, bone than the radius. There are only two carpal bones, one radial and one ulnar.

In the *Apterygidæ* and in the *Casuaridæ*, there is but one complete digit in the manus. It appears to answer to the second of the pentadactyle limb, and is provided with a claw. In the *Struthionidæ* and *Rheidæ*, and in all *Carinataæ*, there are

three digits in the manus, which answer to the pollex and the second and third digits of the pentadactyle fore limb; and the metacarpal bones of these digits are ankylosed together.

Fig. 85.

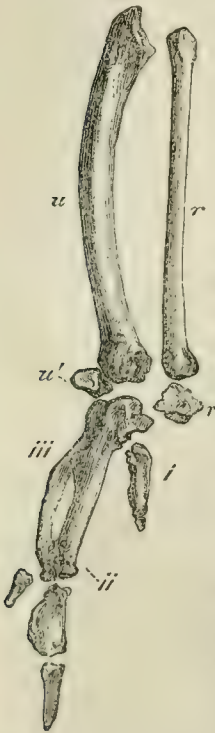

Fig. 85.—The radius (*r*); ulna (*u*); radial and ulnar carpal bones (*r'*, *u'*); with the three digits (*i*, *ii*, *iii*), of the right forelimb of a Fowl. The terminal phalanges of both the first and the second digits were incomplete in the specimen figured.

As a rule, the metacarpal of the pollex is much shorter than the other two; that of the second digit is strong and straight, that of the third is more slender and bowed, so as to leave an interspace between itself and the second, which is often filled up by bony matter. The pollex has two phalanges, and the second of them is, in many birds, pointed, curved, and ensheathed in a horny claw. The second digit has three phalanges, and the terminal phalanx is similarly provided with a claw in sundry birds. In the ostrich, both the pollex and the second digit are unguiculate. The third digit never possesses more than one or two phalanges, and is always devoid of a claw.

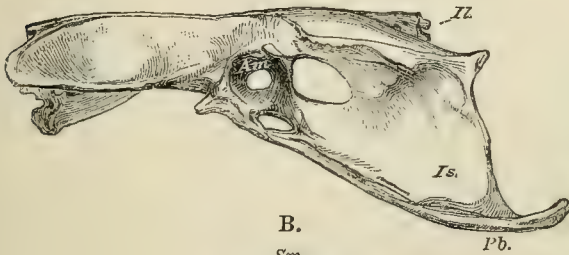
It is a singular circumstance that the relative proportions of the humerus and the manus should present the most marked contrast in two groups of birds, which are alike remarkable for their powers of flight. These are the Swifts and Humming-birds, in which the humerus is short and the manus long; and the Albatrosses, in which the humerus is long and the manus relatively short.

In the Penguins, the pollex has no free phalanges, and its metacarpal bone seems to be ankylosed with that of the second digit. The third metacarpal is slender and straight. The bones of the manus are singularly elongated and flattened.

The pelvis of a bird (Fig. 86), is remarkable for the great elongation, both anteriorly and posteriorly, of the iliac bones (*Il.*), which unite with the whole length of the edges of the sacrum (*sm.*) and even extend forwards, over the pos-

Fig. 86.

A.



B.

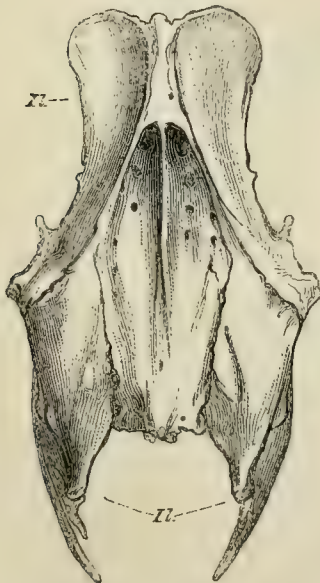
*Sm.**Pb.*

Fig. 86.—A, lateral; and B, dorsal, view of the pelvis of a Fowl.
Sm., sacrum; *Il.*, ilium; *Is.*, ischium; *Pb.*, pubis; *Am.*, acetabulum.

terior ribs of the dorsal region. Below, each iliac bone forms a wide arch over the upper part of the acetabulum (*Am.*),

the centre of which is always closed by fibrous tissue, so that, in the dry skeleton, the bottom of the acetabulum is perforated by a wide foramen. An articular surface on the ilium, on which the great trochanter of the femur plays, is called the *antitrochanter*. In all ordinary birds, the ischium (Fig. 86, *Is.*), which broadens towards its hinder end, extends back, nearly parallel with the hinder part of the ilium, and is united with it by ossification, posteriorly. The iliosciatic interval is thus converted into a foramen. The pubis (*Pb.*) enters, by its dorsal or acetabular end, into the formation of the acetabulum, and then passes backwards and downwards as a comparatively slender, curved, bone, nearly parallel with the ischium. It is united with its fellow only by fibrous tissue. Neither the ischia, nor the pubes, unite directly with the sacrum. Very few birds present any important deviation from this structure of the pelvis. In *Tinamus*, *Casuaris*, *Dromæus*, *Apteryx*, *Dinornis*, the ischium is not united with the backward extension of the ilium by bone. In *Rhea*, the ischia unite with one another beneath the vertebral column, and the vertebræ in this region are very slender and imperfectly ossified. In *Struthio*, alone, among birds, do the pubes unite in a median ventral symphysis. Another, not less remarkable circumstance, in the ostrich, is, that the 31st to the 35th vertebræ inclusively (counting from the atlas) develop five lateral tuberosities. The three middle tuberosities are large, and abut against the pubis and the ischium. In these vertebræ, as in the dorsal vertebræ of *Chelonia*, the neural arch of each vertebra shifts forward, so that half its base articulates with the centrum of the next vertebra in front; and the tuberosities in question are outgrowths, partly of the neural arch, partly of the juxtaposed vertebral centra, between which it is wedged. Hence, in young ostriches, the face of each tuberosity exhibits a triradiate suture.

The upper articular head of the femur is rounded, and its axis is almost at right angles with the body of the bone; a structure which is not found in ordinary *Reptilia*, but exists in the *Iguanodon* and other *Ornithoscelida*. The shaft is re-

lately short and thick, and the two terminal condyles are large and elongated antero-posteriorly. A prominent ridge, which plays between the proximal ends of the tibia and the fibula is apparent upon the posterior and inferior surface of the outer condyle. A similar ridge is faintly developed in some *Lacertilia*, and is well marked in the Dinosaurian reptiles. A patella is usually present, but it is sometimes absent, and may be double.

The fibula of birds is always imperfect, ending in a mere style below. Generally it is decidedly shorter than the tibia, but it has the same length as that bone in some Penguins. The tibia, or rather *tibio-tarsus*, is a highly characteristic bone. Its proximal end is expanded and produced anteriorly, into a great *cnemial* process (which may be variously subdivided) as in *Dinosauria*. The distal end is terminated by a well-marked pulley-like articular surface which is inclined somewhat forwards as well as downwards. Not unfrequently there is an oblique bar of bone on the anterior face, just above the pulley, beneath which the long extensor tendons pass.

The extremity of the cnemial process in *Struthio* and *Rhea* is ossified as an *epiphysis*; and, in young birds, the whole of the distal articular end of the bone is separated from the rest by a suture, and also appears to be an *epiphysis*. But it is, in fact, as Professor Gegenbaur has proved, the proximal division of the tarsus (apparently representing only the astragalus of the other *Vertebrata*),

Fig. 87.

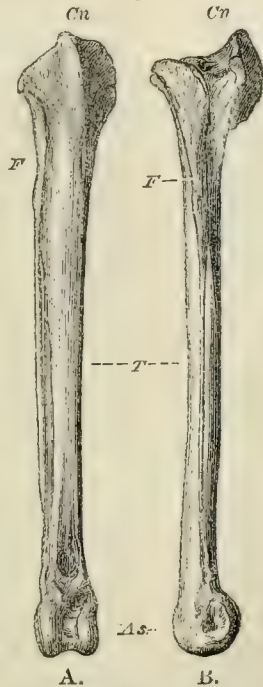


Fig. 87.—The right tibia and fibula of a Fowl. A, front view; B, external lateral view. T., tibia; F., fibula; Cn., cnemial process; As., astragalus.

which exists in the embryo as a separate cartilage, and, as it ossifies, ankyloses with the tibia. The so-called tibia of a bird is therefore, properly speaking, a *tibio-tarsus* (see p. 263, Fig. 77, A, and Fig. 88).

In all birds, even in *Archæopteryx*, the fifth digit of the pes remains undeveloped; and the second, third, and fourth

Fig. 88.

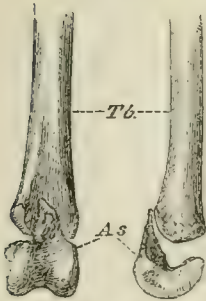


Fig. 88.—The distal end of the left tibia (*Tb.*) with the astragalus (*As.*) detached, of a young Fowl. Viewed from in front, and from the outer side.

metatarsals are ankylosed together, and, by their proximal ends, with a bone, which is a distinct cartilage in the foetus, and represents the distal division of the tarsus. Thus a *tarso-metatarsus* is formed. The distal ends of the metatarsals remain separate, and offer convex articular surfaces to the proximal phalanges of the digits.

In the Penguins, large apertures lie between the several metatarsals of the adult *tarso-metatarsus*; and, in other birds, more or less considerable passages persist between the middle and the lateral metatarsals proximally, and the middle and the outer, distally. In most birds, the middle metatarsal does not remain parallel with the others, but

its proximal end inclines a little backwards, and its distal end a little forwards. Hence the two apertures on each side of its proximal end may lie at the bottom of a fossa, or run into one, in front, while they remain distinct behind.

Again, in most birds, the posterior face of the proximal end of the middle metatarsal, and the adjacent surface of the tarsal bone, grow out into a process, which is commonly, but improperly, termed “calcaneal.” The inferior surface of this *hypo-tarsus* is sometimes simply flattened, sometimes traversed by grooves or canals, for the flexor tendons of the digits.

When a hallux exists, its metatarsal bone is usually incomplete above, and is united by ligament to the inner, or the posterior, surface of the tarso-metatarsus. In the

Frigate-bird (*Phaethon*) and in *Steatornis*, the hallucal metatarsal is remarkably long. The genus *Phaethon* stands alone, so far as I know, in having the hallucal metatarsal ankylosed with the others.

In many of the *Alectoromorphæ*, a spur (*calcar*), consisting of a bony core ensheathed in horn, is developed on the inner side of the metatarsus, and becomes ankylosed with the metatarsal of the second digit. In a few birds, similar spurs (*Palamedea*), or osseous excrescences (*Pezophaps*), are developed in relation with the metacarpus.

The normal number of the pedal phalanges in birds is (as in ordinary *Lacertilia*) 2, 3, 4, 5, reckoning from the hallux to the fourth digit. Among the few birds which constitute exceptions to the rule are the Swifts, in which the third and fourth toe have only three phalanges each (2, 3, 3, 3), and the Goatsuckers and the Sandgrouse, in which the fourth toe only has the number thus reduced (2, 3, 4, 3).

Many birds have only three toes, by suppression of the hallux. In the Ostrich, not only the hallux, but the phalanges of the second digit, are suppressed; and the distal end of the second metatarsal is reduced to a mere rudiment. Hence the ostrich has only two toes (which answer to the third and fourth of the pentadactyle foot), with four phalanges in the inner and five in the outer, though the inner toe is far the longer and the stronger.

In most four-toed birds the hallux is turned more or less completely backwards, and the other three digits forwards. But in many *Aetomorphæ* (especially the Owls), the outer toe can be turned outwards, or even backwards, at will. And in

Fig. 89.

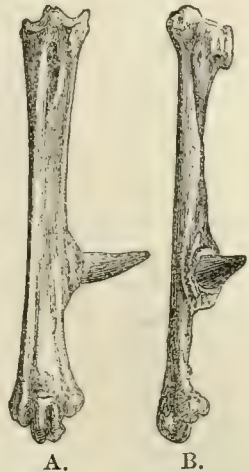

Fig. 89. — The right tarso-metatarsus of a Fowl, consisting of three digits, ii., iii., iv., ankylosed with one another, and with the osseous core of the spur. A., front aspect; B., inner aspect.

the Parrots, Toucans, Cuckoos, Woodpeckers, and other so-called "scansorial" birds, the outer toe is permanently reversed. Under these circumstances the distal end of the outer metatarsal may be divided into two distinct articular surfaces. In the Trogons, there are two toes in front and two behind, as in the Parrots, but it is the second toe which is turned backwards. Lastly, in the Swifts, the *Dysporomorphæ* and the *Spheniscomorphæ*, the hallux is directed more or less forwards, so that all four toes are turned to the front.

As a general rule, the osseous tissue of birds is remarkably dense and hard. Before hatching, the bones are solid and filled with vascular medulla; but, after birth, more or fewer of the bones are always excavated by prolongations of cavities containing air, which lie in their neighbourhood. Such air cavities are always found in the skull, in connection with the nasal and auditory passages, and they may extend through all parts of the skull, with the exception of the jugal arch. In many birds, such as the *Apteryx*, Penguins, Divers, Gulls, and the smaller song-birds, no other bones than those of the skull are pneumatic; but, in most birds, the air sacs of the lungs send off prolongations into the bones of the rest of the skeleton, and thus the whole skeleton in some cases (as in the Hornbills) becomes pneumatic. It is proper to remark, that the amount of pneumaticity of the bones by no means follows the development of the power of flight. In the Ostrich, for example, the bones are far more extensively pneumatic than in the Gull.

In some cases, prolongations of the air sacs extend beneath the integument.

CHAPTER VII.

THE MUSCLES AND THE VISCERA OF THE SAUROPSIDA.

THE most important deviations from the ordinary arrangement of the muscular system occur, as might be expected, in the *Ophidia*, in the *Chelonia*, and in *Aves*. In the first-mentioned group, the numerous muscles of the limbs are, of course, absent, and the mobility of the vertebræ, ribs and jaws, is accompanied by a corresponding differentiation of the muscles of those parts. The episkeletal muscles form a continuous series (divisible into *spinalis*, *semispinalis*, *longissimus dorsi*, *levatores costarum*, and other muscles) from the end of the tail to the head; and, in the region of the back, constitute a thick mass which extends outwards to the ends of the caudal ribs (the so-called transverse processes), and over the dorsal thirds of the other ribs. Beyond these points it is continued, as a thinner layer of muscular fibres, over the ventral half of the tail and trunk, passing from rib to rib in the latter region, where the more dorsal fibres are directed obliquely, only a longitudinal band running along the extremities of the ribs and representing *arctus abdominis*. This muscle is continued forwards to the hyoidean apparatus, and thence to the mandible. Superficial muscular bundles pass from the ribs to the scales. The hyoskeletal muscles are better developed than in most other *Vertebrata*, and also extend from the head to the end of the tail. A median dorsal set are connected with the subvertebral processes in the trunk, and with the bases of the representatives of the chevron bones in the tail, and pass to the caudal and dorsal ribs. One set of these, in the trunk, act as retractors of the ribs. The muscles which

correspond with the *transversus abdominis*, commence in the tail by transversely directed bundles of fibres, which arise from the roots of the caudal ribs (transverse processes) and meet in a median aponeurosis. In the trunk, similar bundles arise from the under surfaces of the ribs, and form two layers of oblique fibres, which also meet in the middle line.

In the *Chelonia*, the episkeletal muscles are always weakly developed, and may be altogether abortive in the dorsal region, while those of the abdominal walls are small. The *recti* are very weak, but muscles answering to the *pyramidales* extend from the pubes to the inner surface of the plastron. A muscular expansion analogous to a diaphragm may be attached to the bodies and ribs of the third and fourth dorsal vertebræ, whence it expands over the surface of the lungs. No muscles pass from the head to the shoulder girdle. The pectoral arch is protracted, and the neck retracted, by a muscle attached to the cervical vertebræ and to the procoracoid. There is also a single retractor of the pectoral arch, apparently representing a *serratus magnus*, and passing from the first costal plate to the scapula. The *pectoralis major* arises from the inner surface of the plastron. The representative of the *latis-simus dorsi* arises from the inner side of the first costal plate.

The cutaneous muscles of birds are well developed, and form broad expansions in various parts of the body. Special bundles of muscular fibres pass to the great quill feathers of the tail and wings, and others to the *patagium*, a fold of integument which extends between the trunk and the brachium behind, and between the brachium and ante-brachium in front. In correspondence with the slight mobility of the dorsal vertebræ, the episkeletal and hyposkeletal muscles of the spine attain a considerable development only in the neck and in the tail. Owing to the great size of the sternum, the abdominal muscles are usually small, and the internal oblique may be absent. A diaphragm, consisting of bundles of muscular fibres, which pass from the ribs to

the aponeurosis covering the ventral face of the lungs, is developed in all birds, but attains the greatest degree of completeness in the *Ratitæ*, and especially in *Apteryx*.

The muscles of the limbs are remarkably modified by the excessive development of some of those found in other *Vertebrata*, and the suppression of others.

Thus in all birds possessing the power of flight, the *pectoralis major*, as the chief agent of the downward stroke of the wing, is very large and thick, taking its origin from the whole length, and a great part of the depth, of the keel of the sternum.

The elevation of the wing is chiefly effected by the *pectoralis tertius*, which arises beneath the foregoing muscle, and passes over the inner side of the scapulocoracoid articulation, as over a pulley, to reach the humerus. The muscles of the forearm and digits are reduced, in accordance with the peculiar modification of the skeleton of these parts. In the hind limb of most birds there is a singular extensor muscle, which arises from the pubis, ends in a tendon which passes to the outer side of the knee-joint, and terminates in the leg by uniting with the *flexor digitorum perforatus*. The result of this arrangement is, that the toes are flexed whenever the leg is bent upon the thigh, and, consequently, the roosting bird is held fast upon his perch by the weight of his own body.

In all the *Sauropsida* the cerebro-spinal axis is angulated at the junction of the spinal cord with the medulla oblongata, the latter being bent down towards the ventral side of the body. The region in which the nerves of the anterior and posterior extremities originate may be enlarged in reptiles, as in birds; but, in the former, the posterior columns of the cord remain parallel in the lumbar enlargement, while, in the latter, they diverge and give rise to the *sinus rhomboidalis*, which is a sort of repetition of the fourth ventricle, the dilated central canal of the spinal cord being covered merely by a thin membrane consisting chiefly of the ependyma and arachnoid.

Fig. 90.

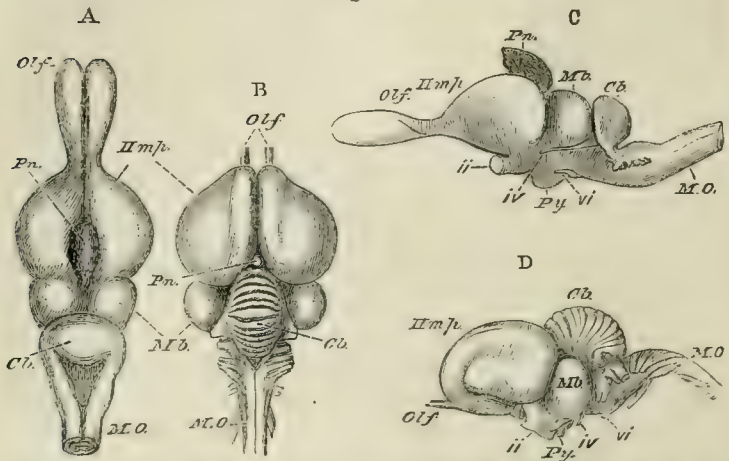


Fig. 90.—A, C, the brain of a Lizard (*Psammosaurus bengalensis*), and B, D, of a bird (*Meleagris gallopavo*, the Turkey), drawn as if they were of equal lengths. A, B, viewed from above; C, D, from the left side. *Olf.*, Olfactory lobes; *Pn.*, Pineal gland; *Hmp.*, cerebral hemispheres; *Mb.*, optic lobes of the mid-brain; *Cb.*, cerebellum; *M. O.*, medulla oblongata; *ii.*, *iv.*, *vi.*, second, fourth, and sixth pairs of cerebral nerves; *Py.*, pituitary body.

The brain (Fig. 90) fills the cavity of the skull in the higher *Sauropsida*, and presents a well-developed cerebellum; a mesencephalon divided above into two optic lobes; and relatively large prosencephalic hemispheres, which attain a considerable size in *Crocodylia* and *Aves*, but never conceal the optic lobes. In *Crocodylia* the cerebellum presents a distinct vermis, with transverse fissures. In birds the latter are more distinct, and the lateral appendages of the cerebellum, or *flocculi*, become well defined, and are lodged, as in many of the lower *Mammalia*, in cavities of the side walls of the skull, arched over by the anterior vertical semicircular canal.

There is no *pons Varolii*, in the sense of transverse fibres connecting the two halves of the cerebellum, visible upon the ventral surface of the mesencephalon. The optic lobes contain ventricles. In *Reptilia*, the optic lobes usually lie close together upon the dorsal side of the mesencephalon,

but in *Aves* (Fig. 90 B, D) they are thrown down to the sides of the base of the brain, and are connected over the *aquæductus Sylvii* by a broad commissural band.

Each prosencephalic lobe contains a lateral ventricle

Fig. 91.

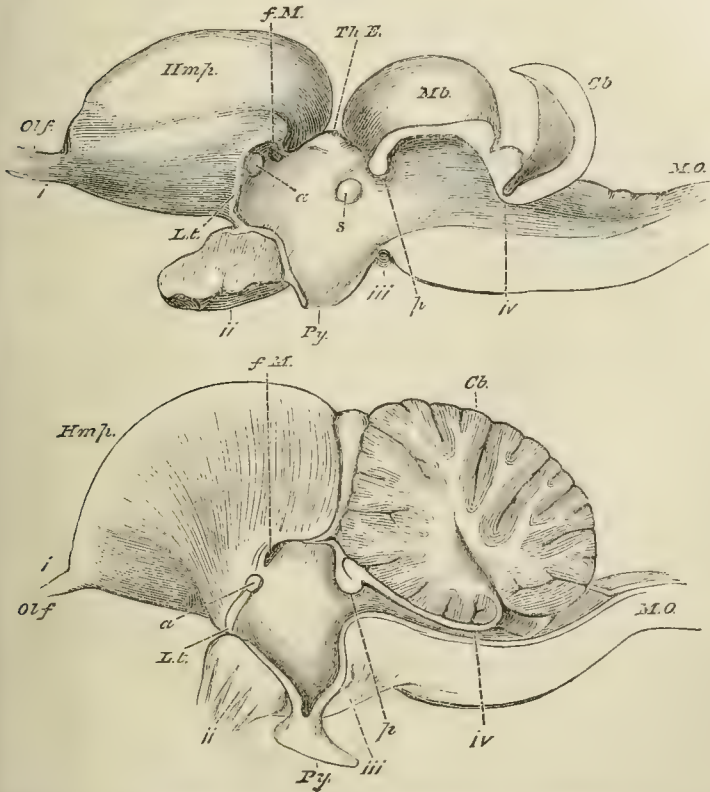


Fig. 91.—The brains of a Lizard (*Psammosaurus bengalensis*) and of a bird (*Meleagris gallopavo*), in longitudinal and vertical section. The upper figure represents the lizard's brain; the lower (taken, like fig. 90, B, D, from Carus' "Erläuterungs-Tafeln") that of the bird.

The letters as in the preceding figure, except *L. t.*, lamina terminalis, or anterior wall of the third ventricle; *f. M.*, foramen of Munro; *a.*, anterior commissure; *Th. E.*, thalamencephalon; *s.*, soft commissure; *p.*, posterior commissure; *iv.*, indicates the exact point of exit of the fourth pair from that part of the brain which answers to the valve of Vieussens.

(continuous through the foramen of Munro with the third ventricle), which is little more than a fissure between the very thin inner wall of the lobe and its thick outer part, which contains the corpus striatum. The corpora striata are united by an anterior commissure, which is not of large size. The thinning of the inner wall of the lobes, from the margin of the foramen of Munro backwards, which gives rise to the fissure of Bichat in the *Mammalia*, extends for a very short distance in the *Sauropsida*, even in birds.

The olfactory lobes are usually elongated, and contain ventricles continuous with those of the prosencephalic hemispheres.

In all *Sauropsida* the motor nerves of the tongue pass through a foramen in the ex-occipital bone. Hence, twelve pairs of cranial nerves are present, except in the *Ophidia*, which possess no spinal accessory nerve.

The lateral cutaneous branches so generally sent to the trunk by the pneumogastric in the *Ichthyopsida* are absent, but the pneumogastric gives a recurrent branch to the larynx. The third, fourth, and sixth nerves arise quite independently of the fifth.

The sympathetic is well developed, except in the *Ophidia*, where it is not distinct from the spinal nerves, in the greater part of the trunk.

The *Ophidia*, many *Sauria*, and *Aves*, possess nasal glands, which, in birds, attain a large size, and lie more usually upon the frontal bone, or in the orbits, than in the nasal cavity.

The eye, rudimentary in some *Ophidia* and *Lacertilia*, is usually large; and, sometimes, as in many birds and in the extinct *Ichthyosauria*, attains very great absolute and relative dimensions.

In the *Ophidia* and some *Lacertilia* (the *Amphisbænoidea*, some *Scincoidea*, all *Ascalobota*), the integument is continued over the eye, and becomes transparent. These reptiles are commonly said to possess no eyelids; but it must be remarked that this is not true of them in the

sense in which it is true of most osseous fishes, as the transparent covering of the eye really represents the two eyelids of the higher *Vertebrata*, and is separated from the eyeball by a chamber lined by conjunctiva, which communicates with the nose by a lachrymal canal. In the other *Sauropsida* two lids are developed, and each generally possesses a special palpebral muscle, which acts as an elevator of the upper, and a depressor of the lower, lid. In some *Scincoidea* the middle of the lower lid is transparent. In many *Lacertilia* it contains a cartilage or an ossification.

Most lizards, all *Chelonia*, *Crocodylia*, and *Aves*, possess a nictitating membrane moved by special muscles, which present three different arrangements.

In the lizards a short thick muscle (*bursalis*) is attached to the inner and posterior wall of the orbit, and ends in a fibrous sheath. A tendon, one end of which is attached to the presphenoidal region of the inner wall of the orbit, passes backwards through the sheath, and then forwards to be attached to the nictitating membrane. When the muscle contracts, it necessarily pulls the latter over the eye. A Harderian gland is always developed, and a lachrymal gland very generally, though not always.

In the *Chelonia*, muscular fibres (forming the so-called *pyramidalis* muscle) arise from the inner side of the eyeball, and, arching over it and the optic nerve, are inserted partly into the outer edge of the nictitating membrane, partly into the lower eyelid. The *Crocodylia* have a *pyramidalis* muscle taking the same origin and course; but it sends no fibres to the lower eyelid, its tendon being inserted altogether into the nictitating membrane.

The third arrangement, which in a manner combines together the first and the second, is that seen in birds. A *pyramidalis* muscle, arising from the inner and under surface of the eyeball, soon ends in a tendon which sweeps round the upper and outer surfaces of the sclerotic to the nictitating membrane, as in the crocodiles. But there is also a *bursalis* muscle, which however arises, not, as in lizards,

from the wall of the orbit, but from the upper surface of the sclerotic itself, whence it passes backwards and ends in a fibrous sheath which incloses the tendon of the *pyramidalis*. The contraction of this muscle necessarily tends to draw the tendon of the *pyramidalis* away from the optic nerve. A tubercle is sometimes developed from the sclerotic above the entrance of the optic nerve, and prevents the tendon of the *pyramidalis* from shifting forwards and inwards.

The eyeball is always moved by four *recti* and two *obliqui*. The superior oblique does not pass over a pulley. The *Chelonia* and most *Lacertilia* have a more or less completely developed retractor, or choanoid, muscle.

A ring formed of bony plates is developed in the fore part of the sclerotic in *Lacertilia*, *Chelonia*, *Ichthyosauria*, *Dicynodontia*, *Pterosauria* and *Aves*, but not in *Ophidia*, *Plesiosauria*, or *Crocodilia*.

The iris and the *tensor choroidei* contain striated muscular fibres.

A pecten is very generally developed. It attains a large size, and becomes much plaited, in most *Aves*.

Only *Crocodilia* and *Aves* possess a rudiment of an external ear.

The *Ophidia* and the *Amphisbænoidea* have no tympanic cavity. In some *Chelonia*, in *Sphenodon*, and in the Chamæleons, the tympanic membrane is covered by the integument, but a tympanic cavity exists. In *Lacertilia*, the tympanic cavities communicate by wide openings with the pharynx; but in *Chelonia*, *Crocodilia*, and *Aves*, the communicating passages, reduced in size, become Eustachian tubes. In the *Chelonia*, these curve backwards, downwards, and inwards, round the quadrate bones, and open separately on the roof of the mouth. In the *Crocodilia* there are, as has been described above (p. 255), three Eustachian tubes—one median and two lateral. In *Aves*, there is but one Eustachian aperture, answering to the median of the *Crocodilia*; and, as in the latter group, each Eustachian tube

usually traverses the osseous base of the skull, to join with its fellow in the common aperture.

The stapes is a columelliform bone, the outer end of which is attached to the tympanic membrane, where the latter is developed; but lies among the muscles when there is no tympanic cavity.

All *Sauropsida* possess a *fenestra rotunda*, as well as a *fenestra ovalis*, and all have a cochlea, which is never coiled spirally, and is more rudimentary in the *Chelonia* than in other groups. Three semicircular canals, an anterior and posterior vertical, and an external horizontal, are connected with the membranous vestibule. In *Aves*, the anterior vertical canal is very large in proportion to the others, and the adjacent crura of the two vertical canals overlap before they unite with one another.

Labial and buccal glands are developed in some *Sauropsida*, and one of them, on each side, attains a large development in the poison glands of the venomous snakes. Well-developed sublingual, submaxillary, and parotid glands appear in Birds, and the sublingual glands attain an immense size in the Woodpecker. The tongue varies greatly, being sometimes obsolete, as in the Crocodile and some birds (*e.g.* the Pelicans), sometimes horny and even spinose, sometimes fleshy. In the snakes, and some lizards, the tongue is forked, and capable of retraction into a basal sheath. In the Chamæleons, it is clubbed at its extremity, and can be retracted or protruded by the invagination or inversion of its hollow stem.

The alimentary canal of the *Sauropsida* is generally divided into an œsophagus, a simple stomach, a small intestine and large intestine, which last always terminates in a cloaca. It is invested by a peritoneal coat, which generally follows all the curvatures of the intestine. But in the *Ophidia*, the folds of the small intestine are united by fibrous tissue, and enclosed by a common sheath of peritoneum.

The stomach is usually a simple dilatation of the alimen.

tary canal, the cardiac and pyloric apertures of which are remote from one another; but, in the Crocodiles, and in most Birds, the pyloric and cardiac apertures are approximated. In many *Crocodylia* and *Aves*, there is a pyloric dilatation before the commencement of the duodenum.

In the *Crocodylia*, and in *Aves*, the walls of the stomach are very muscular, and the muscular fibres of each side radiate from a central tendon or aponeurosis. The thickening of the muscular tunic of the stomach attains its maximum in the graminivorous birds; and it is accompanied by the development of the epithelium into a dense and hard coat, adapted for crushing the food of these animals. Birds commonly aid the triturating power of this gastric mill by swallowing stones; but this habit is not confined to them, crocodiles having been observed to do the same thing.

Birds are further remarkable for the development of a broad zone of glands in the lower part of the œsophagus, which is usually dilated, and forms a *proventriculus*, connected by a narrow neck with the above-mentioned muscular stomach or gizzard (*gigerium*).

Some *Ophidia* have a cœcum at the junction of the small intestine with the large; and two such cœca, which sometimes attain a large size, are very generally developed in *Aves*. In this class also, the small intestine, not unfrequently, presents a cœcal appendage, the remains of the vitelline duct. The duodenum of Birds constantly makes a loop, within which the pancreas lies, as in *Mammalia*.

The liver in the *Sauropsida* almost always possesses a gall bladder, which is usually attached to the under surface of the right lobe, but in the *Ophidia* is removed to some distance from it.

A peculiar glandular sac, the *Bursa Fabricii*, opens into the anterior and dorsal region of the cloaca in birds.

Three forms of heart are found in the *Sauropsida*. The first is that observed in the *Chelonia*, *Lacertilia*, and *Ophidia*; the second, that in the *Crocodylia*; and the third, that in *Aves*.

1. In the *Chelonia*, *Lacertilia*, and *Ophidia*, there are two

auricles. Generally, a distinct *sinus venosus*, with contractile walls, and communicating by a valvular aperture with the auricle, receives the blood from the *venæ cavæ*, and pours it into the right auricle. The pulmonary veins usually open by a common trunk into the left auricle.

The interauricular septum is rarely (in some *Chelonia*) perforated. Its ventricular edge spreads out on each side into a broad membranous valve, the edge of which, during the systole, flaps against a ridge, or fold, developed, on one, or both, sides, from the margin of the auriculo-ventricular aperture, and constituting a rudiment of a second valve. The ventricle contains only one cavity, but that cavity is imperfectly divided into two or three chambers, by septa developed from its muscular walls.

In the Turtle (Fig. 92), a partly muscular, and partly cartilaginous, septum extends from the front wall of the ventricular cavity towards its right-hand end. It imperfectly divides the common ventricular cavity into a right small, and a left large, moiety. The latter of these receives the blood from the auricles. In consequence of the elongated form of the ventricular cavity, and the projection into it of the large auriculo-ventricular valves, especially of that of the right side, this left and larger moiety of the common ventricle is virtually divided into two, a left and a right, at the time of the auricular systole. The left portion becomes filled with arterial blood from the left auricle, and is distinguished as the *cavum arteriosum*; the right receives the venous blood from the right auricle, and is the *cavum venosum*.

No arterial trunk arises from the *cavum arteriosum*, but two arterial trunks arise from the right-hand end of the *cavum venosum*; these are the two aortic arches. One of these passes to the left and the other to the right side, and they cross one another as they do so, because the origin of the left arch lies more to the right, than does the origin of the right arch. The ostia of both arches are guarded by semi-lunar valves; and that of the left arch is placed below and to the right of that of the right arch. As no arterial trunk

arises from the *cavum arteriosum*, the red blood can be driven out of the latter, during the systole, only into the *cavum venosum*.

Fig. 92.

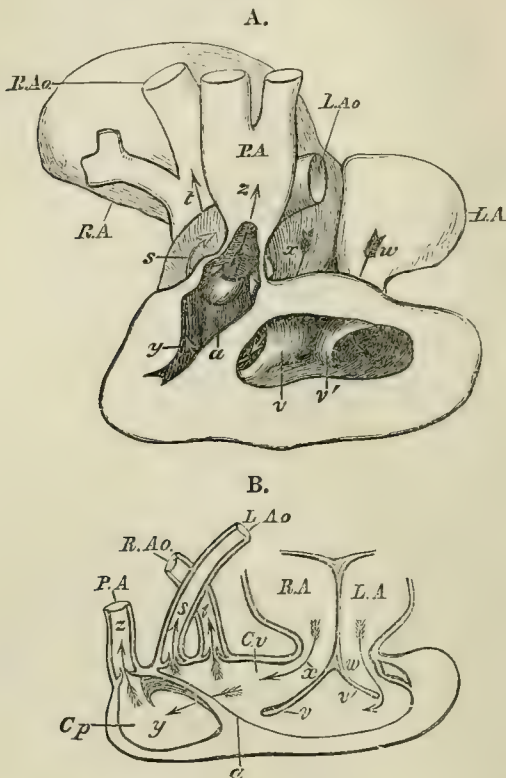


Fig. 92.—The Heart of a Turtle (*Chelone midas*).—*A*, a drawing from nature: the ventral face of the ventricle being laid open. *B*, a diagram explanatory of the arrangement of the cavities and vessels. *R. A.*, *L. A.* right and left auricles. *w*, *x*, arrows placed in the auriculo-ventricular apertures to indicate the course of the blood at the auricular systole. *v*, the right, and *v'*, the left median auriculo-ventricular valves. *C v.*, *cavum venosum*. *C p.*, *cavum pulmonale*. *a*, the incomplete septum which divides the *cavum pulmonale* from the rest of the cavity of the ventricle. *P. A.*, pulmonary artery. *R. Ao.*, *L. Ao.*, right and left aortæ. *s*, arrow showing the course of the blood in the right aorta; *t*, in the right aorta; *z*, in the pulmonary artery; *y*, between the *cavum venosum* and *cavum pulmonale*; *x*, in the left, and *w*, in the right auriculo-ventricular aperture.

The right, comparatively small, moiety of the ventricle is separated from the *cavum venosum* by the already mentioned septum, which is attached between the origin of the left aortic arch, and that of the pulmonary artery, its free edge looking towards the dorsal face of the heart. Thus the pulmonary artery arises from what is, virtually, a separate subdivision of the ventricle, or a *cavum pulmonale*.

When the systole of the ventricle takes place, the practical result of these arrangements is, that the pulmonary artery, and the aortic arches, at first, receive wholly venous blood from the *cavum venosum* and *cavum pulmonale*. But as the arterial blood of the *cavum arteriosum* is driven into the *cavum venosum*, the venous blood of the latter tends to be excluded from the mouths of the aortic arches, and to be driven into the *cavum pulmonale*, while the aortic arches receive arterialised blood. The left arch receives a larger proportion of venous blood than the right. As the ventricle contracts, the free edge of the muscular septum approaches the dorsal wall of the ventricle, and gradually closes the access to the *cavum pulmonale*, which thus finally expels the venous blood which it received from the *cavum venosum*, but admits none of the arterialised blood; consequently none of this reaches the lungs.

2. In the *Crocodylia*, the *cavum venosum* and the *cavum arteriosum* are converted into perfectly distinct right and left ventricles. The right ventricle gives off the pulmonary artery, and, in addition, an aortic arch which crosses over to the left side. From the left ventricle only a single trunk arises, and this, crossing to the right side, becomes the right aortic arch, of which the dorsal aorta is the direct continuation. The walls of the two aortic arches are in contact where they cross one another; and, at this point, a small aperture, situated above the semilunar valves, places the cavities of the two arches in communication.

Thus, in the *Crocodylia*, the venous and the arterial currents communicate only outside the heart, not within it, as in the foregoing groups.

The septum of the *cavum pulmonale* remains as a small muscular band, and the fold of the outer lip of each auriculo-ventricular aperture, has become a distinct membranous valve.

3. In *Aves*, the venous and arterial blood currents, communicate only in the pulmonary and systemic capillaries. The auricular and ventricular septa are complete, as in the *Crocodylia*; but the right ventricle gives off only the pulmonary artery, the left aortic arch having disappeared. The septum of the *cavum pulmonale* becomes a great muscular fold, and takes on the function of an auriculo-ventricular valve. At the origin of the pulmonary artery, and at that of the aortic arch, three semilunar valves are developed.

In Reptiles there are usually only two aortic arches, one on each side, answering to the fourth pair of arches of the embryo. The right gives off the carotid and subclavian arteries, and passes directly into the trunk of the dorsal aorta. The left commonly gives off visceral arteries, and becomes a good deal diminished in size before joining the common trunk.

In many *Lacertilia*, four aortic arches, (answering to the third and fourth pairs of the embryo,) persist, two anterior arches, from which the carotids are given off, springing, by a common trunk, from the right ordinary aortic arch.

In the *Reptilia*, most of the blood of the hind limbs and tail passes through one or other of two "portal systems" before reaching the heart, the one portal system lying in the kidney, the other in the liver. The portion which goes to the liver is carried to it mainly by the anterior abdominal veins, which are represented by two trunks in most *Reptilia*, by one in the *Ophidia*.

In *Aves* there is no renal portal system, and the anterior abdominal vein opens into the inferior vena cava close to the heart. Nevertheless a median trunk, which is given off from the caudal vein, carries a considerable proportion of its blood directly into the hepatic portal system.

All the *Sauropsida* possess a larynx, a trachea, and one or two lungs. The bronchi do not divide dichotomously, as they do in *Mammalia*.

In *Chelonia* and *Crocodylia* the larynx consists of a circular cartilage, apparently corresponding with both the thyroid and the cricoid of the higher *Vertebrata*; and of the arytenoid cartilages, articulated with its anterior and dorsal edge.

The *Lacertilia* have, for the most part, a similar larynx, but the circular cartilage is often interrupted by round, or elongated, membranous fontanelles. In the Chamæleons, the mucous membrane of the larynx between the circular cartilage and the first ring of the trachea protrudes in the form of an air sac.

In the *Amphisbœnoidea*, and in the *Ophidia*, the skeleton of the larynx consists of two lateral longitudinal bands of cartilage, united by from four to sixteen transverse bands. In other words, the structure which answers to the circular cartilage is greatly elongated, and has many transversely elongated fontanelles. There is a single arytenoid cartilage, which is sometimes represented by a process of the anterior dorsal margin of the circular cartilage. An epiglottis is rarely present.

In Birds there are distinct thyroid, cricoid, and arytenoid cartilages, which may be more or less completely ossified. Sometimes an epiglottis is added.

The voice of Birds, however, is not formed in the larynx, but in the *syrinx*, or lower larynx, which may be developed in three positions:—1. At the bottom of the trachea, from the trachea alone. 2. At the junction of the trachea and bronchi, and out of both. 3. In the bronchi alone. The *syrinx* may be altogether absent, as in the *Ratitæ* and the *Cathartidæ*, or American vultures.

The commonest form of *syrinx* is the second mentioned above, or the *broncho-tracheal syrinx*. It is to be met with in all our common song birds, but is also completely developed in many birds, such as the crows, which have no song. In its commonest condition this form of *syrinx* presents

the following characters. The hindermost rings of the trachea coalesce, and form a peculiarly shaped chamber, the *tympanum*. Immediately beyond this, the bronchi diverge, and from their posterior wall, where one bronchus passes into the other, a vertical fold of the lining membrane rises, in the middle line, towards the tympanum, and forms a vertical *septum* between the anterior apertures of the two bronchi. The anterior edge of this septum is a free and thin *membrana semilunaris*, but in its interior a cartilaginous or osseous frame is developed, and becomes united with the tympanum. The base of the frame is broad, and sends out two cornua, one along the ventral, and the other along the dorsal, edge of the inner wall of the bronchus of its side; which, in this part of its extent, is membranous and elastic, and receives the name of the *membrana tympaniformis interna*.

The bronchial "rings" opposite this are necessarily incomplete internally, and have the form of arches embracing the outer moiety of the bronchus. The second and third of these bronchial arcs are freely moveable, and elastic tissue accumulated upon their inner surfaces, gives rise to a fold of the mucous membrane, which forms the outer boundary of a cleft, bounded, on the inner side, by the *membrana semilunaris*. The air forced through these two clefts from the lungs sets their elastic margins vibrating, and thus gives rise to a musical note, the character of which is chiefly determined by the tension of the elastic margins and the length of the tracheal column of air. The muscles, by the contraction of which these two factors of the voice are modified, are extrinsic and intrinsic. The former are possessed by birds in general, and are usually two pair, passing from the trachea to the furcula and to the sternum. Some birds possessing a broncho-tracheal syrinx such as has been described, as the *Alectoromorphæ*, *Chenomorphæ*, and *Dysporomorphæ*, have no intrinsic muscles. Most others have one pair, attached, one on each side, to the rings of the trachea above, and to the tympanum, or the proximal bronchial arcs, below. The majority of the *Coracomorphæ*

have five or six pairs of intrinsic syringeal muscles, which pass from the trachea and its tympanum to the moveable bronchial arcs. The Parrots have no septum, and only three pairs of intrinsic muscles.

The *tracheal syrinx* occurs only in some American *Cora-comorphæ*. The hinder end of the trachea is flattened, and six or seven of its rings above the last are interrupted at the sides, and held together by a longitudinal ligamentous band. These rings are excessively delicate, so that this part of the trachea is in great part membranous.

The *bronchial syrinx* occurs only in *Steatornis* and *Crotophaga*.

In the genus *Cinyxis*, among the *Chelonia*, and in some species of *Crocodylus* (*C. acutus*, e.g.) the trachea is bent upon itself. Similar flexures attain an extraordinary development in many birds, and may lie outside the thorax under the integument (*Tetrao urogallus*, some species of *Crax* and *Penelope*); in the cavity of the thorax (some Spoonbills); on the exterior of the sternum (some Swans and Cranes); or even in a sort of cup formed by the median process of the furcula (the Guinea-fowl). In the Emeu some of the rings of the trachea are incomplete in front, and bound the aperture of an air sac which lies in front of the trachea. Some birds (*Aptenodytes*, *Procellaria*) have the trachea divided by a longitudinal septum, as in *Sphargis* among the *Chelonia*. The tracheal tympanum is greatly enlarged in *Cephalopterus*, and in many Ducks, Geese, and Divers; and in these aquatic birds the enlargement is more marked in the males, and is usually asymmetrical, the left side being generally the larger.

In the *Ophidia*, the bronchus opens at once into the lung; and the latter is an elongated sac, the walls of which are produced into numerous septa, which render the cavity highly cellular near the bronchus, while, at the opposite end, they become smooth and but little vascular. In this latter region the lung may receive its blood from the systemic and not from the pulmonary circulation. The lungs are always unequal in size, and the left is usually the smaller. Very

frequently, especially among the poisonous snakes, one lung is rudimentary or altogether absent; and the posterior portion of the trachea may take on the structure of a lung.

The lungs of Lizards much resemble those of the *Ophidia*, and they are elongated and unequal in size in the snake-like *Lacertilia*. In the ordinary lizards they are more rounded and the trachea and bronchi are shorter. In many *Chamæleons*, and in some *Geckos*, the posterior half of each lung is produced into narrow diverticula, which lie among the abdominal viscera, and foreshadow the air sacs of birds.

In the *Crocodilia* each bronchus traverses its lung, and at first retains, but soon loses, its cartilaginous rings. Lateral apertures in the walls of the bronchus lead into sacculated pouches, each of which resembles the lung of an ordinary *Lacertilian*.

The *Chelonia* have similar lungs; but while, in the foregoing groups, the two lungs are free and invested on all sides by the peritoneum, in this they are fixed against the inner periosteum of the carapace, and are covered by peritoneum on their ventral face only. This resemblance to the arrangement of the lungs in birds is increased by the presence of a muscular diaphragm, the fibres of which spread over the ventral faces of the lungs.

In *Aves* the lungs are firmly fixed on each side of the vertebral column, the dorsal surface of each lung being moulded to the superjacent vertebræ and ribs. The muscular fibres of the diaphragm arise from the ribs outside the margins of the lungs, and from the vertebral column, and end in an aponeurosis upon the ventral surface of the lungs.

Each bronchus enters its lung nearer the centre than the anterior edge; and, immediately losing its cartilaginous or bony rings, dilates, and then traverses the lung, gradually narrowing, to the posterior edge of that viscus, where it terminates by opening into the posterior air sac, which generally lies in the abdomen. From the inner side of the bronchus canals are given off, one near its distal end, and

others near its entrance into the lung, which pass directly to the ventral surface of the lung, and there open into other air sacs. Of these there are four. Two, the *anterior* and the *posterior thoracic*, lie on the ventral face of the lung in the thorax. The other two are situated in front of its anterior end, and are extra-thoracic. The external and superior is the *cervical*, the internal and inferior, the *interclavicular*. This last unites into one cavity with its fellow of the opposite lung. Thus there are altogether nine air sacs; two posterior or abdominal, four thoracic, two cervical, and one interclavicular. Other large canals given off from the bronchus do not end in air-sacs, but those which pass from the inner side of the bronchus, run along the ventral surface, and those on the outer side, along the dorsal surface, of the lung. Here they give off, at right angles, series of secondary canals, and these similarly emit still smaller tertiary canals; and thus the whole substance of the lung becomes interpenetrated by tubuli, the walls of the finest of which are minutely sacculated. The different systems of tubuli are placed in communication by perforations in their walls.

In most birds, the air-sacs (except the anterior and posterior thoracic, which never communicate with any cavity but that of the lungs) are in connection with a more or less extensively ramified system of air passages, which may extend through a great many of the bones, and even give off subcutaneous sacs. Thus the interclavicular air-sac generally sends a prolongation into each axilla, which opens into the proximal end of the humerus, and causes the cavity of that bone to be full of air. When the sternum, the ribs, and the bones of the pectoral girdle are pneumatic, they also receive their air from the interclavicular air-sacs. The cervical air-sacs may send prolongations along the vertebral canal of each side, which supply the bodies of the cervical vertebræ, and communicate with elongated air-chambers in the spinal canal itself. When the dorsal vertebræ are pneumatic, they communicate with the system of the cervical air-sacs. The abdominal air-sacs send pro-

longations above the kidneys to the sacral vertebræ and to the femora, whence these bones, when they are pneumatic, receive their air.

The pulmonary air-sacs and their prolongations do not communicate with the air cavities of the skull, which receive their air from the tympana and the nasal chambers. In some birds, the air is conducted from the tympanum to the articular piece of the mandible by a special bony tube, the *siphonium*.

In all *Sauropsida*, the ureters open directly into the cloaca, which is provided with a urinary bladder in the *Lacertilia* and the *Chelonia*, but not in other *Reptilia*, nor in *Aves*.

Organs of copulation present themselves under three forms:—

1. In the *Chelonia*, the *Crocodylia*, and the Ostrich, a simple solid penis, grooved upon its posterior aspect, is attached to the anterior wall of the cloaca, and contains erectile tissue. In the ostrich this penis lies in a sac of the cloaca, into which it can be retracted somewhat as in the *Menotremata*.

2. In many birds, such as the *Rheidæ*, *Casuaridæ*, *Apterygidæ*, *Tinamomorphæ*; *Penelope*, and *Crax*, among the *Alectoromorphæ*; and in many aquatic birds, there is also a single penis attached to the front wall of the cloaca, grooved on its dorsal side, and supported by two fibrous bodies coated with more or less erectile tissue. But the distal end of the penis is invaginated, and the involution held in this position, except during erection, by an elastic ligament.

3. In *Lacertilia* and *Ophidia*, two copulatory organs are developed at the sides of the cloaca. The integument is prolonged inwards, on each side, into a blind sac, which lies upon the inferior caudal muscles. The inner surface is often armed with spiny developments of the epidermis, and presents a groove, which is continued on the parietes of the cloaca to the aperture of the vas deferens. The wall of the blind sac contains erectile tissue, and it can be erected or retracted by appropriate muscles.

CHAPTER VIII.

THE CLASSIFICATION AND ORGANIZATION OF THE
MAMMALIA.

THE class Mammalia is^o divisible into the following groups :—

A. There are large and distinct coracoid bones, which articulate with the sternum.

The ureters and the genital ducts open into a cloaca, into which the urinary bladder has a separate opening.

The penis is traversed by an urethral canal which opens into the cloaca posteriorly, and is not continuous with the cystic urethra.

There is no vagina.

The mammary glands have no teats.

I. ORNITHODELPHIA.

1. *Monotremata*.

B. The coracoid bones are mere processes of the scapula in the adult, and do not articulate with the sternum.

The ureters open into the bladder; the genital ducts, into an urethra or vagina.

The cystic urethra is continuous with the urethral canal of the penis.

There is a single or a double vagina.

The mammary glands have teats.

A. The embryo does not become connected with the wall of the uterus by an allantoic placenta. The vagina is double.

II. DIDELPHIA.

2. *Marsupialia*.

B. The embryo has an allantoic placenta. The vagina is single.

III.—MONODELPHIA.*

a. Median incisor teeth are never developed in either jaw.

* The manner in which the *Monodelphia* are here subdivided must be regarded as merely provisional.

3. *Edentata*.

b. Median incisor teeth are almost always developed in one or both jaws.

i. The uterus develops no decidua (*Non-deciduata*).

4. *Ungulata*.

5. *Toxodontia* (?).*

6. *Sirenia* (?).*

7. *Cetacea*.

ii. The uterus develops a decidua (*Deciduata*).

a. The placenta is zonary.

8. *Hyracoidea*.

9. *Proboscidea*.

10. *Carnivora*.

β. The placenta is discoidal.

11. *Rodentia*.

12. *Insectivora*.

13. *Cheiroptera*.

14. *Primates*.

I. The ORNITHODELPHIA are those mammals which approach nearest to the *Sauropsida*, although separated from them by all the essential characters of the *Mammalia* which have already been defined.

The two genera *Echidna* and *Ornithorynchus*, which constitute this division, agree with one another, and differ from all other Mammals, in the combination of the following characters:—

In the spinal column, the centra of the vertebræ are devoid of epiphyses. The *os odontoideum*, or so-called "odontoid process" of the second cervical vertebra remains for a long time, if not throughout life, unankylosed with the body of that vertebra, as is the case in many Reptiles. And some of the cervical ribs, in like manner, long persist in a separate condition.

A striking Sauropsidan and Amphibian feature, peculiar to the *Ornithodelphia*, is seen in the fact that the coracoid, which is a large bone, articulates with the sternum directly. In front of it is another considerable ossification called the *epicoracoid*, which corresponds in position, though not in the manner of its ossification, with the ossified cartilage so termed in reptiles. In these mammals alone, again, there is a T-shaped interclavicle, which supports the clavicles.

* The placentation of the *Toxodontia* and *Sirenia* is unknown.

The central portion of the acetabulum remains unossified, and hence, in the dry skeleton, appears perforated, as in *Aves*, *Ornithoscelida*, and *Crocodylia*.

The inner tendons of the external oblique muscles are ossified for a considerable distance; and these ossifications appear in the dry skeleton as bones, which are articulated with the inner portions of the anterior margins of each pubis. These bones correspond with those which exist in a like position in the *Didelphia*, and are called *marsupial* bones; though the term is peculiarly inappropriate, inasmuch as they have nothing to do with the *marsupium*, or pouch, in which the young are sheltered in most of the *Didelphia*.

In the upper view of the brain the cerebellum is left completely uncovered by the cerebral hemispheres. The latter are connected by only a very small corpus callosum. The anterior commissure, unlike that of any of the *Sauropsida*, attains a very great size, and the hippocampal sulcus is prolonged forwards to the corpus callosum.

In the internal ear, the cochlea is only slightly bent upon itself, not coiled into a spiral, as in other *Mammalia*. The stapes is imperforate and columelliform, and the malleus is very large, while the incus is singularly small.

There is a spacious cloaca common to the rectum, genital and urinary organs, as in the *Sauropsida* and many *Ichthyopsida*. In both sexes a long urogenital canal opens into the front part of the cloaca. At its anterior end there are five distinct apertures—one in the middle line for the bladder, and two on each side, which are the openings of the genital ducts and of the ureters. Thus in these *Mammalia*, and in these only, the ureters do not open into the urinary bladder. The testes remain in the abdomen throughout life. The penis is attached to the front wall of the cloaca, and is not united directly with the ischia. It is traversed by an urethral canal, which opens into the cloaca posteriorly, but is not directly connected with either the seminal or the urinary passages. It is probable that during copulation, the posterior aperture of the penial urethra is

applied to the anterior aperture of the urogenital canal, so as to form a continuous passage for the semen.

The ova of the female are very large and project from the surface of the ovary, as in the *Sauropsida*. The mouths of the Fallopian tubes are not fimbriated. There is no vagina distinct from the urogenital chamber. The mammary glands are situated, one upon each side of the middle line, in the hinder part of the abdominal wall. The various ducts of the gland open upon a small area of the integument which is not raised up into a teat, so that, in the strict etymological sense of the word, these animals are not *Mammalia*. The mammary gland is compressed by the *panniculus carnosus*, and not by any prolongation of the *cremaster*.

There is no sufficient evidence of the nature of the fœtal appendages; but the embryo is born in an imperfect condition, and may be provided with a knob or caruncle upon the premaxillæ, such as is found in the *Sauropsida*. In the adult the heart exhibits a *fossa ovalis*.

Both genera of the *Ornithodelphia* are restricted to Australia, including Tasmania under that name.

The one of them, *Echidna*, has the body covered with spines, like a porcupine. It possesses strong digging feet, and a narrow toothless mouth, from which the long tongue, with which it licks up the ants upon which it preys, is protruded.

The other genus, *Ornithorhynchus*, has soft fur; a flattened muzzle resembling the beak of a duck, and covered with a leathery integument; and clawed, but strongly webbed feet, fitting it for its altogether aquatic mode of life. The *Ornithorhynchus*, in fact, frequents fresh water pools and rivers, very much like a water rat, sleeping and breeding in burrows excavated in the bank.

In these animals the angle of the mandible is not inflected. They are devoid of any external ear; and in the males, a kind of spur, which is perforated, and gives exit to the secretion of a gland, is attached to the astragalus. The function of this organ is unknown. In each genus the

heart is provided with two superior cavæ. In *Echidna* the right auriculo-ventricle valve is membranous, but, in *Ornithorhynchus*, it is more or less fleshy.

The hemispheres of the brain are abundantly convoluted in *Echidna*, but are smooth in *Ornithorhynchus*. The ovaries are of equal size in *Echidna*; but, in *Ornithorhynchus*, the right is much smaller than the left, as in Birds. As has already been stated, *Echidna* is entirely devoid of teeth, while *Ornithorhynchus* has four large horny teeth.

II. The DIDELPHIA.—In the *Didelphia*, the “odontoid process” early becomes completely ankylosed with the body of the second vertebra; and, usually, all the cervical ribs speedily lose their distinctness, as in Mammals in general.

The coracoid is reduced to a mere process of the scapula and does not come near the sternum. There is no epicoracoid, such as exists in the *Ornithodelphia*. There is no T-shaped interclavicle, but the clavicles, which are always present (except in *Perameles*) articulate with the manubrium of the sternum, in the same way as in ordinary *Mammalia*. The floors of the acetabula are completely ossified, and consequently are imperforate in the dry skeleton. The cochlea is coiled upon itself.

There is a shallow cloaca, the sphincter muscle being common to the urinary and genital apertures, but there is no such urogenital chamber as in the *Monotremata*. The ureters open directly into the bladder.

In the male, the urogenital part of the urethra, and that which traverses the penis, form one continuous canal, which opens outwards only at the extremity of the penis.

In the female, the vaginal, is perfectly distinct from the urinary, passage. The mouths of the Fallopian tubes are fimbriated, and the ova are not larger than those of the *Monodelphia*.

The mammary glands are provided with long teats.

In all the preceding characters the *Didelphia* agree with the *Monodelphia*, and differ from the *Ornithodelphia*.

But they agree with the *Ornithodelphia*, and differ from

the *Monodelphia* in possessing either bones, or cartilages, attached to the pubes, in the position of the so-called marsupial bones of the *Ornithodelphia*.

Again, the brain, the cerebral hemispheres of which may or may not have a convoluted surface, is provided with a very small corpus callosum, and a large anterior commissure. The hippocampal sulcus is prolonged forwards over the corpus callosum.

The crura of the corpus cavernosum of the penis are not fixed to the ischium.

The embryo does not become connected with the parent by villi developed from the allantois, and it is born in a very imperfect condition.

Certain characters are peculiar to the *Didelphia*. Thus, the testes of the male pass into a scrotum, which is suspended in front of the penis. In the female, the cremaster muscle is largely developed, and spreads over the surface of the mammary gland, which it compresses, so as to drive the milk out of the projecting teat. There is no *fossa ovalis* on the right side of the septum of the auricles. Very generally, though not invariably, the *Didelphia* possess what is termed a marsupial pouch, which is a sort of bag, formed by a fold of the integument of the abdomen, into which muscular fibres of the *panniculus carnosus* extend. These support the ventral wall of the pouch, and are capable of closing its mouth, which may be directed either forwards or backwards. The mammary glands lie in the dorsal wall of this pouch, into which the teats project.

There is no direct communication between the female generative organs and the pouch; but the minute young are transported, in the blind and imperfect state in which they are born, into the interior of the *marsupium*, and each becomes attached to a nipple, which exactly fills its mouth. To this it remains attached for a considerable period, the milk being forced down its throat by the contraction of the cremaster muscle. The danger of suffocation is averted by the elongated and conical form of the upper extremity of the larynx, which is embraced by the soft palate, as in

the *Cetacea*; and thus respiration goes on freely, while the milk passes, on each side of the laryngeal cone, into the œsophagus.

It very commonly happens among the *Didelphia* that the two long vaginae are bent upon themselves, their proximal ends becoming applied together and dilated, and these dilated portions not unfrequently communicate. Another very general peculiarity of the *Didelphia* is the inflection of the lower margin of the angle of the mandible inwards into a strong horizontal process. In the genus *Tarsipes*, however, this process is absent.

There are further anatomical characters which are well worthy of notice, though they are not so important as the foregoing.

The integument is always furry, never spiny or scaly, nor provided with dermal scutes. The pinna of the external ear is well developed. In the skull the carotid arteries pierce the basisphenoid to enter the cranial cavity. The tympanic cavity is, in front, bounded by the alisphenoid; and, very generally, the jugal furnishes part of the articular surface for the mandible.

Many of the cranial sutures, especially in the occipital region, persist throughout life; and the squamosal, the united periotic ossifications, and the tympanic bones remain distinct from one another.

The jaws are always provided with true teeth; and, usually, these teeth are readily distinguished into incisors, canines, false molars, and true molars. The canines, however, are absent in some genera, either in both jaws or in the mandible. There are usually four true molar teeth, and, as Professor Flower has recently discovered, only one grinder succeeds another vertically. It represents the last premolar. The molars never possess a complex structure.

No didelphous mammal has three incisor teeth upon each side above and below; and none but *Phascolomys* has an equal number of incisors in each jaw, the number of the upper being, usually, in excess of that of the lower jaw.

The number of the dorso-lumbar vertebræ is almost

always nineteen; and, of these, six are usually dorsal. The atlas is generally incompletely ossified in the ventral median line. The manus usually possesses five digits, but in *Perameles* and *Chæropus* the outer digits become rudimentary.

The fibula is always complete at its distal end. In some cases it becomes ankylosed with the tibia, while in the Wombat (*Phascolomys*), the Phalangiers (*Phalangistidæ*), and the Opossums (*Didelphidæ*), it is not only free, but is capable of a rotatory movement upon the tibia, similar to the movement of pronation and supination of the radius upon the ulna in Man. The rotation of the fibula towards the ventral side of the tibia is effected by a muscle which, in great measure, occupies the place of the interosseous ligament, and is analogous to the *pronator quadratus* in the fore limb. This muscle is antagonised by the extensors of the digits, so far as they arise from the fibula.

The digits of the pes vary remarkably in their form and relative development among the *Marsupialia*; the different subdivisions of the order being very well distinguished by the modifications of the hind foot.

Thus in the especially carnivorous marsupials—the *Didelphidæ*, of America, and the *Dasyuridæ*, of the Australian province—the second and third digits of the pes are not united together by the integument. In the *Didelphidæ*, the hallux is nail-less, but large and opposable, so as to convert the pes into a prehensile organ like that of many *Primates*; in the *Dasyuridæ*, on the other hand, the hallux is rudimentary or absent. In all the other marsupials, the second and third digits of the pes are syndactyle, or united together by integument. In the Wombat, the fourth toe is bound together with the other two, and the small hallux is devoid of a nail. In the Phalangiers, only the second and third toes are syndactyle, and they are slender, compared with the other digits, while the hallux is well developed and opposable. In the *Peramelidæ* (Bandicoots) and *Macropodidæ* (Kangaroos), the metatarsus is much elongated, and the second and third digits united and slender, while the

fourth toe is very large. The hallux is reduced to its metatarsal bone in the *Peramelidæ*, and the fifth digit is small or rudimentary. In the Kangaroos, the hallux disappears altogether, but the fifth digit remains well developed, though not so large as the fourth.

There is a great range of variation in the characters of the brain. The carnivorous marsupials (*Didelphys*, *Dasyurus*, *Thylacinus*) exhibit the lowest type of cerebral structure, the olfactory lobes being very large and completely exposed, while the cerebral hemispheres are comparatively small and quite smooth. In the Kangaroos, on the other hand, the cerebral hemispheres present numerous convolutions and are much larger in proportion to the olfactory lobes, which they cover.

The stomach may be simple, as in most *Marsupialia*, or provided with a cardiac gland (*Phascolarctos*, *Phascolomys*). In the Kangaroos, it becomes immensely elongated, with longitudinal muscular bands and transverse sacculations, so that it resembles the human colon. The cœcum, which is large in the Kangaroos, but absent in the *Dasyuridæ*, is provided, in the Wombat, with a vermiform appendix like that of Man.

The liver always possesses a gall-bladder. There are two *venæ cavæ superiores*, and they receive the *venæ azygos* of their respective sides. The tricuspid valve in the heart is membranous. There is no inferior mesenteric artery, and the external and internal iliaes arise separately from the aorta.

There are no vesiculæ seminales, and the glans penis is bifurcated in many species. The marsupial pouch is absent in some Opossums and *Dasyuridæ*. When it is present, its mouth is usually directed forwards, but in *Thylacinus* and in some *Peramelidæ* it looks backwards. In *Thylacinus* also the "marsupial bones" remain cartilaginous. The condition of the fœtus is known only in the Kangaroos, and further observations on the embryology of the *Didelphia* are much needed. The fœtus is said to possess a large umbilical sac, the vessels of which extend on to the plaited

chorion; and a small allantois; and to be devoid of a thymus gland.

The *Didelphia* are at present confined to the Australian and the Austro-Columbian provinces, some few species stretching beyond the borders of the latter into the northern parts of North America. The *Didelphidæ* alone are found in Austro-Columbia, all the other groups being Australian.

Gigantic, Kangaroo-like, or Phalangistic, forms (*Nototherium*, *Diprotodon*, *Thylacoleo*), have been found in post-tertiary deposits and caves in Australia. In Europe, *Didelphidæ* occur in Eocene strata; *Didelphidæ*, *Dasyuridæ*, and *Macropodidæ* (*Phascolotherium*, *Amphitherium*, *Plagiaulax*), in middle Mesozoic rocks; and *Macropodidæ* (?) (*Microlestes*) in the Trias.

III. The MONODELPHIA.—In the *Monodelphia*, the *os odontoideum* very soon becomes ankylosed with the second cervical vertebra, of which it appears merely as the odontoid process; and the cervical ribs early become inseparably united with their vertebræ. The coracoid is reduced to a mere process of the scapula, and there is no epicoracoid similar to that of the *Ornithodelphia*.

Clavicles may be present or absent. When completely developed they articulate directly, or by the intermediation of more or less modified remains of the sternal end of the coracoid, with the sternum, and not with any interclavicle. The acetabula are imperforate. The pelvis is devoid of marsupial bones; though, in some *Carnivora*, there are small cartilages in the inner tendons of the external oblique muscle, which have a corresponding form and relations.

The anterior commissure and the corpus callosum, no less than the cerebral hemispheres themselves, vary greatly, the brains of some *Edentata* very closely approaching those of the *Didelphia* in respect of the corpus callosum and anterior commissure; while, as regards the hemispheres themselves, they may either be so small as to allow the cerebellum to be completely exposed on the dorsal aspect, or so large, as completely to cover it and project beyond it. The

external surface of the hemispheres again, may be either perfectly smooth or extremely convoluted.

The cochlea is coiled spirally. The reproductive and urinary apertures, as a general rule, open quite separately from the rectum. The ureters always open into the bladder. The testes may remain in the abdomen throughout life, or may pass into a scrotal pouch. But, when this scrotum forms a distinct sac, it lies at the sides of, or behind, the penis, and not in front of it. The cystic urethra is always continuous with that part of the urethra which traverses the penis.

The ova are small, and the mouths of the Fallopian tubes are fimbriated. The vagina is a single tube, which may however be partially divided by a longitudinal partition. The cremaster has no relation to the mammary glands, which are provided with distinct teats.

The allantois is always well developed, and gives rise to a placenta; and the young are born of large size, and active.

The great majority of the *Monodelphia*, as thus defined, are divisible according to the characters of their placenta into *non-deciduata* and *deciduata*.

In the *non-deciduata* the foetal villi of the placenta are, at birth, simply withdrawn from the uterine fossæ, into which they are received, and no part of the maternal substance is thrown off in the form of decidua, or maternal part of the placenta. In the *deciduata*, on the other hand, the superficial layer of the mucous membrane of the uterus undergoes a special modification, and unites, to a greater or less extent, with the villi developed from the chorion of the foetus; and, at birth, this decidual and maternal part of the placenta is thrown off along with the foetus, the mucous membrane of the uterus of the parent being regenerated during, and after, each pregnancy.

There are, however, two orders of existing monodelphous *Mammalia*, the nature of the placentation of which is not yet fully made out. One of these is the *Sirenia*, the placentation of which is unknown. The other is the ill-defined

and heterogeneous assemblage called *Edentata*. Some of the members of this group certainly possess deciduate placenta, while, in others, it appears questionable whether the decidua is, or is not, developed. And as this group, the *Edentata*, is decidedly the lowest of the whole division, I shall take it first in order, while the *Sirenia* are arranged, provisionally, among the *Non-deciduata*.

The EDENTATA, or BRUTA.—In these Mammals the teeth are by no means always wanting, as the name of the group would seem to imply; but, when teeth are present, incisors are either altogether absent, or, at any rate, the median incisors are wanting in both jaws. The teeth are always devoid of enamel, consisting merely of dentine and cement. As they grow for an indefinite period they never form roots; and, so far as our knowledge at present extends, those which first appear are displaced by a second set only in some of the Armadillos. The ungual phalanges of the digits support long and strong claws.

There are mammae upon the thorax, and sometimes, in addition, on the integument of the abdomen; or, in the inguinal region.

The brain varies greatly, its hemispheres being sometimes quite smooth, with a very small corpus callosum and large anterior commissure; while, in other cases, the corpus callosum is much larger, and convolutions appear upon the surface of the brain.

The *Edentata* are divided into the *Phytophaga*, or vegetable feeders, and the *Entomophaga*, or insect-eating forms. Leaves are the chief food of the former group, while the latter delight chiefly in ants, though some take, in addition, worms and carrion.

1. In the *Phytophaga* the long bones are without medullary cavities. The lateral part of the zygomatic arch sends down a remarkable vertical process. The acromial process of the scapula coalesces with the coracoid. In the carpus, the scaphoid and the trapezial bones ankylose and form one. The ischia become united with the anterior

caudal vertebræ, and these ankylose with the proper sacrales to form the long sacrum.

The ankle joint has the character of a peg and socket, and the hind foot is, more or less completely twisted, resting upon its outer edge, and not upon its sole.

Vascular canals connected with the pulp cavity traverse the dentine of the teeth.

The *Phytophaga* are divisible into two groups, one existing, and the other extinct. The former consists of the Sloths, or *Tardigrada*; remarkable animals, which are confined to the great forests of South America, where they lead a purely arboreal life, suspended by their strong, hook-like, claws to the branches of the trees.

Their distinctive characters are these:—The tail is short, and the limbs exceedingly long and slender, the anterior, being longer than the posterior, pair. In both the fore and the hind limbs the internal and the external digits are rudimentary, but the hind foot always has the three middle toes completely developed; while, in the fore foot, it sometimes happens that only two remain. The unguis phalanges are very long and hooked.

The zygomatic arch is incomplete posteriorly, not being united by bone with the squamosal. The cervical vertebræ in this remarkable group sometimes exceed, and sometimes fall short of, the number (seven) which is so characteristic of the *Mammalia* in general; some species of Sloths having nine, and others only six, vertebræ in the neck.

The pelvis is exceedingly spacious, and the acetabula are directed backwards as well as outwards. The femur is devoid of a *ligamentum teres*. The distal end of the fibula sends inwards a process which fits into a fossa situated upon the outer surface of the astragalus, giving rise to that kind of peg and socket ankle-joint which is peculiar to these animals.

A good deal of confusion prevails respecting the structure of the ankle-joint in the Sloths. Cuvier ('*Ossemens fossiles*,' t. viii. p. 143), writes of the Ai, or three-toed Sloth:

“ In the greater number of animals, the principal articu-

lation of the astragalus connects it with the tibia, by means of a more or less loose ginglymus, which allows the foot to be bent on the leg. But here the principal and superior facet of the astragalus is a conical fossa, into which the pointed extremity of the fibula penetrates, like a pivot. (See Pl. 208, fig. 2a.) The inner edge of this fossa turns against a very small facet, which occupies only a third of the lower head of the tibia. The result of this arrangement is that the foot turns on the leg, like a weathercock on its support, but that it cannot be flexed. It further follows that the plane of the sole of the foot* is almost vertical when the leg is so, and that the animal can only place the plantar surface of its foot on the ground by spreading out the leg so as to make it almost horizontal."

Meckel, † has already justly remonstrated against Cuvier's assertion that only abduction and adduction are possible to the pes of the Ai, affirming that it is capable of flexion and extension, though only to a limited extent. A. Wagner follows Meckel, but Rapp ('Edentaten,' p. 46) adopts Cuvier's statement in its fulness: "Extension and flexion of the foot cannot take place, but only abduction and adduction." However, it is easy to demonstrate on the uninjured dead animal, or still better, on the limb from which the muscles have been removed, while the ligaments have been left intact, that the pes of the three-toed Sloth is capable of extensive motion in three directions; 1st, in abduction and adduction; a movement in azimuth, when the leg is vertical; 2ndly, in flexion and extension; a more extensive movement in altitude, under the same circumstances; and 3rdly, in rotation upon its own axis, by means of which the sole can be moved through 90° from a position perpendicular to the axis of the leg to one parallel with it.

The anatomical arrangements upon which the execution of these movements depend are the following. The astraga-

* Cuvier's words are: "Il en résulte encore que le plan, le corps du pied, est presque vertical quand la jambe l'est."

† 'System der vergleichenden Anatomie,' 2te Theil., 2te Abtheilung, p. 457.

lus presents two facets to the bones of the leg, one of which (when the pes is in the position usual in other quadrupeds) looks inwards and upwards, while the other looks outwards and upwards. The former, convex from before backwards, as well as from side to side, is by no means a mere rim, though it is not so wide as the other. It is the proper proximal surface of the astragalus, and articulates with the tibia. The other surface is excavated by a deep conical pit. Into this is received a correspondingly conical process of the distal end of the fibula, which is directed from above and without, downwards and inwards—not vertically, therefore, but very obliquely. Hence, even if the pivot fitted its socket quite accurately, there would still be abundant opportunity for flexion and extension, though the movement of the pes would be obliquely inwards, as well as upwards, in the former case; and obliquely outwards, as well as downwards, in the latter. But the socket fits the pivot loosely, and hence, as experiment demonstrates, the movement of the pes in flexion and extension is but very slightly oblique.

The true movement of abduction and adduction is so much less extensive than the movement in flexion and extension, because it is checked by the short and strong internal and external lateral ligaments of the ankle-joint.

With respect to the rotation of the foot on its own axis—it is to be observed, in the first place, that the *calcaneum*, *cuboides*, *naviculare*, the three *cuneiformia*, the three complete and the three rudimentary metatarsals, and the three basal phalanges of digits *ii.*, *iii.*, and *iv.*, are ankylosed together into one bony mass; while, as in the manus, there is hardly any motion between the basal and the middle phalanges. Practically, in fact, the only bones of the pes which are movable upon one another are: 1. The distal phalanges, which have a movement of extension and flexion through 180° upon the middle phalanges. 2. The tarsophalangeal synostosis above described is freely movable on the astragalus; and the joint is disposed in such a manner as to allow the sole of the foot to be rotated from the

plantigrade position in which it is perpendicular to the axis of the leg, to the scansorial position, in which it lies parallel with the axis of the leg. It may be doubted, however, whether the former position can be given to the sole by the living animal. The *tibialis anticus* and the *extensor hallucis longus* are extremely strong muscles, and have no efficient antagonists; so that their tonic contraction must pull the navicular metatarsal tuberosity into which they are inserted as far upwards as it will go, causing the tarso-phalangeal synostosis to rotate upon the astragalus, and thus obliging the sole of the foot to look inwards.

In the two-toed Sloth, or Unau (*Choloepus*), the general structure of the ankle-joint is the same, but the fossa of the astragalus looks almost directly outwards, and the pivot of the fibula is more nearly horizontal, when the leg is vertical. The tibial facet of the astragalus looks directly upwards. Hence, the movement of the pes is more exclusively one of flexion and extension than in the Ai. No ankylosis of the tarsal, metatarsal, and phalangeal bones occurs, but the rotation of the distal moiety of the tarsus upon the astragalus is much more complete and permanent than in the Ai. The calcaneum is twisted round under the astragalus, in such a manner that its proper external face becomes inferior, while the articular surface for the cuboid is not only below, but is partially internal to, the navicular facet of the astragalus. As a result of this position of the cuboid, the outer metatarsals, which it supports, are placed directly beneath the inner ones, and the pes rests absolutely upon its outer edge, the plane of the sole being vertical.

The Sloths, it thus appears, are naturally club-footed; but neither in the Ai, nor in the Unau, does this depend in any way on the structure of the ankle-joint. On the contrary, it results, in the Unau, from the manner in which the *calcaneum* and *naviculare* articulate with the astragalus; and, in the Ai, from the action of the muscles on the tarso-phalangeal synostosis. Neither in the Ai, nor the Unau, is there anything to interfere with free flexion and extension of the pes.

The teeth are five in number on each side above, and four below, and become sharpened by mutual attrition into a chisel-like form. The stomach is remarkably complex.

The *Gravigrada* are, for the most part, like the Sloths, South American forms, but they are entirely extinct; and while, in most respects, they resemble the Sloths, in others they present an approximation to Ant-eaters.

The jugal arch may be complete or incomplete. The articular surfaces of the dorsal vertebræ are sometimes complicated in a manner similar to that observed in the Ant-eaters. The tail is very long and strong. The limbs are short and sub-equal, while the fore foot has the ulnar digit imperfect, as in the Ant-eaters. The fibula has no inward process, and the astragalus is consequently devoid of any fossa upon its outer surface. But another kind of peg and socket ankle-joint is produced by the interlocking of the surfaces of the tibia and of the astragalus.

The great extinct animals, *Megatherium*, *Mylodon*, *Megalonyx*, &c., the remains of which have been found almost wholly in later tertiary deposits of America, belong to this group.

2. The *Entomophaga*.—In this group of *Edentata* the zygoma sends down no process from its lateral region, although, in some rare cases, the anterior part of the arch has a descending prolongation. The acromion and the coracoid do not become united. The scaphoid and the trapezium remain distinct; and the sole of the hind foot rests upon the ground by a greater or lesser extent of its whole surface, and not merely by its outer edge.

The insectivorous edentates are divisible into four groups—*a.* the *Mutica*, *b.* the *Squamata*, *c.* the *Tubulidentata*, and *d.* the *Loricata*.

a. The group of the *Mutica* contains the genera *Myrmecophaga* and *Cyclothurus*, the Ant-eaters of South America. The bodies of these animals are covered with hair, and they are provided with very long tails, which are sometimes prehensile. The skull is greatly elongated, and the small pre-

maxillæ are but loosely connected with it. The jugal arch is incomplete. In *Myrmecophaga*, the pterygoids, which are very long, stretch back to behind the level of the tympanic bullæ, with the whole inner edges of which they are united either by bone or by membrane; and as, at the same time, they unite in the middle line, the roof of the palate is greatly prolonged, and the posterior nares are bounded below and at the sides, by the pterygoid bones. This arrangement is to be found in no other Mammals, except some *Cetacea*, nor in any other *Vertebrata*, except the Crocodiles. The mandible is very slender, the ascending ramus, coronoid process, and angle of the jaw, being obsolete. The articular surface of the condyle is flat. The hyoid is placed far back beneath the posterior cervical vertebræ, and is connected with the skull only by muscles. The thyroid and the cricoid cartilages are ossified. The dorso-lumbar vertebræ are complicated by the presence of accessory articular processes. Well-developed clavicles are present in the climbing *Cyclothurus didactylus*, but they are incomplete, or absent, in the other species. In the manus, the outer digit, or digits, are devoid of claws, and the weight of the body, when the animal walks, is supported upon its outer edge, which is frequently thick and callous. The pes has five digits, each provided with a strong nail, and the sole rests upon the ground.

The tongue is extraordinarily long and protractile; it is not connected to the hyoid by the ordinary *hyo-glossus* muscles; but long muscles, which are attached to the sternum (*sternoglossi*), retract it, while it is protracted by the *genio-glossi* and *stylo-hyoidei*.

Immense submaxillary glands extend back over the thorax, and cover the tongue with a viscid secretion, when it is thrust into the nests of the ants, upon which the *Myrmecophaga* preys. The insects, entangled by thousands in this substitute for birdlime, are then dragged back into the mouth of the Ant-eater, and swallowed. The pyloric portion of the stomach is so exceedingly thick and muscular as to be comparable to a gizzard. The brain presents

numerous convolutions, and has a large corpus callosum. The anterior commissure is also remarkably large. In the female, the uterus is simple, but has a double *os uteri*. The placenta is said to be discoidal in form in *Myrmecophaga didactyla*.

b. The group of the *Squamata* contains the single genus *Manis*, species of which are found both in Africa and Southern Asia. In these singular animals, the body is covered with overlapping, horny scales, and they have the power of rolling up like hedgehogs. In walking, the long claws of the fore foot are bent under, so that their dorsal surfaces rest upon the ground, while the weight of the hinder part of the body is thrown upon the flat soles of the hind feet.

The skull is elongated, the premaxilla is small, and the zygoma usually incomplete. The pterygoids are much elongated and extend backwards beyond the bullate tympanic bones, but they do not unite in the middle line. The mandible has no ascending ramus, and its condyle is flat. Air passages in the walls of the skull place one tympanum in communication with the other and extend into the squamosal bone. There are no clavicles. The "xiphoid" extremity of the sternum is large, and may be produced into two long cornua, as in Lizards. The mouth is toothless.

The large salivary glands extend on to the thorax. The stomach is divided into a thin-walled cardiac sac, lined by a dense epithelium, and a thick muscular pyloric portion. It is always found to contain numerous stones. The placenta appears to be diffuse and non-deciduate.

c. The *Tubulidentata* are also represented only by a single genus, *Orycteropus*, which is a native of South Africa. The body is hairy, provided with thoracic and inguinal teats, and the ears are long, not short or rudimentary, as in the preceding genera. In both the fore and the hind limbs, the foot rests evenly upon the ground and mainly upon the plantar surfaces of the strong claws. The fore foot has only four digits, in consequence of the absence of the pollex, while the hind foot is pentadactyle.

The skull has a complete zygoma and well-developed pre-maxillæ. The lachrymal bone is large, and the lachrymal foramen is situated upon the face. The tympanic bone is annular, and the periotic mass so large, and enters so much into the lateral walls of the skull, as to remind one of its proportions in the *Sauropsida*. The mandible has an ascending ramus. The clavicles are complete.

The jaws are provided with teeth, the substance of which is traversed by a great number of parallel vertical canals. These teeth are rootless molars, and the greatest number which has been observed is $\frac{8 \cdot 8}{6 \cdot 6}$, but the small anterior ones fall out, reducing them to $\frac{5 \cdot 5}{4 \cdot 4}$. The hindermost, and the small anterior ones, are simple cylinders, but the middle teeth present a longitudinal groove, on each side.

The submaxillary glands are very large. The stomach is divided into a right and a left portion; the former having very thick and muscular walls. The intestine has a cœcum. It is stated that the *ductus arteriosus* long remains open.

The two uteri open separately into the vagina. The placenta is deciduate and discoidal.

d. In the *Loricata*, the dorsal region of the body is covered by a carapace, composed of epidermal scales, and of suturally united quadrate, or polygonal, scutes, which are dermal ossifications, so that the whole structure is strictly comparable to the dorsal shield of a crocodile. These are the only mammals in which such scutes exist. When fully developed, the dorsal armour of one of these animals presents five distinct shields, the edges of which permit of a certain amount of motion between them. One of these covers the head, and is called *cephalic*; another, *nuchal*, protects the back of the neck; a third, *scapular*, covers the shoulders like a great cape; a fourth, usually consisting of a number of free and movable segments, covers the posterior dorsal and lumbar region, as the *thoraco-abdominal* shield; and the fifth, the *pelvic*, is attached by its

deeper surface to the ilia and ischia, and arches over the rump like a half dome. The tail may further be invested by a series of incomplete bony rings and scattered scales; and scutes are distributed over the limbs. In one genus, *Chlamydophorus*, the scutes are developed only in the pelvic region.

In the skull the premaxillæ are well developed, and the zygoma is complete. The mandibular ramus usually has a well-developed ascending portion and coronoid process. Clavicles are present. The fore and the hind feet rest upon the ground evenly, and indeed the hind limbs are usually plantigrade, or nearly so; but, in the singular genus *Tolypeutes*, the fore foot is supported upon the extremities of the long nails. The pollex is always present in the fore foot, but the fifth digit sometimes becomes rudimentary. There are always five toes in the hind foot.

In the genus *Euphractes*, each premaxilla contains a single tooth, which, consequently, is an incisor.

This group contains two divisions, the *Dasypodidæ* and the *Glyptodontidæ*; both are South American, but the former is chiefly composed of living animals, while the latter only contains an extinct genus.

The *Dasypodidæ* are what are commonly known by the name of *Armadillos*. In this division the thoraco-abdominal shield, when present, as it is in all the genera except *Chlamydophorus*, consists of, at fewest, three, and, at most thirteen, transverse movable zones of scutes.

In the skull, the ends of the nasal bones project beyond the level of the premaxillæ, so that the nasal aperture looks more or less downwards. The premaxillæ have a considerable size, and articulate largely with the nasals. The anterior part of the jugal arch offers, at most, a rudimentary downward prolongation. The mandibular symphysis has but a moderate length, and the posterior alveoli of the mandibles do not extend along the inner face of the ascending portion of the ramus of the jaw.

The teeth of the upper and lower jaws alternate, and hence their grinding surfaces wear down into ridges.

The odontoid vertebra is ankylosed with a greater or smaller number of its successors. The cervical vertebræ which follow these have peculiar accessory articular surfaces; and the hinder dorsal and the lumbar vertebræ are also provided with accessory articular facets and processes. A number of the anterior caudal vertebræ are always ankylosed with one another, and with the true sacrals, to form the long sacrum; and the transverse processes of some of these caudal vertebræ abut against the inner surfaces of the ischia, and become ankylosed therewith.

The first rib is broad and flattened, and the anterior piece of the sternum is expanded. The succeeding vertebral ribs are connected by ossified sternal ribs with the sternum, and these are articulated, not only with the sternum, but with one another.

In the carpus, the cuneiform bone bends round the unciform, and articulates with the fifth metacarpal, when that bone is present. The ungual phalanges of the manus are long and pointed. The femur has a third trochanter, and the four inner metatarsals are much longer than they are broad.

The division of the *Glyptodontidæ* contains the single genus *Glyptodon*, which is essentially a large armadillo; but it departs, in some respects, not only from all these animals, but from all other *Mammalia*, and even stands alone among the *Vertebrata*.

The carapace covers the whole body, but presents no movable thoraco-abdominal zones, inasmuch as it consists of polygonal plates firmly united together, and fringed by a margin of scutes with raised conical surfaces.

The nasal bones are short and broad, and their free ends do not project so far as the premaxillæ; whence the anterior nasal aperture looks slightly upwards as well as forwards. The premaxillæ, however, are very small bones, and if they unite with the nasals at all, do so for a very short distance. The anterior portion of the jugal arch gives off a great downward process. The mandibular symphysis is very long, and the posterior alveoli of the man-

dible are situated upon the inner face of the very high perpendicular part of the ramus. The teeth are trilobed, two deep grooves excavating their inner and their outer surfaces. And, as the crowns of those of each jaw are placed opposite each other, they are worn flat.

The last cervical and the anterior dorsal vertebræ are ankylosed together into a single "tri-vertebral" bone, which moves by a hinge joint upon the third dorsal. This and the succeeding dorso-lumbar vertebræ are immovably united, and, for the most part, ankylosed, together. The head of the first rib is engaged in the socket furnished to it by the tri-vertebral bone in such a manner as to be immovable, and the rib is not flat, but rounded and columnar.

In the carpus, the cuneiform bone articulates with the fourth, as well as with the fifth metacarpal, the latter bone being entirely supported by the cuneiform. The metacarpals and phalanges are all very short and broad. The pollex is rudimentary, while the fifth digit is fully developed.

The supra-condyloid ridge of the femur is not distinct from the third trochanter, even if the latter can be said to exist at all. The metatarsal bones are as broad as they are long, or broader; and, as in the fore foot, the majority of the phalanges are comparatively short and truncated.

THE NON-DECIDUATE MAMMALIA.—I. UNGULATA.—A large number of the non-deciduate Mammalia are conveniently comprehended under the title of the *Ungulata*, though it may be open to question whether the group thus named represents a single order, or more than one.

In all the *Ungulata* the placenta is either diffuse, that is to say, the villi are scattered evenly over the surface of the chorion; or it is cotyledonary, in which latter case, the villi are accumulated in distinct patches on the chorion. These patches are called *cotyledons*.

All *Ungulata* have milk teeth, succeeded vertically by teeth of the permanent set. The teeth consist of enamel, dentine and cement, and the grinders have broad crowns, with tuberculated, ridged, or folded enamel.

Clavicles are never present. The limbs have not more than four complete digits. The unguis phalanges are clothed in obtuse horny sheaths, which are commonly very thick and go by the name of *hoofs*. Upon these the weight of these quadrupeds is usually supported, whence they have been called *unguligrade*. Some few, however, rest the weight of the body upon the under surfaces of the phalanges, or are *digitigrade*. The metacarpal and metatarsal bones are elongated, and take a vertical, or much inclined position.

In the female, the mammæ are either few in number, when they are inguinal in position; or numerous, when they are disposed in two rows along the abdomen.

The intestine is very generally provided with a cœcum of considerable size.

The cerebral hemispheres always exhibit convolutions, which are usually very numerous; and, when the brain is viewed from above, the surface of the cerebellum is largely uncovered.

The *Ungulata* are divisible into the *Perissodactyla* and the *Artiodactyla*, though it is probable that the attempt to define these groups will break down with the increase of our knowledge of fossil forms.

1. In the *Perissodactyla*, the number of the dorso-lumbar vertebræ is not fewer than twenty-two. The third digit of each foot is symmetrical* in itself, and the toes of the hind foot are odd in number (Fig. 93, B). The femur has a third trochanter (Fig. 100-³). The two facets upon the front face of the astragalus are very unequal; the less articulating with the cuboid bone.

In the skull, the tympanic bone is small; and, as in sundry other mammals, the root of the pterygoid process of the sphenoid is perforated by an aperture or canal.

The posterior premolar teeth are, generally, very like the molars. The stomach is simple, and the cœcum exceedingly large.

The teats are inguinal, or situated in the groin. When

* Or at least very nearly so.

the head is provided with horny appendages, they are entirely epidermal and devoid of a bony core; and they are placed in the middle line of the skull.

Fig. 93.

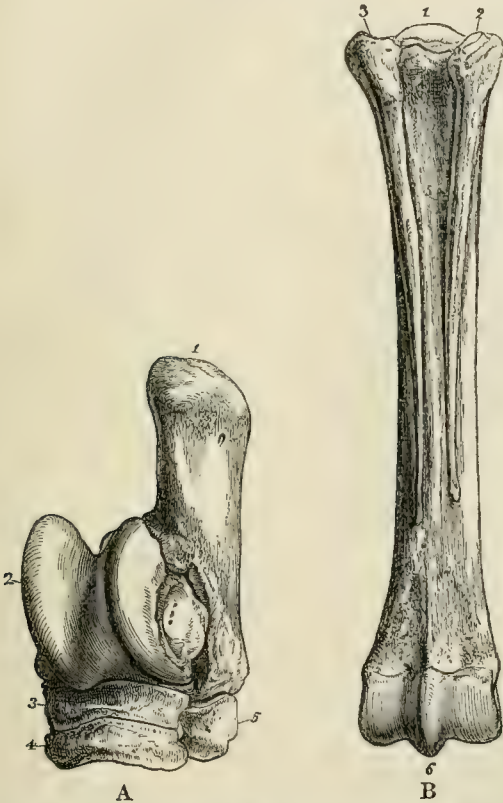


Fig. 93.—A, Front aspect of the left tarsus of a Horse. 1. Calcaneum. 2. Astragalus. 3. Naviculare. 4. Ectocuneiform. 5. Cuboides. B, Posterior aspect of the left metatarsus of a Horse. 1. The metatarsal of the third digit. 2, 3. The metatarsals of the rudimentary digits.

The *Perissodactyla* consist of the existing families *Equidæ*, *Rhinocerotidæ*, and *Tapiridæ*, and of the extinct *Palæotheridæ* and *Macrauchenidæ*.

a. The *Equidæ*, or Horses and Asses, have one toe on

each foot—the third—much longer and larger than the rest. The latter are represented only by their metacarpal or metatarsal bones, the inner and outer toes being absent, or represented by mere ossicles (as rudiments of their metacarpals or metatarsals) in all existing *Equidæ*. But, in the extinct *Hipparion*, the second and fourth digits were complete, though small and like dew claws; while the miocene *Anchitherium*, which most nearly approaches the *Palæotheridæ*, has the lateral toes much larger, and taking their share in supporting the weight of the body.

See page 345.

Fig. 94. — A, right fore foot of a Horse. 1. Radius. 2. Groove in the front face of the radius. 3. Saphoïdes. 4. Lunare. 5. Cuneiforme. 6. Pisiforme. 7. Magnum. 8. Unciforme. 9. Metacarpale, *iii*. 10. Metacarpale, *iv*. 11. Sesamoid bones in the ligaments at the back of the metacarpo-phalangeal articulation. 12. Proximal phalanx (fetter bone). 13. Middle phalanx (coronary). 15. Distal phalanx (coffin bone). 14. Sesamoid bone in the tendon of the *flexor perforans* (called "navicular" by Veterinarians).

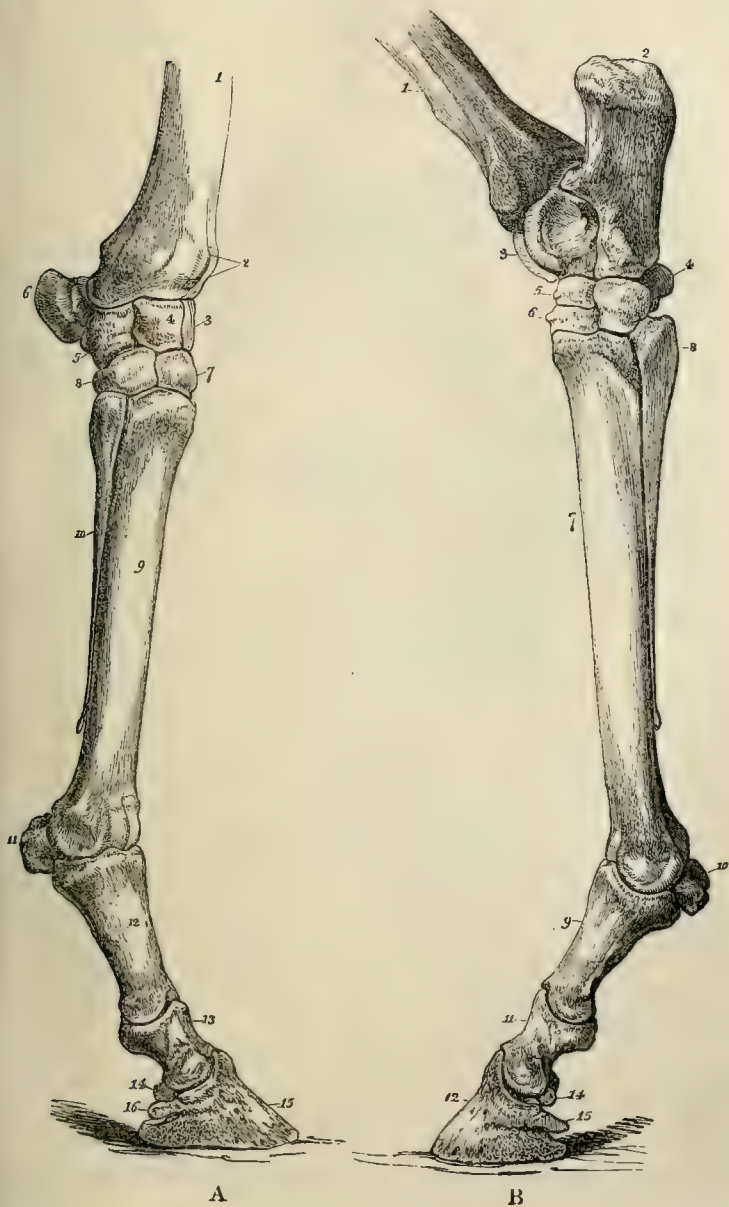
B, left hind foot of a Horse. 1. Tibia. 2. Calcaneum. 3. Astragalus. 4. Cuboid. 5. Navicular, or scaphoid. 6. Ectocuneiform. 7. Metatarsale, *iii*. 8. Metatarsale, *iv*. 9, 11, 12. Phalanges. 10, 14. Sesamoids.

The dental formula is $i. \frac{3 \cdot 3}{3 \cdot 3} c. \frac{1 \cdot 1}{1 \cdot 1} p.m. \frac{4 \cdot 4}{4 \cdot 4} m. \frac{3 \cdot 3}{3 \cdot 3}$. The tooth here counted as the first premolar may be a milk tooth, as it appears to have neither predecessor nor successor, and soon disappears.

The molar teeth present an outer wall, which is bicrescentic in transverse section; and two inner ridges, which are curved more or less inwards and backwards, and correspond respectively with the anterior and the posterior crescents of the outer wall. The valleys may be more or less completely filled up with cement, which also coats the tooth. The incisors are similar in form in each jaw, and in *Equus* and *Hipparion* their crowns present a wide and deep median cavity, formed by a fold of the enamel.

These are the distinctive characters of the *Equidæ*. It may be useful to add some special details respecting the anatomy of the Horse as a familiar example of the perisodactyle group.

Fig. 94.



The Horse has seven cervical vertebræ, twenty-four dorso-lumbar (eighteen or nineteen of which are dorsal), five sacral, and about seventeen caudal vertebræ. The

Fig. 95.

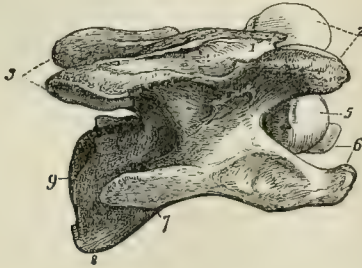


Fig. 95.—A cervical vertebra of a Horse. 1. The rudimentary spine. 2, 3. The pre- and post-zygapophyses. 5. The convex anterior face of the centrum. 9. Its concave posterior face. 6, 7. The transverse processes and rudimentary ribs.

atlas has very wide lateral processes, the faces of which look obliquely downwards and forwards, and upwards and backwards. The centra of the other cervical vertebræ are much elongated, strongly convex in front, and correspondingly concave behind. The neural spines are obsolete in all but the seventh. The *ligamentum nuchæ* is a great sheet of elastic tissue, which extends from the spines of the anterior dorsal vertebræ to the occiput, and is fixed, below, into the neural arches of the cervical vertebræ.

In the dorsal region, the opisthocœlous character of the centra of the vertebræ gradually diminishes, though the anterior face of the centrum of the last lumbar is still distinctly convex. The spines of these vertebræ increase in length to the fourth or fifth. The spine of the sixteenth is vertical, those in front inclining backwards, and those behind a little forwards.

In none of these vertebræ do the prezygapophyses bend round the postzygapophyses of the vertebra in front, as is often the case in the *Artiodactyla*. The transverse processes of the penultimate, and of the last, lumbar vertebræ present concave facets upon their posterior margins, which

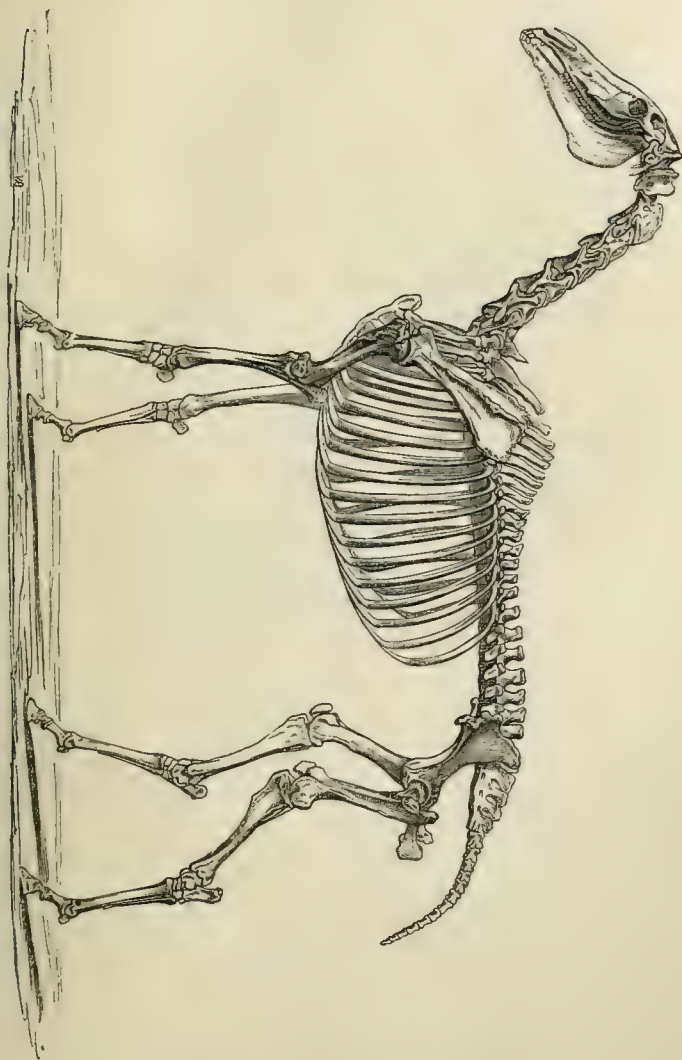


Fig. 96.—The skeleton of the Horse.

articulate with convex facets developed upon the anterior margins of the last lumbar and first sacral vertebræ respectively.

In the skull, the plane of the supra-occipital is inclined upwards and forwards, and gives rise to the middle part of a transverse ridge which is continued at the sides into the squamosal. The ridges which limit the origins of the temporal muscles above, unite in the middle line posteriorly, and thus produce a low sagittal crest. The orbit is bounded behind by the united postorbital processes of the frontal and the jugal. The lachrymal aperture lies in the orbit. The nasal bones unite, for a short distance only, with the premaxilla. There is no prænasal bone. The posterior margin of the palate is opposite the penultimate molar tooth. The glenoidal surface is transversely elongated and convex from before backwards.

The tympanic bulla is not very large, and is rugose inferiorly. It is not ankylosed with the surrounding bones. The post-tympanic process of the squamosal does not approach the postglenoidal process of the same bone, below the *meatus auditorius*.

The proper mastoid process is distinct, but short. There is a long and strong paramastoid developed from the ex-occipital.

The rami of the mandible are ankylosed at the symphysis. The perpendicular part of each ramus is long, the condyle transverse and convex from before backwards, and the narrow coronoid process rises far above the level of the condyle. In a longitudinal section of the skull the cerebral chamber lies almost altogether in front of that for the cerebellum.

The structure of the limbs of the Horse is such as might be expected from its pre-eminent cursorial powers.

That excessive development of the epidermis which gives rise to a *nail* takes place, in the Horse, not only upon the dorsal surface of the terminal joint of the digit, but upon its ventral surface and sides, and thus produces a *hoof*.

The animal is supported by these greatly-developed nails, and hence is said to be *unguligrade*. The long axes of its

phalanges are greatly inclined to the surface upon which it stands, while those of the metacarpals and metatarsals are

Fig. 97.

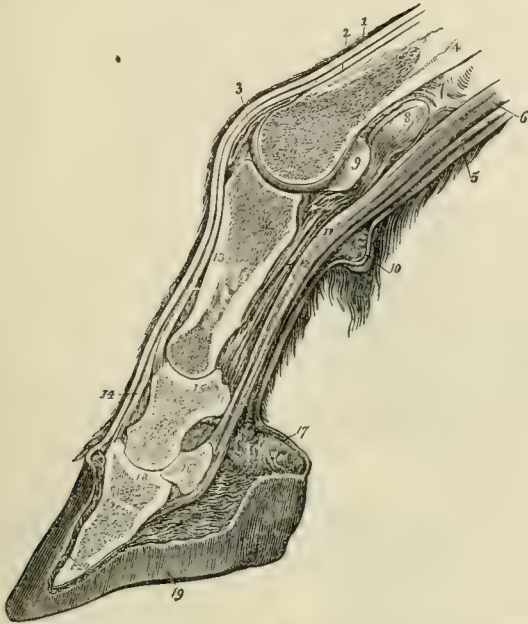

Fig. 97.—Longitudinal median section of the foot of a Horse. 13, 14, 18. The three phalanges. 16. The navicular sesamoid. 5. The flexor perforatus. 6. The flexor perforans. 19. The hoof.

perpendicular and greatly elongated. The wrist of the Horse thus comes to occupy the middle of the length of its fore-leg, and constitutes what is improperly called the “knee.” The heel is similarly raised to the middle of the hind leg, and is termed the “hock.” The forearm and the leg are free, but their motions are almost restricted to an antero-posterior plane. The fore arm is fixed in the prone position. The arm and thigh are closely applied to the sides of the body and inclosed in the common integument, so as to be capable of very little proper motion. At the same time, the axis of the humerus is inclined obliquely backwards and downwards, at right angles with the long axis

of the scapula; and that of the femur obliquely forwards and downwards at right angles with that of the *os innominatum*; and the long axes of both these bones make a great angle with those of the fore-arm and leg respectively. Each limb thus forms a sort of double C spring, upon the top of which the weight of the body is supported—in the hind limbs by means of the solid connection of the ilia with the sacrum; in the fore limbs, by the great muscular slings formed by the *serratus magnus* and the *levator anguli scapulae*.

Fig. 98.

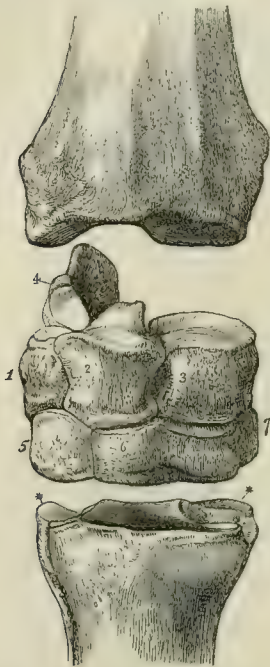


Fig. 98.—Front view of the right carpus of a Horse.
 1. Cuneiforme. 2. Lunare.
 3. Scaphöides. 4. Pisiforme.
 5. Unciforme. 6. Magnum.
 7. Trapezoides.

The scapula is long and narrow; the low spine has no acromion; the coracoid process is small, and there is no clavicle.

The head of the humerus looks backwards, and the distal articular surface of the bone is completely ginglymoid. The two bones of the antibrachium are ankylosed; the shaft of the ulna becomes exceedingly slender, and its small distal end is distinguishable only with difficulty. The articular surface for the carpal bones is, therefore, almost wholly furnished by the radius. There are seven carpal bones, the trapezium being obsolete. A line prolonging the axis of the third metacarpal and that of the *os magnum* does not pass through that of the *lunare*, but corresponds more nearly with the junction between *scaphöides* and *lunare*.

The pollex and the fifth digit are suppressed, or represented only by minute nodules of bone, and the only complete digit is the third; the second and the fourth being represented

only by the splint-like metacarpal bones. The third metacarpal, which is somewhat flattened from before backwards, is nearly symmetrical in itself. Careful observation, however, shows the inner moiety to be rather the broader.

There are two large sesamoid bones (the greater sesamoids) developed in the ligaments which connect the metacarpal with the basal phalanx; and one transversely elongated sesamoid gives attachment to the tendon of the perforating flexor, and lies upon the ventral aspect of the joint between the middle and the distal phalanx.

The *ossa innominata* are elongated, and their long axes, on the length of which depends the proportional size of the "quarter" of a Horse, form an acute angle with the spine. The crests of the ilia are wide and directed transversely, and the symphysis pubis is very long.

Fig. 99.

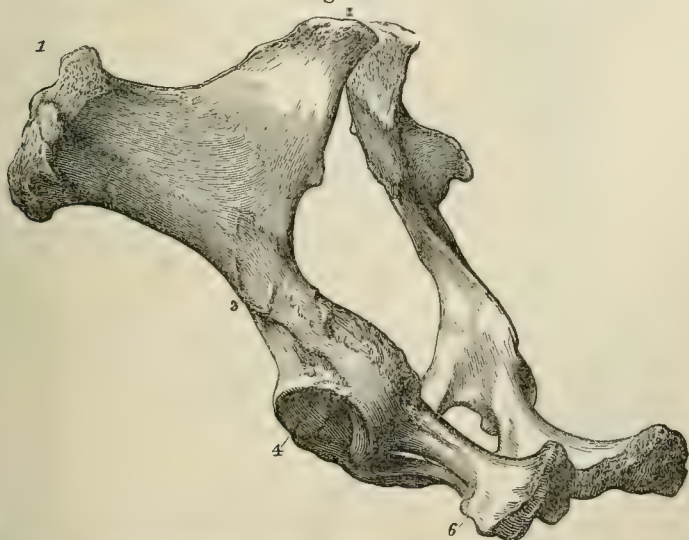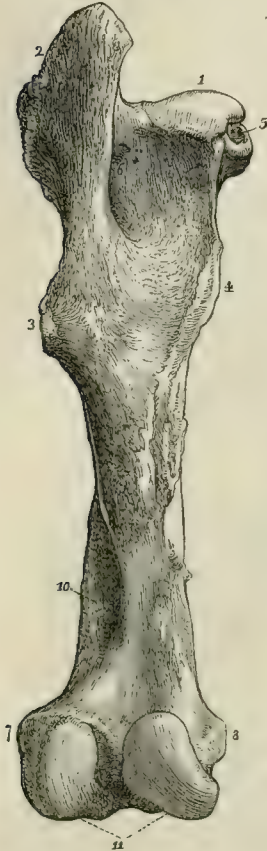


Fig. 99.—The ossa innominata of a Horse viewed from the left side and behind. 1. The crest of the ilium. 2. The surface by which it articulates with the sacrum. 4. The acetabulum. 6. The ischium.

The femur has a large third trochanter (3, Fig. 100), into which the *glutæus maximus* is inserted. Its head presents a

deep pit for the round ligament, and there is a peculiar and very characteristic fossa ⁽¹⁰⁾ on the inner and posterior face of the distal moiety of the bone.

Fig. 100.



A.

Fig. 100.—A, Left femur of a Horse, posterior view. 1. Head. 2. Great trochanter. 3. Third trochanter. 4. Lesser trochanter. 5. Pit for round ligament. 10. Fossa. 11. Condyles.

The proximal end of the fibula is reduced to a mere rudiment; its shaft is not represented by bone; and its distal end is ankylosed with the tibia, and has the appearance of being an external malleolar process of that bone. The distal end of the tibia presents two deep, obliquely-directed concavities, which correspond with the convexities of the astragalus.

There are six or seven tarsal bones, according as the ento- and meso-cuneiform bones remain distinct or become ankylosed. The astragalus (Fig. 93 A, 94 B) is extremely characteristic. It presents two convex ridges separated by a deep fossa, and directed obliquely from behind and within, forwards and outwards, to the tibia; and it has a nearly flat distal face, which articulates almost wholly with the naviculare, presenting only a very small facet to the cuboid.

The naviculare and the ecto-cuneiform are peculiarly broad and flattened in form (Fig. 93 A, 94 B).

The metatarsus and digits repeat the arrangements of the fore limb; but the principal metatarsal is more slender in its proportions,

and is flattened from side to side rather than from before backwards (Fig. 93 B, 94 B).

As might be expected, the principal peculiarities of the muscular system of the Horse are to be observed in the limbs.

The *serratus magnus* and the *levator anguli scapulæ* (which really form one muscle), together with a *sterno-scapularis*, form the great sling already mentioned, by which the weight of the fore part of the body is transmitted to the anterior extremities. The power of abduction is hardly needed by a purely cursorial animal; hence the deltoid is reduced to its scapular portion, which is very small. On the other hand, the pro- and re-tractors, the flexors and extensors, are well developed. The *supra-* and *infra-spinatus* are large. There is a great *cephalo-humeralis*, answering to the clavicular portions of the human sternomastoid and of the deltoid, which run into one another, in consequence of the total absence of the clavicle. The anterior portion of the sternomastoid is fixed to the mandible, and thus becomes "sternomaxillary."

The *latissimus dorsi* and *teres* muscles are very large, as are the flexors and extensors of the antibrachium.

The supinators and pronators are wanting; but there is a distinct *extensor minimi digiti*, the tendon of which unites with that of the *extensor communis*. Radial and ulnar extensors of the carpus are also present. The *flexor perforatus* has only a single tendon, which splits, and is attached, as usual, to the sides of the middle phalanx. The *flexor perforans* also has only a single tendon, which pierces the former, and is inserted into the lesser sesamoid and the distal phalanx.

The *interossei* of the third digit are represented only by the ligaments which connect the greater sesamoid bones with the metacarpal, and in which a few muscular fibres are sometimes found. There are said to be two others, one for each lateral metacarpal, and a *lumbricalis*.

In the hind limb, the femoral muscles are in the Horse the same as in Man, but enormously developed. There is

no *tibialis anticus*, *peronæus longus*, or *brevis*, nor any *tibialis posticus*.

The *extensor longus digitorum* has a head which arises from the external condyle of the femur; there is a simple *extensor brevis*.

The *flexor hallucis* and *flexor digitorum perforans* unite into the single perforating flexor tendon for the distal phalanx; while the perforated tendon is the termination of that of the *plantaris*, which passes over a pulley furnished by the calcaneum.

The deciduous or milk dentition of the Horse has the following formula: $d.i. \frac{3 \cdot 3}{3 \cdot 3}$ $d.c. \frac{1-1}{1-1}$ $d.m. \frac{4 \cdot 4}{4 \cdot 4}$. It is complete at birth, with the exception of the outer incisors, which appear before the foal is nine months old. The incisors have the same structure as in the adult. The canines and first deciduous molars are simple and very small, the canines being smaller than the molars. In the upper jaw, the other deciduous molars all have the same structure. The outer wall of the tooth is bent in such a manner as to present, from before backwards, two concave surfaces separated by a vertical ridge. From the anterior end, and from the middle, of this outer wall, two laminæ of the crown pass inwards and backwards, so as to be convex inwards and concave outwards, and thus to include two spaces between themselves and the outer wall. From the inner surface of the hinder part of each of these crescentic laminæ a vertical pillar is developed, and the inner surface of the pillar is grooved vertically. The outer wall, the laminæ, and the pillars are all formed of dentine and enamel, thickly coated with cement. The attrition which takes place during mastication wears down the free surfaces of all these parts, so as, in the long run, to lay bare a surface of dentine in the middle of each, surrounded by a band of enamel, and, outside this, by the cement with which the interspaces are filled. The band of enamel is simple and unplaited. The general pattern of the worn surface may be described as consisting, externally, of two longitudinal crescents, one behind the

other, and with their concavities turned outwards, which arise from the wear of the wall; internal to these, of two other crescents, partly transverse in direction, and connected by their anterior ends with the wall, which arise from the wear of the laminæ; and attached to the inner surface of these, two hour-glass-shaped surfaces, produced by the wear of the grooved pillars.

In the mandible, the structure of the molars and the resulting pattern are quite different. The outer wall presents two convex surfaces separated by a longitudinal depression, and thus reverses the conditions observable in the upper molars. The result of the wear of this is, necessarily, two crescents, the concavities of which are turned inwards. A vertical pillar, longitudinally grooved on its inner face, is developed on the inner face of the tooth at the junction of the anterior and posterior crescents, and gives rise to a deeply bifurcated surface when worn. A second smaller pillar appears in connection with the inner face of the posterior end of the outer wall.

Thus the grinding surface of the upper molars may be represented by four crescents with two inner pillars; and that of the lower molars by two crescents with two inner pillars. The upper crescents are concave outwards; the lower concave inwards; and by this arrangement, together with the unequal wear of the dentine, enamel, and cement, a permanently uneven triturating surface is secured.

As is the general rule among Mammals, the first permanent molar is the first permanent tooth which appears (unless the eruption of the inner incisor be contemporary with it), and it comes into place and use long before the deciduous molars are shed and replaced by the premolars. Hence, when the last premolar comes into place as a fresh and unworn tooth, the first molar, which lies next to it, is already considerably worn. This disparity of wear is maintained for a long time, and furnishes a very useful means of distinguishing the last premolar from the first molar in the adult, when, as in the Horse, the premolars and molars are very similar.

The first deciduous molar usually falls out when the first premolar appears, and is not replaced; but it is occasionally retained. All the other milk teeth have successors, and there are three permanent molars. Consequently the dental formula of the adult Horse is

$$i. \frac{3 \cdot 3}{3 \cdot 3} c. \frac{1-1}{1-1} pm. \frac{3 \cdot 3}{3 \cdot 3} m. \frac{3 \cdot 3}{3 \cdot 3} = 40.$$

The permanent canines are the last teeth to be fully developed, and, in the mare, they often do not make their appearance. The upper canines are distant from the outer incisors, while the lower canines are quite close to them. In both jaws there is a wide interval, or *diastema*, between the canines and the premolars.

The deep valley of the incisor teeth becomes filled up with masticated matter, and thus the dark "mark" is produced. As the incisors wear down, the mark changes its form in consequence of the differences in the transverse section of the valley at different points; and eventually, when the wear has extended beyond the bottom of the valley, it disappears. The presence or absence of the "mark" thus serves as an indication of age. The structure and patterns of the grinding surfaces of the permanent molars are essentially the same as those of the milk molars; but the enamel becomes more or less plaited; and, at an advanced period of life, the development of the long teeth is completed by the formation of roots. It is important to notice that the last molar of the Horse is not more complex in its structure than the other molars, and that the last milk molar is not more complex than the premolar which succeeds it.

The alimentary canal of the Horse is about eight times as long as the body. The stomach, simple in its form, presents a cardiac and a pyloric division, which are sharply distinguished by the dense epithelium which lines the inner surface of the former.

The cœcum is enormous, having fully twice the volume of the stomach. There is no gall-bladder. A cartilage is developed in the septum of the heart. There is no

Eustachian valve, and only one anterior cava remains. The aorta divides immediately after its origin into an anterior and a posterior trunk; the latter becomes the thoracic aorta; the former is the source of the arteries for the head and the anterior extremities, giving off first the left subclavian, and then as an "innominata" supplying the right subclavian and the carotids.

The trachea divides into only two bronchi, no accessory bronchus being given off to the right lung. In the brain the following points are worthy of notice. The medulla oblongata presents *corpora trapezoidea*. The flocculi do not project at the sides of the cerebellum, and the vermis and lobes of the cerebellum are unsymmetrically convoluted. The cerebral hemispheres are elongated and subcylindrical, and do not overlap the cerebellum when the brain is viewed from above. The sulci are very deep, and separate numerous gyri, upon the upper and outer surfaces of the hemispheres. The uncinat gyrus (or natiform protuberance) and the region which answers to the insula, are not hidden by the overlapping of the convolutions in the lateral aspect of the brain. The sylvian fissure is indicated. The corpus callosum is large, and the anterior commissure is of moderate size. The posterior cornu of the lateral ventricle is wanting.

Large air sacs are connected with the Eustachian tubes.

The testes pass into a scrotum, but the inguinal canal remains permanently open.

The prostate is single. Cowper's glands are present, and there is a large *uterus masculinus*. The large penis is sheltered within a prepuce and is retracted by a special muscle, which arises from the sacrum.

The uterus is divided into two cornua, and the vagina of the virgin mare is provided with a hymen. The period of gestation is eleven months. The yolk sac of the foetus is small and oval. The allantois spreads over the whole interior of the chorion and covers the amnion, which is vascular. The minute villi which it supplies with vessels are evenly scattered over the whole surface of the chorion.

The existing *Equidæ* are naturally restricted to Europe, Asia, and Africa; and are distinguished into the Horses, which have horny patches on the inner sides of both pairs of limbs—above the wrist in the fore limb and on the inner side of the metatarsus in the hind limb; and the Asses, which possess such callosities only on the fore limbs.

Fossil remains of *Equidæ* are abundant in the later tertiary deposits of Europe, Asia, and the Americas; but the group is not known to be represented earlier than the miocene, or later eocene, epoch.

The *Equidæ* are among the very few groups of *Mammalia*, the geological history of which is sufficiently well known, to prove that the existing forms have resulted from the gradual modification of very different ancestral types. The skeleton of the older pliocene and newer miocene *Hipparion* very closely resembles that of an Ass, or a moderate-sized Horse. There is a curious depression on the face in front of the orbit, somewhat like that which lodges the "larmier" of a stag (traces of which are observable in some of the older species of *Equus*); otherwise the cranium is altogether like that of a Horse. Again, the shaft of the ulna is very slender, but it is larger than in the Horse, and is distinctly traceable throughout its whole length although firmly ankylosed with the radius. The distal end of the fibula is so completely ankylosed with the tibia, that, as in the Horse, it is difficult to discern any trace of the primitive separation of the bones. But, as has been already mentioned, each limb possesses three complete toes—one strong, median, and provided with a large hoof, while the two lateral toes are so small that they do not extend beyond the fetlock joint. In the fore limb, rudiments of the first and fifth toes have been found.

The teeth are exceedingly like those of the Horse, but the crowns of the molars are shorter; and, in the upper jaw, that which, in the true Horses, is a large fold of the inner face of the tooth becomes a detached pillar. The smaller plications of the enamel are also more numerous, close-set, and complicated. On the outer face of the lower milk

molars there is a column such as exists in the Stags. Of this a rudiment exists, as a fold, in the corresponding teeth of the existing Horse.

In the genus *Anchitherium*, all the known remains of which are of older miocene (and, perhaps, newer eocene) age, the skeleton in general is still extraordinarily like that of a Horse. The skull, however, is smaller in proportion than in the Horse, and the jaws are more slender. The hindermost molar tooth is situated farther back under the orbit, and the orbit itself is not completely encircled by bone, as it is in the Horses and Hipparions.

The shaft of the ulna is stouter than in *Hipparion*, and is less closely united with the radius. The fibula appears, at any rate in some cases, to have been a complete though slender bone, the distal end of which is still closely united with the tibia, though much more distinct than in the Hipparions and the Horses. In some specimens, however, the middle of the shaft seems to have been incompletely ossified. Not only are there three toes in each foot, as in *Hipparion*, but the inner and the outer toes are so large that they must have rested upon the ground. Thus, so far as the limbs are concerned, the *Anchitherium* is just such a step beyond the *Hipparion*, as the *Hipparion* is beyond the Horse, in the direction of a less specialized quadruped. The teeth are still more divergent from the Equine type. The incisors are smaller in proportion, and their crowns lack the peculiar pit which characterizes those of *Equus* and *Hipparion*. The first grinder is proportionately much larger, especially in the upper jaw, and like the other six has a short crown and no thick coat of cement. The pattern of their crowns is wonderfully simplified. The fore and hind ridges run with but a slight obliquity across the crown, and the pillars are little more than enlargements of the ridges, while in the lower jaw these pillars have almost disappeared. But the foremost of the six principal grinders is still somewhat larger than the rest, and the posterior lobe of the last lower molar is small, as in the other *Equidae*.

In all those respects in which *Anchitherium* departs from the modern Equine type, it approaches that of the extinct *Palæotheria*; and this is so much the case that Cuvier considered the remains of the *Anchitherium* with which he was acquainted to be those of a species of *Palæotherium*.

b. In the *Rhinocerotidæ* the second, third, and fourth toes are nearly equally developed in both the fore and the hind feet.

The dental formula is $i. \frac{1.1}{1.1}$ or $i. \frac{0.0}{0.0}$ $c. \frac{0.0}{0.0}$ $p.m. \frac{4.4}{4.4}$ $m. \frac{3.3}{3.3}$.

But the teeth differ from those of the Horse in many other respects besides the number of the incisors and the absence of canines. Thus, the upper incisors differ greatly in form from those which are situated in the lower jaw; and, in some species, incisors are absent. Their crowns are not folded as in the Horse. The peculiarities of the grinding teeth will be mentioned below.

The skin is very thick and may be converted into a jointed armour; the hair is scanty. The upper lip is much produced and is very flexible. In some species one, or sometimes two, horns are attached in the middle line to the nasal or frontal bones. But these horns are formed, as it were, by agglomeration of a great number of hair-like shafts.

The distal phalanges of the tridactyle feet of the Rhinoceros are invested by small hoofs; but these do not entirely support the weight of the body, which rests, in great measure, upon a large callous pad developed from the under face of the metacarpal and metatarsal regions; these are much shorter than in the Horse.

The dorsolumbar vertebræ are twenty-two or twenty-three, of which twenty are dorsal. There are four sacral and twenty-two caudal. The cervical vertebræ, as in the Horse, are strongly opisthocœlous, and the transverse processes of the last lumbar articulate with those of the penultimate lumbar and with the sacrum.

The skull differs from that of the Horse in the absence of any frontal or zygomatic processes, in consequence of

which the orbit and temporal fossa form one cavity. The nasals are immense, and are separated from the premaxillæ by a wide extent of the maxilla on each side. The premaxillæ are relatively small, and reduced to little more than their palatine portions. The glenoidal surface of the mandible is transverse and convex. The squamosal sends down an immense post-glenoidal process, which is longer than either the post-tympanic or the paramastoid. It unites with the post-tympanic to form a kind of false auditory meatus, in the absence of any proper ossified canal of that kind. The periotic and the tympanic bones are ankylosed, the tympanic being a mere irregular hoop of bone. The *pars mastoidea* is completely hidden by the junction of the short post-tympanic with the long paramastoid. The hinder margin of the bony palate is opposite the middle of the antepenultimate molar.

The mandibular condyle is transverse and convex. The perpendicular portion of the ramus is large, and the coronoid process ascends slightly above the condyle. In a vertical and longitudinal section of the skull, the form of the cerebral cavity is seen to be similar to that of the Horse. The inner and outer tables of the bony roof of the skull are separated by great air-cavities.

The spine of the scapula has no acromion, but gives off a strong recurved process from the middle of its length.

The radius and ulna are complete, but are ankylosed.

The carpus has the eight ordinary bones. In the manus the digits ii. iii. iv. are complete, and a bony tubercle articulated with the outer facet of the *cuneiforme* represents digit v. The digit iii. is largest and longest, and its phalanges are symmetrical in themselves; those of the digits ii. and iv. are not symmetrical in themselves. The terminal phalanges have somewhat the form of the coffin bone of the Horse.

The ilia have wide transversely directed crests, as in the Horse. The femur is provided with a very strong third trochanter. The tibia and the fibula are complete, and

the tarsus has the ordinary seven bones. The pulley of the astragalus is not very deeply grooved, and is hardly at all oblique. The facet for the cuboid is very small. The metatarsals resemble the metacarpals in their number and symmetry, but there is no rudiment of the fifth.

In some species of *Rhinoceros* there are $\frac{3 \cdot 3}{2 \cdot 2}$ incisors in the milk dentition, and $\frac{1 \cdot 1}{2 \cdot 2}$ or $\frac{1 \cdot 1}{1 \cdot 1}$ incisors in the permanent dentition. In the latter the upper incisors are large, long-crowned teeth, very unlike the lower ones, of which it seems probable that only one pair, in any case, are permanent teeth. In some *Rhinoceroses*, as has been already stated, the adult is devoid of incisor teeth.

There are no canines in either dentition. Of the four milk molars, the first, as in the Horse, is smaller than the others, and is not replaced. The structure of both the upper and the lower molars is substantially the same as in the Horse, but the roots are developed much sooner; the laminae of the upper molars take a much more transverse direction; the laminae of the upper molars do not develop pillars, though accessory crests may be developed from the two faces of the posterior lamina; the lower molars have no pillars; and the cement does not fill up the valleys between the wall and the laminae.

The cardiac division of the simple, though large, stomach is lined by a white callous epithelium, as in the Horse. The small intestine presents large processes or tags, half an inch long or more, upon which the true villi are borne. The cæcum is very large, and the colon enormous. There is no gall-bladder. The heart and brain are very similar to those of the Horse.

The male can hardly be said to have a scrotum, as the testes lie close to the abdominal ring. A prostate, vesiculæ seminales, and Cowper's glands are present. The long penis has a mushroom-shaped glans, and the animal is retro-mingent. The cornua uteri are proportionately longer than in the mare. The teats are two and inguinal in position.

The characters of the foetal membranes and the nature of the placentation are unknown.

At the present day the genus *Rhinoceros* is confined to Africa and Asia. The African species all have two horns, a nearly smooth skin, and the adult has no incisors. The Asiatic species have one horn only (except that of Sumatra, which has two). The skin is marked out by deep folds into shields, and the adults have well-developed incisors.

Rhinoceroses are known in the fossil state as far back as the miocene epoch. *R. tichorhinus*, with the nasal septum ossified, and a covering of long woolly hair, inhabited Europe and Asia during the cold of the glacial epoch. *R. incisivus* had four digits in the manus, and larger incisor teeth than any existing species. *R. hexaprotodon* had more numerous incisors than any other species.

c. In the *Tapiridæ* there are four toes on the front foot, though the ulnar digit does not reach the ground. The hind foot has three toes.

The dental formula is $i. \frac{3 \cdot 3}{3 \cdot 3} c. \frac{1 \cdot 1}{1 \cdot 1} p.m. \frac{4 \cdot 4}{3 \cdot 3} m. \frac{3 \cdot 3}{3 \cdot 3}$.

The molar teeth each present two transverse, or slightly oblique, ridges, connected by a low wall externally.

The skin is soft and hairy, and the muzzle and snout are prolonged into a short proboscis.

The Tapirs have twenty-three or twenty-four dorsolumbar vertebræ, of which nineteen, or twenty, are usually dorsal. The centra of these vertebræ, and the transverse processes of the last lumbar, have the same peculiarities as those of the Horse and Rhinoceros. There are seven sacral and about twelve caudal vertebræ. The skull is partly Rhinocerotie, partly Equine in its characters. Thus there is a sagittal crest—the post-tympanic processes are large, but they are not so long as the paramastoids, and they do not unite with the post-glenoidal processes beneath the meatus. In these respects the Tapir is Horse-like, but in the following it is more Rhinocerotie.

Thus the tympanic is quite rudimentary; the post-

glenoidal process is larger than in the Horse; the orbit is not separated from the temporal fossa; the nasals are widely separated from the premaxillæ; the premaxillæ are very small, and are early ankylosed.

The hinder margin of the osseous palate is opposite the anterior edge of the penultimate molar. The mandibular rami unite in a very long symphysis; the ascending portion of the ramus is large, and projects backwards with a convex edge in a remarkable manner. There is a high coronoid process.

In the fore limb, the scapula has no acromion, and the coracoid is a mere tubercle. The supraspinous fossa is very much larger than in the Horse or Rhinoceros. The radius and the ulna are complete, but not movable upon one another. Although, by the completion of the fifth digit, in addition to the second, third, and fourth, there are four digits in the manus, the Perissodactyle character is manifested by the fact that the third is longest, and symmetrical in itself, while the others are asymmetrical. The femur has a strong third trochanter; the fibula is complete; the astragalus more Rhinocerotie than Equine. There is no trace of a hallux, but the fifth digit of the pes appears to be represented by an osseous rudiment.

In the presence of the full complement of incisors and canines the Tapir is more Horse-like than Rhinocerotie, but is still very peculiar; for the outer upper incisors are larger than the canines, while the outer lower incisors are much smaller than the canines, and are apt to fall out at a certain age. The canines, are still more closely approximated to the incisors than in the Horse, especially in the lower jaw, and, consequently, the diastema is very large. The six posterior molars in the upper jaw, and the five posterior molars in the lower, present nearly the same structure. There is a low outer wall with two slightly marked concavities (in the maxillary teeth) or convexities (in the mandibular teeth) on its outer face. From this two ridge-like laminae run inwards and a little backwards across the crown of the tooth. The valleys are broad and shallow,

and the coat of cement very thin. The molar tooth of the Tapir thus represents the plan of structure common to the *Perissodactyla* in its simplest form. Deepen the valleys, increase the curvature of the wall and laminae, give the latter a more directly backward slope; cause them to develop accessory ridges and pillars, and increase the quantity of cement; and the upper molar of the Tapir will gradually pass through the structure of that of the Rhinoceros to that of the Horse.

In the anterior upper premolar (or milk molar?) the anterior moiety of the crown is incompletely developed. In the anterior lower premolar the anterior basal process, which exists in all the molars, is excessively developed, so that the crown of the tooth assumes the bicrescentic pattern of the Rhinoceros' lower grinder. This probably indicates the manner in which the Tapiroid form of inferior molar is converted into the Rhinocerotid, or Equine, form.

The stomach is simple and oval, the cardiac and pyloric orifices being closely approximated. The cæcum is proportionally smaller than in the Horse or Rhinoceros. There is no gall-bladder. The heart is devoid of a septal bone and of a Eustachian valve. There is only a *single vena cava anterior*, and the aorta divides into an anterior and a posterior trunk. There is no third bronchus. No distinct scrotum is present. There are vesiculæ seminales and prostatic glands, but no Cowper's glands. The placentation is diffuse. The teats are two, and inguinal.

There are two or three species of Tapir at present living in South America and one in South-west China, Malacca, and Sumatra. The genus *Tapirus* has been found fossil in Europe in rocks of miocene age. The closely allied extinct genera *Lophiodon* (and *Coryphodon*?) carry the *Tapiridæ* back through the eocene epoch.

d. The Palæotheridæ.—These are all extinct animals, the remains of which are found in the older tertiary rocks; and which are closely allied, on the one hand, with the Horses and, on the other, with the Tapirs.

The type of the family, *Palæotherium*, resembles the Tapir

in most respects, but has only three digits in the manus as well as in the pes. The dental formula, however, is $i. \frac{3 \cdot 3}{3 \cdot 3} c. \frac{1-1}{1-1} p.m. \frac{4 \cdot 4}{4 \cdot 4} m. \frac{3 \cdot 3}{3 \cdot 3}$. The diastema is smaller than in the Tapir, and the patterns of the grinding teeth of both jaws are more like those of the Rhinoceros.

e. The *Macrauchenidæ*.—The genus *Macrauchenia* is also an extinct form, which occurs in later tertiary or quaternary deposits in South America.

The feet are tridactyle, and the dental formula is $i. \frac{3 \cdot 3}{3 \cdot 3} c. \frac{1 \cdot 1}{1 \cdot 1} p.m. \frac{5 \cdot 5}{4 \cdot 4} m. \frac{3 \cdot 3}{3 \cdot 3}$. The teeth are disposed in a nearly continuous series. The crowns of the incisors present a deep fossa, as in the *Equidæ*. The molars are in part Equine, in part Rhinocerotid in character. The skull is, on the whole, Equine, but the nasal bones are very short and tapiroid. The vertebræ of the long neck are extraordinarily similar to those of the *Camelidæ*, and especially of the Llamas.

2. The *Artiodactyla*.—The number of the dorso-lumbar vertebræ in this group is always fewer than twenty-two, and rarely exceeds nineteen.

The third digit of each foot is asymmetrical in itself, and usually forms a symmetrical pair with the fourth digit; and the functional toes of the hind foot are even in number—that is to say, either two or four.

The femur is devoid of any third trochanter; the facets upon the distal face of the astragalus are subequal, that for the cuboid being nearly as large as that for the navicular bone. The tympanic is large, and the pterygoid process of the sphenoid is not perforated.

The posterior premolar teeth usually differ a good deal from the succeeding molars, being simpler in pattern. The last milk molar in the lower jaw is trilobed; but this is also the case in some *Perissodactyla*.

The stomach is more or less complex. The cæcum, though well developed, is smaller than in the *Perissodactyla*.

The mammæ are inguinal or abdominal. When horns are

present, they are double, supported, wholly or partly, by the frontal bone and provided with an osseous core, which is almost always an outgrowth from that bone.

The *Artiodactyla* are divisible into the *Non-Ruminantia* and the *Ruminantia*.

A. The *Non-Ruminantia* usually have more than one pair of incisors in the upper jaw. The molar teeth have either a mammillate, a transversely ridged, or a rhinocerotie pattern. In only one genus, *Dicotyles*, are any of the metatarsal or metatarsal bones ankylosed together. They are devoid of horns, and the stomach has rarely more than two divisions.

The *Non-Ruminantia* are divisible into three families:—The *Suidæ*, the *Hippopotamidæ*, and the *Anoplotheridæ*; but more or fewer of the members of this last group may have ruminated.

a. The *Suidæ* have the skin of moderate thickness and hairy; the limbs slender, and the third and fourth toes considerably longer than the second and fifth. The teats are abdominal, and there is a scrotum. The dental formula varies considerably, but the molars have a multituberculate or transversely ridged grinding surface.

In the genus *Sus*, the dental formula is $i. \frac{3 \cdot 3}{3 \cdot 3} c. \frac{1 \cdot 1}{1 \cdot 1} p.m. \frac{4 \cdot 4}{4 \cdot 4} m. \frac{3 \cdot 3}{3 \cdot 3}$.

By way of contrast with the Horse, I add some more detailed statements regarding the anatomy of the Pig as a common and very good example of an Artiodactyle. The Pig has seven cervical vertebræ, nineteen* dorsolumbar, of which fourteen are dorsal, four sacral, and twenty to twenty-three caudal. The atlas has wide oblique alæ, as in the Horse. The centra of the other cervical vertebræ are short, with nearly flat articular surfaces, and this flatness is retained in the dorsolumbar region. The cervical and dorsal vertebræ are provided with long spines, that of the first dorsal vertebra being the longest of all. Up to the twelfth dorsal the spines all slope backwards; beyond it they slope forwards, if at all.

* Exceptionally, the number may be increased to twenty-two.

In the ninth dorsal vertebra the postzygapophysis presents an articular surface on its dorsal side, and the prezygapophysis of the tenth vertebra bends round so as to overlap this surface. This character is continued in the succeeding vertebræ as far as the first sacral. The transverse processes of the penultimate and last lumbar vertebræ are tolerably long, but they are inclined forwards as well as outwards, and do not articulate with one another, or with the first sacral.

In the skull the supraoccipital is inclined upwards and forwards into a great transverse crest, to which the parietals contribute but little. The parietals are early ankylosed. The temporal ridges remain widely separated in the middle of the roof of the skull.

The frontal bone has a post-orbital process, and so has the jugal, but the two do not meet so as to bound the orbit. The lachrymal is very large, and its two canals open on the face. The nasals are very long, and the premaxillæ unite with them for a great distance. There is a prænasal bone, or ossification of the cartilaginous septum of the nose. The bony palate extends back beyond the level of the last molar. The base of the external pterygoid process is not perforated. The surface for the articulation of the lower jaw is transversely elongated, convex from before backwards, and bounded behind and internally, by a post-glenoidal ridge.

The tympanic bulla is very large, and the exceedingly long bony meatus curves upwards and outwards, between the squamosal and the mastoid, with both of which it is ankylosed, to the root of the zygoma, where its aperture looks almost directly upwards. The post-tympanic is closely appressed to the post-glenoidal process, so as, with the latter, to encircle the meatus. The proper mastoid is distinct, though short, but there is a very long paramastoid developed from the exoccipital and extending behind and below the mastoid.

The rami of the mandible are completely ankylosed at the symphysis. There is a long perpendicular portion of the ramus. The condyle is transversely elongated and

convex, antero-posteriorly; the coronoid process ascends hardly higher than it. In a longitudinal section, the cavity of the cerebral hemispheres is more rounded than in the Horse, and lies above, as well as in front of, that for the cerebellum.

The scapula is long and narrow. It is devoid of acromion, and has but a small coracoid process.

The radius and ulna are complete, but are ankylosed together in the prone position. The distal end of the ulna articulates with the cuneiform bone.

The carpus contains eight bones, but the radial bone in the distal series may be either the trapezium, or a rudiment of the pollex. The lunare, and the axis of the third metacarpal have the same relation as in the Horse. The third and fourth digits are larger than the other two, and form a symmetrical pair. There are sesamoid bones on the ventral face of the articulations between the metacarpal and the basal phalanx, and of that between the middle and the distal phalanges. Each distal phalanx is incased in a small hoof. The femur has a round ligament. There is no third trochanter. The fibula is complete, and its distal end articulates with the calcaneum. There are the usual seven tarsal bones. The tibial end of the astragalus has the form of a deeply-grooved pulley, the direction of the groove corresponding nearly with the length of the foot. The distal end presents a convex subcylindrical surface divided by a ridge into two facets, of which one is somewhat less than the other, and articulates with the cuboid.

The metatarsus and phalanges of the pes are disposed like the corresponding bones in the manus.

The fore part of the body is supported upon the anterior extremities by a muscular sling composed of the *serratus*, *levator anguli scapulae*, and *sternoscapularis*, much as in the Horse, with which the Pig exhibits a general correspondence in its myology. The muscles which move the digits, however, have undergone less modification. Each digit of the manus, for example, has its proper extensors, and there is an *extensor ossis metacarpi pollicis* which ends on the basal

phalanx of the second digit. A *pronator teres* is inserted into the lower half of the radius. The *flexor perforatus* has only two tendons, which go to the third and fourth digits. The *flexor perforans* sends two large tendons to the third and fourth, and two small ones to the second and fifth digits. There is a large *interosseus* muscle on the radial side of the third digit, and another on the ulnar side of the fourth; but the *interossei* of the interspace between these digits are represented only by fibrous tissue. The second and fifth digits have each two *interossei*. There is no *soleus*. The strong and fleshy *plantaris* arises from the outer condyle, beneath the *gastrocnemius*; and, inclosed between the two heads of the latter, passes to the inner side of the *tendo Achillis*; its tendon curves round this tendon, passes over the end of the calcaneum as over a pulley, enters the sole, and finally divides into the two perforated tendons of the third and fourth digits. The inner and outer digits of the pes, like those of the manus, have no perforated tendons.

A large and fleshy *flexor hallucis longus* arises from the fibula and the interosseous ligament, and its broad tendon passes into the sole and coalesces with the tendon of the smaller *flexor longus digitorum*. The conjoined tendons divide into four slips—two large, median, and two small, inner and outer. These go to the distal phalanges and sesamoids of the respective digits.

The *tibialis posticus* is absent, but there is a small *tibialis anticus*.

A very complicated muscle represents the *extensor longus digitorum* and the *peronæus tertius*. It arises by (*a*) a strong round tendon from the outer condyle of the femur, just in front of the external lateral ligament. From this tendon proceed two fleshy bellies, one of which supplies tendons to the third, fourth, and fifth digits, while the other ends in a broad band of tendinous fibres, which is inserted into the third metatarsal and the ectocuneiform. Into this band is inserted (*b*) the second fleshy head which arises from the upper part of the tibia; and it is traversed by the tendon

of (c) the third head, which is slender, arises from the fibula, and sends its long and delicate tendon to the dorsum of the second digit.

The *peronæus longus* is present, and its tendon is inserted into the entocuneiform and the second metatarsal. There is no *peronæus brevis*. A *peronæus 4ti et 5ti digiti* arises from the upper part of the fibula, behind the *peronæus longus*, and ends in a tendon which passes behind, and on the inner side of, that of the latter muscle, to the dorsum of the foot, where it divides into two branches which join the extensor sheaths of the fourth and fifth digits.

The *extensor brevis* goes to the two middle digits, and is connected with the middle tendon of the extensor longus.

The *interossei* are similar to those of the *manus*.

The formula of the milk dentition of the Pig (which is complete at the third month after birth) is $d.i. \frac{3 \cdot 3}{3 \cdot 3} d.c. \frac{1-1}{1-1}$
 $d.m. \frac{4 \cdot 4}{4 \cdot 4}$.

The outer upper incisors are directed obliquely outwards and backwards. In the upper jaw, the anterior two molars present sharp longitudinal edges, while the posterior two have broad crowns with two transverse ridges. In the mandible the anterior three molars have sharp longitudinal edges, while the hindermost has a broad, three-ridged crown.

The first permanent molar is the first tooth of the permanent set which comes into place (at about six months after birth), and the permanent dentition is completed in the third year, at which time the first deciduous molar, which is not replaced, falls out. Hence the formula of the per-

manent dentition is $i. \frac{3 \cdot 3}{3 \cdot 3} c. \frac{1-1}{1-1} p.m. \frac{3 \cdot 3}{3 \cdot 3} m. \frac{3 \cdot 3}{3 \cdot 3} = 40$.

The permanent incisors in the upper jaw have short, broad, vertically-disposed crowns, and lie in a longitudinal series, the external being separated by an interval from the others. The elongated inferior incisors lie side by side, are greatly inclined forwards and upwards, and are grooved upon their upper or inner faces. The strong, angulated

crowns of the canines are bent upwards and outwards in both jaws. They work against one another, in such a manner, that the upper wears on its anterior and external face, the lower on the posterior aspect of its apex. The crowns of the premolars are all brought to a cutting longitudinal edge, while the molars have broad crowns with transverse ridges subdivided into tubercles. Of these ridges there are two in the anterior two molars of each jaw, while the posterior molar is more complex, having at fewest three distinct ridges. The molar teeth all develop roots; but the canines continue to grow for so long a time, in the Boar, that they might be said to be rootless.

The alimentary canal is ten or twelve times as long as the body.

The stomach is less simple in structure than it appears to be at first sight. The cardiac end presents a small cœcum, in which is a spiral fold of the mucous membrane; and, at the entrance of the œsophagus, the epithelial lining is folded so as to form a sort of valve. Folds of the mucous membrane, between which there lies a groove, extend from the cardia towards the pylorus, and foreshadow the more developed structure observable in Ruminants.

The cœcum has not above one-sixth the capacity of the stomach, and the ilium projects into it, so as to form a very efficient ilio-cæcal valve. The liver is provided with a gall-bladder. The heart is devoid of an Eustachian valve, and sometimes, but not always, possesses a septal ossification.

There is only one anterior cava. The aorta gives off an *innominata*, from whence the right subclavian and the two carotids arise, and a left subclavian. This is an arrangement midway between that observed in the Horse and that in Man.

The trachea, before it divides, gives off a third bronchus, which passes to the right lung; and the lungs are deeply lobed.

In the brain the cerebral hemispheres rise above the cerebellum much more than they do in the Horse.

In the male, the penis is contained in a long prepuce, and, like that of the Horse, is devoid of a bone and provided with retractor muscles. The prostate is lobed. There is a large uterus masculinus and well-developed vesiculæ seminales. The ducts of Cowper's glands open into a cæcal cavity contained in the muscular bulb. The testes descend into a scrotum. In the Sow, a pair of *Gaertner's canals*, or persistent Wolffian ducts, open into the vestibule beside the urinary meatus. The uterine cornua are very long, and the ovaries are lobulated. The period of gestation is sixteen to twenty weeks. The ovum, at first spherical, retains that form until it attains a diameter of nearly half an inch. It then rapidly elongates into a coiled filiform body, as much as twenty inches long. Both the allantois and the umbilical vesicle at the same time assume a spindle-shape.

The allantois soon becomes divided into an internal epithelial and an external vascular layer; the latter becoming united with the chorion, through the extremities of which the allantois eventually passes. The villi are very numerous, minute, and spread over the whole surface of the ovum.

The *Suidæ* exhibit great variations in their dentition and in the structure of the stomach.

In *Porcus* (the Babyrussa) the dental formula is $i. \frac{2 \cdot 2}{3 \cdot 3}$
 $c. \frac{1 \cdot 1}{1 \cdot 1} p.m.m. \frac{5 \cdot 5}{5 \cdot 5}$; the canines are enormously elongated and recurved, and the pharynx is provided with peculiar air sacs.

The stomach is divided into three chambers, and the groove leading from the œsophagus towards the pylorus is more distinctly marked than in *Sus*.

In *Dicotyles* (the Peccaries) the upper incisors are also reduced to two on each side, and the molar teeth present transverse ridges, which are more distinct and less tuberculated than in *Sus*.

The stomach is divided into three sacs, and is provided with an œsophageal groove as in the preceding genus.

The middle metatarsals and metacarpals coalesce into a

cannon bone, and the fifth digit of the pes is represented only by its metatarsal.

In *Phacochærus* (the Wart-hog) the upper incisors are reduced to one pair, and the hindermost molars, which are the only ones which are not shed in the old animal, are of great size, and possess a complicated, tuberculated, structure.

The *Suidæ* are represented by one genus or another in all the great distributional provinces except the Australian* and Novo-Zelanian. *Porcus* is peculiar to part of the Malay Archipelago, *Dicotyles* to South America, and *Phacochærus* to South Africa.

A great variety of Swine-like *Ungulata* existed during the deposition of the older tertiary strata, and are the earliest known members of the group.

b. The *Hippopotamidæ* are represented at present only by the genera *Hippopotamus* and *Chæropus*. These animals have a huge head, a heavy body, covered with a thick integument, provided with scanty hairs, and short, stout, tetradactyle limbs, all the four toes of which rest on the ground. The female has inguinal teats, and the male is devoid of a scrotum.

The dental formula of the adult *Hippopotamus* is $i. \frac{2 \cdot 2}{2 \cdot 2}$ c. $\frac{1 \cdot 1}{1 \cdot 1}$ p.m. $\frac{3 \cdot 3}{3 \cdot 3}$ m. $\frac{3 \cdot 3}{3 \cdot 3}$, while *Chæropus* has only two incisors in the lower jaw. The tubercles of the molar teeth, when ground down by mastication, present a double trefoil pattern, and the hindermost inferior molar is trilobed. The incisors are straight and tusk-like. The very large and curved canines are directed downwards in the upper jaw, upwards in the lower. Their mutual attrition wears the anterior face of the extremity of the upper, and the posterior face of that of the lower, flat.

The milk dentition consist of $d.i. \frac{3 \cdot 3}{3 \cdot 3}$ $d.c. \frac{1 \cdot 1}{1 \cdot 1}$ $d.m. \frac{4 \cdot 4}{4 \cdot 4}$. The last lower deciduous molar is trilobed, and the first deciduous molar persists a long time, and seems not to be replaced.

* The Papuan pig may have been introduced from the westward.

The stomach is divided into three or four compartments, and there is no cœcum. The liver has a gall-bladder, and the kidneys are lobulated.

The skeleton is very pig-like, but in some respects approaches the Ruminants. The centra are slightly convex in front, and concave behind, in the cervical region, but not elsewhere. The prezygapophyses overlap the postzygapophyses in the posterior dorsolumbar vertebræ. On the other hand, the transverse processes of the last lumbar vertebræ articulate with those of the preceding and succeeding vertebræ, as in the Horse and other Perissodactyles.

In the skull the orbits are nearly complete posteriorly, and they become almost tubular by the outward production of the frontal and lachrymal bones.

The nasals and premaxillæ unite for a great extent. The osseous palate is long; the large tympanic bone is ankylosed with the approximated post-glenoidal and post-tympanic processes.

The mandible is extremely massive, and has a backwardly produced angle.

The scapula has a short acromion. The radius and ulna are complete and ankylosed, and there are eight bones in the carpus. The fibula is complete, and the tarsus, which has seven bones, much resembles that of the Pig.

The *Hippopotamidæ* are at present confined to Africa; but a species abounded in the rivers of Europe in the later tertiary times.

Merycopotamus of the miocene Fauna of the Sewalik Hills appears to have been a Hippopotamid, with upper molars having a quadri-crescentic, ruminant-like, pattern, and lower molars bi-crescentic and rhinocerotie in character.

In the *Suidæ* and *Hippopotamidæ*, it is interesting to remark the tendency to the coalescence of the metacarpals and metatarsals in *Dicotyles*; the disappearance of the upper incisors by pairs in *Dicotyles*, *Porcus*, and *Phacochoerus*; and the great complexity of the stomach in *Dicotyles* and *Hippopotamus*; as they are so many approximations towards the structure of the Ruminant *Artiodactyla*. And the tran-

sition from the non-Ruminant to the Ruminant groups, or rather the common stem of both, is furnished by the *Anoplotheridæ*.

c. The family of the *Anoplotheridæ* exclusively contains extinct Mammals belonging to the eocene and miocene epochs. They are most conspicuously distinguished by the circumstance that the teeth, of which there are eleven on each side, above and below, in the adult dentition, are not interrupted by any gap in front of and behind the canine, as they are in the preceding genera, but form an uninterrupted and even series, as in Man.

The dental formula of the adult *Anoplotherium* is $i. \frac{3 \cdot 3}{3 \cdot 3} c. \frac{1 \cdot 1}{1 \cdot 1} p.m. \frac{4 \cdot 4}{4 \cdot 4} m. \frac{3 \cdot 3}{3 \cdot 3}$, supposing that the first pre-molar is really such, and not a persistent milk molar.

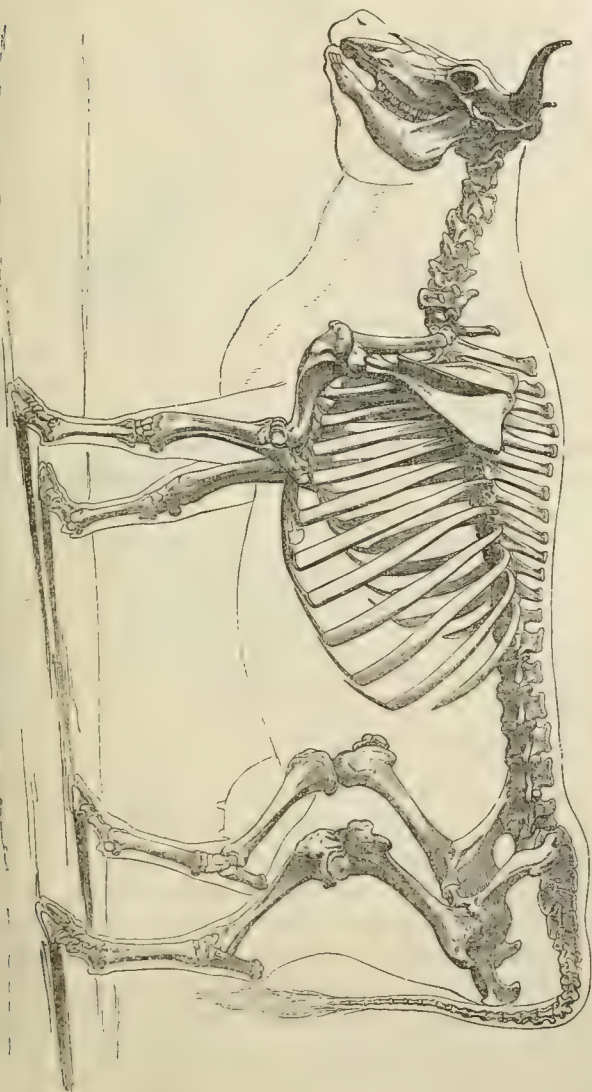
The upper and lower molars have the general structure of those of the Rhinoceros; but the laminae of the upper are bent more backwards into parallelism with the outer wall, and a strong conical pillar is developed on the inner side of the anterior lamina. The skull resembles that of the Ruminant *Tragulidæ* in structure, but the orbit is incomplete behind. The rest of the skeleton partly resembles that of the Pigs, and partly that of the Ruminants.*

In *Xiphodon* and *Cainotherium*, which are ordinarily comprised among the *Anoplotheridæ* (though, in all probability, they are true Ruminants of the Traguline group), the orbit is complete, and both upper and lower molars put on the Ruminant characteristics. In dentition, *Cainotherium* differs from a Ruminant only in possessing all the upper incisors, while no existing adult Ruminant has more than the outer upper incisors. We are of course unacquainted with the structure of the stomach in these animals, but they so closely resemble Ruminant *Artiodactyla* that it is highly probable they may have possessed the faculty of rumination in a more or less perfect degree.

* In *Anoplotherium secundarium* the digit *ii.* is developed in each foot, though not nearly so long as *iii.*, which is nearly symmetrical in itself. There is an approach to the same structure in the manus of *Cainotherium*.

B. *The Ruminantia*.—In the commonly recognised members of this division of the *Artiodactyla* there is never

Fig. 101. The skeleton of an Ox (*Bos*).



more than one pair of incisors, and that the outermost, in the upper jaw of the adult. Canines may or may not exist in the upper jaw; they are always present in the lower jaw, and are generally inclined forwards and closely approximated to the incisors, which they usually resemble in form. It consequently happens that they are often reckoned as incisors, and Ruminants are said to possess eight cutting teeth in the lower jaw.

With one exception (*Hycemoschus*), the metacarpal and metatarsal bones of the third and fourth digits early become ankylosed together into a single, so-called, *cannon bone*. There is a peculiar bone called *malleolar*, which takes the place of the distal end of the fibula, articulating below with the calcaneum and above with the astragalus.

The great majority of the Ruminantia possess horns, the bony supports, or cores, of which are developed on each side of the middle line; and, except in the Giraffe, are outgrowths of the frontal bones.

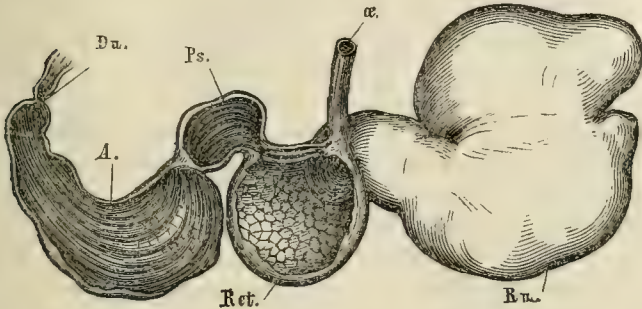
The stomach has, at fewest, three divisions; and, in the majority of the *Ruminantia*, it has four compartments.

If the stomach of a typical Ruminant, such as a Sheep or an Ox, be examined, it will be found to be divisible into two principal moieties, the one cardiac and the other pyloric, while each of these is again subdivided into two others. Thus the extreme cardiac end of the cardiac moiety is dilated into an enormous sac of irregular form, the mucous membrane of which is raised up into a vast number of close-set papillæ. This chamber is the *Rumen*, or *Paunch*. It communicates, by a wide aperture, with a much smaller chamber, which constitutes the second sub-division of the cardiac moiety. This is called the *Reticulum*, or *Honeycomb* stomach, from the fact that its mucous membrane is raised up into a great number of folds, which cross one another at right angles, and, in this way, inclose a multitude of hexagonal-sided cells. The reticulum communicates by a narrow aperture with the first subdivision of the pyloric moiety, which is somewhat more elongated in form. The mucous membrane of this subdivision is produced into a

vast number of longitudinal folds of various heights, but the majority of them are sufficiently large to extend almost

Fig. 102.

A.



B.

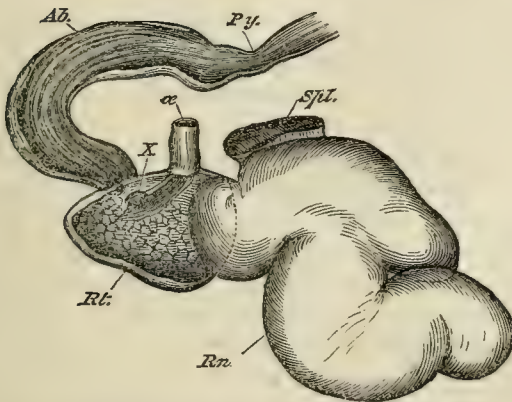


Fig. 102.—A, the stomach of a Sheep. B, that of a Musk-deer (*Tragulus*).

α., cesophagus; Rn., rumen; Ret., reticulum; Ps., psalterium; A., Ab., abomasum; Du., duodenum; Py., pylorus.

completely across the cavity of the chamber; they thus reduce that cavity to a series of narrow radiating clefts interposed between the lamellæ. When this portion of the stomach is slit open, longitudinally, the lamellæ fall apart like the leaves of a book, whence it has received the fanciful name of the *Psalterium* from anatomists, while butchers give

it that of *Manyplies*. The fourth segment of the stomach, or second subdivision of the pyloric moiety, is termed the *Abomasum*, or *Rennet* stomach. This portion is comparatively slender and elongated, and its mucous membrane has a totally different character from that of the other three segments, being soft, highly vascular, and glandular, and raised into only a few longitudinal ridges.

It will be observed that the psalterium is so constructed as to play the part of a very efficient strainer between the reticulum and the abomasum; nothing but very finely divided, or semi-fluid matter, being capable of traversing the interstices of its lamellæ.

The gastric aperture of the œsophagus is situated at the junction of the paunch and the reticulum; the margins of its opening are raised into muscular folds, and are produced, parallel with one another, along the roof of the reticulum to the opening which leads into the psalterium. When the lips of this groove are approximated together, a canal is formed, which conducts directly from the œsophagus to the psalterium.

A Ruminant, when feeding, crops the grass rapidly and greedily, seizing it with its tongue and biting off the bundle of blades thus collected, by pressing the lower incisors against the callous pad formed by the gum which covers the pre-maxillæ. The bunches of grass are then hastily swallowed, accompanied by abundant saliva. After grazing until its appetite is satisfied, the Ruminant lies down, usually inclining the body to one side, and remains quiescent for a certain space of time. A sudden movement of the flanks is then observed, very similar to that which might be produced by a hiccough; and careful watching of the long neck will show that something is, at the same time, quickly forced up the gullet into the cavity of the mouth. This is a bolus of grass, which has been sodden in the fluids contained in the stomach, and is returned, saturated with them, to be masticated. In an ordinary Ruminant this operation of mastication is always performed in the same way. The lower jaw makes a first stroke, say in the direction from left to right, while the

second stroke, and all those which follow it until the bolus is sufficiently masticated, takes place from right to left, or in the opposite direction to that of the first. While the mastication is going on, fresh quantities of saliva are poured into the mouth, and when the grass is thoroughly ground up, the semifluid product is passed back into the pharynx and swallowed once more. These actions are repeated until the greater portion of the grass which has been cropped is pulpified.

The precise nature of the operation, the external features of which have now been described, has been the subject of much investigation and discussion. The following points appear to have been clearly established:

1. Rumination is altogether prevented by paralysis of the abdominal muscles, and it is a good deal impeded by any interference with the free action of the diaphragm.

2. Neither the paunch, nor the reticulum, ever becomes completely emptied by the process of regurgitation. The paunch is found half full of sodden fodder, even in animals which have perished by starvation.

3. When solid substances are swallowed, they pass indifferently into the rumen, or reticulum, and are constantly driven backwards and forwards, from the one into the other, by peristaltic actions of the walls of the stomach.

4. Fluids may pass either into the paunch and the reticulum; or into the psalterium, and thence at once into the fourth stomach, according to circumstances.

5. Rumination is perfectly well effected after the lips of the œsophageal groove have been closely united by wire sutures.

It would appear, therefore, that the cropped grass passes into the reticulum and rumen, and is macerated in them. But there is no reason to believe that the reticulum takes any special share in modelling the boluses which have to be returned into the mouth. More probably, a sudden and simultaneous contraction of the diaphragm and of the abdominal muscles, compresses the contents of the rumen and reticulum, and drives the sodden fodder against the cardiac aperture of

the stomach. This opens, and then the cardiac end of the œsophagus, becoming passively dilated, receives as much of the fodder as it will contain. The cardiac aperture now becoming closed, the bolus, thus shut off, is propelled, by the reversed peristaltic action of the muscular walls of the œsophagus, into the mouth, where it undergoes the thorough mastication which has been described.

The sodden fodder is prevented from passing out of the psalterial aperture of the reticulum, in part by the narrowness of that aperture, and in part by the fine grating formed by the edges of the psalterial laminae. But when the semifluid matter, returned after mastication, once more reaches the cardia, it is compelled to pass towards the psalterial end of the reticulum (even apart from the guidance afforded by the lips of the œsophageal groove) on account of the direction of the œsophagus and the bounding of the cardiac aperture, on the side of the rumen, by a raised ridge. The chewed matter thus flowing over the surface of the more solid contents of the reticulum reaches the psalterium; and, in consequence of the fine state of division of its solids, readily traverses the interspaces of the lamellæ of that organ, and passes into the fourth stomach, there to be submitted to the action of the gastric juice and to undergo the digestion of the protein compounds, which have remained unaffected by the previous mastication and insalivation.

The *Ruminantia* are divided into three groups: *a.* the *Tragulidæ*, *b.* the *Cotylophora*, and *c.* the *Camelidæ*.

a. The *Tragulidæ* are a remarkable family, formerly united with the genus *Moschus*, and still commonly known under the name of Musk Deer, though they are devoid of the musk sac and, in other respects, are totally different from *Moschus*. They are at present restricted to southern Asia and Africa; and they are particularly interesting, as affording, in many respects, a connecting link between the typical Ruminants and the other *Artiodactyla*, especially the *Anoplotheridæ*. Thus, the second and fifth digits are complete in both fore and hind feet, and the metacarpals

and metatarsals of the third and fourth digits unite very late, or, as in one genus, *Hyæmoschus*, not at all. The canines are well developed in both jaws, and the premolar teeth are sharp and cutting.

The œsophagus opens at the junction of the rumen with the reticulum, the communication between the two being very wide (Fig. 102 B). The epithelium of the rumen is papillate, and there are two œsophageal folds, as in ordinary Ruminants, but the psalterium is represented only by a very short and narrow tube, the lining membrane of which is devoid of folds.

The surface of the hemispheres of the brain has fewer convolutions than in any other Ruminants, though this may very possibly be connected with the small size of the animal; as it is a general rule that, within the same group, the brain is less convoluted in small than in large animals.

The blood corpuscles, small in all *Ruminantia*, are remarkably minute in the *Tragulidæ*, not exceeding $\frac{1}{10000}$ of an inch in diameter. They have circular contours.

The placenta is very nearly *diffuse*, the foetal villi being scattered over the chorion in bands, not collected into cotyledons.

As further remarkable peculiarities of this group may be mentioned the ankylosis of the malleolar bone with the tibia, and the tendency to ossification in the pelvic ligaments and of the aponeurosis of the muscles of the back, in adult males. Finally, the navicular, cuboid, and ecto-cuneiform bones in the tarsus are all ankylosed together. If, as is probable, *Xiphodon* is one of the *Tragulidæ*, the group has existed since the eocene epoch.

b. The *Cotylophora* are, like the preceding group, unguligrade, but the outer metacarpals and metatarsals are incomplete at their proximal ends, and the middle ones are early ankylosed into a cannon bone. The malleolar bone is always distinct. The navicular and the cuboid bones of the tarsus are ankylosed together, but rarely with any other tarsal bone. The premaxilla is devoid of teeth in the adult. The stomach has the structure which has been described as typical.

The blood corpuscles are circular, and may have a diameter of as little as $\frac{1}{5000}$ of an inch.

The fœtal villi are gathered together into bunches or cotyledons, which may present either a convex or a concave face towards the uterus. They are received into persistent elevations of the mucous membrane of the uterus, the surfaces of which present a reverse curvature.

All the *Cotylophora* except *Moschus*, the true Musk Deer, are provided with horns, but these horns are of two kinds. The bony core, in the one case, is ensheathed in a strong horny epidermic case; while, in the other, the epidermis of the integument which covers the core does not become so modified. In the former kind of horn, the core becomes excavated by the extension into it of the frontal sinuses, whence the ruminants which possess such horns are not unfrequently called *Cavicornia* (Antelopes, Sheep, Goats, Oxen). As a general rule, the horny sheath persists throughout life, growing with the growth of the core. But in the remarkable Prong-horned Antelope of North America (*Antilocapra*), the horny sheath is annually shed and replaced by a newly-formed one.

Of the second kind of horn, or that which acquires no horny sheath, there are also two kinds. In the Giraffe, the horn cores are attached over the coronal suture, at the junction of the frontal and parietal bones, with which they are not ankylosed; they persist throughout life, and are always covered by a soft and hairy integument.

In the Deer, on the other hand, the frontal bones grow out into solid processes, which are, at first, covered by soft and hairy integument; generally they are developed in the male sex only, but both sexes have them in the Reindeer. The horns attain their full size very rapidly, and then a circular ridge, which makes its appearance at a short distance from the root of the horn and is called the "burr," divides the horn into the "pedicel" on the skull side of the burr, and the "beam" on the opposite side. The circulation in the vessels of the beam now gradually languishes, its integument dies and peels off, and the dead

bony substance beneath is exposed. Absorption and sloughing next occur at the extremity of the *pedicel*, just as might happen in any other case of necrosis. The beam and burr are shed, and the end of the pedicel scabbing over, fresh integument gradually grows up under the scab, and eventually restores to the extremity of the pedicel its pristine smooth and hairy covering.

The rapidity with which the development of bony matter into Deer horn takes place is wonderful, horns weighing 72 lbs. having been produced in ten weeks.

The *Cotylophora* are represented in all parts of the world except the Australian and Novo-Zelanian provinces. They have not yet been traced back further than the miocene epoch.

c. The *Camelidæ* or (*Tylopoda*) are devoid of horns; and, unlike the other Ruminants, they walk upon the palmar and plantar surfaces of the phalanges of the third and fourth toes, which are alone developed. Broad integumentary cushions form a sole to the foot; while the nails are flattened and can hardly be called hoofs.

The arches of the cervical vertebræ, and not their transverse processes, are perforated by the canal of the vertebral artery; a character which the camels share with the *Macrauchenidæ*.

The metacarpals are separated by a deep cleft, and the distal phalanges of the digits are nearly symmetrical in themselves. The distal facets of the astragalus are more unequal than in the other *Ruminantia*, and the navicular and cuboid bones are not ankylosed together.

The premaxillæ have a single strong outer incisor on each side. Large curved and pointed canines are developed in each jaw, and are quite distinct from the series of the incisors in the mandible. There are not more than five grinding teeth in a continuous series above and below.

The stomach is unlike that of the typical Ruminants. The œsophagus opens directly into the paunch, which is lined by a smooth, not papillose, epithelial coat. From its walls, at least two sets of diverticula, with comparatively

narrow mouths, are developed. These, the so-called "*water cells*," serve to strain off from the contents of the paunch, and to retain in store, a considerable quantity of water. The reticulum is sharply defined from the rumen, and communicates with it by a comparatively small aperture. The œsophageal groove is bounded by only one ridge, which lies upon its left side. The psalterium is reduced to a mere tubular passage, without laminae; and the abomasum is large, and has the ordinary structure. The pyloric end of the duodenum is considerably dilated, and has been taken for a division of the stomach. The cœcum is short and simple. By a remarkable exception among the *Mammalia*, the red blood corpuscles are elliptical. The foetal villi are scattered evenly over the chorion, so that the placenta is *diffuse*.

While the *Tragulidæ* connect the typical Ruminants with the non-ruminant Artiodactyles, the *Camelidæ*, on the other hand, link them with *Macrauchenia* and the *Perissodactyles*.

The *Camelidæ* are at present represented by two very distinct groups—the Camels of the old world and the Llamas of the new. They occur in the fossil state as far back as the miocene epoch.

II. THE TOXODONTIA.—This order has been founded for the reception of the large extinct Mammal (*Toxodon*), remains of which have been discovered in the later tertiary deposits of South America.

The supraoccipital surface of the massive skull slopes obliquely upwards and forwards. There are supraorbital prolongations. The zygomata are very strong and arched, and the bony palate is very long.

In the upper jaw there are two small, inner, and two large, outer, incisors. In the lower jaw there are six incisors. In the mandible there are canines in the middle of the interval between the incisors and the grinders. In the upper jaw of the adult, only indications of the former existence of alveoli for canines remain. The grinding teeth are seven on each side above, and six on each side below. They are

greatly bowed (whence the name of the genus), so as to be convex outwards and concave inwards. They grow from persistent pulps, and the enamel is absent upon their inner faces.

The centra of the cervical vertebræ have flattened articular faces. The dorsolumbar vertebræ and the sacrum are not known. The ribs are spongy internally, like those of ordinary Mammals, not compact, as in the *Sirenia*.

The scapula has a very large supraspinous fossa, as in *Tapirus*. There is no acromion, and the coronoid is very small. The humerus and the ulna are very massive, but the rest of the fore-limb is unknown. The femur is devoid of any third trochanter, and, like the tibia and astragalus, presents a good many points of resemblance to the corresponding bone in the Elephants.

It is a curious comment upon the pretension to reconstruct animals from mere fragments of their bones and teeth which some have put forward, that although we know the skull, the dentition, and the most important of the limb bones of *Toxodon*, no one ventures to predict the characters of its feet, still less to say anything about its internal organization. Even its zoological affinities are extremely doubtful, and it is hard to say whether *Toxodon* is merely an aberrant Ungulate, or whether it is the type of a new order.

III. The SIRENIA.—As has been already said, nothing is known of the placentation of this small but important group of *Mammalia*, all the existing forms of which are aquatic in their habits, frequenting great rivers and their estuaries; and are devoid of hind limbs, while the integument of the caudal end of the body is produced into a flattened horizontal fin. No dorsal fin is ever present. The demarcation between the head and neck is but obscurely marked, and the forelimbs are converted into paddles, upon which only rudimentary nails are developed. Scanty bristles cover the surface of the body. The snout is fleshy and tumid, and the valvular nostrils, which are perfectly distinct from one another, are situated consider-

ably above its termination. There is a well-developed third eyelid, the pinna of the ear is absent, and the mammæ are thoracic; a circumstance which has probably not a little contributed to the origination of the myths respecting the existence of mermaids.

The *Sirenia* were formerly united with the Whales and Porpoises as *Cetacea herbivora*. But their organization differs from that of the true Cetaceans in almost every particular, while they are closely allied with the *Ungulata*.

The cervical vertebræ are reduced to six in one genus—*Manatus*. The bodies of these vertebræ are always compressed from before backwards, but they are never all ankylosed together (it is rare for any of them to be thus united), and the second has a distinct odontoid process. The dorsal vertebræ have broad and depressed spines, and may be as many as seventeen or eighteen in number, while there are not more than three lumbar vertebræ; and the hindermost of these even is probably to be regarded as sacral. There are twenty or more caudal vertebræ, the terminal ones being not polygonal, but depressed, with well-developed processes.

The zygapophyses of successive vertebræ articulate together in the dorsal region; but, in the lumbar and caudal regions, the postzygapophyses disappear and the prezygapophyses are small, and neither overlap, nor embrace, the spine of the antecedent vertebra. The posterior moiety of the spine thus acquires considerable flexibility. There is no true sacrum, the vertebra called "sacral" being only determined as such by its connection with the rudimentary pelvis. Strong subvertebral chevron bones are placed beneath the interarticular cartilages of the caudal vertebra. The heads of the ribs articulate with the centra of all the vertebræ. The bodies of the ribs are very thick, rounded, and have a remarkably dense and laminated structure. The narrow and elongated sternum is an undivided mass of bone, and is connected by ossified sternal ribs with the anterior three pairs of vertebral ribs.

In the skull the elongated and subcylindrical form of the

cranial cavity is worthy of notice, as it strongly contrasts with the form of the brain-case in the *Cetacea*. The supra-occipital is very large and slopes upwards and forwards a long way on to the upper surface of the skull; but it does not separate the parietal bones; which, as usual, unite in the sagittal suture. The frontals are prolonged into broad supra-orbital processes. The nasal bones are abortive, and, in the dry skull, the external nares are very wide and look upwards. The tympanic bone is a thick hoop, ankylosed with the periotic bones, and readily comes away from the skull with them. The zygoma is enormously stout. The premaxillæ constitute a large portion of the boundary of the gape; and the lower jaw has a high ascending portion, with a large coronoid process.

The scapula has a distinct spine occupying the ordinary position. There are no clavicles. The humerus has its distal end fashioned into articular surfaces, upon which the radius and ulna are freely movable. The pollex is rudimentary, and the other digits have no more than three phalanges each.

The pelvis is rudimentary, the bones which represent the *ossa innominata* being connected by their proximal ends with the transverse processes of the last of the pre-caudal vertebræ. They are disposed vertically to the axis of the body. No trace of the hind limbs has been observed in any of the existing *Sirenia*.

The premaxillary region of the palate, and the corresponding surface of the mandible, are coated with mammillated and rugose horny plates formed of hardened epithelium; and, in the extinct genus *Rhytina*, these plates were the only masticating organs, as there were no teeth. In *Halicore* (the Dugong), there are teeth which have no vertical successors, form no roots, and are devoid of enamel; while, in *Manatus*, there are milk molars, and the grinding teeth are enamelled, and present crowns with double transverse ridges.

The adult Manatee has no incisors. In the Dugong there are no incisors in the mandible of the adult. The

male has two tusk-like incisors which project from their sockets in the premaxillæ; while, in the female, the tusks remain concealed in their alveoli.

In the fœtal state, both *Halicore* and *Manatus* have incisors in the mandible as well as in the premaxillæ.

The stomach is divided into two portions by a median constriction, and its cardiac end is provided with a peculiar gland. Its pyloric end, in some species, gives off two cœca.

There is a cœcum at the junction of the large and small intestine. Salivary glands are well developed. The apical portion of the *septum ventriculorum* is deeply cleft, so that the ventricles are separated from one another through about half their extent.

Fig. 103.

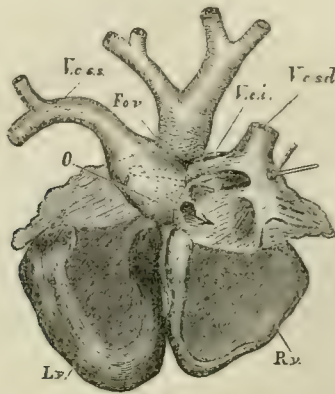


Fig. 103.—Dorsal view of the heart of a Dugong (*Halicore*), its cavities being laid open. *R. v.*, right ventricle; *L. v.*, left ventricle. *V. c. s. s.*, left superior vena cava. *V. c. s. d.*, right superior vena cava. *V. c. i.*, vena cava inferior. *F. o. v.*, the inner end of a cœcal diverticulum of the right auricle, into which a style is introduced, and which represents the foramen ovale. *O.*, the auricular septum.

There are two superior cavæ and a Eustachian valve. Extensive arterial and venous *retia mirabilia* are developed in *Manatus*. In consequence of the great length of the thoracic region and the brevity of the sternum, the diaphragm takes a very unusual course, extending very obliquely from before backwards, and causing the upper

part of the thoracic cavity to extend posteriorly over almost the whole of the abdomen. The greatly elongated lungs fill this part of the thoracic chamber, while the broad heart lies in its anterior and sternal portion.

The arytenoid cartilages are not prolonged as in the *Cetacea*. A broad and high epiglottis is capable of covering the glottis completely.

There is no third bronchus.

The cutaneous muscle is largely inserted into the humerus, and the sub-caudal muscles extend forward as far as the posterior lumbar vertebræ. The chief muscles of the antibrachium and manus are present.

The male *Sirenia* possess vesiculæ seminales. The uterus is two-horned.

There are two living genera of *Sirenia*—the Dugong (*Halicore*), which is found upon the shores of the Indian Ocean and of Australia; and the Manatee (*Manatus*), which is confined to the South American and African borders of the Atlantic.

A third genus, *Rhytina*, which had a coriaceous integument almost devoid of hair, and possessed no teeth, abounded in Behring's Straits less than a century ago. It is now altogether extinct.

The Miocene genus, *Halitherium*, appears to have possessed distinct, though small, hind limbs.

IV. The CETACEA.—In this order of *Mammalia* the form of the body is still more fish-like than in the *Sirenia*. There is no trace of a neck, the contour of the head passing gradually into that of the body. A horizontally flattened caudal fin is always present; and, very generally, the dorsal integument is produced into a median, laterally compressed, dorsal fin. The body is encased in a thick smooth integument, beneath which a very thick layer of fat is deposited. Hairs are almost entirely absent in the adult state.

As in the recent *Sirenia*, the anterior limbs alone are present. Externally they do not present any indication of

division into brachium, antebrachium, and manus, but have the form of a broad flattened paddle, without any vestiges of nails.

The one or two apertures by which the cavity of the nose opens externally, are always situated at the top of the head, and far removed from the extremity of the snout. There is no third eyelid, and the very small auditory apertures are totally devoid of any pinna. The teats are two, and, in the female, are lodged in depressions on each side of the vulva.

The articular surfaces of the centra of the vertebræ are flat, and the epiphyses usually remain distinct for a long time.

The spinal column, as a whole, is remarkable for the shortness of its cervical, and the length of its lumbar region, there being sometimes a greater number of lumbar than of dorsal vertebræ. There is no sacrum. The caudal vertebræ are only distinguishable from the posterior lumbo-sacral vertebræ by their chevron bones. The second vertebra of the neck is devoid of any odontoid process; and it very commonly happens that more or fewer of the cervical vertebræ, the bodies of which are often so short as to be mere discs, are ankylosed together, either by their arches, or by their centra, or by both. The centra of all the succeeding vertebræ are large in proportion to their arches, and the inter-vertebral fibro-cartilages are exceedingly thick, so as to confer great flexibility and elasticity on the spine. The arches of the hinder dorsal vertebræ, and of those of the lumbar and caudal regions, are not articulated together by zygapophyses. The centra of the posterior caudal vertebræ lose their processes and become polygonal.

Very few of the ribs become connected with the sternum at their distal ends; and, in contradistinction to what happens in most *Mammalia*, the proximal ends of the majority of the ribs are connected only with the transverse processes of the vertebræ, and not with their bodies.

The skull is even more remarkably modified than the vertebral column. The brain case itself has a spheroidal form; while the jaws are greatly prolonged, the principal

enlargement of the upper jaw taking place in the region which lies in front of the nasal aperture. The *basis cranii*, as a whole, is remarkably broad, and its upper surface concave from before backwards, the *sella turcica* being very slightly indicated. The parietal bones are comparatively small, and do not meet in a sagittal suture, as they do in other *Mammalia*; the supraoccipital, with an interparital bone, being interposed between them, and extending forwards so as to unite with the frontals. Each frontal bone is produced outwards into a great bony plate which covers the orbit. The squamosal bone sends a very large and stout zygomatic process forwards to meet this supra-orbital prolongation of the frontal. The proper jugal bone, on the other hand, which bounds the orbit below, is exceedingly slender. The very large maxilla extends backwards and outwards in contact with the frontal, or even overlapping the greater part of its surface; and it stretches forwards to very near the anterior end of the snout, so that almost the whole of the gape is bounded by the maxilla.

The premaxillæ, on the other hand, though very long, inasmuch as they occupy the whole length of the jaw in the middle line, from the anterior nasal aperture to the end of the snout, are almost entirely excluded from the gape.

The nasal bones are always short; and, sometimes, are mere bony tuberosities united with the frontal bones behind the anterior nasal aperture. The turbinal bones are almost always rudimentary, and the nasal passages are nearly vertical, in consequence, for the most part, of the rudimentary condition and shortness of the nasal bones.

The periotic bones are loosely connected with the squamosal and tympanic, and are usually united with the other bones of the skull only by cartilage, so that they fall out very readily in the dry skull. The tympanic bones are commonly of very considerable size, thick and scroll-shaped.

The lower jaw has hardly any coronoid process, and its ramus has no perpendicular portion, the condyle being

situated upon its posterior extremity. The body of the hyoid is a very broad plate of bone, and has two pair of stout well-ossified cornua.

The *Cetacea* are devoid of clavicles. If the spine of the scapula is present, it is a low ridge situated close to the anterior edge of the bone; but it commonly terminates in a long acromion process, and, sometimes, there is a conspicuous, straight, and flattened, coracoid. The humerus is short, and the articular surfaces at its distal end are, in all recent *Cetacea*, flat facets inclined to one another at an angle. The ulna and the radius are short, laterally compressed bones, without any movement upon one another; and, in all recent *Cetacea*, they are not freely movable upon the humerus. The carpus is often imperfectly ossified. When the carpal bones are complete, they are polygonal and imbedded in a fibrous tissue; not united by articulations provided with synovial membranes. The digits do not exceed five in number, but there are always more than three phalanges in some of them.

The pelvis is represented by two bones which lie parallel with the axis of the vertebral column, give attachment to the corpora cavernosa in the male, and, therefore, probably represent the ischia. They are elongated, convex upwards and concave downwards, and are connected with the vertebral column only by fibrous tissue. In some few *Cetacea* (*Balænoidea*) ossicles, which lie on the outer side of the pelvic bone, appear to represent the femur, but no further indication of a hind limb has been discovered.

In most of the *Cetacea*, the muscles which, in other *Mammalia*, move the antibrachium and the manus, are absent, those which move the humerus upon the shoulder-blade being, alone, represented.

In no recent Cetacean have the teeth any vertical successors, nor more than a single root. The alveoli are often incompletely separated from one another. The number of the teeth varies very greatly, but they are almost always nearly uniform in character. There appear to be no salivary glands. The stomach is complicated, being divided into,

at fewest, three chambers, of which the first is a kind of paunch lined by a thick epithelium, while the second and the third are more elongated, the last stomach being that in which digestion takes place.

The arteries and veins form great plexuses, or *retia mirabilia*, and these are especially conspicuous in the cavity of the thorax, upon each side of the vertebral column, and in the intercostal spaces.

The soft palate is remarkably long and muscular. The epiglottis and the arytenoid cartilages are more or less produced, so as to give the glottis the shape of a funnel, the apex of which is embraced by the soft palate, in such a manner as to form a continuous air-passage from the posterior nares to the larynx, on each side of which the food passes. The very short trachea, before it divides into the bronchi, gives off the so-called "third bronchus" to the right lung, as in the Bears, Walruses and Ruminants.

The kidneys are deeply subdivided into lobules. In the male the testes always remain in the abdomen, and there are no vesiculæ seminales. The penis is devoid of a bone. The uterus of the female is deeply divided into two horns, and the villi of the fœtus are scattered over its chorion, as in other mammals with a diffuse placentation.

The Cetacea are divisible into three groups; the *Balænoidea*, the *Delphinoidea*, and the *Phocodontia*.*

a. In the *Balænoidea* the nasal chambers communicate with the exterior by two apertures, which are capable of being shut at the will of the animal, and are called spiracles. These are not connected with any saccular dilata-tions of the nasal passages, situated between the skull and the integument.

In the spinal column, no rib has a complete neck and capitulum, the heads of even the most anterior ribs being united with the bodies of the vertebræ only by ligament. The chief connection of all the ribs therefore, and the only

* For further information respecting the characters of the recent *Cetacea*, I refer the reader to Prof. Flowers' very valuable memoir "On the Osteology of *Inia* and *Pontopercia*," published in the "Transactions of the Zoological Society for 1867."

connection of most of them, is with the transverse processes of the vertebræ. The short and broad sternum

Fig. 104.

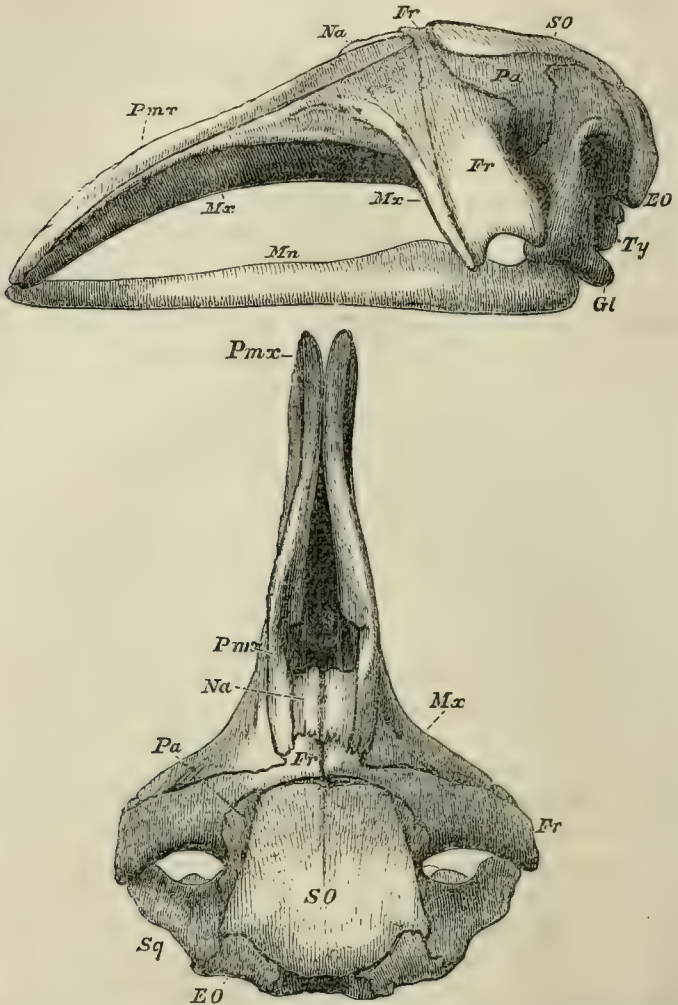


Fig. 104.—Lateral and superior views of the skull of a foetal Whale (*Balæna australis*). The jugal bones are absent, and the figure does not sufficiently indicate the outward curvature of the ramus of the mandible (*Mn*).

unites only with the first rib, and the union is direct, so that there are no sternocostal ribs.

Fig. 105.

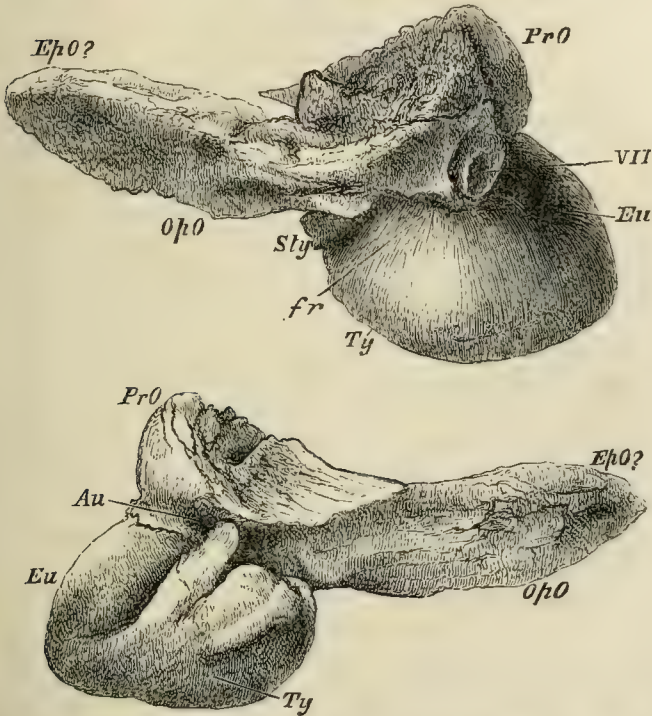


Fig. 105.—“Ear bones” of the adult *Balæna australis*. Seen from within in the upper figure; from without in the lower. *Eu.*, Eustachian canal; *Au.*, external auditory meatus; *Sty.*, ossified root of the styloid process.

The skull (Fig. 104) is exceedingly large in proportion to the body, and nearly symmetrical. The nasal bones, *Na.*, though short, are longer, and more like those of ordinary mammals, than is the case in other *Cetacea*. The maxilla, *Mx.*, extends outwards in front of the great supraorbital process of the frontal, *Fr.*, but it does not cover the frontal bone. There is a distinct lachrymal. Each ramus of the mandible, *Mn.*, is convex outwards and concave inwards;

and the space between the rami of the mandible is very much greater than the width of the maxillo-premaxillary part of the skull, which tapers to its anterior end, and is more or less convex upwards and concave inferiorly. The two rami of the mandible are connected only by ligament at the symphysis.

Minute teeth are developed in foetal *Balænidæ*, but are very soon lost, and their place taken by the so-called *Whalebone*, or *Baleen* plates. Each of these is triangular, with a thick, smooth outer edge, somewhat concave from above downwards, which, in the natural position of the plates, is nearly vertical, and is covered by the great lower lip. The upper edge of the plate, also slightly concave, is attached to a transverse elevation of the gum covering the palate. Vascular papillæ extend from this ridge into cavities of corresponding dimensions, which lie, parallel with one another, in the baleen plate. The third side of the triangular baleen-plate, somewhat convex and sloping from the middle line above, downwards and outwards, gives origin to a number of filamentous processes, into which the baleen appears to be, as it were, frayed out. When the mouth is shut, these frayed edges of the numerous and close set baleen plates, which are longest in the middle of each series, and shortest at each end, enclose a cavity, the bottom of which is occupied by the large and fleshy tongue. By raising the tongue, whatever solid matters are inclosed in the mouth can be forced back into the pharynx and swallowed; while the water in which they were suspended is driven out between the baleen-plates. The Whale feeds by putting this gigantic strainer into operation, as it swims through the shoals of minute molluscs, crustaceans and fishes, which are constantly found at the surface of the sea. Opening its capacious mouth, and allowing the sea water, with its multitudinous tenants, to fill the oral cavity, the Whale shuts the lower jaw upon the baleen plates, and straining out the water through them, swallows the prey stranded upon its vast tongue.

In some of the *Balænoidea*, e. g., *Balæna rostrata*, the

cricoid cartilage and the rings of the trachea are incomplete in front, and a large air sac is developed in the cricothyroid space. The *Balænoidea* possess olfactory nerves and a distinct, though small, olfactory apparatus. The sclerotic coat of the eyeball is enormously thick, and the optic nerve is surrounded by a *rete-mirabile*. The tympanic membrane is connected with the malleus by ligament. The semicircular canals are very small, but the cochlea is large, and makes only $1\frac{1}{2}$ turns. The muscles of the antebrachium and manus are not altogether absent.

The Right Whale (*Balæna*), and the Fin-fishes (*Megaptera*, *Balænoptera*, &c.), belong to this division.

b. In the *Delphinoidea* the nasal chambers open by only a single spiracle on the top of the head; and saccular dilatations, of various dimensions, are developed from the walls of the passage which connects this aperture with the bony naso-palatine passages, and lie between the integument and the outer surface of the skull.

More or fewer of the anterior ribs have heads and necks, the capitula articulating with the bodies of the vertebræ, as in other *Mammalia*. The elongated sternum is, almost always, composed of several pieces arranged in a longitudinal series; and cartilaginous, or ossified, sternal ribs are present in greater or smaller number. The nasal bones, which are very short, and have their upper surfaces tubercle-like, are more or less asymmetrically developed, as are also the maxillæ; so that the facial part of the skull appears distorted. The maxillæ are expanded behind, and cover the orbital process of the frontal bone wholly, or partially. The lachrymal bone is usually small and confluent with the slender jugal, but it may be large and distinct. The rami of the mandible are not arcuated outwards, and they become united in a longer, or shorter, symphysis. The mandible, as a whole, is not sensibly broader than the corresponding portion of the maxillo-premaxillary part of the skull.

Teeth always exist after birth, and are never replaced by baleen plates. They are usually numerous, but sometimes

few and deciduous. Occasionally, only one or two teeth persist, and these, as in the Narwhal, may take the form of immensely elongated tusks.

To this division belong the *Physeteridæ*, *Platanistidæ* and *Delphinidæ*.

The *Physeteridæ* possess functional teeth only in the lower jaw. The asymmetry of the skull is strongly pronounced; and, in the adult, the maxillary and frontal bones are produced, so as to form a sort of basin upon the upper and anterior surface of the skull. The pterygoids meet in the middle line below, and the mandibular symphysis is sometimes extremely long.

The greater number of the cervical vertebræ are ankylosed. The hinder ribs lose their tubercular, but retain their capitular articulation with the vertebræ. The costal cartilages are not ossified. The pectoral limbs are small, and a dorsal fin is usually present.

The proper Sperm Whales (*Physeterineæ*) have an enormous head, with a quadrate, truncated snout, at the anterior superior angle of which the spiracle is placed. The teeth become fully developed only in the lower jaw. The cranial basin is immense, and is filled by a loose connective tissue, in which the peculiar fat known as *spermaceti* is contained. Ambergris is a sort of bezoar, found in the alimentary canal of the Cachalot, and seemingly derived from the fatty matter contained in the *Cephalopoda* on which the Cetacean feeds. In the other group of the *Physeteridæ*—the *Ziphiinae* or *Rhynchoceti*—to which the Bottlenosed Whale (*Hyperoodon*) belongs, there are only one or two pairs of fully formed teeth in the mandible. Some recent and many fossil (middle and later tertiary) genera of these Cetaceans are remarkable for the elongated rostrum formed by the solid ossification and ankylosis of the ethmoid, premaxillæ and maxillæ.

The *Platanistidæ* are fluviatile or estuarine *Cetacea*, which occur in the Ganges and in the rivers of South America. The cervical vertebræ are not ankylosed, and the costal cartilages are not ossified. The tubercula and capitula of the

Fig. 106.

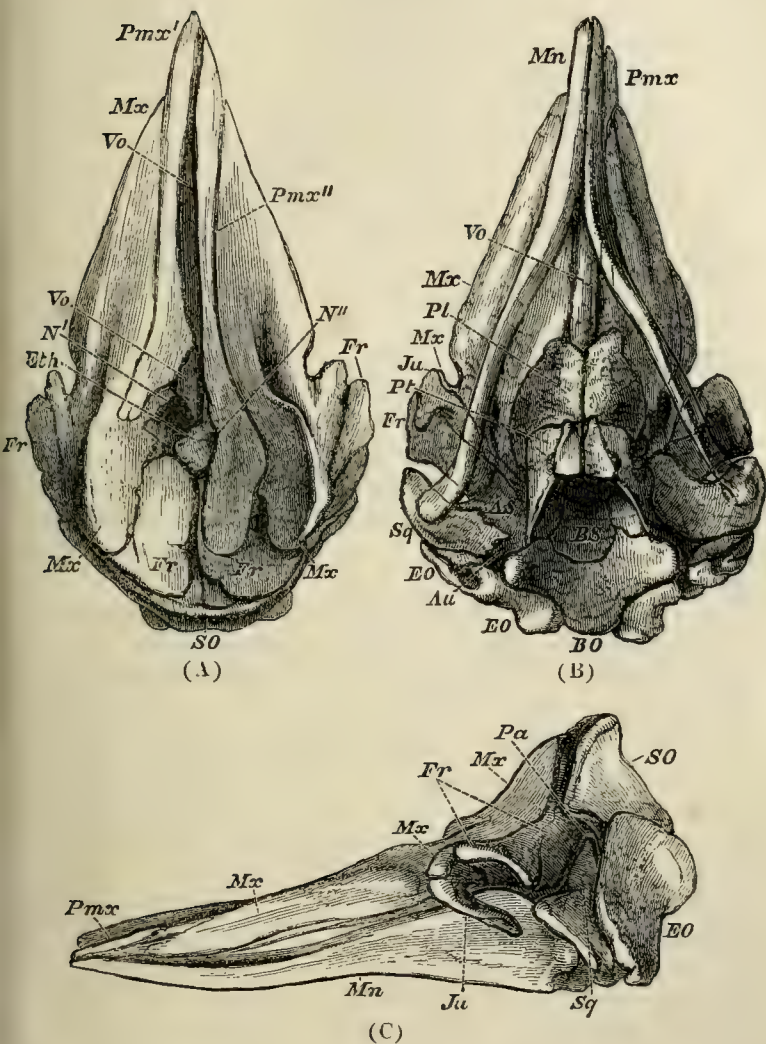


Fig. 106.—Upper (A), under (B), and lateral (C) views of the skull of a fœtal Cachalot (*Physeter*). The nasal bones are not represented in the upper view, and the hinder end of the jugal is displaced from its natural connection with the squamosal in (C).

ribs blend together posteriorly. The symphysis of the mandibles is extremely long and the jaws are narrow. Numerous teeth with compressed fangs are found in both jaws. The eyes are small, and in *Platanista* they are rudimentary.

In the *Delphinidæ* lastly (Dolphins, Porpoises, Grampuses), the teeth are usually numerous in both jaws, though the Narwhal is an exception to this rule, as has already been mentioned.

The anterior cervical vertebræ are generally ankylosed together. The posterior ribs lose their capitula and become articulated only with the transverse processes of the vertebræ. The costal cartilages are well ossified. The symphysis of the mandible does not exceed one-third of the rami in length, and the frontal and maxillary bones are not especially produced upwards at their edges.

As the common Porpoise (*Phocæna communis*), which is a member of this group, is the Cetacean which is most likely to come within reach of the student, it may be useful to speak at some length of its more interesting anatomical peculiarities.

The adult animal is usually about five feet long, and is covered with a smooth integument upon which no hair is to be discovered, though a few hairs are visible about the mouth in the young animal. The contour of the anterior part of the head is very convex, and presents, in the middle line, the spiracle or blow-hole, which has the form of a crescent with the points turned downwards and forwards. The eyes are small and placed low down, close to the posterior end of the gape of the mouth, which is bounded by dense and rigid lips. The aperture of the ear lies about an inch and three-quarters behind the eye, and is so minute as to be discovered with difficulty. The genital aperture is placed a long way in front of the anus in the male; while, in the female, the interval, in which the fossæ which lodge the teats are situated, is much less. There is a conspicuous vertical dorsal fin in addition to the flattened caudal fin. Immediately beneath the skin is a thick layer of blubber, as in other *Cetacea*.

In the spongy texture of all the bones, the absence of medullary cavities in those of the limbs, and in the long persistent separability of the epiphyses of the centra of the vertebræ, the Porpoise resembles other *Cetacea*; as it does in the shortness of the cervical, and the length of the lumbar, region of the spinal column.

The seven cervical vertebræ are all ankylosed together, and the atlas, which is very large in proportion to the rest, overlaps them above and at the sides. The centra of the hinder cervicals are so short and broad that they are mere plates of bone. There are twenty-eight dorso-lumbar vertebræ, of which fifteen are dorsal. In all but the most anterior of these vertebræ, the zygapophyses are abortive; and long accessory processes, developed from the front part of the neural arches, loosely embrace the spine of the vertebra in front. This arrangement, together with the thickness of the intervertebral ligaments, gives great flexibility to the spinal column. The transverse processes of the hinder dorsal, and of the lumbar, vertebræ are very long. There are five pairs of true ribs. The sternæ ankylose into an elongated sternum. The anterior caudal vertebræ are provided with large chevron bones, and their transverse processes exhibit notches through which branches of the aorta pass.

In consequence of the globular form of the brain-case, and the prolongation of the jaws, the skull has a flask-like shape. There is a slight want of symmetry about the base of the upper jaw, but it is hardly appreciable.

In a longitudinal section, the flatness and the upwardly concave contour of the base of the skull; the extreme shallowness of the *sella turcica*; the presence of an ossified tentorium; and the broad imperforate anterior wall, in the place of the cribriform plate of the ethmoid, are striking features. The synchondrosis between the basi- and presphenoid is persistent. On the base of the skull the basi-occipital gives off great processes outwards and downwards, to form, together with a paramastoid prolongation of the exoccipital, and the squamosal, a chamber in which the

ankylosed tympanic and periotic bones are contained. The ex- and supra-occipitals, together with the interparietals, form the whole back wall and middle of the roof of the cranium, separating the parietals completely, and the frontals largely, and reaching the nasal bones.

The basi-sphenoid is ankylosed with the small and almost horizontal alisphenoids, and there are no sphenoidal pterygoid processes. The parietals are small, and occupy only the under and lateral portions of the brain-case. The frontal bones are very broad and expanded, and are completely ankylosed together, where they form the front wall of the brain-case. Posteriorly and above, they diverge to receive the interparietal. The supra-orbital processes are extremely large, and are directed forwards and outwards, not backwards and outwards, as in the Whalebone Whales. The greater part of the superior surface of the frontals and of their orbital processes is rough and covered over by the expanded maxillary bones, which allow only a narrow, transverse, smooth, band-like surface, formed by the frontals, to be seen on the upper and anterior region of the skull. The rough surface is marked by two shallow grooves which pass from below upwards, and are convex towards one another and to the middle line. Corresponding grooves exist on the under side of the expanded proximal ends of the maxillaries; and when these are in their natural positions, the coadapted grooves form two canals, which are blind in front and above. These, in the natural state, are full of air and communicate with the air chambers at the base of the skull and with the Eustachian tubes.

The narrow premaxillæ are ankylosed with the inner margins of the maxillæ, and contribute only a very small portion of the alveolar margin of the upper jaw. The alveoli are not completely separated from one another. The pterygoid bones do not unite in the palate. They have a peculiar excavated form, and are notched for the passage of the ends of the Eustachian tubes into the nasal passages. These are nearly vertical and are separated by the large and strong vomer. Their superior apertures are left quite

uncovered in consequence of the small size, tubercular form, and backward position of the nasal bones. The squamosal is relatively small, but has the characteristically cetacean, large, zygomatic process; this extends forwards nearly to the posterior end of the supra-orbital process, and gives attachment to the slender jugal.

The periotic bones form a dense osseous mass, which is ankylosed with the no less heavy and thick, scroll-shaped, tympanic. The *pars mastoidea* of the periotic mass fits pretty accurately into a recess of the chamber which has already been described; and is thus held in position in the dry skull, though it is very easily detached.

When the *tympano-periotic* bone and all the facial bones are removed, only two pair of foramina are visible in the base of the skull. The anterior pair give exit to the second, third, fourth, the anterior division of the fifth and the sixth nerves, and these answer to the optic and sphenorbital foramina. The posterior pair take the place of the oval, posterior lacerated, and jugular foramina, and the precondyloid foramina open into them posteriorly. The rami of the mandibles are only united by a short symphysis. The body of the hyoid is broad and hexagonal, and has two slender, anterior, and two broad and flat, posterior, cornua.

In the natural position the fore limbs stand out from the body with their flat surfaces looking upwards and downwards; the upper surface being directed a little backwards, and the lower, a little forwards. The tuberosity of the short humerus is directed forwards. The carpus contains six or seven ossifications. The number of phalanges in the digits is two, eight, six, three, two, counting the pollex as the first.

The pelvic bones are elongated, slightly curved, osseous styles. They lie with their long axes parallel to the vertebral column, their convex sides upwards, and their smaller ends forwards, within an inch of the centra of the vertebræ, their hinder ends being close to the third chevron bone of the tail. The front ends are about an inch apart. Behind its centre, each bone presents a flattened thickening for the attachment of the corpus cavernosum of its side.

The cutaneous muscle is very largely developed and lies between two layers of blubber, the thick superficial one separating it from the skin, and the thin deep layer from the subjacent muscles. It may be said to be disposed in two broad layers, a dorsal and a ventral, on each side; these extend from the occipital crest, and from the rami of the mandibles, to the tail. Both these divisions send off strong bundles to the humerus, which act as powerful adductors, abductors, protractors, and retractors of the fin. There is no *trapezius*, and the representative of the *latissimus dorsi* is very small. A strong *occipito-humeralis*, from the parmastoid to the tuberosity of the humerus, seems to represent the cleido-mastoid and clavicular deltoid. A *costo-humeralis* extends from the sternum to the inner tuberosity of the humerus. A small *coraco-brachialis* extends from the apex of the coracoid to the inner tuberosity of the humerus. The *pectoralis major* seems to be represented by a muscle which arises from the sternum, close to the attachment of the third and fourth ribs, and is inserted into the ulna. The *triceps extensor* is represented by tendinous fibres in which muscle cannot always be detected, which extend from the posterior face of the humerus to the ulna. The other muscles of the fore-arm and all those of the manus are absent. The dorsal muscles form a thick continuous mass from the end of the tail to the occiput; and, on the ventral side of the spinal column, the subcaudal muscles are similarly continued forwards, as far as the middle of the thorax. An *ischio-caudalis* passes, on each side, from the anterior chevron bones to the ischium. Between their attachments is an aponeurosis which supports the anus; ischio-cavernous muscles pass from the ischia to the *corpora cavernosa*.

The diaphragm has no tendinous centre. Its pillars are very thin, and, extending between the kidneys and the spine, become tendinous, and are attached to the ventral faces of the vertebræ, as far as the ninth lumbar. A strong fibrous aponeurosis is continued back over the subvertebral muscles to the pelvic bones. Between these bones and the ends of

the transverse processes of the twenty-eighth and twenty-ninth vertebræ (counting from the first dorsal) the aponeurosis is so stout as to form an almost distinct fibrous band, which occupies the place of an ilium. The ureter lies between the ischio-vertebral fascia and the peritoneum.

The teeth are small and numerous, and their crowns are obtuse and constricted. The passage of the pharynx is divided in the middle, the soft palate being prolonged into a muscular funnel, the opening of which closely fits the constricted neck of the long cone into which the epiglottis and the arytenoid cartilages are produced. Thus the arrangement which is transitory in the Marsupial is permanent in the Cetacean.

The stomach is divided into three sacs. The first is large, conical, and lined by a coarse white epithelial coat. The gullet opens directly into it. The second stomach communicates with the first by an aperture which is close to the cardiac end of the gullet, and is surrounded by a very prominent rugose lip. A curved passage about one inch long and capable of admitting the finger, lined by a white epithelium similar to that of the first, leads into the second stomach. The second stomach is lined by an extremely vascular and soft mucous membrane, with about ten strong longitudinal folds, separated by deep sulci, interrupted by transverse ridges. A narrow and curved canal leads from this into the third stomach, which has a tubular form and is bent upon itself. Its lining membrane is quite smooth. A small, circular, pyloric aperture places this in communication with the dilated commencement of the duodenum, which has sometimes been regarded as a fourth stomach. Its lining membrane presents longitudinal rugæ continuous with those of the duodenum itself. The conjoined pancreatic and biliary ducts open just beyond the dilated part of the duodenum. There is no cœcum, or demarcation between the large and small intestines. The bilobed liver has no gall bladder.

In the heart the fossa ovalis is distinct, but there is neither Eustachian nor Thebesian valve. The vena cava

inferior is long and wide, but is not especially dilated near the heart. Muscular fibres are not continued on to it from the diaphragm. The aorta and pulmonary arteries are not dilated at their origins. The arteries have a great tendency to break up into plexuses. Thus the internal carotids form great networks which communicate with vertebral plexuses, extending throughout the entire spinal canal. The brachial artery divides into two branches, and these subdivide into innumerable parallel twigs. The intercostal arteries are the chief source of the large thoracic plexuses, which lie at the sides of the vertebral column in the dorsal half of the thorax. Finally, an arterial *rete mirabile* surrounds the caudal aorta. The veins form plexuses corresponding to, and mixed up with, those of the arteries; and a very large venous plexus lies on the subvertebral muscles in the abdomen and thorax.

The respiratory apparatus of the Porpoise presents many remarkable peculiarities. The contour of the front part of the head, as bounded by the integument, is very convex—the corresponding facial region of the skull, on the contrary, is very concave. The interval between the two is occupied, in part, by fibrous and fatty tissue; and, in part, by a singularly sacculated *spiracular chamber*, which connects the single spiracle with the double external nares of the skull. Two valves, an anterior and a posterior, lie immediately above these external nares and close the communication between them and the chamber, except at such times as it is forced open from below. Each nasal passage remains distinct from the other as far as the valves, the middle of each of the latter being fastened to the septum, so that there may be said to be a pair of valves for each opening between the passages and the spiracular chamber. Each nasal passage, after it ceases to be surrounded by bone, sends off two diverticula, one forwards and one backwards. The anterior, which lies between the anterior valve and the premaxilla, is a simple sac, lined with a thin, black, smooth membrane. The posterior diverticulum lies between the posterior valve and the ethmoid and nasal bones. It is incompletely

divided by a sort of shelf, is prolonged forwards, round, and in front of, the anterior valve, and ends blindly in the middle line above the anterior sac. The spiracular chamber itself is produced, on each side, into a large lateral sac, the walls of which are raised in strong parallel ridges, and covered with a black papillose integument. The walls of these sacs are strong and elastic. Layers of muscular fibres pass from the occipital ridge to the posterior lip of the spiracle, and from the edges of the maxillæ to its anterior lip. Their action is necessarily to open the spiracle and compress the sacs. There is no sphincter, the form of the spiracle causing it to be naturally shut by the fitting together of its walls, and the pressure of the water upon them.

When a Porpoise comes to the surface to "blow," the shape of the posterior, concave, lip of the crescentic spiracle does not sensibly alter; but the anterior, convex, lip is pulled downwards and forwards, its surface becoming somewhat depressed, and its free edge nearly straight—so that the aperture, when fully dilated, assumes the form of a half-moon. At the same time, the air is expelled with a rushing sound. The inspiratory act must be very rapid, as the spiracle remains open for only a very short time after expiration ends. When the larger *Cetacea* come up to breathe, the expired vapour suddenly condenses into a cloud; and, if expiration commences before the spiracle is actually at the surface, a certain quantity of spray may be driven up along with the violent current of the expelled air. This gives rise to the appearance termed the "spouting" of Whales, which does not arise, as it is commonly said to do, from the straining off of the sea-water swallowed with the food, and its expulsion by the nostrils.

The epiglottis, in front, and the arytenoid cartilages behind, are prolonged into a tapering tube, dilated at its summit into a knob. The muscular soft palate embraces the neck of this knob so closely that it cannot be withdrawn without considerable effort. And thus, during life, the nasal air-passages and the glottis are kept perfectly continuous; while the Porpoise dashes through the water, open mouthed,

after its prey. The point at which the extra bronchus to the right lung is given off is separated by four rings from the bifurcation of the trachea. The lungs are not lobed and their tissue is very dense and elastic.

The cerebral hemispheres are, taken together, broader than they are long. In the upper view they leave not more than a seventh of the length of the cerebellum exposed, while they overlap it largely at the sides. The outer surface of the hemispheres is extremely convoluted, the gyri being numerous and separated by deep sulci. There is a well-marked Sylvian fissure, with a central lobe, or insula. A rudiment of a posterior cornu has been observed in the lateral ventricle. The corpus callosum is small, relatively to the size of the hemispheres, and the anterior commissure is almost obsolete. The medulla oblongata has *corpora trapezoidea*. The olfactory nerves are wanting—a circumstance which agrees with the entire absence of ethmoidal turbinals. The eye has a thick sclerotic, and there is a choanoid muscle; no nictitating membrane is present.

The external auditory aperture is so small as to be easily overlooked. The meatus auditorius is a narrow undulating tube about two inches long. The tympanic membrane is concave externally; and, as is usual in the *Cetacea*, is connected by a ligament with the handle of the malleus. There is only a small aperture in the stapes. The *tensor tympani* arises, as in Carnivores, from a fossa in the periotic ossification.

The Eustachian tube passes through the notch in the pterygoid and opens into the nasal passage on the inner side of that notch. Close to its commencement it communicates, by an oval aperture, with a remarkable air chamber, which extends backwards between the periotic mass and the *basis cranii*, and forwards to the under side of the expanded part of the maxilla, where it opens into the canal between the maxilla and the frontal already described. These chambers, like the bronchi, are generally full of nematoid worms. The testes and penis of the male are enormous in proportion to the size of the body. The penis

is devoid of a bone, and, ordinarily, is bent up in the long preputial sheath.

c. The *Phocodontia* are represented only by *Zeuglodon*, *Squalodon*, and other large extinct cetaceans of the tertiary epoch. These remarkable fossil forms constitute connecting links between the *Cetacea* and the aquatic *Carnivora*. The cervical vertebræ are distinct and unankylosed, nearly resembling those of the *Rhyncoceti*. The caudal vertebræ have their transverse processes perforated vertically, as in many *Cetacea*. The distal ends of the ribs are enlarged somewhat as in the *Sirenia*. The skull is symmetrical, and the nasal bones, though still short, are longer than those of any other cetacean. The zygomatic processes of the squamosal are large and thick, and the supraorbital processes of the frontals wide and expanded as in the *Cetacea*.

The scapula appears to have had a spine and acromion like that of *Manatus*. The humerus is compressed from side, and has true articular surfaces upon its distal end, although they are of small size.

The molar teeth have laterally compressed crowns with serrated edges and two fangs, resembling those of many seals, and *Zeuglodon* differs from all the other *Cetacea* in the circumstance that some of its teeth have vertical successors.

The DECIDUATE MAMMALIA.—These may be subdivided according to the form of the placenta, into two groups: the *Zonaria* and the *Discoidea*. In the former the placenta surrounds the chorion like a hoop, leaving its ends free of villi, or nearly so.

In the *Discoidea*, on the other hand, the placenta takes the form of a thick disc, which is sometimes more or less lobed.

The mammalia which possess a zonary placentation are the *Carnivora*, the *Proboscidea*, and the *Hyracoidea*.

Each of these divisions is very closely related to one of the foregoing. Thus the *Carnivora* approach the *Cetacea*; the *Proboscidea*, the *Sirenia*; and the *Hyracoidea*, the *Ungulata*.

The ZONARIA. 1. The CARNIVORA.—In this order the head, relatively to the body, is of moderate or small size; and hair is abundant.

The cervical vertebræ are free and unankylosed, and their centra are elongated. The odontoid process of the second is well developed. The dorso-lumbar vertebræ are almost always twenty in number, rarely twenty-one or nineteen. The number of dorsal and lumbar vertebræ, respectively, varies between sixteen dorsal and four lumbar, and thirteen dorsal and seven lumbar. The dorso-lumbar vertebræ are always articulated together by their zygapophyses, and there is a complete sacrum.

The sternæ are numerous and laterally compressed.

In the skull the nasal bones are well developed, and have the ordinary form. When supraorbital enlargements of the frontal exist, they are of moderate size. The parietals unite in a long sagittal suture. The orbit and the temporal fossa communicate freely, the posterior boundary of the orbit never being completed by bone. The jugal bone is large and unites by a broad surface with the maxilla. There is a distinct coronoid process, and the long axis of the articular surface which receives the head of the mandible is transverse.

The hyoid has a small body and many-jointed anterior cornua.

Both pairs of limbs are fully developed, and the tail is not provided with a horizontal fin. Clavicles may be absent, and, when ossified, they do not occupy more than half the interval between the acromion and the sternum. The scapula has a distinct spine, and a large supra-spinous fossa.

Neither the hallux nor the pollex are opposable. The carpal and tarsal bones have the ordinary number and arrangement; except that, in the carpus, the *scaphoid* and *lunare* are united into one bone. The terminal phalanges of the digits, which never fall below four in number, are almost always provided with sharp and pointed claws.

The teeth are always distinguishable into incisors, canines and molars; they are lodged in distinct sockets, and their

crowns are covered with enamel. There are always two sets of teeth, a milk and a permanent dentition. As a very general rule, there are six incisors above and an equal number below. The canines are long, curved, and pointed.

The stomach is simple and undivided, and the cœcum, which is never large, may be altogether absent.

The liver is deeply subdivided and there is a gall bladder.

In the brain, the cerebellum is never completely covered by the cerebral hemispheres, which are connected by a large corpus callosum, and, except in the aquatic forms, by a well-developed anterior commissure. On the exterior of each hemisphere, there are usually three distinct convolutions surrounding the sylvian fissure. But, in the aquatic *Carnivora*, the gyri are much more numerous and complicated; the cerebral hemispheres are much broader and longer in proportion to the length of the brain; and they may even exhibit a rudiment of the posterior cornu. In all these respects they approach the *Cetacea*.

The inferior turbinal bones are always large and have a complicated form.

There are no vesiculæ seminales, and an *os penis* is very generally present. The ovary is inclosed in a peritoneal sac.

The *Carnivora* are divisible into the *Pinnipedia*, or aquatic Carnivores; and the *Fissipedia*, which are mainly terrestrial and cursorial.

a. In the *Fissipedia* the incisors are, with one exception (*Enhydris*, the Sea-otter, with $i. \frac{3 \cdot 3}{2 \cdot 2}$), six in number in each jaw.

The hind limbs have the position usual in mammals, and the tail is free to its root. The pinna of the ear is fully developed. The middle, or outermost, digits of the pes are longest, the hallux being shorter than the others.

Almost invariably, the distal phalanges of both limbs are provided with claws; and, in the most thoroughly carnivorous forms, these claws are very strong, curved and pointed. The phalanx which supports the claw has a similar form, and a

plate of bone rises from its base as a short sheath. An elastic ligament connects the base of the unguis phalanx

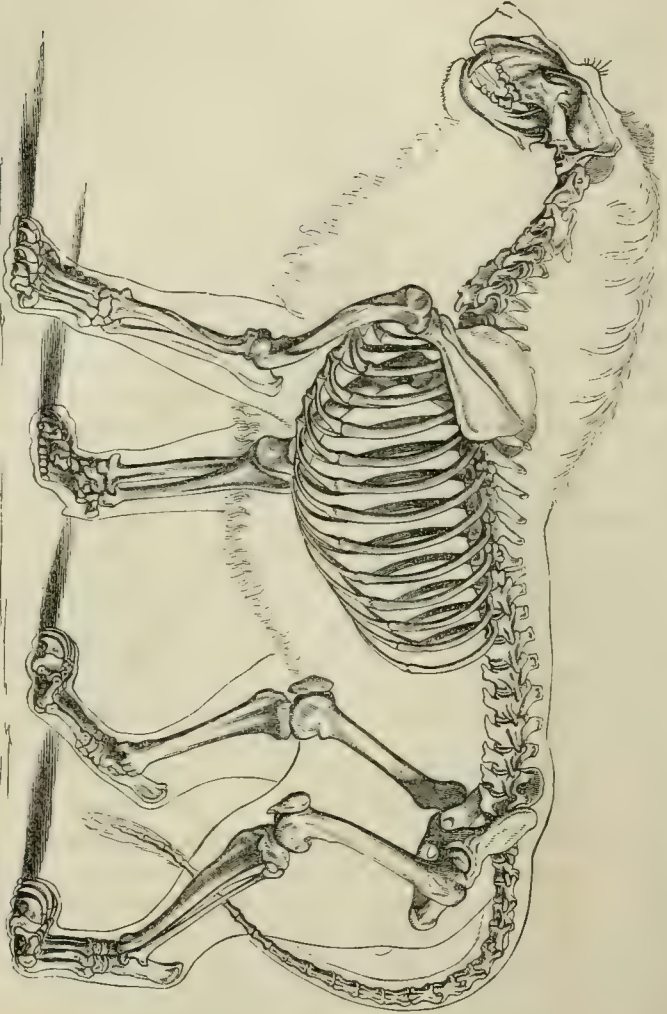


Fig. 107.—Skeleton of the Lion (*Felis leo*).

Fig. 107.

with the middle phalanx, so that when the *flexor profundus digitorum* is not in action, the unguis phalanx is pulled back upon the middle phalanx, and the claw which it bears is retracted into an integumentary sheath.

The olfactory lobes are usually large and the cerebral hemispheres elongated.

As the Dog (*Canis familiaris*) is an excellent and easily accessible example of a fissipede carnivore, it may be useful to mention some of the more important points in its anatomy.

The vertebral column contains twenty dorso-lumbar vertebræ, of which thirteen are dorsal and seven lumbar, three sacral, and eighteen to twenty-two caudal vertebræ. The atlas has broad and rounded alæ, the anterior margins of which are deeply excavated near the roots. The posterior edge of the spinous process of the axis vertebra is almost perpendicular and very thick.

Nine pairs of ribs are usually connected by sterno-costal cartilages with the sternum, which is composed of eight laterally-compressed sternibræ. Only two of the three ankylosed sacral vertebræ articulate with the ilia.

As in the *Carnivora* in general, the occipital foramen is placed at the posterior end of the skull, and looks almost directly backwards. The sagittal and lambdoidal crests are greatly developed and meet in a prominent occipital spine; the zygomata are very wide and arched outwards; and the coronoid process of the mandible is very large. The size of these parts is in relation to the magnitude of the muscles of the neck and jaws.

The ramus of the mandible is nearly straight, the proper angle of the jaw being obsolete. A supra-angular process projects outwards from the ascending portion of the ramus, and takes the place of the proper angle. The articular condyle is much elongated transversely, narrow and convex from before backwards; and the pre- and post-glenoidal processes of the squamosal are produced downwards so as to convert the joint into a complete ginglymus and to restrict

the motion of the jaw to the vertical plane. The supra-orbital processes of the frontals are small and pointed. The root of the alisphenoid is traversed by a longitudinal canal. The tympanum is bounded below by a convex osseous wall, which is termed the *bulla*. It opens externally by the short external meatus, at the inner end of which is a circular elevation for the attachment of the tympanic membrane. A short distance internal to this frame for the membrane of the drum, a low crest rises from the floor of the bulla and imperfectly divides it into an outer and anterior portion which communicates with the Eustachian tube, and an inner blind spheroidal cavity which occupies the greater part of the bulla. The part of the bulla which forms the floor of this cavity is the result of the ossification of a process of the periotic cartilage, while the other part is furnished by the tympanic bone. The low crest is produced by the conjunction of both. Posteriorly and internally, the periotic region of the bulla presents a canal, through which the internal carotid artery passes. The posterior opening of the carotid canal looks into the *foramen lacerum posticum*, and is not visible without dissection. There is a large paroccipital process, with a prominent free extremity; but, for the greater part of its length, it is closely applied to the back of the bulla. The condyloid foramen is quite distinct from the *foramen lacerum posterius*. A large foramen behind the glenoidal cavity transmits a vein from the interior of the skull. In the nasal cavity, the ethmoidal turbinals are very large; the superior turbinals are prolonged into the great frontal sinus, and the inferior turbinals unite, in the middle line, with the septum.

The clavicles of the Dog are always rudimentary and are generally represented only by a gristly intersection of the muscles which represent the sterno-mastoid and deltoid.

The olecranon fossa of the humerus is perforated. The hallux is much shorter than the other digits. When the Dog stands, the metacarpal bones of these digits are nearly vertical; the basal phalanges are horizontal; the middle and the distal phalanges are inclined in the form of

a V with the apex (the articulation between the two) downwards. The claws are, consequently, raised from the ground, the foot resting partly on a thick integumentary pad, which lies beneath the basal phalanges; and, partly, on the under surfaces of the joints between the middle and the distal phalanges. The distal phalanges are kept bent upon the middle ones by elastic ligaments, which pass from one to the other, and which antagonise the action of the long flexors. The Dog, therefore, possesses the mechanism for the retraction of the claws, but its action is not sufficient to protect them from wear. *Fabellæ*, or sesamoid bones developed in the tendons of the *gastrocnemius*, lie behind the condyles of the femur. The fibula is thin and closely applied to, but not ankylosed with, the tibia. The hallux is usually rudimentary; only the metatarsal, and the basal phalanx, being represented by two small ossicles. In some breeds of dogs, however, the hallux is fully developed.

In the myology of the Dog the insertion of the tendon of the external oblique muscle of the abdomen presents some interesting peculiarities. The outer and posterior fibres of this muscle end in a fascia which is partly continued over the thigh as *fascia lata*, and partly forms an arch (Poupart's ligament) over the femoral vessels; by its inner end it is inserted into the outer side of a triangular fibro-cartilage, the broad base of which is attached to the anterior margin of the pubis, between its spine and the symphysis, while its apex lies in the abdominal parietes. The internal tendon of the external oblique unites with the tendon of the internal oblique to form the inner pillar of the abdominal ring, and is inserted into the inner side of the triangular fibro-cartilage. The *pectineus* is attached to the ventral face of the cartilage; the outer part of the tendon of the rectus into its dorsal face; but the chief part of that tendon is inserted into the pubis behind it. This fibro-cartilage appears to represent the marsupial bone, or cartilage, of the Monotremes and Marsupials.

The *trapezius* and the *sternomastoid* coalesce into a single

muscle; and, in the absence of a complete clavicle, the outer fibres of the latter and those of the anterior part of the deltoid are continuous. In this way a muscle which has been called *levator humeri proprius* is formed. The *omohyoid* and the *subclavius* are absent. There is a *trachelo-acromialis* and a *dorso-epitrochlearis*. The *supinator longus* is absent, but there is a *pronator quadratus*. The *extensor communis digitorum manus* divides into four tendons, in which sesamoid bones are developed over the articulations between the first and second phalanges. The *extensor primi internodii pollicis* is absent. The *extensor secundi internodii* is one muscle with the *extensor indicis*. The *extensor minimi digiti* sends tendons to the third, fourth, and fifth digits. All these deep extensors have sesamoid bones over the metacarpo-phalangeal articulations. The *palmaris longus* appears to be absent; but all the other flexors of the manus, even the *palmaris brevis*, are represented. The tendons of the *flexor pollicis longus* and *flexor digitorum perforans* are united. The divisions which the common tendon sends to the five digits develop sesamoid bones, just before their insertions into the bases of the distal phalanges. The fifth digit has its *abductor*, *flexor brevis*, and *opponens*; the pollex, an *abductor*, *adductor*, *flexor brevis*, and, perhaps, an *opponens*. The second, third, and fourth digits have each a pair of *flexores breves*, which represent the *interossei*, and are inserted into the bases of the proximal phalanges, a relatively large sesamoid being developed in each. Each sends off a fine tendon dorsad to the extensor sheath. The *plantaris* is large, and, as in the Pig, its tendon passes into the representative of the *flexor brevis digitorum pedis*. The tendons of the *flexor hallucis longus* and *flexor perforans* unite into a common tendon, which subdivides into slips for the digits.

The dental formula of the Dog is $i. \frac{3 \cdot 3}{3 \cdot 3} c. \frac{1-1}{1-1} p.m. \frac{4 \cdot 4}{4 \cdot 4}$
 $m. \frac{2 \cdot 2}{3 \cdot 3} = 42$. The two upper inner incisors, on each side, have distinctly trilobed crowns—the lateral cusps of the crown arising from outgrowths of the *cingulum* at its base. The

outer incisor is larger than the others, and its middle cusp is very large, while the outer is rudimentary. The large canine has a strong, curved, pointed crown, with a longitudinal ridge along its posterior face. The crowns of the anterior three premolars are triangular, with a smooth-cutting anterior edge; the hinder edge is also sharp, but is divided by a notch into two lobes, of which the hinder is the smaller. These teeth are two-fanged. The fourth premolar is a large tooth. In form, its crown has a general similarity to that of the foregoing; but, firstly, the posterior lobe is relatively much larger, and pointed, so as to form an obvious second cusp; and, secondly, a strong process of the crown projects inwards from its anterior end, and is supported by a distinct fang—so that this premolar is three-fanged. It is termed a *carnassial*, or *sectorial*, tooth, as it bites like a scissor-blade against a corresponding tooth in the mandible. The preceding teeth have cutting crowns; but those of the molars are broad and crushing. They exhibit an outer division, formed by two large subequal cusps, and an inner division, also presenting two cusps, the posterior of which is much smaller than the anterior. In addition, the cingulum sends up a strong process on the inner side of the crown.

In the lower jaw, the crowns of the incisors, the outer of which is the largest, are all trilobed. The outer cusp is stronger than the inner in all, and particularly in the outer incisors. The canines resemble those of the upper jaw. Each premolar has two fangs and a sharp triangular crown, the posterior edge of which is trilobed, as in the upper premolars; but the posterior lobe is small in the fourth, which differs but little from the rest. The first molar, on the other hand, is a large tooth, with a blade-like crown, which bites against the inner side of the upper fourth premolar, and is called the *carnassial* or *sectorial* tooth of the lower jaw. The crown is elongated, and presents a large anterior external cusp, divided into two lobes by a deep notch. On the inner side of this is a small internal cusp. The two posterior cusps are very much lower than

the anterior ones, and form a sort of heel to the blade-like anterior portion of the crown. An oblique ridge connects the outer and larger of the two posterior cusps with the small inner and anterior cusp. The second molar has a broad quadricuspidate crown, the inner posterior cusp being almost obsolete. The crown of the last molar is small, simple, and obtusely conical.

It thus appears that the *sectorial*, or *carnassial*, teeth in the two jaws differ in their nature, the upper being the last premolar, and the lower the anterior molar. The milk dentition of the Dog is *d.i.* $\frac{3 \cdot 3}{3 \cdot 3}$ *d.c.* $\frac{1 \cdot 1}{1 \cdot 1}$ *d.m.* $\frac{3 \cdot 3}{3 \cdot 3}$, the "first premolar" of the adult dentition having no deciduous predecessor; so that, in this, as in so many other cases, it is doubtful whether it ought to be counted in the milk, or in the adult, dentition. The middle deciduous molar in both jaws resembles the hindermost premolar of the adult dentition, and the hindermost, the first molar of the adult. The so-called "first premolar" of the adult, and the anterior molars, appear before any of the deciduous molars are shed.

The cœcum of the Dog is long, and folded upon itself, in which respects it is unlike that of other Carnivores. The arch of the aorta gives off an anomya and a left subclavian.

In the brain, the olivary bodies are inconspicuous, the *corpora trapezoidea* large, and the *corpora mammillaria* distinctly double. The olfactory lobes are very large, and expand posteriorly on the sides of the brain into a broad mass continuous with the *gyrus uncinatus*, or hippocampal lobule. The cerebral hemispheres extend for a considerable distance over the cerebellum, in the upper view, and overlap it laterally. The Sylvian fissure does not extend more than half-way to the median fissure. The surface which answers to the *insula* is quite smooth. The anterior ends of the calloso-marginal sulci pass on the upper surfaces of the hemispheres, and give rise to the "crucial" sulcus. There are three principal gyri upon the outer surfaces of the hemispheres; one which immediately bounds the Sylvian

fissure, one which runs along the upper margin of the hemisphere, and one between these two. The corpus callosum is long, and the anterior commissure well developed.

There is a *musculus choanoides* in addition to the usual ocular muscles, and the rudimentary nictitating membrane is said to possess a muscle.

The *tensor tympani* arises from a deep pit above the promontory, and its tendon passes directly outwards to the *malleus*.

The male is devoid of Cowper's glands. The penis has a bone, and the glans becomes swollen during copulation, so as to prevent the withdrawal of the penis from the vagina of the female. The ovary of the female is enclosed in a sac of the peritoneum, and the uterus has long cornua. The umbilical sac is drawn out to a point at each end.

The Dogs (including the Wolves, Jackals, and Foxes under this head) form the most central group of the Carnivora, which may be termed the *Cynoidea*.* From these the Bears, Weasels and *Procyonidæ* depart, on the one hand, and the Cats, Civets, and Hyænas on the other. The former group (*Arctoidea*) have the cavity of the *bulla tympani* undivided by a septum. The paroccipital process is not applied to the posterior wall of the *bulla*. The mastoid process is widely separated from the paroccipital. The condyloid foramen is not merged in a common opening with the *foramen lacerum posticum*. The intestinal canal is devoid of a cœcum. The large penis has a bone which is not grooved; there are no Cowper's glands, and the prostate is small.

In the latter group (*Ailuroidea*) the *bulla tympani* is large and rounded, and the septum, which is rudimentary in the *Cynoidea*, is so much enlarged as to leave only a narrow aperture of communication between the two chambers. The paroccipital is closely applied to the posterior wall of the *bulla*. The mastoid process is often obsolete. The con-

* See Professor Flower's important memoir on the Classification of the *Carnivora* in the Proceedings of the Zoological Society for 1869.

dyloid foramen opens into a fossa common to it and the *foramen lacerum posticum*. All have a short cœcum. The penis is small, and its bone small, irregular, or absent. They have Cowper's glands and a well-developed prostate.

The *Cynoidea* are all digitigrade, and resemble the Dog in their dentition. The *Arctoidea* are plantigrade, while the *Ailuroidea* are for the most part digitigrade, but may be plantigrade. In dentition, each of these groups presents forms such as the Bears on the one hand, and the Cats on the other, which may be regarded as extreme modifications, in opposite directions, of the type exhibited by the Dog.

In the Bears, the dental formula is the same as in the Dogs, but the crowns of the teeth are all more obtuse. The *sectorial* teeth lose their marked characters, and the molars have flat and tuberculated crowns. The anterior premolars fall out as age advances. It is a remarkable circumstance that the teeth of frugivorous and carnivorous Bears exhibit no such differences as would lead to a suspicion of their complete difference of habit, if we were acquainted with these animals only in the condition of fossils.

The Cats have the dental formula $i. \frac{3 \cdot 3}{3 \cdot 3} c. \frac{1-1}{1-1} p.m. \frac{3 \cdot 3}{2 \cdot 2}$
 $m. \frac{1-1}{1-1} = 30$. The canines are very long and sharp. The premolars are like the Dogs', except that they are sharper, and that the hindermost (the sectorial tooth) has hardly any internal process. The single upper molar is a small tooth with a flat transversely elongated crown, and it lies within, as well as behind, the great sectorial premolar. In the lower jaw, the sectorial, or first, molar is the last tooth in the series. The crown is a deeply bifurcated blade representing the antero-external cusp of the corresponding tooth in the Dog. The "heel" is obsolete.

While the Bears are among the most completely plantigrade of the Carnivora, the Cats are most entirely digitigrade, and the apparatus for the retraction of the ungual phalanges is so well developed that the claws are completely retracted within sheaths of the integument, when the animal does not desire to use them. To this end the

elastic ligaments are very strong, and the median phalanx is excavated, in order to allow of the lodgment of the retracted phalanx on one side of it.

b. The *Pinnipedia*, or Seals and Walruses, are those *Carnivora* which come nearest the *Cetacea*. The tail is united, by a fold of skin which extends beyond its middle, with the integument covering the hind legs. These are, in most species, permanently stretched out in a line with the axis of the trunk. The pinna of the ear is small or absent. The toes are completely united by strong webs, and the straight nails are sometimes reduced in number, or even altogether abortive. The inner and the outer digits of the pes are very large. The incisors vary in number and lose their cutting form. The premolar and molar teeth are similar in character, and never have more than two fangs. There is no lachrymal bone or canal.

The brain-case of the cranium is generally much more rounded than that of other *Carnivora*; and, in some genera, the supra-orbital processes of the frontals are very largely developed. In both of these characters, and in the great breadth and complication of the convolutions of their cerebral hemispheres, as well as in their relatively small olfactory nerves and anterior commissure, the *Pinnipedia* approach the *Cetacea*.

There are three groups of *Pinnipedia*: the *Otaridæ*, the *Trichechidæ*, and the *Phocidæ*.

1. The *Otaridæ*, or Eared Seals, are so termed because the ear possesses a distinct though almost rudimentary pinna. These Seals have long necks, and can stand or walk upon all fours, the hind limbs being capable of supporting the body in the ordinary way.

In many respects, these animals are closely allied with the Bears; and by no part of their organization is this more clearly shown than by the skull, which in its general form, its large supra-orbital processes, the small and rugged *bulla tympani*, the perforation of the alisphenoid by a canal, and the presence of a crest on the inner surface of the parietals, is extremely ursine.

2. The *Trichechidæ*, or Walruses, are devoid of external ears, but resemble the *Otaridæ* in their mode of standing and walking. The skull resembles that of the Bear in the same respects, but the muzzle is distorted by the enormous development of the superior canines. The Walruses resemble the Bears in another point, namely, in the presence of a supplementary bronchus; the right bronchus, before it reaches the lung, dividing into two trunks, a large and a small. The thyroid cartilage is deeply excavated, in front, by a triangular fissure; and the epiglottis is extremely small.

In the brain, the remarkably large and richly convoluted hemispheres cover the cerebellum, and present a rudimentary posterior cornu. The anterior commissure is very small, as are the olfactory nerves.

The dentition of the Walrus is extremely peculiar. In the adult, there is one simple conical tooth in the outer part of the premaxilla, followed by a huge tusk-like canine, and three, short, simple-fanged, teeth. Sometimes, two other teeth, which soon fall out, lie behind these, on each side of the upper jaw. In the mandible there are no incisors, but a single short canine is followed by three, similar, simple teeth, and by one other, which is caducous.

The dental formula is therefore $i. \frac{1-1}{0 \cdot 0} c. \frac{1-1}{1 \cdot 1} p.m.m. \frac{3-3}{3 \cdot 3}$
 $+ \frac{2 \cdot 2}{1 \cdot 1} = 24.$

3. The *Phocidæ*, or ordinary Seals.—The pinna is altogether absent. The hind limbs are permanently stretched-out, parallel with the tail; and, consequently, they are unable to support the body, or assist in locomotion on land.

The space between the orbits is extremely narrow, and supra-orbital processes are absent. The *bulla tympani* is very large and thick-walled; and the middle, are much shorter than the outer, digits of the pes.

The common Seal (*Phoca vitulina*) is a native and accessible member of this group. It has a rounded head and a neck which is well marked, though shorter in proportion than that of the Eared-seals. The nasal apertures are slit-

like and can be closed at will, the eyes large and brilliant, and the auditory apertures small and devoid of a pinna. The limbs are large, and their distal, longer than their proximal, divisions. The fore limb is buried beyond the elbow in the common integument, but the flexible wrist allows the weight of the body to be supported by the palmar surface of the manus. The hind limbs, on the contrary, are permanently extended and turned backwards parallel with the tail, which lies between them, and with which they form a sort of terminal fin. When the Seal swims, in fact, the fore limbs are applied against the sides of the thorax, and the hinder moiety of the body being very flexible, the conjoined hind limbs and tail are put to the same use as the caudal fin of a Cetacean. The Seal has twenty dorso-lumbar vertebræ, of which five are lumbar. There are four sacral vertebræ, but only one of these unites with the ilia. Eleven vertebræ enter into the formation of the short tail. There are ten true ribs and nine sternæ, the manubrium being prolonged forwards into a long cartilaginous process.

The brain-case is smooth, rounded, and spacious, but the cranium narrows rapidly in the interorbital region. Its floor is remarkably flattened from above downwards and very thin, the broad basi-occipital sometimes presenting a perforation in the dry skull. The falx is partially, and the tentorium is wholly, ossified. The occipital segment is very large, and the supra-occipital advances between the parietals, but does not separate them completely. The alisphenoids are small and almost horizontal, and the synchondrosis between the basisphenoid and presphenoid persists. In all these respects the Seal's skull is strikingly cetacean. In fact, if the supra-orbital processes were sawn off, a Porpoise's brain-case would closely resemble a Seal's. But the nasal bones and the parietals are large, and the ethmoidal region is very peculiar. The *lamina perpendicularis* is largely ossified, and the vomer soon becomes ossified into one mass with it. The two ethmoidal turbinals (or the superior and middle) are small and flattened,

and the latter ankyloses with the vomer on each side. The inferior, or maxillary, turbinal is extremely large and complicated, and it blocks the nasal passage in front of the others like a sieve, or strainer. There is no lachrymal bone, but the jugal is large. The squamosal is ankylosed with the periotic and tympanic. The latter is massive and shell-shaped, somewhat as in the *Cetacea*, but it has rather different relations to the auditory meatus. The periotic is very large, and its tumid *pars mastoidea* appears largely on the exterior of the skull. The fossa under the superior vertical semicircular canal is prolonged into this tumid part of the periotic.

The alveolar portions of the premaxillæ are very small, but these bones extend far up the sides of the anterior nares. The maxillæ do not extend over the frontals. The mandible has a well-developed coronoid process.

The pollex is the longest and strongest digit, the others gradually decreasing in length. The fifth metacarpal articulates with the cuneiform bone, as well as with the unci-form.

The ilium is short, and the long pubis and ischium are greatly inclined backwards, so that the long diameter of the *os innominatum* makes only an acute angle with the spine. The femur is much shorter than the humerus. The tibia and fibula are ankylosed, and more than twice as long as the femur. The pes is longer than the tibia. The astragalus has a peculiar, roof-shaped, tibial surface, and sends a process backwards which contributes to the formation of the very short heel. The hallux is the strongest of the digits; while this and the fifth digit are the longest of those of the pes.

The cutaneous muscle is largely developed and inserted into the humerus. The *pectoralis major* is very large, and arises from each side of the prolonged manubrium, and even in front of it, beneath the neck; the fibres of the muscles of opposite sides are continuous. The *palmaris longus* is a strong muscle, but the proper digital muscles are weak or absent, as in the case of the *abductor*, *adductor*,

flexor brevis, and *opponens* of the fifth digit. A special long abductor of this digit, however, passes from the olecranon to the distal phalanx. The *iliacus* is wanting, and there is no *psaos major*; but muscles which represent the *psaos minor* and the subvertebral muscles of the *Cetacea* are very large and play an important part in effecting the locomotion of the Seal. The *pectineus* is very small, and the other adductors are inserted, not into the femur, but into the tibia. The *glutæus maximus* is inserted into the whole length of the femur. The *semi-membranosus* and *semi-tendinosus* are replaced by a *caudo-tibialis*, which arises from the anterior caudal vertebræ and is inserted into the tibia, some of its tendinous fibres extending to the plantar aspect of the hallux. The *poplitæus* and *gastrocnemius* are strong, but there is no *solæus*. The tendon of the *plantaris* passes over the calcaneum and ends on the plantar fascia of the perforated tendon of the fourth digit. The other perforated tendons seem to arise from the fascia attached to the calcaneum.

The dental formula is $i. \frac{3-3}{2-2} c. \frac{1-1}{1-1} m.p.m. \frac{5-5}{5-5} = 34$.

The grinding teeth have triangular crowns with notched edges, and at most two fangs.

The milk teeth are shed during fœtal life, and at this period there are three molars above and below on each side, which appear to be replaced by the second, third, and fourth of the adult set. If such be the case, only the hindmost of these last will be a true molar.

The tongue is bifid at the extremity. The œsophagus, very wide and dilatable, passes without any very well marked line of demarcation into the stomach, which is a great pyriform sac with its pyloric end bent upon itself. The intestine is about twelve times as long as the body. The colon is short, and is provided with a cœcum. The liver is divided into a great number of lobules, which are, as it were, set upon the inferior cava. The latter vessel, just below the diaphragm, presents a great dilatation, into which the *venæ hepaticæ* of the several lobules open. After tra-

versing the diaphragm, the vena cavâ is surrounded, for about an inch, by a layer of red circular muscular fibres. The aorta and the pulmonary artery are both dilated at their commencements.

The penis of the male is contained within a prepuce, supported by a loop of the cutaneous muscle. There is a large os penis, which presents a groove for the urethra inferiorly. The prostate is small, and there are no vesiculæ or Cowper's glands. The testes lie just outside the inguinal canal. The anus and the vulva of the female are surrounded by a common fold of integument. The clitoris has no bone. The body of the uterus is divided by a longitudinal septum.

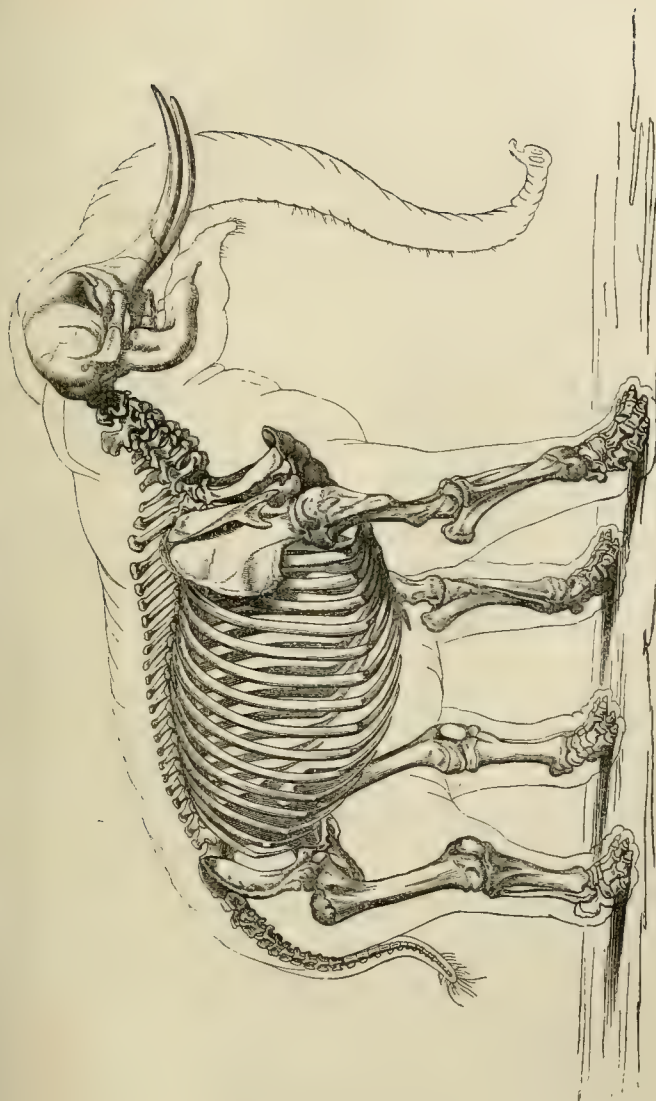
II. The *Proboscidea*.—These are massive animals, walking upon the extremities of the five toes, with which each foot is provided, and upon a great tegumentary cushion which unites these, and forms a flat sole behind them.

The nose is prolonged into a flexible proboscis, which is at once a strong, and a delicate, organ of prehension. The hairy covering is scanty in the recent species; but there was abundant long hair, and an undercoat of wool, in at least one extinct Proboscidean, the Mammoth (*Elephas primigenius*), which ranged over Northern Europe and Asia during the glacial epoch. The pinna of the ear is large and flat. The testes of the male remain in the abdomen, and the mammæ of the female are placed between the fore limbs.

The dorso-lumbar vertebræ amount to as many as twenty-three, and not more than three of these are lumbar, so that the dorsal region is, proportionally, exceedingly long. There are four sacral vertebræ, followed by a comparatively short tail. The centra of the vertebræ are far more flattened, from before backwards, than those of any other terrestrial mammal, and this is particularly the case in the cervical region, whence it follows that the neck is extremely short.

The skull is enormous, even in proportion to the body, its size arising, in great measure, from the development of air cavities in the diploe. The interspace between the

Fig. 108.

Fig. 108.—The skeleton of the African Elephant (*Lorodon africanus*).

inner and the outer tables of the skull is often, in an old elephant, considerably greater than the diameter of the cerebral cavity itself. The cranial cavity is elongated and subcylindrical. The supra-occipital rises far upon the roof of the skull, so that the parietals are much narrower at the sagittal suture than elsewhere. The premaxillæ are very large, and the nasal bones short, the nasal passages being nearly vertical. The jugal bone forms only the middle part of the jugal arcade. The rami of the mandible have a high perpendicular portion, and they are largely ankylosed at the symphysis, which is produced into a sort of spout.

The acromion of the scapula has a recurved process, such as is frequently found in the Rodents, to which order the *Proboscidea* present many curious approximations. There are no clavicles. In the antebrachium, the radius is permanently fixed (though not ankylosed) in the prone position, crossing the ulna obliquely. The carpal and metacarpal bones, and the phalanges, are remarkable for their short and thick form, and the manus is larger than the pes.

The ilia are immensely expanded transversely. The femur, which is not connected by any round ligament to the acetabulum, is relatively long and slender; and, when the animal is at rest, is directed perpendicularly to the axis of the trunk, not bent up, so as to form an acute angle with that axis, as it is in ordinary quadrupeds. The ham consequently occupies the middle of the length of the hind leg; the flexion of which, at this point, when the animal walks, gives an elephant a gait which is strikingly different from that of other quadrupeds. The tibia is relatively short. The fibula is distinct and complete, and the bones of the pes have the same broad and short form as those of the manus. The hallux has only a single phalanx in some species.

The *Proboscidea* have only two kinds of teeth, incisors and molars, canines being entirely absent. The incisors are composed of dentine and cement, with or without a

longitudinal belt of enamel, and, in the recent Elephants, are developed only in the upper jaw. As their growth continues for a long period, or throughout life, they usually take the form of long tusks, which project on each side of the upper jaw. The molar teeth are composed of dentine, enamel, and cement, and their crowns, when unworn, are always ridged, the ridges very often being made up of distinct tubercles. The intervals between the ridges are sometimes, as in the Asiatic Elephant, exceedingly deep, narrow, and completely filled up with cement; or, as in the African Elephant, they may be shallow and open, the cement forming only a thin coat. In the recent Elephants, only the two incisors are preceded by milk teeth. The molars are, altogether, six on each side, above and below; they come into place and use successively, the hinder ones moving forward, in proportion as the anterior ones are worn down by the attrition of those which are opposed to them.

The stomach is simple and elongated, and there is a very wide cœcum. The trilobed liver has no gall bladder. The heart has two anterior cavæ.

The cerebellum is left uncovered by the cerebral hemispheres; which, in the existing Elephants are large, and have greatly convoluted surfaces.

The male reproductive organs exhibit two very large vesiculæ seminales, and four prostates. The uterus of the female has two cornua.

Some, if not all, species of the extinct genus *Mastodon* were provided with a pair of short tusks in the mandible, in addition to the large ones in the premaxillæ. And in some of these animals, as in certain other extinct Elephants, the anterior grinding teeth had vertical successors. The Miocene genus, *Dinotherium*, possessed two large, downwardly-directed, tusks, one on each side of the symphysis of the mandible, while there were none in the upper jaw. The second and the third anterior grinding teeth had vertical successors.

The *Proboscidea* are, at present, restricted to Asia and

Africa, where they are represented by two very distinct forms, to which the names of *Loxodon* (*E. africanus*) and *Euelephas* (*E. indicus*) proposed by the late Dr. Falconer may be very properly applied. The oldest rocks in which their remains occur are of Miocene age. Fossil remains of elephants occur not only in the old world, but also in both North and South America.

III. The *Hyracoidea*.—The genus *Hyrax*, which is the sole member of this group, was referred by Pallas to the Rodents; and by Cuvier, who demonstrated that it could not be a Rodent, it was placed among the *Ungulata*, in the immediate neighbourhood of *Rhinoceros*, without any better evidence than that afforded by the characters of the molar teeth. Professor Brandt of St. Petersburg, in an elaborate memoir just published, arrives at the conclusion that it is a “gliriform Ungulate,” intermediate, in a certain sense, between the *Rodents* and the *Ungulata*; but, still, more Ungulate than Rodent. It appears to me to be neither Ungulate nor Rodent, but the type of a distinct order, in many respects intermediate between the *Ungulata*, on the one hand, and the *Rodentia* and *Insectivora*, on the other.

The small, Rabbit-like, animals comprised in the genus *Hyrax* are plantigrade, and provided with four visible toes in front and three behind. The nails are not hoof-like, but nearly flat, except the innermost of the hind foot, which is peculiarly curved. The body is covered with fur, and the *muffle*, or snout, is split, as in the Rodents. There is a pendulous penis, but no scrotum; and there are four inguinal and two axillary teats.

There are from twenty-nine to thirty-one dorso-lumbar vertebræ, which is the greatest number known in any terrestrial mammal. Twenty-one or twenty-two of these are dorsal. No mammal, except *Cholæpus*, the two-toed Sloth, possesses so large a number of dorsal vertebræ as this. The transverse processes of the last lumbar vertebra articulate with the sacrum, as is the case in many Ungulate Mammals. In the skull, the post-orbital processes, which are chiefly furnished by the parietal and the jugal, nearly meet.

Part of the articular facet for the mandible is formed by the jugal, which extends forwards until it comes into contact with the lachrymal bone. The base of the external pterygoid process is perforated by a canal, as in *Perissodactyla* and *Lemuridæ*. There are large pre- and post-tympanic processes, and the post-tympanic is much shorter than the par-occipital process. The premaxillæ are large, and unite extensively with the nasal bones; the perpendicular ramus of the mandible is very wide, and somewhat like that of the Tapir in shape. The posterior margin of the bony palate is opposite the anterior edge of the last molar tooth.

The scapula is devoid of an acromion process, as in the *Perissodactyla*. There are no clavicles, but the coracoid process is well developed. The ulna is complete, and a rudiment of the pollex is present. In the carpus, a line prolonging the axis of the third metacarpal bisects the *os magnum* and the *lunare*, which is not the case in any Ungulate Mammal.

In the hind limb, the femur possesses a small third trochanter, which is not nearly so conspicuous as in some Rodents. The tibia and fibula are complete. The extremity of the inner malleolus articulates with a shelf-like process of the astragalus, the distal face of which bone has on facet for the cuboid. The digits *i.* and *v.* are not represented even by rudiments. The terminal phalanx of *ii.* is longitudinally cleft.

The dentition of the adult is *i.* $\frac{2 \cdot 2}{2 \cdot 2}$ *c.* $\frac{0 \cdot 0}{0 \cdot 0}$ *p.m.* $\frac{4 \cdot 4}{4 \cdot 4}$, and *m.* $\frac{3 \cdot 3}{3 \cdot 3}$. The outer upper incisors are very small, and soon fall out; the inner, which are very large, curved, and have a thick coat of enamel on their anterior faces, continue to grow throughout life, as in Rodents. The lower incisors have crowns denticulated at the edges, like those of *Galeopithecus* and some Bats. They bite upon a callous pad which lies behind the upper incisors. The patterns of the upper and lower molar teeth are very similar to those of the corresponding teeth in *Rhinoceros*. As in the Horse,

part of the Eustachian tube is dilated into a thin-walled sac extending on the inner side of the *bulla tympani* from the pterygoid processes to the exit of the ninth nerve.

A slight constriction marks off the cardiac from the pyloric division of the stomach. The cardiac portion is lined by a dense epithelium. The intestine is provided with three cæca—one in the ordinary position, and two placed much lower down on the colon, opposite one another, and terminating by pointed ends. There is no gall-bladder. The ureters open, not near the neck of the bladder as in Mammals generally, but near the fundus, as in some few Rodents.

The male has *vesiculæ seminales*, prostatic and Cowperian glands. The uterus is two-horned, and the vulva and anus are surrounded by a common fold of integument.

In the fœtus the yelk sac and the vitello-intestinal duct early disappear. The amnion is not vascular. The allantois spreads over the interior of the chorion, and gives rise to the broad zone-like placenta, which is composed of both maternal and fœtal parts. The maternal vessels pass straight through the thickness of the placenta towards its fœtal surface, on which they anastomose, forming meshes, through which the vessels of the fœtus pass towards the uterine surface of the placenta.

The species of the genus *Hyrax* are found only in Syria and Africa. No fossil *Hyracoidea* are known.

THE DISCOIDEA.—The Mammalia with discoidal placenta are the *Rodentia*, the *Cheiroptera*, the *Insectivora*, and the *Primates*.

1. The RODENTIA.—This large group of Mammalia is most definitely characterized by its dentition. There are no canines, and the mandible never contains more than two incisors, which are placed one on each side of the symphysis, and continue to grow throughout life. They are coated with enamel much more thickly upon their front surfaces than elsewhere; so that by attrition they acquire and retain a chisel-shaped edge, the enamel in front wearing away less rapidly than the rest of the tooth.

With the exception of one group of Rodents, there are only two teeth in the premaxillæ; and these have the same characters as the incisors of the mandible. The *Lagomorpha*, or Hares and Rabbits, however, have a second pair of incisors of small size, behind the first, in the upper jaw. The molars are from two to six in number, in each half of the upper jaw, and two to five, in the lower jaw. They consist of enamel, dentine, and cement, and their crowns may be tuberculate or laminate in pattern. Sometimes they form roots, but, in other cases, they grow throughout life. Where there are more than three grinding teeth, the one which precedes the three hindermost has displaced a milk tooth; but where the grinding teeth are fewer than three, or only three, none of them displaces a milk tooth. Even when milk teeth exist they may be shed before birth, as in the Guinea-pig.

The premaxillary bones are always large, and the orbits are never shut off by bone from the temporal fossa. Very generally, the condyle of the mandible is elongated from before backwards.

With the exception of one group, the Dormice (*Myoxinæ*), all Rodents have a large cœcum.

The cerebral hemispheres leave the cerebellum largely uncovered, when the brain is viewed from above. They are either smooth externally, or very moderately convoluted. The corpus callosum is well developed.

With the exceptions noted, the foregoing characters are universal among the *Rodentia*. There are other peculiarities which are generally present, and when they exist, are very characteristic, though they are not universal.

Thus the dorso-lumbar vertebræ are usually nineteen in number. There is a large interparietal ossification. The jugal bone is comparatively short, and occupies only the middle of the zygomatic arch.

The clavicles are very generally present; though wholly absent in some genera, as, for example, the Guinea-pig, (*Cavia*). The acromion commonly sends a process backwards over the infra-spineous fossa. There is a ninth bone

in the carpus intercalated between the proximal and the distal series. The digits are five, unguulate, and provided with small claws.

There is a bone in the penis. The testes do not leave the abdomen, but come down into the groin in the breeding season. Vesiculæ seminales and prostatic glands are present. In the female the uterus is, in many genera, completely divided into two cornua, each of which opens separately into the vagina; but, in the rest, the cornua unite into a *corpus uteri*.

Some genera depart widely from the rest in particular points; for example, in the Porcupines, the hairs on the dorsal region of the body are very much enlarged, acquire a peculiar structure, and form the so-called "quills." Some of the Porcupines have prehensile tails.

In *Cavia* and *Hydrochærus* the toes are reduced to three, and the nails have almost put on the character of hoofs.

The Squirrels have the short pollex almost opposable.

The femur in some Rodents has a well-developed third trochanter; and in *Dipus*, the Jerboa, the long metatarsals become ankylosed together into a cannon bone.

In the Porcupines, the suborbital foramen is enormous, and an anterior fasciculus of the masseter muscle arises from the maxilla, and traverses the foramen to its insertion.

The Hamster (*Cricetus*) has great cheek pouches, provided with special retractor muscles connected with the spines of two lumbar vertebræ.

In some genera, the stomach, which is usually simple, tends to become complex. Thus the cardiac division of the stomach of the Beaver is provided with a special glandular mass. The cardiac end of the œsophagus of the Dormouse is glandular and dilated like the *proventriculus* of a bird. And, in *Arvicola*, the stomach becomes deeply constricted, and a groove leads from the œsophagus towards the pyloric end, reminding one of certain *Artiodactyla*.

In some few genera, the ureters open into the fundus of the bladder, or near it.

Although the genera and species of the *Rodentia* are

more numerous than those of any other mammalian order; and although they are adapted to very different modes of life—some, like the “Flying Squirrels,” floating through the air by means of a parachute-like expansion of the integument between the fore and hind limbs; others being arboreal, like the ordinary Squirrels; or among the swiftest of runners, as the Hares; or strong burrowers, as the mole-like *Bathyergus*; or aquatic, like the Water-vole—their structural differences are comparatively insignificant, and the subdivision of the order into large groups is proportionately difficult.

Brandt has divided the Rodents according to their cranial characters into *Sciuromorpha*, *Myomorpha*, *Hystri-comorpha*, and *Lagomorpha*; or, Squirrels, Rats, Porcupines, and Conies, if we use these English names in a broad and tribal sense.

The student will find the Rabbit, one of the *Lagomorpha*, to be a conveniently sized and easily obtained subject for study. The following are the most important points to be noted in its structure. The hairy covering of the body extends over the palmar and plantar regions of the feet, and into the interior of the mouth, so that there is a band of hair on the inside of each cheek. There are five digits on the fore foot, or manus; but the pollex is smaller than the others. The pes has only four digits, and the hind limb is longer than the fore limb. The upper lip is large, flexible, and cleft in the middle line; the large eyes are provided with a third eyelid, and the pinnae of the ears are very long and mobile. The tail is short and recurved. The male has a recurved penis, and on each side of it a scrotal sac. The female has five pair of abdominal teats. In both sexes perineal glands are present, consisting of a saccular involution of the integument with rugose walls, into which the duct of a special gland lodged at the side of the penis, or of the clitoris, opens.

There are nineteen dorso-lumbar vertebræ, of which twelve are dorsal. Of the four sacral vertebræ only the first unites with the ilia. The dorsal vertebræ have well-developed

spinous and transverse processes. At about the eighth, a mammillary process, or *metapophysis*, becomes obvious; and, in the succeeding vertebræ this increases in length and strength, till in the lumbar region it becomes as long as the spinous process. In the last lumbar, it is short, and in the sacrum, it is obsolete, but it is traceable through the series of the anterior caudal vertebræ. Accessory processes, or *anapophyses*, are observable in the last dorsal and four or five anterior lumbar vertebræ. The transverse processes of the lumbar vertebræ are exceedingly long, and that of the first lumbar is bifurcated at its extremity. These transverse processes give attachment above, to the *sacro-lumbalis*, and below, to the *psoas major*, both which muscles are very large; while the heads of the *longissimus dorsi* are attached to the long metapophyses. The great mass of these extensor and flexor muscles of the spine, and the leverage afforded by the mode of their attachment to the long processes of the vertebræ, would seem to be related to the leaping and scratching movements of the Rabbit. Strong median processes are developed from the ventral faces of the centra of the three anterior lumbar vertebræ; these give attachment to the crura of the diaphragm.

The tubercles of the second to the eighth ribs inclusively are prolonged into spiniform processes, which give attachment to the tendons of the *longissimus dorsi*. There are five sternibræ and a long xiphoid process. The manubrium is long, narrow, deep, and keeled inferiorly.

In the skull, the great supra-orbital processes of the frontal are to be noted. The presphenoid is high and greatly compressed from side to side, so as to form a thin septum between the orbits, and the optic foramina run into one, as in some Seals. The tympanic and the periotic are ankylosed together, but remain distinct from the adjacent bones, and are merely held in position by abutting against the basi-sphenoid on the inner side and by the post-tympanic hook of the squamosal on the outside. The tympanic is prolonged upwards and outwards into a tubular meatus.

The glenoid cavity is elongated from before backwards. The suture between the jugal and the maxillary becomes obliterated, and there is no orbital process given off from the zygoma. A considerable extent of the outer wall of the maxilla remains incompletely ossified. The premaxilla is extremely large and trifurcated.

The ascending portion of the ramus of the mandible is long, and the coronoid process well developed. The long axis of the condyle is antero-posterior, and the angular process has a slight inward projection. In the palate, the prepalatine, or incisive, foramina are enormous; and partly in consequence of this, partly by the posterior excavation of the palatal plate of the palatine, the roof of the palate is reduced to little more than a transverse bar of bone.

The scapula is long and narrow, and the backward process of the acromion, to which reference has already been made, gives attachment to a slip of the *trapezius*. A bony clavicle is present, but it is incomplete at both ends. There is a supra-condyloid foramen in the humerus. The radius and ulna are complete, but are fixed in the attitude of pronation.

The femur has a small third trochanter. The tibia and fibula are ankylosed. The internal cuneiform bone is wanting, and the plantar surface of the *naviculare* gives off a large process. The inner side of the base of the second metatarsal sends a process along the inner face of the meso-cuneiform to articulate with the naviculare. This may represent a rudiment of the hallux with the ento-cuneiform.

In the myology of the Rabbit the vast size of the flexors and extensors of the back has already been noted. The muscles moving the fore, and especially the hind, limbs, and the *masseter*, are not less remarkable for their dimensions. In the fore limb, the *supinator longus* is absent. The *extensor indicis* and *secundi internodii pollicis* form one muscle. The *extensor minimi digiti* goes to the fourth and fifth digits. The *flexor perforans* and the *flexor pollicis longus* unite in a common tendon which divides into five slips, one for each digit. There are three lumbricales from the radial sides

of the tendons for the third, fourth, and fifth digits. The *flexor sublimis*, or *perforatus*, for digits *ii.*, *iii.*, and *iv.* arises from the inner condyle as usual; but that for the fifth digit springs from the pisiform bone—thus simulating the ordinary arrangement of the perforated flexor in the pes. There is no *pronator quadratus*; but the *palmaris longus* is distinct, and its slender tendon expands into the palmar aponeurosis. Each digit, except the pollex, has a pair of *flexores breves*, or *interossei*, which lie on the palmar faces of the metacarpal bones.

In the hind limb, the *soleus* has only a fibular origin. The *plantaris* is very large and ensheathed in the *gastrocnemius*; it ends in a tendon nearly as large as the *tendo Achillis*, which passes over the end of the calcaneum, being connected with this and the *tendo Achillis* by a strong fascia laterally, but being, otherwise, separated from it by a synovial sac. In the sole of the foot it divides into four tendons, which become the perforated tendons of the four digits. The *flexor perforans* and *flexor hallucis* are fused into one muscle, the tendon of which divides in the sole into the four perforating tendons. There are three lumbricales, and four pair of *interossei* (*flexores breves*). There is no proper *tibialis posticus*, but a muscle arises from the upper part of the inner face of the tibia, internal to, and in front of, the insertion of the *popliteus*, becomes tendinous about the middle of the leg, passes behind the inner malleolus, and runs along the inner and dorsal aspect of the second metatarsal to be inserted into the extensor tendons. It seems to stand in the same relation to the second digit as the *peronæus quinti*, on the opposite side of the pes, to the fifth digit. The *peronæus longus* is inserted into the base of the second metatarsal: a *peronæus brevis*, *p. quarti*, and *p. quinti digiti* are present. There is no *extensor hallucis longus*, nor any *extensor brevis digitorum*.

The principal characters of the brain of the Rabbit have already been described (see p. 64, and Figs. 21 and 22). There is a single large *corpus mammillare*. Of the *corpora quadrigemina*, the nates are larger than the testes. There

is a very large and completely exposed flocculus, and the vermis is large in proportion to the lateral lobes of the cerebellum. The *corpora trapezoidea* are well marked.

The *membrana nictitans* is very large, has a convex free edge, and contains a triangular cartilage. There are no *puncta lachrymalia*, but a crescentic aperture leads into the lachrymal canal. The large lachrymal gland lies above and external to the eyeball, and there is a well-developed Harderian gland on its lower and inner side.

The dental formula is $i. \frac{2-2}{1-1} c. \frac{0-0}{0-0} p.m. \frac{3 \cdot 3}{2 \cdot 2} m. \frac{3 \cdot 3}{3 \cdot 3} = 28$.

The lower, and the inner upper, incisors are very large and long; they grow continuously from persistent pulps, and they are coated with enamel only in front, so that wear keeps them constantly sharp. The second pair of small incisors exists only in the upper jaw. A great diastema separates the incisors from the first premolar above and below. The grinding teeth all grow from persistent pulps, and do not form fangs; they have transversely ridged crowns, the patterns of which are very similar throughout, the first and the last only presenting some differences. The young Rabbit has three incisors and three milk molars on each side, in the upper jaw. In the lower jaw, there are only two milk molars on each side.

The stomach is simple, and there is a large cœcum. Special glands pour their secretions at the side of the anus.

The pancreas is very large, and its duct enters the intestine nearly a foot from the pylorus, and far distant from the biliary duct.

There are two anterior cavæ; and the external jugular vein is very much larger than the internal.

In the male, the inguinal canal remains permanently open, and there is a large uterus masculinus. In the female, the uteri are quite separate, and each opens by a distinct *os tinæ* into the vagina.

The distribution of the *Rodentia* is almost world-wide, Madagascar being the only considerable island in which indigenous Rodents are unknown. The Austro-Colum-

bian province may be regarded as the headquarters of the group.

Remains of Rodents have been found, in the fossil state, as far back as the eocene formation.

II. The INSECTIVORA.—It is exceedingly difficult to give an absolute definition of this group of mammals. But all the *Insectivora* possess more than two incisors in the mandible; and their molar teeth, which are always coated with enamel, have tuberculated crowns, and form roots.

The fore limbs have the structure usual among unguiculate mammals; and, in both limbs, the digits are provided with claws. The hallux is not opposable, and, like the other digits, it is provided with a claw.

In addition to these distinctive characters there are others which are met with in all members of the group.

The *Insectivora* are, almost all, either plantigrade or semi-plantigrade. The clavicles are completely developed in all, except *Potamogale*. The stomach is simple. The testes of the male are either inguinal or abdominal, and do not descend into a scrotum. The female has a two-horned uterus.

The cerebral hemispheres leave the cerebellum uncovered, in the upper view of the brain; and are almost, or wholly, devoid of sulci and gyri. The corpus callosum is sometimes exceedingly short.

No Insectivore attains a large size, and some, such as the Shrew Mice, are the smallest of the *Mammalia*.

The *Insectivora* present a great diversity of organization, the common Hedgehog being an almost central form. The Shrews tend towards the *Rodentia*, the *Tupayæ* towards the *Lemurs*; while the Moles, on the one hand, and the *Galeopithec*i on the other, are aberrant modifications. Relations of a more general character connect them with the *Carnivora* and the *Ungulata*.

The Hedgehog (*Erinaceus Europæus*) is pentadactyle and plantigrade. It has a long flexible snout. The eyes are small; the pinnæ of the ears are rounded, and the integument lining the concha is produced into a transverse, shelf-

like, fold. The under surface of the body bears hairs of the ordinary kind; but, on the dorsal aspect of the head and trunk, the hairs are converted into strong fluted spines. There are twenty-one dorso-lumbar vertebræ (of which fifteen are dorsal, and six lumbar), three or four sacral, and twelve to fourteen caudal. Accessory processes, or metaphyses, are developed on several of the dorso-lumbar vertebræ. The sternebræ are laterally compressed, except the manubrium, which is broad; and eight of the fifteen pair of ribs are connected with the sternum.

The occipital foramen is placed completely at the hinder extremity of the skull, in the lower part of the perpendicular occipital face of the cranium, and looks backwards. There are large paramastoid processes. The glenoidal surface for the mandible is flattened. The zygoma is stout, and the jugal bone is, as it were, applied upon the outer side of it. The orbit has no posterior osseous boundary. The lachrymal foramen lies upon the face. There are unossified spaces in the bony palate, and the posterior margins of the palate are thickened, as in the Lemurs. The large and bullate tympanic bone does not ankylose with the squamosal, or the periotic, and is readily lost from the dry skull. The alisphenoid contributes largely to the formation of the front wall of the tympanum; and a large portion of the inner wall of the tympanic cavity is formed by a broad process of the basisphenoid, the outer and lower edge of which joins, by a sort of harmonia, with the inner and lower edge of the tympanic.

The ascending portion of the ramus of the mandible is short, and the angle is slightly inflected. The two rami are not ankylosed at the symphysis. The supra-scapular fossa is wider than the infra-scapular. The spine is strong, and the acromion bifurcates, sending a prolongation backwards. The clavicles are long and convex forwards. The humerus has an intercondyloid foramen; but there is no foramen above the inner condyle, and this circumstance is unusual among the *Insectivora*. The bones of the anti-brachium are fixed in the prone position. There is an *os*

centrale in the carpus, so that it has nine bones. The scaphoid and lunare are ankylosed, as in the *Carnivora*, and the pisiform bone is much elongated. The pollex and the fifth digit are the shortest.

The pelvis is remarkably spacious. The symphysial union of the pubes is always small, and, sometimes, the bones remain separate. The subpubic arch is much rounded. The ilium is narrow, and a mere ridge separates the iliac fossa from the gluteal surface. The femur has a round ligament, and a prominent ridge represents a third trochanter. The distal ends of the tibia and fibula are ankylosed together.

One of the most notable peculiarities of the Hedgehog is its power of rolling itself up into a ball, from all sides of which the spines protrude. This is effected, for the most part, by the contraction of the greatly developed cutaneous muscle, the chief fibres of which are disposed as follows. A very broad band, the *orbicularis panniculi*, encircles the body laterally. In front, it, partly, arises from the nasal and frontal bones, and, partly, is the continuation of a thick mass of fibres which pass over the occiput. Posteriorly, each lateral division of the muscle spreads out into a very broad band, which is thick ventrally and thin dorsally, and adheres closely to the skin, from the line at which the hairy and spinigerous surfaces join, to near the median line of the back. Posteriorly, the two lateral halves of the orbicular muscle pass into one another upon the distal half of the short tail.

The action of this muscle will depend upon the attitude of the animal when it contracts. If the head and tail are fully extended, the *orbicularis* can only diminish the dimensions of the spinigerous region of the skin and erect the spines. But if the head and tail be more or less flexed, as they always are in the ordinary attitude of the Hedgehog, the *orbicularis* will play the part of a powerful sphincter, approximating the edges of the spinigerous area towards the centre of the ventral side of the body, and forcibly enfolding the trunk and limbs within the bag thus formed:

It is, in fact, the chief agent in coiling the body up, and keeping it so coiled.

Numerous muscular bundles take a radiating direction on the dorsal aspect of the body, and antagonize the *orbicularis*: 1. A pair of slender *occipito-frontales* arise from the occipital crest, and are inserted into the integument over the frontal and nasal bones. 2. A pair of *occipito-orbiculares* arise from the same crest, and pass into the anterior part of the *orbicularis*. 3. A pair of broader *cervico-orbiculares* arise from the fascia of the neck, and pass to the dorsal part of the anterior fourth of the *orbicularis*. 4. Slender *dorso-orbiculares* arise close to the hinder ends of the *trapezii* and spread out above the foregoing. 5. Two stout muscles, *coccygeo-orbiculares*, arise from the middle caudal vertebræ, and after receiving fibres from the ventral region, end in the dorsal margins of the *orbicularis*. 6. Two muscles attached to the pinnæ of the ears (*auriculo-orbiculares*) pass backwards to the *orbicularis* on each side.

On the ventral aspect are certain muscles which assist the *orbicularis*: 1. Two broad muscles (*sterno-faciales*) arise in the middle line, over the anterior part of the sternum, and pass outwards and forwards to the sides of the lower jaw and the integument of the face and ears. Muscular slips from these are sent up over each shoulder to the *orbicularis*. 2. A *humero-abdominalis* arises from each humerus beneath the insertion of the *pectoralis major*, and, passing backwards over the sides of the abdomen, these become connected with the ventral edges of the *orbicularis*. The external fibres of these muscles are continued round the ischial region to the *coccygeo-orbicularis*; the internal fibres pass to the prepuce, and over the middle line of the abdomen, in front of it. 3. A *humero-dorsalis* arises from the humerus close to the foregoing, and passing upwards and backwards through the axilla, spreads out in the mid-dorsal integument and the *orbicularis*.

The contraction of all these muscles must tend to bring together the edges of the integumentary bag, and to tuck the head, tail, and limbs into it.

In the myology of the limbs the following points are noteworthy: The *supinator longus*, *pronator teres* and *palmaris longus* are absent. The *palmaris brevis* is present. A single muscle takes the place of the *extensor secundi internodii pollicis* and *extensor indicis*, and sends a third tendon to the middle digit. The *extensor minimi digiti* supplies the other two digits. The *flexor perforans* and *flexor pollicis longus* are represented by five distinct muscular heads, each with a tendon of its own; but all the tendons unite in the middle of the forearm, and the common tendon again subdivides into only four slips, the pollex receiving no tendon. There are no *lumbricales*. The pollex has only a rudimentary *flexor brevis* and an *abductor*. The other digits have each two *interossei*, or *flexores breves*, inserted into the metacarpophalangeal sesamoids.

In the leg, the *soleus* has only a fibular head, and the *flexor brevis digitorum* arises wholly from the calcaneum. The *flexor hallucis* and *flexor perforans* have a common tendon, which, in the sole, divides into five tendons, one for each digit. There are no *lumbricales*, nor *flexor accessorius*. The *tibialis posticus* seems to be represented by two small muscular bellies, one of which arises from the prominent end of the tibia, and the other from that of the fibula. The tendons of both pass behind the inner malleolus, and that of the former muscle goes to the tibial and plantar surface of the hallucal metatarsal, while the latter is inserted into the ento-cuneiform bone. The *interossei pedis* are represented by a pair of *flexores breves* for each digit except the hallux.

The adult Hedgehog has thirty-six teeth, of which twenty are in the upper, and sixteen in the lower jaw. The dental formula is $i. \frac{3 \cdot 3}{3 \cdot 3} c. \frac{0-0}{0-0} p.m. \frac{4-4}{2 \cdot 2} m. \frac{3 \cdot 3}{3 \cdot 3} = 36$.

The grinding surface of the crowns of the first and second upper molars exhibits a pattern fundamentally similar to that of the corresponding teeth in Man, the *Anthropomorpha*, and the majority of the Lemurs; that is to say, there are four cusps, and the antero-internal is connected with the postero-external cusp by an oblique ridge. The

cusps are remarkably sharp and pointed, and the outer surface of the postero-external one alone is somewhat inflected.

In the lower jaw, the corresponding molars are each marked, as in most Lemurs, by two transverse ridges. In front of the anterior ridge is a basal prolongation of the tooth, on to which a curved ridge is continued inwards and forwards from the anterior principal ridge, giving rise to an imperfect crescent with its convexity outwards.

According to Rousseau there are twenty-four milk teeth,

i. $\frac{3.3}{4.4}$ *d.m.* $\frac{4.4}{1.1}$, which fall out seven weeks after birth.

The brain of the Hedgehog is remarkable for its low organization. The olfactory lobes are singularly large, and are wholly uncovered by the cerebral hemispheres; which, on the other hand, do not extend back sufficiently far to hide any part of the cerebellum. Indeed they hardly cover the corpora quadrigemina. Only a single shallow longitudinal sulcus marks the upper and outer surface of each hemisphere. On the under surface, a rounded elevation corresponds with the base of each corpus striatum. Behind this, another elevation represents the end of the uncinata gyrus and the termination of the hippocampus major; and therefore answers, in a manner, to the temporal lobe. The inner face of the hemisphere presents neither convolution nor sulcus, except behind and below, where a very broad depression follows the contour of the fissure of Bichat and the fornix, and represents the dentate sulcus. Above, this sulcus ends behind the posterior margin of the corpus callosum. The latter is remarkably short, and directed obliquely backwards and upwards. It has no *genu*, and the pre-commissural fibres of the ventricular wall spread out, beneath its anterior end, upon the face of the hemisphere. The part of the corpus callosum which answers to the *lyra* is very thick in proportion, and is inclined at an acute angle to the rest.

In a transverse section, the corpus callosum is seen to be very thin, and to curve upwards and outwards into the roof of the ventricular cavity. The inner walls of the lateral ventricles, which answer to the septum lucidum, are

thick, while the fornix is comparatively thin and slender. The anterior commissure is very stout. In this circumstance, as in the small corpus callosum, the brain of the Hedgehog closely approaches that of the *Didelphia* and *Ornithodelphia*. There is no trace of a posterior cornu, or calcarine fissure, and the lateral ventricle extends forwards into the olfactory lobe. The optic nerves are very slender; the *corpora geniculata externa* are large and prominent; the testes are smaller than the testes, and transversely elongated. The cerebellum has a large vermis and small lateral lobes; the *floculi* are prominent and are lodged in fossæ of the periotic bones. The *pons Varolii* is very small; the *corpora trapezoidea* proportionally large.

The spinal cord is remarkable for its thickness, and, at the same time, for its brevity, as it ends in the middle of the dorsal region. As a consequence of this arrangement the *cauda equina* is particularly large and long.

The stomach is simple, but the mucous membrane of the considerable cardiac dilatation is thrown into numerous, and very strong, longitudinal rugæ. The intestine is about six times as long as the body, and presents no distinction into small and large; nor is there any cæcum. The liver is divided by deep fissures into six lobes; a central one which bears the gall-bladder, a bifid spigelian lobe, and, on each side of these, two other lobes. The pancreas is a large and irregularly ramified gland; and the spleen is elongated and trihedral.

The pericardium is extremely thin. The arteries arise from the arch of the aorta, as in Man, by an *anonyma*, a left carotid and left subclavian. The course of the internal carotid is remarkable. When it reaches the base of the skull it enters the tympanum and there divides into two branches, of which one traverses the stapes, and passing forwards in a groove of the roof of the tympanum, enters the skull and gives rise to the middle meningeal and ophthalmic arteries. The other branch passes over the cochlea, enters the skull by a narrow canal near the *sella turcica*, and unites with the circle of Willis.

The external jugular vein is very much more capacious than the internal, the latter being very small and hardly traceable to the internal jugular foramen. It is by the external jugular vein, in fact, that the great mass of the blood within the skull is carried away, a foramen in the squamosal bone allowing of a free communication between the external jugular vein and the lateral sinus. There is a left superior vena cava, which winds round the base of the left auricle, receives the coronary vein, and opens into the right auricle. The vascular system thus retains many embryonic characters.

The right lung is four lobed; the left may possess from one to three lobes.

Two ossifications, one on each side of the opening for the aorta, occur in the diaphragm.

The testes of the male do not leave the cavity of the abdomen, but they descend as far as the inner side of the inguinal ring, to which they are connected by a short gubernaculum and cremaster. The *vasa deferentia* descend to the base of the bladder and then enter a hollow muscular sheath on their way to a "chamber," which is lodged in the distal end of that sheath. This "chamber" passes into the penial urethra; the cystic urethra opens into it by a narrow slit in its front wall; and it receives the ducts of three pair of appendages. The proximal pair consist of a multitude of ramified tubuli, which have been found to contain spermatozoa, and are usually regarded as vesiculæ seminales. The middle pair (the so-called "prostatic glands") have a similar structure and have also been observed to contain spermatozoa. The lowermost pair are Cowper's glands. The "chamber" appears to represent the urogenital sinus of the embryo, which has not become differentiated into prostatic and bulbous urethra.

The ovaries are inclosed in wide-mouthed peritoneal sacs, and a ligamentous band, the diaphragmatic ligament, extends from the ovary to the posterior surface of the diaphragm. The cornua uteri are large and long. There are five pair of teats; the anterior pair being axillary and

the posterior inguinal. The other three pair are equidistant, and lie along the ventral surface, internal to the edge of the *orbicularis panniculi*.

Like the *Rodentia*, the *Insectivora* have a great diversity of habit; some *Galeopithec*i flitting through the air after the fashion of the flying Squirrels; some arboreal, as the *Tupayæ*; some terrestrial and cursorial, like the majority of the order. A few are swimmers; and some, like the Mole, are the most completely fossorial of mammals.

The most aberrant form of the *Insectivora* is the genus *Galeopithecus*, essentially an Insectivore of arboreal and frugivorous habit, with very long and slender limbs. These are connected with one another, with the sides of the neck and body, and with the tail, by a great fold of the integument, which is called *patagium*; and, unlike the web of the Bat's wing, is hairy on both sides, and extends between the digits of the pes. By the help of this great parachute-like expansion, the *Galeopithecus* is enabled to make floating leaps, from tree to tree, through great distances. When at rest, the *Galeopithec*i suspend themselves by their fore and hind feet, the body and the head hanging downwards; a position which is sometimes assumed by the Marmosets among the *Primates*.

The fore limbs are slightly larger than the hind limbs. There are four axillary teats. The male has a pendent penis and inguinal scrotal pouches. The pollex and the hallux are short, and capable of considerable movement in adduction and abduction, but they are not opposable; and their claws are like those of the other digits.

The occipital foramen is in the posterior face of the skull. The orbit is nearly, but not quite, encircled by bone. The lachrymal foramen is in the orbit. The bony roof of the palate is wide and its posterior margin is thickened. There is a strong curved post-glenoidal process of the squamosal, which unites with the mastoid, beneath the auditory meatus, and restricts the movement of the mandible to the vertical plane. A longitudinal section of the skull shows a large olfactory chamber projecting beyond

that for the cerebral lobes, and two longitudinal ridges upon the inner face of the latter, prove that these lobes must have possessed corresponding sulci. The tentorial plane is nearly vertical and the floccular fossæ are very deep.

The ulna is very slender inferiorly, where it becomes ankylosed to the distal end of the radius, which bears the carpus. When the ilia are horizontal, the acetabula look a little upwards and backwards as well as outwards. The fibula is complete. As in the Sloths and most *Primates*, the navicular and cuboid readily rotate upon the astragalus and calcaneum, so that the *planta pedis* is habitually turned inwards.

The dental formula is $i. \frac{2 \cdot 2}{3 \cdot 3} c. \frac{1-1}{1-1} p.m. m. \frac{5-5}{5-5} = 34$.

The outer incisor, in the upper jaw, has two roots, a peculiarity which is not known to occur elsewhere. The canines of both jaws also have two roots, as in some other *Insectivora*. The lower incisors are single-fanged; and their crowns are broad, flat, and divided by numerous deep longitudinal fissures, or "pectinated."

The length of the whole alimentary canal from mouth to anus is not more than six times that of the body. The sacculated cœcum is as long as the stomach, and its capacity must be greater than that of the latter organ.

Galeopithecus has, at one time, been placed among the Lemurs, and at another, among the Bats. But the resemblances with the former are general and superficial, and the differences in the form of the brain, the dentition, the structure of the limbs and of the skull, exclude it from the order of the *Primates*.

Galeopithecus agrees with the Bats in the disposition of the tail, and in the existence of a *patagium* provided with special muscles. Further, in a slight obliquity of the acetabula, such as is seen in its extreme development in the Bats; in the imperfect condition of the ulnæ; and in the pectoral position of the teats and the pendent penis. Both of these last, however, it must be recollected, are also Primatic characters. Finally, the somewhat similarly pec-

minated lower incisor teeth are found in the Cheiropteran genera, *Diphylla* and *Desmodus*.

But *Galeopithecus* differs from the Bats completely in the structure of the fore limbs; in the position of the hind limbs and the absence of a *calcar*; in the two-fanged outer incisors and canines; and in the presence of a cœcum.

On the other hand, the peculiarities of the skull and brain are mainly insectivorous, as is the two-fanged canine; and I see no reason for dissenting from Prof. Peters' view that *Galeopithecus* belongs neither to the Primates, nor to the Cheiroptera, but that it is an aberrant Insectivore.

With respect to other *Insectivora*, it is worthy of note, that *Macroscelides* has the radius and the ulna ankylosed. The *Tupayæ* possess a large cœcum. *Chrysochloris* has pectoral mammary glands; *Centetes* and the Moles have the penis pendent.

The *Tupayæ* are soft-furred, long-tailed, tree-loving animals, with complete bony orbits and a large cœcum, and are those *Insectivora* which most nearly approach the Lemurs.

The Shrews (*Sorices*) most nearly resemble Rodents outwardly, being very like small mice. The zygoma is imperfect, the tibia and fibula are ankylosed, and the pubic bones do not meet in the symphysis. There are sixteen to twenty teeth in the upper jaw and twelve in the mandible. Canines are absent, and there are six incisors above and four below. The inner lower incisors are greatly elongated and proclivous, and some of the teeth not unfrequently become ankylosed with the jaws. There is no cœcum, and peculiar musk glands are sometimes developed at the sides of the body.

The Moles (*Talpinæ*) have no external ears, and the eyes are rudimentary. The fore limbs are much larger than the hind, and are inclosed within the integument up to the carpus. The palmar surface of the broad manus is turned outwards and backwards.

The manubrium of the sternum is very broad, and its ventral surface gives rise to a strong median crest. The scapula

is as long as the humerus and the radius together. It is triquetral and possesses an acromial process, but no distinct coracoid. The clavicle, which is very strong, is perforated by a great foramen, and at the middle of its posterior margin sends off a truncated re-entering process. Proximally, it furnishes an articular surface for the humerus. In the carpus there is a distinct *centrale*, and a large accessory C-shaped bone lies on its radial side. The pubes are separate at the symphysis, and an accessory styloid bone is connected with the naviculare of the foot.

The distribution of the *Insectivora* is singular in this respect, that although they are met with, under very various climatal conditions, throughout the Old World and North America, there are none in South America or Australia.

In the fossil condition they are not certainly known to occur in strata older than the tertiary.

Fig. 109.

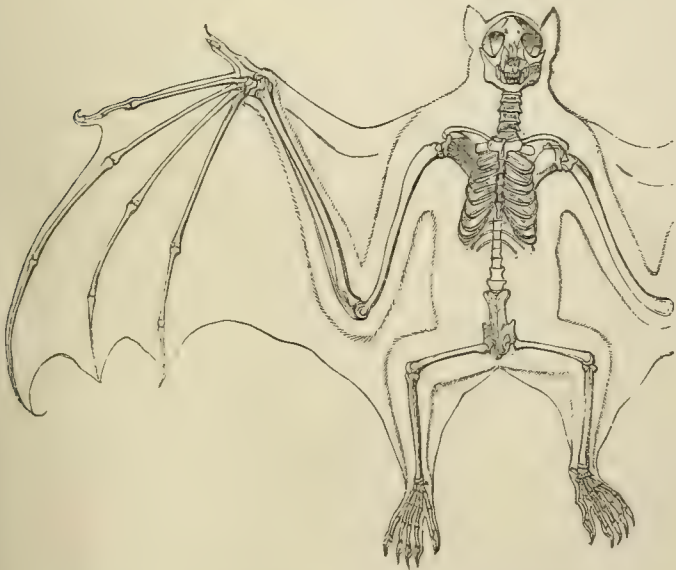


Fig. 199.—The skeleton of a Flying Fox (*Pteropus*).

III. The CHEIROPTERA.—The *Cheiroptera* may be regarded as exceedingly modified *Insectivora*, having their nearest ally in *Galeopithecus*.

They possess one or two pair of pectoral teats; and the fore limbs are very long, some of the digits particularly being immensely elongated. There is a *patagium*, or expansion of the integument, uniting the fore limbs with the body, and extended, as a membranous web, between the elongated fingers. Of these the third, fourth and fifth, and very frequently the second, are devoid of nails. The pollex always has a claw-like nail. When the animal is resting upon the ground, the thigh is twisted upwards and backwards, in such a manner, that its extensor face looks forwards, and its flexor face backwards. In consequence of this the knee looks upwards and backwards, and the toes are turned backwards and slightly outwards. Under the same circumstances, all the digits of the manus are flexed upon their metacarpal bones; and the folded-up wing rests against the side of the body, whilst the pollex, with its claw, is extended forwards. In this position the animal shuffles along, with considerable rapidity; hauling itself forward by the claws on the pollices, and shoving itself along, by extending the hind limbs.

The favourite attitude of a Bat, when at rest, however, is that of suspension by the claws of one or both legs, with the head downwards, and the *patagium* folded over it like a cloak. The most active movement of the Bat is effected by flight, the fore limbs being extended, and the *patagium*, which they support, playing the part of the feathers of a bird's wing.

The cervical vertebræ are remarkably large in proportion to the others, but, as in the rest of the vertebral column, the spinous processes are very short. The ribs are long and curved, so as to include a relatively capacious chest. The manubrium of the sternum is very wide, and the middle of its under surface raised into a crest. In the lumbar region, the vertebral column is bent, so as to be concave forwards and to describe almost the quarter of a

circle. As a consequence, the axis of the sacrum is at right angles to that of the anterior thoracic vertebræ.

In the skull, the orbit is not divided by bone from the temporal fossa, and the premaxillæ are relatively small, and sometimes altogether rudimentary.

The clavicles are remarkably long and strong, and the broad scapula has a strong spine. The ulnæ are imperfect distally, the carpus being borne altogether by the radius. There is only a single bone in the proximal row of the carpus, the pisiform being absent. Those digits of the manus which are devoid of nails, possess not more than two phalanges.

The pelvis is very narrow and elongated, and the pubic bones are widely separated at the symphysis, as in some *Insectivora*. The anterior caudal vertebræ and the ischia are frequently united. The axes of the acetabula are directed towards the dorsal side of the body as well as outwards; whence, in part, arises the peculiar position of the thigh, which has already been described. The fibula is rudimentary, its upper part being represented only by ligament, and there is an elongated bone, or cartilage, attached to the inner side of the ankle-joint which lies in and supports the *patagium*, and is called the *calcar*. The distal moiety of the tarsus readily rotates upon the astragalus and calcaneum, permitting the sole to turn inward with much ease.

All *Cheiroptera* possess three kinds of teeth, incisors, canines, and molars; and the intestine is devoid of a cæcum.

The heart is provided with two superior cavæ, a right and left; and the smooth cerebral hemispheres leave the cerebellum completely exposed.

The testes are abdominal throughout life, or may descend into the perinæum, but there is no true scrotum. The penis is pendent. There are vesiculæ seminales. The form of the uterus varies, being sometimes rounded and sometimes two-horned.

The Bats are ordinarily divided into the *Frugivora* and the *Insectivora*.

a. The *Frugivora* live, as their name implies, exclusively upon fruits. With the single exception of *Hypoderma*, all the genera embraced in this group have a nail on the second digit of the manus, and the crowns of the molar teeth, which soon wear down, are, when entire, divided by a longitudinal furrow.

The incisors do not exceed $\frac{2 \cdot 2}{2 \cdot 2}$.

The pyloric portion of the stomach is immensely elongated.

The nose has no foliaceous appendages, and the well-developed pinna of the ear has the ordinary form, neither the tragus, nor any other part, being unusually developed.

These Bats are confined to the hotter parts of the Old World and of Australia, where, from their dog-like heads and reddish colour, they are known as "Flying Foxes" (*Pteropus*, *Harpya*, &c.)

b. The division of the *Insectivora* contains Bats which, for the most part, live upon insects, though some delight in fruits, and others suck the blood of larger animals.

The second digit of the manus is devoid of a nail, and sometimes is without any bony phalanges.

The stomach is usually pyriform, with a moderate cardiac enlargement. The molar teeth almost always have such a pattern as is observed in the typical *Insectivora*, and do not exceed six, or fall below four, on each side above and below.

The incisors are ordinarily $\frac{2 \cdot 2}{2 \cdot 2}$ or $\frac{2 \cdot 2}{3 \cdot 3}$, but their number may be much reduced.

The integument of the nose is developed into an appendage which is sometimes very large and leaf-like, and the tragus of the large ears is often similarly modified. The tail is often long, and sometimes prehensile.

The genera *Desmodus* and *Diphylla* (of which the group *Hæmatophilina* has been formed) are the most completely blood-sucking of all the Bats in their habits. They have a pair of enormous, sharp-pointed, upper incisors, while the four lower incisors are small and pectinated. The

canines are very large and sharp, and the molars, which are reduced to two above and three below, on each side, have their crowns converted into sharp longitudinally disposed ridges, like the edges of scissors. In *Desmodus*, the very narrow œsophagus leads into a stomach which would be of extremely small dimensions, were it not that its cardiac end is dilated into a great sac, which is longer than the body, and lies, folded up on itself, within the cavity of the abdomen. Into this sac it would appear that the blood swallowed by the animal at first passes, to be thence slowly drawn along the intestine.

Mr. Darwin* thus speaks of the habits of *Desmodus D'Orbigny* :

“The Vampire Bat is often the cause of much trouble by biting the horses on their withers. The injury is generally not so much owing to the loss of blood as to the inflammation which the pressure of the saddle afterwards produces. The whole circumstance has lately been doubted in England. I was therefore fortunate in being present when one was actually caught on a horse's back. We were bivouacking late one evening near Coquimbo, in Chili, when my servant, noticing that the horses were very restless, went to see what was the matter, and fancying he could distinguish something, suddenly put his hand on the beast's withers and secured the Vampire. In the morning the spot where the bite had been inflicted was easily distinguished, from being slightly swollen and bloody. The third day afterwards we rode the horse without any ill effects.”

IV. The PRIMATES.—The *Primates* have two pectoral mammæ, and, rarely, additional ones upon the abdomen. Incisor and molar teeth are always present, and, with one exception, canines. The incisors are never more than two, nor are there more than three premolars and three molars, on each side, above and below.

Saving individual exceptions, which occur in one genus, and may be regarded as abnormal, the hallux possesses a

* “Voyage of the Beagle,” Mammalia, p. 2.

flat nail. The hallux differs in form from the other digits of the foot, and is so disposed as to be capable of more or less extensive motion in adduction and abduction; and, very generally, it is opposable to the other digits of the foot.

The *Primates* are divisible into—*a.* the *Lemuridæ*, *b.* the *Simiadae*, and *c.* the *Anthropidæ*.

a. The first of these divisions, the *Lemuridæ*, is more widely separated, anatomically, from the other two, than these are from one another,* and it contains some forms which very closely approximate to the *Insectivora*, while others are nearly affined to the *Rodentia*.

All the *Lemuridæ* are habitually quadripedal, have the integument furry, and are usually provided with long tails which are never prehensile. They are devoid of cheek pouches and of callous patches upon the integument covering the ischia.

The fore limbs are shorter than the hind limbs. In the foot, the hallux is large and opposable, and the second digit differs from the rest in size, and in the claw-like form of its nail. The fourth digit is usually longer than the others, the difference being especially marked in the pes.

In the skull, the brain-case is small relatively to the face, and is contracted anteriorly. If a straight line drawn from a point midway between the occipital condyles, through the median plane of the skull, to the junction of the ethmoid and presphenoid, in the floor of the cerebral cavity, be termed the *basi-cranial axis*; and if the planes of the cribriform plate of the ethmoid, of the tentorium cerebelli, and of the occipital foramen, be respectively termed the *ethmoidal*, *tentorial*, and *occipital planes*; then, the greatest length of the cerebral cavity hardly exceeds the length of the basi-cranial axis; and the ethmoidal, tentorial, and occipital planes are very much inclined to that axis. The upper aperture of the lachrymal foramen lies upon the

* On the strength of these differences M. Gratiolet relegated the Lemurs to the *Insectivora*; and Mr. Mivart, in his valuable paper "On the Axial Skeleton in the Primates," published in the Proceedings of the Zoological Society for 1855, divides the *Primates* into two sub-orders, *Lemuroidea* and *Anthropoidea*.

face, outside the front margin of the orbit. The frontal and the jugal bones are united behind the orbit, but a mere bar of bone results from their union; and it is so narrow that the orbit and the temporal fossa are in free communication. The bony palate is elongated and, in many species, its posterior free edge is thickened.

The lateral processes of the atlas are, usually, expanded. The lumbar region of the spine is elongated; the vertebra composing it, in some cases, being as many as nine. There are nine bones in the carpus. The ilia are narrow and elongated, and the ischia are not everted. In most Lemurs, the tarsal bones resemble those of the other *Primates*; but, in *Otolincus* and *Tarsius*, they have undergone a modification, a parallel to which is not to be found among Mammals, but must be sought among the *Batrachia*. When the distance between the heel and the digits is great in other *Mammalia*, the elongation affects the metatarsal bones and not the tarsus; but, in these Lemurs, the calcaneum and the naviculare are prolonged, as they are in the Frogs.

The *sublingua*, a process of the mucous membrane of the floor of the mouth, developed between the apex of the tongue and the symphysis of the mandible, acquires a considerable size, and is often denticulated, or comblike, at its free end. The stomach is simple, with the cardiac and pyloric apertures approximated. The cœcum is long, and has no vermiform appendage.

In many Lemurs (*Stenops*, *Nycticebus*, *Perodicticus*, *Arctocebus*, *Tarsius*) the great arteries and veins of the limbs break up into *retia mirabilia* formed of parallel branches.

The ventricles of the larynx may be enlarged, but there are no great air sacs, such as exist in many other *Primates*.

In the brain, the cerebral hemispheres are relatively small and flattened, and have narrow and pointed frontal lobes. They are so short as to leave the cerebellum largely uncovered. The gyri and sulci are scanty, or absent, upon the outer surface of the hemispheres, but the internal face exhibits the calcarine sulcus. The large olfactory lobes project forwards beyond the cerebral hemispheres.

The pendent penis of the male commonly contains a bone; the testes are lodged in a more or less complete scrotum; and vesiculæ seminales are generally present.

In the female, the uterus has two long cornua, and the urethra traverses the clitoris. Sometimes there are one or two pairs of teats on the abdomen, in addition to the ordinary pectoral pair.

The *Lemuridæ* are distinguishable into two families, the *Lemurini* and the *Cheiromyini*.

In the *Lemurini*, the pollex is large, opposable, and almost always has a broad, flat nail.

The usual dental formula is $i. \frac{2 \cdot 2}{2} c. \frac{1 \cdot 1}{1 \cdot 1} p.m. m. \frac{5 \cdot 5}{5 \cdot 5}$, or $\frac{6 \cdot 6}{6 \cdot 6}$.

The upper incisors are vertical, and the pairs of opposite sides are generally separated by an interval. The upper canines are large and pointed, and very different from the incisors. The lower incisors are close set, laterally compressed, long and proclivous, and the canines, which resemble them in form and direction, are closely applied to the outer incisors. When six grinders are present, the anterior three are premolars. The anterior premolars, and sometimes all of them, have triangular and sharp-pointed crowns; the first premolar of the lower jaw, in fact, resembles a canine, but its true nature is shown by its biting behind the upper canine, not in front of it.

Very generally the crowns of the upper molars are quadricuspidate, and an oblique ridge passes from the antero-external to the postero-internal cusp, as in the highest *Primates*; while, in the lower jaw, there are either two transverse ridges, or longitudinal crescents. The cusps of the molars are usually much produced, as in the *Insectivora*.

In the *Cheiromyini*, the pollex is not truly opposable, and its nail is claw-like and resembles that of the other digits. All the digits of the pes, except the hallux, have compressed, claw-like, nails. The middle digit of the manus is much more slender than any of the others, and is longer than the fourth. The long axis of the articular head of the mandible is antero-posterior. The dentition differs from that of all

the other Lemurs (and indeed from that of all the other *Primates*), and resembles that of the Rodents.

Thus there is only one pair of incisors in each jaw,* and these grow from persistent pulps and have a thick layer of enamel on their anterior faces, whence they wear to sharp chisel edges, like the incisors of the *Rodentia*. No canines are developed, and there are four grinders with simple crowns on each side above and below.

The formula of the milk dentition is $d.i. \frac{2 \cdot 2}{2 \cdot 2} d.c. \frac{1-1}{0-0} d.m.$
 $\frac{2 \cdot 2}{1 \cdot 1}$

The *Lemuridæ* are confined to Eastern Asia, Madagascar, and South Africa; Madagascar presenting the greatest number and diversity of genera and species.

b. In the great group of the *Simiadæ*, which contains the Apes and Monkeys, the attitude is sometimes habitually quadrupedal, the axis of the body being horizontal; but, in a few species, the trunk is habitually held in a more inclined position, and the animals readily assume the erect attitude.

The *Simiadæ* are sometimes terrestrial in habit, and good runners, but they are always excellent climbers, and, in some cases, they are necessitated by their organization to be almost as thoroughly arboreal as the Sloths.

The hallux is always much shorter than the second digit of the foot, and capable of very free movement in adduction and abduction.

The series of the teeth, in each jaw, is interrupted by a diastema in front of the canine in the upper jaw, and behind it, in the lower; and the canine teeth are longer than the others, the points of their crowns projecting for a greater or less distance beyond the rest.

In the skull, the length of the basi-cranial axis equals more than half the extreme length of the cavity which contains the brain. The absolute capacity of the cranium

* Among the *Lemuridæ*, the outer and upper incisors of *Nycticebus* and *Tarsius* soon fall out. *Lichanotus* and *Tarsius* have only one pair of incisors in the mandible.

is less than forty cubic inches; and, if there is any difference in the length and abundance of the hair which covers

Fig. 110.

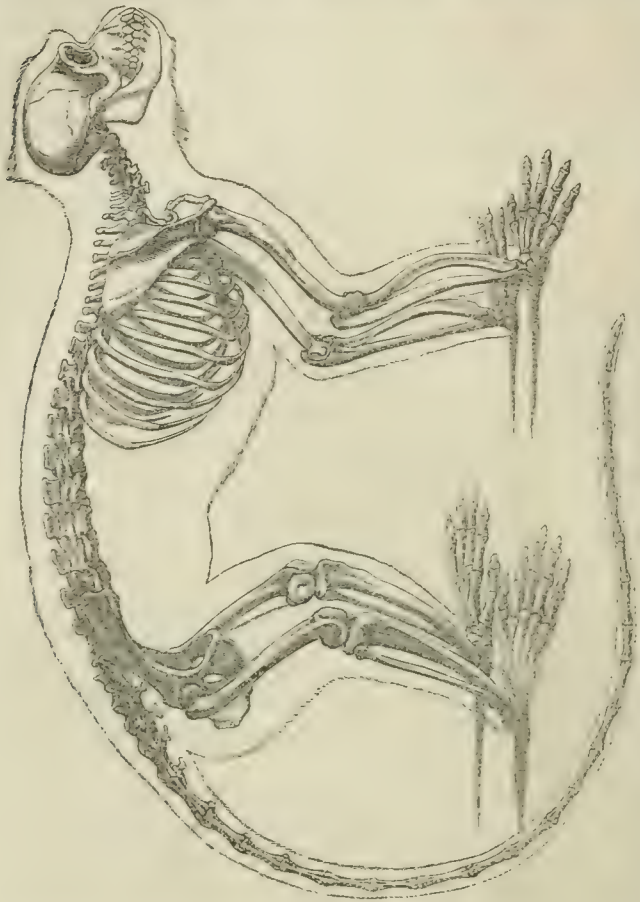


Fig. 110.—The skeleton of a Catarrhine Monkey (*Cercopithecus*).

the body, it is longest on the back. The uterus is undivided, and the clitoris is not perforated by the urethra. The teats are only two in number, and they are pectoral.

The *Simiadae* are divisible into three families—the *Arctopithecini*, the *Platyrrhini*, and the *Catarrhini*.

1. The *Arctopithecini*, or Marmosets, are small, thickly

furred, long-tailed, habitually quadrupedal, Squirrel-like, animals, which are found only in South America. None of them are provided with cheek pouches, nor possess bare and callous patches of integument over the ischia. The ears are large and hairy, and the nose is flat and broad, as in the *Platyrrhini*.

The fore limbs are shorter than the hind limbs. The pollex is not opposable, nor susceptible of extensive abduction from the other digits, which it resembles in being provided with a sharp curved claw. The manus, consequently, is a mere paw, and the term "hand" is not applicable to it. The hallux of the foot is very small and is provided with a flat nail. The nails of all the other digits of the pes are falcate. The plantar surface is very long, and the digits are very short. It follows from these facts that the term "quadrumanous" is not applicable, in any sense, to the Marmosets.

The skull is remarkable for the smooth and rounded surface and relatively large size of the brain-case. Although the orbits are large, the brow ridges are inconspicuous, and the occipital region of the skull projects so far backwards that the occipital foramen may lie completely upon the under surface of the skull, towards the junction of its middle and posterior thirds; and have its plane almost horizontal, when the face looks forwards. The orbit is almost completely shut off from the temporal fossa by bone.

The hyoid resembles that of the Lemurs, its body being narrow and much arched from side to side, while the anterior cornua are strong.

There are usually nineteen dorsolumbar vertebræ, and the transverse processes of the atlas are somewhat broad and flattened.

The dental formula is $i. \frac{2 \cdot 2}{2 \cdot 2} c. \frac{1-1}{1-1} p.m. \frac{3 \cdot 3}{3 \cdot 3} n. \frac{2 \cdot 2}{2 \cdot 2} = 32$.

Thus the number of the teeth is the same as in Man and the *Catarrhini*; but in the number of the premolars and molars the *Arctopithecini* differ from both the *Catarrhini* and the

Platyrrhini, having one premolar more than the former and one true molar fewer than the latter. In *Hapale*, the lower incisors are proclivous; and the canines are approximated to them, and similarly inclined, as in the Lemurs.

Although the manus is a paw and the pollex is not opposable, this digit has its proper *abductor*, *adductor*, and long and short flexors. The existence of a proper *opponens* of the pollex is doubtful, but there is an *opponens minimi digiti*. The *flexor longus* is completely united with the *flexor profundus digitorum*, but the tendon for the pollex comes off on the radial side instead of on the ulnar side, as it does in some of the higher *Simiadae*. The *extensor secundi internodii pollicis* is united with the *extensor indicis*, and the *extensor minimi digiti* gives off slips to the third, fourth, and fifth digits, so that there is a complete set of deep extensors. The four dorsal and three palmar *interossei* are not distinctly subdivided, but they send slips to the extensor tendons.

There are four *peronæi*: *p. longus*, *p. brevis*, *p. quarti*, and *p. quinti digiti*. The *flexor brevis digitorum* of the pes has one division which arises from the calcaneum and goes to the second digit; the other three heads arise from the tendons of the *flexor perforans*. The *flexor accessorius* furnishes almost the whole of the long flexor tendons of the hallux, the *flexor longus digitorum* supplying the perforating tendons of the second and fifth digits; while the *flexor hallucis longus* gives off the corresponding tendons of the third and fourth digits. The *interossei*, in the pes, appear to be represented only by the pairs of muscles which act as short flexors of the basal phalanges, and these lie altogether upon the plantar aspect of the five metatarsal bones. The hallux has no special *adductor*, nor is there any *transversus pedis*. In fact, the pes is almost as completely a "paw" as is the manus.

The brain has long and relatively large cerebral hemispheres, the posterior lobes of which project far beyond the cerebellum, and thus completely hide it, in the upper view of the brain. The external surfaces of the hemi-

spheres are almost smooth, but the Sylvian fissure is well marked, and there is a trace of that of Rolando. On the inner face of each hemisphere, the calcarine fissure is deep and gives rise to a well-marked *hippocampus minor* within the posterior cornu of the lateral ventricle. The *corpus callosum* has about a third the length of the hemispheres. The *septum lucidum* is very thick, and the precommissural fibres abundant. The *vermis* projects beyond the lateral lobes of the cerebellum, and the *floculi* are large.

2. The *Platyrrhini* are essentially quadrupedal and plantigrade, though some, like the Spider Monkeys (*Ateles*), occasionally assume the erect posture. They all possess tails, and in some genera (*e.g.* *Ateles*) this organ becomes very flexible and muscular, and the under surface of its extremity is devoid of hair and highly sensitive. The tail, thus modified, is a powerful prehensile organ, and serves as a fifth hand. The partition between the nostrils is broad and separates them widely, so that the nose is remarkably wide and flat, whence the name of the group. The ears are rounded and bare. There are no cheek pouches, nor ischial callosities, in any Platyrrhine Monkey. In most, the fore limbs are shorter than the hind limbs, but the reverse is the case in the Spider Monkeys. The pollex differs less from the other digits than it does in the *Catarrhini*. It is more nearly parallel with, and in the same plane as, the other digits of the manus; and though capable of extensive adduction and abduction, can hardly be said to be truly opposable. The hallux is large, and susceptible of extensive movements in abduction and adduction.

The number of the dorso-lumbar vertebræ varies from seventeen to twenty-two, the greatest number being possessed by *Nyctipithecus*, which has 22 (14 + 8 or 15 + 7). In those forms which have prehensile tails the terminal caudal vertebræ are flattened from above downwards. The articular surface of the head of the humerus looks more backwards than inwards; and, not unfrequently, there is a foramen above the inner condyle. The carpus contains nine bones. The pollex is generally complete, but, in *Ateles*,

it is reduced to a small metacarpal (to which, usually, a single minute nodular phalanx is articulated), and is completely hidden beneath the integument. The pelvis is, generally, elongated, and the anterior ramus of the pubis lies at right angles with the long axis of the narrow ilium. The tuberosities of the ischia are everted, but not rugose. In *Ateles*, the pelvis is broader, and the pubis forms a more open angle with the ilium. The calcaneal process is always very short, and compressed from side to side.

The brain-case is rounded and devoid of strong crests. There is no distinct mastoid process, and the styloid is not ossified. The coronal suture is generally V-shaped, the apex of the frontal bone extending far back on the vertex of the skull. The alisphenoid and the parietal bones unite upon the side walls of the skull. The external auditory meatus is not ossified, the tympanic bone retaining its fœtal hoop-like form. The frontal bones approach one another on the floor of the skull, but rarely unite over the junction of the presphenoid with the ethmoid. On the inner surface of the petrotic bone there is a fossa overarched by the anterior vertical semicircular canal, in which the flocculus rests. In *Ateles* the greater part of the tentorium is ossified. In other respects, the skull presents extraordinary variations among the *Platyrrhini*; the two extremes being presented by the Howling Monkeys (*Mycetes*) and the Squirrel Monkeys (*Chrysothrix*). In the former, the face is very large and prominent, with a low facial angle. The roof of the brain-case is depressed; the plane of the occipital foramen is almost perpendicular to the basi-cranial axis; and that of the tentorium is very much inclined. The occipital condyles are, consequently, situated at the posterior end of the *basis cranii*, and the basi-cranial axis is as long as the cerebral cavity. In *Chrysothrix*, on the contrary, the face is relatively small, with a high facial angle; the brain-case is moderately arched; the plane of the tentorium is horizontal, like that of the occipital foramen, which lies but little behind the middle of the base of the skull. The basi-cranial axis is much shorter than the

cerebral cavity. The premaxillo-maxillary suture disappears early in *Cebus*.

The formula of the adult dentition is $i. \frac{2 \cdot 2}{2 \cdot 2} c. \frac{1-1}{1-1} p.m. \frac{3 \cdot 3}{3 \cdot 3}$
 $m. \frac{3 \cdot 3}{3 \cdot 3} = 36$. The crowns of the molar teeth usually have two transverse ridges, ending in four cusps. In the upper molars of *Ateles* and *Mycetes* an oblique ridge crosses the crown from the antero-external to the postero-internal cusp. The permanent canines usually make their appearance before the last molar.

The stomach is simple, the cœcum large, and devoid of any vermiform appendix; the liver is usually five lobed; and the kidney has a single papilla.

The ventricles of the larynx are not usually developed into air-sacs. In *Ateles*, however, a median air-sac is developed from the posterior wall of the windpipe between the cricoid cartilage and the first ring of the trachea. A very remarkable modification of the hyoid and larynx takes place in *Mycetes*. The cornua of the hyoid are rudimentary, but its body is converted into a large thin-walled bony drum, the cavity of which communicates, beneath the large epiglottis, with that of the larynx. The thyroid cartilage is very large, and the cartilages of Wrisberg and Santorini are replaced by a fibrous mass, which is united posteriorly with its fellow of the opposite side. In addition to the hyoidean air-sac the ventricles of the larynx are dilated and prolonged upwards, coming into contact above the larynx; two pharyngo-laryngeal pouches may be added to these. *Mycetes* is famous for the distance to which its howling voice can be heard in the South American forests.

Although the pollex is rudimentary and apparently functionless in *Ateles*, all its characteristic muscles (*abductor*, *adductor*, *flexor brevis*, and *opponens*) are present, except the long flexor.

In *Nyctipithecus* the pedal *interossei* are *flexores breves*, and lie on the plantar surfaces of the metatarsal bones, as in the Marmosets; but both the *adductor hallucis* and the *transversus pedis* are well developed.

The brain varies remarkably in different *Platyrrhini*. In *Chrysothrix*, the cerebral hemispheres project beyond the cerebellum to a greater relative extent than in any other Mammal, namely, by one-fifth of their total length. On the other hand, in *Mycetes*, the cerebral hemispheres hardly hide the cerebellum, when the brain is viewed from above.

In *Cebus*, the outer surface of the brain is almost as much convoluted as in the Catarrhine Apes. *Ateles* has the external perpendicular fissure almost obliterated by the annectent gyri, and, so far, exhibits a higher type of brain than the *Catarrhini*; but, in *Pithecia*, *Chrysothrix* and *Nyctipithecus*, the external sulci gradually disappear, until the brain is almost as smooth as in the Marmosets. On the inner faces of the hemispheres, however, the internal perpendicular, the calloso-marginal, the calcarine, and the collateral sulci remain, while, in the interior of the hemispheres, the posterior cornu and the *hippocampus minor* are always present.

The *vermis* of the cerebellum is large and projects beyond the level of the posterior margins of its hemispheres; the *floculus* is large and lodged in a fossa of the periotic ossification, as in the Marmosets. The upper ends of the pyramids are separated by *corpora trapezoidea* from the *pons Varolii*.

The penis is usually terminated by a large button-shaped glans. The cavity of the *tunica vaginalis* is not shut off from the abdomen, and the testes lie at the sides of, rather than behind, the penis. The female *Ateles* has a long clitoris, which depends from the vagina.

The *Platyrrhini* occur only in the Austro-Columbian province, and are known in the fossil state only in certain caves of that region.

3. The *Catarrhini*.—The *Simiadae* of this division present a great range of variation in most respects, but they agree in having the partition between the nostrils narrower than in the *Platyrrhini*; in possessing a bony meatus auditorius; in the dental formula $i. \frac{2 \cdot 2}{2 \cdot 2} c. \frac{1 \cdot 1}{1 \cdot 1} p.m. \frac{2 \cdot 2}{2 \cdot 2} m. \frac{3 \cdot 3}{3 \cdot 3}$, and in

being inhabitants of the old world. They fall into two very distinct groups, the *Cynomorpha* and the *Anthropomorpha*.

a. The *Cynomorpha* are distinguished from the other group by being essentially quadrupedal and, usually, provided with a tail, which is never prehensile. The femur and tibia, taken together, are longer than the humerus and the radius. The outer inferior incisors are not larger than the inner ones, but are often smaller. The crowns of the molar teeth present two transverse ridges, a third being present, in some genera, on the last inferior molar.

All the *Cynomorpha* have ischial callosities, which sometimes attain a very large size, and are brightly coloured.

The dorsolumbar region of the spinal column is concave towards the ventral aspect, and the lumbo-sacral angle is very large. The atlas has narrow transverse processes. The ordinary number of dorsolumbar vertebræ is nineteen, of which twelve, or thirteen, are dorsal; and seven, or six, lumbar. The middle cervical vertebræ have short spines, which are not bifurcated at their extremities. In the posterior dorsal, and anterior lumbar, vertebræ, the mammillary and accessory processes may be enlarged and interlock. The long transverse processes of the lumbar vertebræ bend forwards. The sacrum usually contains only three ankylosed vertebræ. The caudal vertebræ vary in number, from three in *Inuus* (where they form little more than a coccyx), to as many as thirty-one. In the anterior part of the tail the vertebræ are provided with subvertebral, or chevron, bones.

The thorax is laterally compressed, and the manubrium of the sternum is broad; but the six or seven sternæ which follow it are compressed and constricted.

The skull presents a considerable range of variation. In the *Semnopithec*i and *Colobi*, the frontal region is rounded, the facial angle is comparatively large, and the ascending portion of the ramus of the mandible is high. In the *Macaci* and *Cynocephali*, on the other hand, the supra-orbital ridges become so much enlarged as to hide the forehead; and the horizontal portion of the ramus of the

mandible is much larger than the ascending portion, in accordance with the great production of the upper jaw, and the consequent low facial angle. In many of the *Cynocephali*, longitudinal osseous ridges are developed upon the maxillæ, and greatly increase the brutishness of their aspect. Sagittal and lambdoidal crests may appear along the lines of the corresponding sutures. There is no distinct mastoid process; and the styloid process is not ossified. The parietal bones do not unite with the alisphenoids, being separated from them by the union of the squamosals with the frontals. The brain case is flattened and elongated, and the convex roofs of the orbits project into it and greatly diminish the capacity of its frontal portion. The olfactory fossæ are very deep, and sometimes almost tubular. The two frontal bones send thick processes across the base of the skull, which unite over the junction of the presphenoid and the ethmoid, and thus narrow the entrance to the olfactory fossæ. The basicranial axis is shorter than the cerebral cavity, but is still proportionally long. The occipital foramen lies in the posterior sixth of the base of the skull, and it looks obliquely backwards and downwards. The premaxillo-maxillary suture never disappears until long after the second dentition is complete, and may persist throughout life. The palate is long and narrow. The nasal bones are flat, and early ankylose into one bone.

The scapula is relatively longer and narrower than that of Man; but the spine lies at right angles to the vertebral border, and the supra-spinous, is much smaller than the infra-spinous fossa.

The axis of the articular head of the humerus is not directed upwards and inwards, but upwards and backwards; the bicipital groove lies on the inner side; and the shaft of the bone is so bent that it is convex forwards. In all these characters the fore limb shows its relation to the function of support. The radius exhibits modifications which have the same signification. Its proximal head is transversely elongated, and lies somewhat in advance of the ulna,

articulating more largely with the humerus than in the higher Apes. The neck of the radius (between the head and the bicipital tuberosity) fits more closely to the ulna, and hence the movements of pronation and supination are restricted.

There are nine bones in the carpus. The pisiforme is much elongated, making a sort of heel for the manus. Together with the cuneiforme, it furnishes an articular face for the ulna. The distal articular surface of the trapezium is saddle-shaped, and the pollex is usually complete, though short relatively to the other digits. In *Colobus* it is rudimentary.

The pelvis is long and narrow. The ilia are narrow bones with much-excavated posterior and outer faces. Their crests generally lie opposite the transverse processes of the penultimate lumbar vertebra. The long axis of the ilium and that of the anterior ramus of the pubis cut one another nearly at a right angle; while the long axis of the ilium and that of the posterior ramus of the ischium lie nearly in one straight line. The symphysis pubis is very long, and the subpubic arch correspondingly reduced. The posterior ends of the ischia are everted, broad and rough, for the attachment of the callous pads of integument. The femur has a round ligament. The tarsus has not more than one-third the length of the foot. The calcaneal process is flattened from side to side, and has a pulley-like excavation upon its posterior extremity. The tibial facet of the astragalus is inclined slightly inwards, as well as upwards, and its outer edge is raised. The distal division of the tarsus, consisting of the cuboid and navicular, with the cuneiform bones, is capable of a considerable amount of rotatory motion upon the astragalus and the calcaneum. The entocuneiform bone is large, and has a transversely-convex articular surface for the metatarsal of the hallux. Consequently the latter (which is short, reaching to only about the middle of the proximal phalanx of the second digit) is capable of free motion in abduction and adduction.

In the *Cynomorpha*, and even in the so-called "tail-less"

genus, *Inuus*, proper caudal muscles are present. In the limbs there is a *levator claviculæ* which passes from the transverse process of the atlas to the acromion; a *dorso-epitrochlearis*, consisting of a muscular bundle detached from the *latissimus dorsi* near its insertion, and passing to the distal and inner end of the humerus, or even further down; a *scansorius*, from the ventral edge of the ilium to the great trochanter, which sometimes becomes confounded with the *glutæus minimus*; a special *abductor ossis metacarpi quinti*; and a *peronæus quinti digiti*, arising from the fibula, between the *peronæus longus* and *brevis*, passing behind the external malleolus, and sending its tendon to the extensor sheath of the fifth digit.

The *extensor primi internodii pollicis* and the *peronæus tertius* are absent in this, as in the preceding group.

The *biceps femoris* usually possesses only an ischial head, and the *soleus* arises only from the fibula. The *flexor brevis digitorum* arises partly from the tendon of the *plantaris*, where this passes over the pulley on the posterior surface of the calcaneal process to become continuous with the plantar fascia, and partly from the tendons of the long flexor. The *transversus pedis* is usually fully developed, but has only two heads of origin from the distal ends of the second and third metatarsals. The *interossei pedis* are just visible on the dorsal aspect of the foot, but none are, properly speaking, dorsal. None of them are penniform muscles arising from adjacent sides of the metatarsal bones; but they are attached, in pairs, to the plantar and lateral aspects of the metatarsal bones of the digits to which they appertain. They are inserted into the sesamoid bones, of which each digit has two, and into the bases of the proximal phalanges, and give off no distinct tendons to the extensor sheaths. Additional muscles may arise over the proximal ends of the metatarsal bones, and pass to the three fibular digits.

The *interossei manûs* are very similar to those of Man, being divided into a dorsal and a palmar set, and sending slips to the extensor sheaths of the digits, without that complete subdivision which is seen in the *Anthropomorpha*.

There is a complete double set of extensors in the four ulnar digits of the manus, the *extensor minimi digiti* giving a tendon to the fourth digit, and the *extensor indicis* one to the third digit. The *extensor ossis metacarpi pollicis* gives a distinct slip to the trapezium, and thus precisely corresponds with the *tibialis anticus*, which has two tendons, one for the ento-cuneiform, and one for the metatarsal of the hallux. The *flexor digitorum profundus* and *flexor longus pollicis* are represented by one muscle, a slip from the ulnar side of the tendon of which usually goes to the pollex.

The tendons of the *flexor perforans digitorum* and *flexor hallucis* unite to form the deep flexor tendons of the pedal digits in very variable proportions. The *flexor accessorius* is very generally present.

The anterior upper premolar has its outer cusp peculiarly modified and sharpened. The anterior lower premolar has the anterior margin of its crown prolonged and cutting, so that it works, like a scissor-blade, against the posterior edge of the upper canine. In the upper jaw, the premolars have three roots; in the lower, two. The molars in both jaws have four cusps connected by two transverse ridges. Sometimes there is "heel" behind the posterior ridge of the last lower molar.

The formula of the milk dentition is $d.i. \frac{2 \cdot 2}{2 \cdot 2} d.c. \frac{1-1}{1-1} d.m.$
 $\frac{2 \cdot 2}{2 \cdot 2} = 20$; and the anterior milk molar resembles the permanent premolars, while the posterior is like a permanent molar.

The permanent canines make their appearance before or, at latest, contemporaneously with, the hindermost molar in both jaws. They are large and long, and are separated, by a well-marked diastema, from the outer incisor above, and from the first premolar below.

The *Cynomorpha* very generally possess cheek-pouches, which serve as pockets for the temporary stowage of food. The stomach is usually simple, with a globular cardiac extremity and an elongated pyloric portion; but, in *Semnopithecus* and *Colobus*, the stomach is divided into three com-

partments, the middle of which is sacculated. A groove with raised edges leads from the cardiac end of the gullet to the middle compartment.

The cœcum, though distinct, is relatively small, and has no vermiform appendage.

The liver varies much in the degree of its subdivision into lobes, being least divided in the *Semnopitheci*, and most in the Baboons. The innominate artery generally gives origin to both carotids, as well as to the right subclavian, the left subclavian arising directly from the arch of the aorta.

When laryngeal air sacs are developed, they are not formed by dilatations of the lateral ventricles of the larynx; but a single sac, with a median aperture, is formed in the thyro-hyoidean space immediately beneath the epiglottis. This median air sac is very large, extending down over the front of the neck, and sending processes into the axillæ, in some *Semnopitheci* and *Cynocephali*. The right lung is usually four-lobed, the left two-lobed.

The kidney has only a single papilla.

The posterior lobes of the cerebrum project beyond the cerebellum in all the *Cynomorpha*; they are shortest in the *Semnopitheci*, and longest in the *Cynocephali*. The principal sulci and gyri which are found in the human brain are always indicated; but the external perpendicular fissure is strongly marked. The posterior cornu of the lateral ventricle is large, and there is a strongly-marked *hippocampus minor*.

There is usually, if not always, a bone in the penis, which is provided with two special retractor muscles. The females are subject to a periodical turgescence of the sexual organs, sometimes accompanied by hæmorrhage, and comparable to menstruation. The placenta is often bilobed.

b. The *Anthropomorpha* differ from the *Cynomorpha* in the following characters: They are especially arboreal animals, which habitually assume a semi-erect posture, supporting the weight of the fore part of the body upon the ends of the fingers or, more usually, upon the knuckles. There is

no tail. The thigh and the leg are, respectively, shorter than the arm and the fore arm. The dorsolumbar vertebræ are seventeen or eighteen in number, and their spines are not inclined towards a common point. They develop no interlocking mammillary and accessory processes. The sacrum contains more than three ankylosed vertebræ. The thorax is rather broad than laterally compressed, and the sternum is flattened from before backwards, and wide. The axis of the head of the humerus is directed more inwards than backwards, and the upper part of the shaft is not bent as in the *Cynomorpha*. The radius is capable of complete pronation and supination.

The relative proportions of the incisor teeth are the same as in Man; that is to say, the inner upper incisors and the outer lower incisors are larger than the others. The crowns of the upper and lower molars have the same patterns as those of Man.

The caudal muscles are small or absent. When the pollex has a flexor tendon, that tendon is not a slip given off from one common to the *flexor pollicis* and *flexor perforans*, as in the *Cynomorpha*. The plantaris does not pass over a pulley furnished by the calcaneal process, as in the *Cynomorpha*; and the *flexor brevis* has an origin from that process. The *peronæus quinti digiti* has not been observed.

There are three well-marked genera of *Anthropomorpha*—*Hylobates*, *Pithecus*, and *Troglodytes*; and perhaps a fourth, *Gorilla*, may be advantageously separated from the last-named.

Pithecus, the Orang, has the smallest distributional area, being confined to the islands of Borneo and Sumatra; *Hylobates*, the Gibbons, of which there are several species, is found over a considerable area of Eastern Asia and the islands of the Malay Archipelago. The *Chimpanzee* and *Gorilla* are met with only in the intertropical parts of West Africa.

The Gibbons are those *Anthropomorpha* which are most nearly allied to the *Cynomorpha*. They possess ischial callosities, and the nails of the pollex and hallux, only, are

broad and flat. The arms are so long that the points of the fingers readily touch the ground when the animal stands upright, as it very readily and commonly does. The Gibbons also run with great swiftness, putting the sole of the foot flat on the ground and balancing themselves with their long arms. Nevertheless, they are essentially arboreal animals, leaping from bough to bough of the trees in the forests which they frequent with marvellous force and precision. The manus is longer than the pes, and the antebrachium considerably longer than the brachium. The Gibbons do not exceed three feet in height; their heads are small, and their bodies and limbs remarkably slender.

None of the other *Anthropomorpha* have callosities, and the nails of all the digits are flattened. They are all heavier in make, with proportionally shorter limbs and larger heads than the Gibbons. In the Orangs, which rarely attain a stature of more than four feet and a half, the arms are very long, their span, when outstretched, being nearly double the height of the animal. The brachium and the antebrachium are equal in length. The long and narrow pes is longer than the equally-narrow manus, and the sole cannot be placed flat upon the ground, but the animal rests upon the outer edge of the foot when it assumes the erect posture. This posture, however, is quite unnatural, and the Orangs cannot run as the Gibbons do, but swing themselves along upon their long arms, as it were upon crutches.

The pollex and the hallux are both short, the latter remarkably so; and the hallux is not uncommonly devoid of a nail. The palmar and plantar aspects of the digits are naturally concave, and they cannot be completely straightened.

The Chimpanzee attains a stature somewhat greater than that of the average Orang. The span of the arms is about half as much again as the height. The antebrachium is about as long as the brachium. The manus is equal to, or a little longer than, the pes; and these parts of the limbs are not so elongated, or so curved, as the corresponding parts of the Orang. The sole can be readily placed flat upon the

ground, and the Chimpanzee easily stands or runs erect. But his favourite attitude is leaning forward and supporting himself on the knuckles of the manus. Both the hallux and the pollex are well developed and possess nails.

The Gorilla exceeds five feet in height and may reach five feet six inches. The span is to the height as about three to two. The brachium is much longer than the antebrachium. The pes is longer than the manus, and both are much broader than in the other *Anthropomorpha*. In consequence of this circumstance and of the greater development of the heel, the erect posture is easily maintained, but the ordinary attitude is the same as that assumed by the Chimpanzee. The hallux and the pollex have well-developed nails. The basal phalanges of the three middle digits of the foot are bound together by the integument.

With respect to the skeleton in the *Anthropomorpha*, the Gibbons have the spinal column nearly straight, with a very open vertebro-sacral angle. In the Orangs the dorsolumbar vertebræ form a curve, which is nearly as much concave forwards as in a new-born child. In the Chimpanzee the spinal column begins to exhibit the curvatures which are characteristic of the adult human subject; and these are still more marked in the Gorilla.

The spinous process of the second cervical vertebra is bifurcated in the Chimpanzee, but this human character does not appear in the others.

In the Gibbons there are usually eighteen dorsolumbar vertebræ; but in the other *Anthropomorpha* the number is ordinarily seventeen, as in Man, or may be reduced to sixteen. The Orang has the human number of twelve pairs of ribs; but the Chimpanzee and Gorilla have thirteen, and the Gibbons may possess fourteen pairs of ribs. The thorax is wide, and the sternum broad and flat. In the Orang it may ossify from a double longitudinal series of centres, as sometimes happens in Man.

In the Gibbons the transverse processes of the last lumbar vertebra are not exceptionally broad, and do not unite with the ilia. But in both the Chimpanzee and Gorilla they

are wide, and become more or less closely connected with the ilia. The last lumbar vertebra may become ankylosed with the sacrum in the Gorilla. All these conditions of the last lumbar vertebra are occasionally met with in Man.

The sacrum is broad, and contains not fewer than five ankylosed vertebræ, but its length always exceeds its breadth (whereas its breadth is equal to, or exceeds, its length, in Man), and its anterior curvature is but slight. The short coccyx is made up of not more than four or five vertebræ. In the skull, the proper form of the brain-case is always more or less disguised in the adult males, by the development of crests for muscular attachment, or of the orbits and the supraorbital ridges. In the Gibbons and Chimpanzees, the latter are large, but the sagittal crest is absent, and the lambdoidal small. In the Orang, the brow ridges are small, so that the true form of the forehead is seen better than in the other Apes, but the sagittal and lambdoidal crests are strong. In the old male Gorilla the sagittal and lambdoidal crests, and the supraorbital ridges, are alike enormous. The frontal sinuses are large, and extend into the brow ridges both in the Gorilla and Chimpanzee. The jaws are largest in proportion to the brain case in the Gorilla and the Orang; smallest in some varieties of Chimpanzee.

In all the *Anthropomorpha* the transverse is much less than the longitudinal diameter of the cranial cavity. The roofs of the orbits project into the frontal portion of the brain case, and diminish its capacity by causing its floor to slope from the middle line obliquely upwards and outwards. The occipital foramen is situated in the posterior third of the base of the skull, and looks obliquely backwards and downwards. The frontals meet in the base of the skull over the ethmo-presphenoidal suture in the Gibbons and in the Gorilla, as in the Baboons; but not in the Chimpanzee or the Orang. The alisphenoids unite suturally with the parietals, as is the rule in Man, in the Gibbons and (usually) in the Orangs; but, in the Chimpanzee, the squamosal unites with the frontal and separates the alisphenoid from the parie-

tal, as happens, exceptionally, in Man. The nasal bones are flat and early ankylosed together, in the Gibbons, Orangs, and Chimpanzees. In the Gorilla the nasal bones are distinctly convex from side to side, and rise above the level of the face. None of these Apes has a *spina nasalis anterior*; and, only in the Siamang, is there a rudiment of the mental prominence in the mandible. The premaxillo-maxillary suture persists beyond the completion of the second dentition in all but the Chimpanzee, in which it disappears before that period. The epiotic region is never developed into a distinct mastoid process; and there is an ossified styloid process only occasionally in the Orangs. The palate is long and narrow, the alveolar margins being nearly parallel, or even diverging anteriorly. The zygomatic arches are strong, wide, and curved in two directions.

The proportion of the length of the basi-cranial axis to that of the cerebral cavity, does not fall lower than the ratio of 10 to 17 in any of the *Anthropomorpha*.

The body of the hyoid approaches the form of that of Man most nearly in the Orang. In the other genera it is more excavated posteriorly.

The scapula of the Orang is most like that of Man, especially in the proportion of the supra- and infra-spinous fossæ, in the proportional length of the anterior and the posterior borders, and in the angle made by the spine with the vertebral margin. In the other genera the posterior border is longer in proportion than in Man, and the spine of the scapula cuts the vertebral margin more obliquely. After the Orang's, the scapula of the Gorilla comes nearest to that of Man.

On the other hand, the long and straight clavicle of the Orang is least like that of Man.

The head of the humerus loses the backward inclination which it has in the lower Apes, and becomes directed upwards and inwards, as in Man. The radius and ulna are curved, and leave a wide interosseous space. There are nine bones in the carpus in both *Hylobates* and *Pithecus*, but only eight in the Chimpanzee and Gorilla. In *Hylo-*

bates the articular surface presented by the trapezium for the pollex is almost globular. It is evenly convex in the Chimpanzee; but, in the Gorilla, it has the characteristically human saddle shape. The pollex is longest and strongest in proportion in *Hylobates*; its length in proportion to that of the manus being in *H. syndactylus* as three to seven. In the Gorilla, the pollex has rather more than one-third the length of the manus; in the Orang and Chimpanzee it has about one-third the length of the manus.

The pelvis differs but little from that of the *Cynomorpha* in *Hylobates*. In the other genera the pelvis is still elongated. The antero-posterior diameter of the brim of the pelvis greatly exceeds the transverse, the tuberosities of the ischia are strongly everted, and the pubic symphysis is very long, the arch being correspondingly reduced; but the ilia are wider and more concave forwards in the Chimpanzee, than in the Orang, and in the Gorilla than in either.

In the female Chimpanzee, which is of about the same size as the male, the dimensions of the basin of the pelvis, and of its outlets, are greater than in the male, though the general form and absolute length of the pelvis are the same in the two sexes. The female Gorilla is much smaller than the male, and the pelvis is shorter in proportion, but the intersciatic measurement of the outlet is absolutely as great as in the male, and the transverse diameter of the brim is nearly as great. As, at the same time, the antero-posterior diameter is much shorter, the brim of the pelvis of the female is much more round. The female Orangs, also, are smaller than the males. The basin of the pelvis is relatively, but not absolutely, larger in all its dimensions, and the brim rounder.

The femur of the Orang has no round ligament, and differs in this respect from the same bone in the other *Anthropomorpha*. The femur of the Gorilla resembles that of Man, most especially in the projection of the articular surface of the inner condyle beyond the outer.

The length of the whole foot to that of the tarsus is, in *Hylobates*, as thirty-five to ten, and the proportion is about

the same in the Orang; in the Chimpanzee it is as twenty-four to ten; and, in the Gorilla, about the same (twenty-three to ten in the specimen measured).

The hallux has not more than one-fourth of the length of the foot in the Orang; in the Gorilla less than five-twelfths; in the Chimpanzee and in *Hylobates* a little more.

In the second digit of the pes of the Orang and the Chimpanzee, the phalanges, taken together, are longer than the metatarsal bone of the digit; in the Gorilla, they are about equal in length to the metatarsal. The calcaneal process is longest, strongest, and broadest in the Gorilla. In the astragalus the articular surface for the tibia is broadest in the Gorilla; but, in this Ape, as in the others, it is inclined a little inwards when the foot is in its natural position; and the surface for the external malleolus is oblique, and looks upwards as well as outwards.

It is a mistake, however, to suppose that the disposition of these surfaces has anything to do with the more or less marked tendency of the plantar surface to turn inwards, and of the outer edge of the pes to be directed downwards, which is observable in all the *Anthropomorpha*. This tendency is the result of the free articulation between the scaphoid and the cuboid, on the one hand, and the astragalus and the calcaneum on the other; the consequence of which is that the distal portion of the pes, with the first-mentioned bone, being pulled by the *tibialis anticus*, easily rotates round its own axis, upon the surface presented by the astragalus and calcaneum. This ready inversion of the sole must as much facilitate climbing, as it must interfere with the steadiness of the foot in walking.

The distal surface of the entocuneiform is much inclined inwards in all the *Anthropomorpha*, and is convex from side to side, or subcylindrical. The metatarsal bone of the hallux presents a corresponding articular concavity to this surface, and has a great range of motion in adduction and abduction. The inward inclination of the articular facet of the entocuneiform, and its consequent separation from the facet upon the mesocuneiform for the second digit, is

greatest in the Orang, in which the hallux is habitually directed at right angles to the long axis of the foot. The distal phalanx of the hallux is not unfrequently absent in the Orang.

All the *Anthropomorpha* possess certain muscles which are not usually found in Man, though they may occur as varieties in the human subject. These are the *levator claviculæ*, the *dorso-epitrochlearis*, the *scansorius*,* and the *abductor ossis metacarpi quinti digiti*. They are also devoid of two muscles which are usually present in Man—the *extensor primi internodii pollicis*† and the *peronæus tertius*. The former of these is sometimes, and the latter frequently, wanting in the human subject.

The *flexor accessorius* appears to be regularly absent in *Hylobates* and *Pithecus*, and, in the majority of cases, in the Chimpanzee. The *transversus pedis* seems to be absent in the Orang, but it is present in the other *Anthropomorpha*.

Many muscles which exist both in these Apes and in Man have different origins in the former. Thus, the *solæus* has only a fibular head, and takes no origin from the tibia. The *flexor brevis digitorum pedis* never arises altogether from the calcaneum, but a large proportion of its fibres spring from the tendons of the deep flexors. The calcaneal head furnishes the tendons for the second, or the second and third, digits. The interosseous muscle which lies on the tibial side of the middle digit of the pes, usually arises from the fibular side of the second metatarsal as well as from the tibial side of its own metatarsal, and its origin lies on the dorsal side of that of the fibular interosseous muscle of the second digit. Hence, of the so-called dorsal *interossei* (or *interossei* which are visible on the dorsal aspect of the pes) two belong to the middle digit, and one, to the second and fourth digits respectively; which is the same arrangement as that which obtains in the

* Not actually described in the Gorilla, and absent in some Chimpanzees.

† The former muscle is said to be present by several anatomists in the Chimpanzee and other Apes; but what they have taken for it is the metacarpal division of the *extensor ossis metacarpi*.

manus. The *flexor pollicis* is more or less closely connected with the *flexor communis perforans*, or with that part of the muscle which goes to the index digit. The connection is slightest in *Hylobates*, the origins of the two muscles, only, being united. It is most extensive in the Orang, in which no tendon goes to the pollex. The same complete loss of the *flexor pollicis*, as a thumb muscle, occasionally takes place in the Gorilla; but in this animal, as in the Chimpanzee, the rule appears to be, that the *flexor pollicis* unites at its origin with part of the *flexor perforans*, and that the fleshy fibres converge to a common tendon which divides into two, one for the pollex and the other for the index. In *Hylobates*, the short head of the *biceps brachii* arises from the *pectoralis major*, and the *adductor hallucis* and *transversus pedis* form but one muscle.

The *flexor longus hallucis* takes an origin from the external condyle of the femur in the Orang; and the *pectoralis major* arises by three distinct slips.

Some of the muscles in the *Anthropomorpha* differ in their insertion, or in the extent to which they are subdivided, from what is usual in the corresponding muscles of Man. Thus the *extensor ossis metacarpi pollicis* ends in two distinct tendons; one for the trapezium, and the other for the base of the metacarpal bone of the pollex. That part of the *tibialis anticus* which goes to the metatarsal of the hallux is usually very distinct, and is sometimes reckoned as a separate muscle, the *abductor longus hallucis*.

In the Gibbons and in the Orang, there is a complete set of deep extensors for the four ulnar digits, the tendons of the *extensor indicis* and *extensor minimi digiti* subdividing to supply the third and fourth digits.

In the Gorilla and Chimpanzee each of these muscles have but a single tendon, as is the usual arrangement in Man.

The interossei of the hand are each divided into two muscles with distinct tendons—a *flexor brevis primi internodii* and an *extensor brevis tertii internodii*. The division is less obvious in the Orang than in the other *Anthropomorpha*.

In *Hylobates*, the tendon of the *flexor perforans pedis* goes only to the fifth digit, and is not directly connected with that of the *flexor longus hallucis*, which supplies the other four digits. In the Orang, also, the tendons of the two muscles are separate; but the *flexor perforans* supplies the second and the fifth digits, and the *flexor hallucis* the third and fourth. It gives no tendon to the hallux. In both the Chimpanzee and the Gorilla, a very large tendon is given to the hallux by the *flexor hallucis*, and it also supplies the third and fourth digits. The tendon of *flexor longus digitorum* is but slightly connected with that of the *flexor hallucis*, and its divisions go to the second and fifth toes. In both the manus and the pes of *Hylobates* a muscle occurs which is not, at present, known in any other Mammal. It arises from the second metacarpal or metatarsal bone, and is inserted by a long tendon into the pre-axial side of the unguis phalanx of the second digit; it may be termed "*abductor tertii internodii secundi digiti*."

The Orang, in like manner, stands alone in possessing a small, but distinct *opponens hallucis*.*

The volume of the brain, in the Orang and in the Chimpanzee, is about twenty-six or twenty-seven cubic inches; or about half the minimum size of a normal human brain. In the Gorilla, the volume rises to near thirty-five cubic inches. In the Gibbons the brain is very much smaller; and the Siamang, among these, is remarkable for the short posterior lobes of the cerebrum, which, in this anthropomorphous Ape, do not overlap the cerebellum, as they do in all the others.

The cerebral hemispheres are higher in proportion to their length in the Orang than in the other *Anthropomorpha*; but, in all, they are elongated and depressed, as compared with those of Man. The frontal lobes taper off anteriorly, and their inferior surfaces are excavated from without downwards and inwards, in correspondence with the pro-

* It must be borne in mind that these statements respecting the myology of the *Anthropomorpha* are based upon my own dissections (sometimes supplemented by those of Duvernoy and other anatomists) of particular specimens. Endless varieties will no doubt be met with by those who carry their inquiries further.

jection of the upwardly convex roofs of the orbits into the cranial cavity. The posterior cornu of the lateral ventricle is always well developed, and contains a prominent *hippocampus minor* and *eminentia collateralis*. An occipito-temporal or "external perpendicular" sulcus is always present. It is most nearly obliterated in the Orangs. All the gyri of the human brain are represented in the cerebral hemispheres of the Chimpanzee; but they are simpler and more symmetrical, and larger in proportion to the brain (See Figs. 21 and 22). The fissure of Sylvius is less inclined backwards, and that of Rolando is placed more forwards than in Man. The insula has simpler and fewer radiating sulci, and is not completely hidden by the temporal lobe. Only the second, third, and fourth annectent gyri appear upon the surface. The first remains folded upon itself, and gives rise to the characteristically simian occipito-temporal or external perpendicular sulcus. The occipito-parietal sulcus, on the inner face of the hemisphere, is much more nearly perpendicular than in the human brain. The corpus callosum is relatively smaller; the septum lucidum is very thick, and the pre-commissural fibres are well developed. The vermis is small in proportion to the lateral lobes of the cerebellum, and the flocculi are relatively small, and lie below the latter.

The whole cerebellum is larger in proportion to the cerebral hemispheres; the latter being to the former, as $8\frac{1}{2}$ to 1 in Man, but as $5\frac{3}{4}$ to 1 in the Chimpanzee.* The nerves are larger in proportion to the brain than in Man. There are no *corpora trapezoidea*, such as exist in the lower Mammals, and the *corpora albicantia* are double.

In all the *Anthropomorpha*, the inner incisors are larger than the outer, in the upper jaw; smaller, in the lower jaw. There is a diastema, though it is often but small in the female Chimpanzees. The canines are large and strong, and may be grooved longitudinally on their inner sides.

* It must be recollected that the brains of young anthropomorphous Apes, only, have been examined. Perhaps this has to do with the absence of mineral deposits in the pineal gland of the Apes.

The premolars have three roots in the upper jaw, two in the lower. The crowns of the middle molars, above, have four cusps, and an oblique ridge which extends from the antero-external to the postero-internal cusp; and those of the middle molar, below, have five cusps, as in Man. The crown of the anterior premolar in the lower jaw is pointed, and has a long, sharp, oblique anterior edge as in the *Cynomorpha*.

In the Gibbons, the permanent canine emerges contemporaneously with, or before, the last molar; but, in the other *Anthropomorpha*, the last permanent canine is cut, ordinarily, only after the appearance of the last molar.

In the Orang the circumvallate papillæ of the tongue are arranged in a V, as in Man. In the Chimpanzee they are disposed like a T, with the top turned forwards. The Chimpanzee and the Siamang have an uvula, but the Orang has none. The stomach of the Chimpanzee is very like that of Man; but in the Orang the organ is more elongated, with a round cardiac and more tubular pyloric portion. An *appendix vermiformis* is found in the cæcum of all four genera. In the Chimpanzee and Gorilla, the origin of the great arteries from the arch of the aorta takes place as in Man. In the Orang, they are sometimes disposed as in Man; while in other specimens the left carotid comes off from the innominata, and only the subclavian of the left side arises directly from the aorta. In *Hylobates*, the latter arrangement appears to obtain.

The kidney has only a single papilla in *Hylobates* and *Pithecus*.

Only one species of *Hylobates*, namely, the Siamang, is known to possess a laryngeal sac. This is globular, and communicates by two apertures, situated in the thyrohyoid membrane, with the larynx. In the Orang, Chimpanzee, and Gorilla, enormous air sacs result from the dilatation of the lateral ventricles of the larynx. These dilatations extend down, in front of the throat, on to the thorax and even into the axillæ, and sometimes open into one another in the middle line.

In the adult male Chimpanzee the penis is small and

slender, and terminates in a narrow and elongated glans. The testes are very large, and the communication between the tunica vaginalis and the peritoneum is completely closed. The glans penis of the Gorilla is button-shaped. In the Orang it is cylindrical, and the testes are situated close to the inguinal canal, which has been found open on one side, and closed on the other. An os penis is developed in the males.

The females have the clitoris large, and the uterus, which is undivided into cornua, resembles that of the human subject. The placenta of a Chimpanzee fœtus, $11\frac{1}{2}$ inches long, was simple, rounded, $3\frac{1}{2}$ inches in diameter, and 0·6 inch thick in the centre. The umbilical cord was inserted near one of its edges.

The proportions of the limbs to one another and to the body do not sensibly change after birth; but the body, limbs and jaws, enlarge to a much greater extent than the brain-case.

The amount of variation in the characters of the skull among the Chimpanzees, Gorillas, and Orangs, is exceedingly remarkable, especially if taken in connection with their very limited areas of distribution.

Of the four genera of the *Anthropomorpha*, the Gibbons are obviously most remote from Man, and nearest to the *Cynopithecini*.

The Orangs come nearest to Man in the number of the ribs, the form of the cerebral hemispheres, the diminution of the occipito-temporal sulcus of the brain, and the ossified styloid process; but they differ from him much more widely in other respects, and especially in the limbs, than the Gorilla and the Chimpanzee do.

The Chimpanzee approaches Man most closely in the character of its cranium, its dentition, and the proportional size of the arms.

The Gorilla, on the other hand, is more Man-like in the proportions of the leg to the body, and of the foot to the hand; further, in the size of the heel, the curvature of the spine, the form of the pelvis, and the absolute capacity of the cranium.

c. The *Anthropidæ* are represented by the single genus and species, Man, and they are distinguished from the *Simiadaæ*, and especially the *Anthropomorpha*, by the following characters:

In progression on the ground, the erect posture is the easiest, and no assistance is given by the arms, which are shorter than the legs. After birth, the proportions of the body alter in consequence of the legs growing faster than the rest of the body. In consequence, the middle point of the height of the body—which, at birth, is situated about the umbilicus—becomes gradually lower, until, in the adult male, it is as low as the *symphysis pubis*.

In the manus, the pollex is strong and long, reaching to the middle of the basal phalanx of the index digit. In the pes, the tarsus takes up half the length of the foot; the calcaneal process is long, and expanded posteriorly. The hallux has half the length of the foot, and is nearly as long as the second digit; and its mobility in adduction and abduction is slight, compared with that of the hallux of the other *Primates*.

Hair is more abundant upon the crown of the head; and, usually, in the axillæ, the pubic region, and the front part of the thorax, than elsewhere.

In the new-born infant the whole dorso-lumbar region of the spine is concave forwards, and the vertebro-sacral angulation is slight; but, in the adult, the spinal column is concave forwards in the thoracic, and convex forwards in the lumbar, region, mainly in consequence of the disposition of the elastic ligaments which connect the faces and the arches of the vertebræ. There is a strongly-marked vertebro-sacral angulation. Normally, there are twelve dorsal, five lumbar, five sacral, and four coccygeal vertebræ, and the transverse processes of the last lumbar vertebra are not expanded or directly connected with the ilia; but, in these respects, variations occur.

The spinous processes of the middle cervical vertebræ are much shorter than the seventh, and are usually bifurcated. The breadth of the sacrum is greater than its

length. In the skull, the occipital condyles lie within the middle fifth of the base, and the occipital foramen looks downwards, and either a little forwards or but slightly backwards. Neither sagittal nor lambdoidal crests are developed, but the mastoid processes are distinct, and generally conspicuous. The supraorbital ridges are never so largely developed as in some of the *Anthropomorpha*. The orbits and the jaws are relatively smaller, and situated less in front of, and more below, the fore-part of the brain-case. A *spina nasalis anterior* is almost always present,* and, in the profile view of the face, the nasal bones project more beyond the level of the ascending process of the maxilla than they do in any Ape. The palate is broader and its contour more arched than in any of the *Anthropomorpha*. Its posterior margin is ordinarily produced in the middle line into a *spina nasalis posterior*, and the palato-maxillary suture is directed transversely.

The distance between the zygomata is either less than the greatest transverse diameter of the calvaria, or exceeds it but little. The malar, is deeper than the squamosal, portion of the zygoma, and the upper edge of the zygoma is but little curved.

The post-glenoidal process of the squamosal is small, while the auditory foramen is vertically elongated, its anterior wall being more or less flattened.

The interorbital space occupies about one-fourth of the interval between the outer walls of the orbits.

The planes of the orbital surfaces of the ethmoid bones (*ossa plana*) are nearly parallel with one another.

The symphysis of the lower jaw has a mental prominence. The length of the cerebral cavity is more than twice that of the basi-cranial axis.

After birth, no trace of the premaxillo-maxillary suture remains upon the face, though it may persist in the palate.

* The only human skull in which I have been able to find no trace of the existence of the anterior nasal spine, is that of an Australian, which, some years ago, I presented to the Museum of the Royal College of Surgeons.

The nasal suture usually persists, and the direction of the fronto-nasal suture is nearly transverse.

The *cranio-facial angle** does not exceed 120° , and in the higher races of mankind does not go much beyond 90° .

The supra-orbital plates of the frontal bones project but little into the frontal region of the brain-case, and they are almost horizontal, instead of being strongly inclined upwards and outwards, as they are in the *Anthropomorpha*. The cribriform plate is long and wide, and the *crista galli* is usually prominent. The capacity of the brain-case of a healthy adult is invariably more than forty cubic inches, and may rise to more than a hundred cubic inches.

The scapula is broad in proportion to its length, and its spine cuts its vertebral edge nearly at right angles. The ilia are very broad; their inner faces present a well-marked concavity, and their crests an S-shaped curvature. A line drawn from the centre of the articular surface of the sacrum to the centre of the acetabulum makes nearly a right angle with the chord of the arc offered by the anterior face of the sacrum. In all the *Anthropomorpha* this angle is much more open.

The tuberosities of the ischia are hardly everted. The symphysis pubis is comparatively short, and the subpubic arch well marked. The width of the whole pelvis, from one iliac crest to the other, is greater than its height, which is the reverse of what obtains in the Apes. The transverse diameter of the brim is usually not exceeded by the antero-posterior diameter, though the contrary proportion occasionally obtains. The female pelvis is more spacious, and has a wider subpubic arch than the male.

The proximal articular surface of the astragalus looks almost directly upwards, and hardly at all inwards, when the sole is flat upon the ground; and the lateral facets are more nearly at right angles to this surface than in any Ape. The inner and outer malleoli are stronger and more downwardly produced. The calcaneal process is thick, strong, enlarged at its hinder end, and not incurved

* See p. 496 for the explanation of this term.

inferiorly, but produced into two tuberosities on which the heel rests. The form and disposition of the astragalar, navicular, and calcaneo-cuboid articulations are such that the distal moiety of the tarsus is capable of only a slight rotatory motion upon the proximal portion.

The distal articular surface of the ento-cuneiform bone is very nearly flat, though it has a slight convexity from side to side, and is irregularly concavo-convex, from above downwards. The comparatively slight mobility of the metatarsal bone of the hallux arises partly from this circumstance, partly from the fact that the proximal articular surfaces of the four outer metatarsal bones are not perpendicular to the axes of those bones, but are obliquely truncated, from the tibial side, backwards, to the fibular side. Hence the four outer metatarsal bones, instead of diverging widely from the hallux as they would do if their axes were perpendicular to the distal facets of the meso- and ento-cuneiform and cuboid bones, take a direction more nearly parallel with the metatarsal of the hallux, and the base of the second metatarsal, as it were, blocks the latter, in adduction. The hallux thus loses most of its prehensile functions; but, in exchange, it plays an important part in supporting the weight of the body, which, in the erect position, falls on three parts of the pes; namely, the heel, the outer edge, and the integumentary pad which stretches beneath the metatarso-phalangeal articulations, from the hallux to the fifth digit.

In the infant, the sole naturally turns inwards, and the digits (especially the hallux) retain much of their mobility.

The only muscles which exist in Man, but have not yet been found in any Ape, are the *extensor primi internodi pollicis* and the *peronæus tertius*.

The only peculiarities in the origin of muscles which ordinarily obtain in Man, and have not yet been found in the Apes, are—the complete separation of the *flexor pollicis longus* from the *flexor digitorum perforans*; the presence of a tibial, as well as of a fibular, origin of the *soleus*; the origin of all four heads of the *flexor brevis digitorum pedis*

from the calcaneum; the origin of the fibular *interosseus* of the second digit of the pes from the middle metatarsal, on the dorsal side of the tibial *interosseus* of the middle digit. The result of the last-mentioned arrangement is that the second digit of the pes has two "dorsal" interossei, like the third digit of the manus. In the Apes the *interossei* of the second digit are generally arranged in the same way in both manus and pes.

The tendons of the *flexor hallucis longus* and *flexor digitorum perforans* are usually more closely connected in the sole of the foot in Man, than in the *Anthropomorpha*. But it is to be noted that all the apparently distinctive peculiarities of the myology of the *Anthropomorpha* are to be met with, occasionally, as varieties in Man.

In the brain of Man, the only distinctive features, apart from its absolute size (55 to 115 cubic inches), are the filling-up of the occipito-temporal fissure; the greater complexity and less symmetry of the other sulci and gyri; the less excavation of the orbital face of the frontal lobe; and the larger size of the cerebral hemispheres, as compared with the cerebellum and the cerebral nerves.

There is no diastema, though the summits of the canines project, slightly, beyond the level of the other teeth. The premolars have not more than two roots, and the anterior edge of the crown of the anterior lower premolar is not prolonged and sharp. The permanent canine tooth emerges before the second molar.

The penis is devoid of a bone (though a prismatic cartilaginous body has occasionally been found in the centre of the glans), and its glans has a different shape from that of any of the *Anthropomorpha*. The vulva looks downwards and forwards, and the clitoris is comparatively small.

The changes in the proportions of the different parts of the body, at different periods of intra- and extra-uterine life, are very remarkable. In a foetus an inch and a half long, from the vertex to the heel, the head takes up from one-third to one-fourth of the entire length. The arms and legs are of about the same length, and are shorter than the

spine. The fore arm is about as long as the upper arm, and the leg as the thigh. The manus and pes are very similar in size and form; and neither pollex, nor hallux, are so different from the other digits as at later periods. In a fœtus rather more than five inches high, the head occupies a fourth of the entire height; the arms are longer than the spine by one-sixth of their whole length, and are a little longer than the legs. The fore arm is about as long as the upper arm, and the thigh is a little longer than the leg. The manus and pes are about equal in length. In a fœtus eight and a half inches high, the head measures less than a fourth of the whole height; the arms are longer than the spine by a fourth of their whole length, and they are longer than the legs. The extremities of the digits reach down to the knee when the body is erect.

At full term, the height of the head of the human fœtus is rather less than a fourth that of the whole body, and the legs are longer than the arms. The arm is longer than the fore arm, and the thigh than the leg. The hands and the feet are still about equal in length.

Thus it would appear that, while the head grows more slowly than the rest of the body, throughout the period of gestation, after the embryo has attained more than two inches in length; the arms grow proportionally quicker than the body and legs, in the middle of gestation, when the proportions most nearly resemble those of the *Anthropomorpha*. In the latter part of the period of gestation the legs gain on the arms, and the proximal segments of the limbs on the distal ones. After birth these changes are continued. The adult has, on the average, three and a half times the height of the new-born child, and his arms are elongated in the same proportion. But the head is only twice as large, while the legs of the adult are five times as long as those of the child. At all ages after birth, the distance between the extremities of the digits of the outstretched arms is equal to the height in average Europeans.

Sexual differences, independent of the genitalia, are perceptible at birth; and the female infant is, as a rule, slightly

smaller than the male. These differences become more marked at, and subsequent to, puberty; and are seen in the smaller stature of the female, the larger size of the head in proportion to the stature, the shorter thorax, the longer abdomen, and the shorter legs; so that the middle point of the stature of the female is nearer the umbilicus than in the male. The hips are wider in proportion to the shoulders, whence the femora are more oblique. The ridges and muscular processes of all the bones are less marked, and the frontal contour of the skull is more sharply angulated. When the peculiarities of the female sex are not connected with reproduction, they may be said to be infantile.

The different persistent modifications or "races" of mankind present a very considerable amount of variation in their anatomical characteristics. The colour of the skin varies from a very pale reddish brown—of the so-called "white" races—through all shades of yellow and red browns, to olive and chocolate, which may be so dark as to look black.

The hair differs much in its character, having sometimes a circular, sometimes an oval or flattened transverse section, and presenting all varieties, from extreme length and straightness to short, crisp wool.

The hair on the scalp is longer than that elsewhere; and it is very often, but not always, longer in the female. Hair upon the face and body is scanty in most races, and almost absent, except in the eyebrows, in some; but in others it becomes greatly developed over the lips, chin, and sides of the face, on the thorax, abdomen, and pubes, in the axillæ, and sometimes, though more rarely, upon the rest of the body and limbs. When hair is developed upon the limbs the points of the hairs of the arm and fore arm slope towards the elbow, and those of the leg and thigh away from the knee, as in the *Anthropomorpha*.

Enormous accumulations of fat take place upon the buttocks of the Bosjesmen, especially in the females; and the nymphæ of these and some other Negroid tribes become greatly elongated.

It appears that in some of the lower races, *e.g.*, Negroes

and Australians, the fore arm and hand, and the foot and leg, are often longer in proportion than in Europeans. From not wearing shoes, the hallux is much more moveable in these races, and the foot is commonly employed for prehension.

There is no proof of what is so commonly asserted, that the heel is longer, in proportion to the foot, in Negroes.

The spines of the middle cervical vertebræ sometimes cease, more or less completely, to be bifurcated in the lower races. Thirteen pair of ribs are sometimes present, and occasionally there is a sixth lumbar vertebra. There may be one more sacral vertebra than the normal number; and a modification of the last lumbar, so that it resembles a sacral vertebra, and becomes connected with the ilia, seems to be more common in Australians and Bushmen than in other stocks.

In the lower races, the male pelvis is less in many of its dimensions, and seems to differ more from the female, especially in the tendency to equality of the transverse and antero-posterior diameters of the brim, and the narrowness of the intersciatic diameter, than in the higher races. This is particularly obvious among the Australians. The antero-posterior diameter of the brim of the pelvis is occasionally greater than the transverse, and this variety would seem to be commoner among the Bushwomen of South Africa than elsewhere.

But it is in the skull that the different races of mankind present the most striking osteological differences. The proportions of the antero-posterior and the transverse dimensions of the brain-case vary extremely. Taking the antero-posterior diameter as 100, the transverse diameter varies from 98, or 99, to 62. The number which thus expresses the proportion of the transverse to the longitudinal diameter of the brain-case is called the *cephalic index*. Those people who possess crania with a cephalic index of 80 and above are called *brachycephali*; those with a lower index are *dolichocephali*. The brain-case also varies greatly in its relative height. The proportion of the length of the cerebral chamber to the basiscranial axis (as 100) may rise

to 270 in the higher, and sink to 230 in the lower races; and there are great diversities in the extent to which the cerebral cavity is rotated backwards or forwards upon this axis. The position and the aspect of the occipital foramen vary considerably, as does the plane of that part of the *squama occipitis* which lies above the superior semicircular ridge. The supra-ciliary ridges vary greatly in their development, and in the extension of the frontal sinuses into them. They are nearly, or quite solid in many Australian skulls.

In the size, form, and disposition of the facial bones the different races of mankind present great diversities. A line drawn from the anterior extremity of the premaxilla to the anterior extremity of the basicranial axis, may be taken to represent the *facial axis*, and the angle included between these two is the *craniofacial angle*. It varies with the extent to which the face lies in front of, or below, the anterior end of the cranium, from less than 90° to 120°. When it is great, the face is *prognathous*; when it is small, the face is *orthognathous*. This is the fundamental condition of *prognathism* or *orthognathism*. A secondary condition is the form of the alveolar portion of the upper jaw, which, so far as it is vertical, tends towards orthognathism; but, so far as it is oblique and produced, tends to prognathism.

The arch formed by the teeth is, in the most orthognathous races, wide and evenly rounded; while, in the most prognathous, it is prolonged, and its sides are nearly parallel. The teeth themselves are much larger, the roots of the premolars and molars more distinct, and the hindermost molar not so small relatively to the others, in some of the lower races, notably the Australians.

The mental prominence may project beyond the line of the vertical alveolar margin of the mandible, in the higher races, or it may be almost obsolete, and the alveolar margin may be greatly inclined forwards, in the lower.

The different races of mankind are divisible into two primary divisions; the *Ulotrichi*, with crisp or woolly hair, and the *Leiotrichi*, with smooth hair.

a. The colour of the *Ulotrichi* varies from yellow-brown to the darkest hue known among men. The hair and eyes are normally dark, and, with only a few exceptions (among the Andaman Islanders), they are *dolichocephali*. The Negroes and Bushmen of ultra-Saharal Africa, and the Negritos of the Malay peninsula and archipelago, and of the Papuan islands, are the members of this *Negroid* stock.

b. The *Leiotrichi* are divisible into—

1. The *Australioid* group, with dark skin, hair, and eyes, wavy, black hair, and eminently long, prognathous, skulls, with well-developed brow ridges, who are found in Australia and in the Dekhan. The ancient Egyptians appear to me to have been a modification of this race.

2. The *Mongoloid* group, with, for the most part, yellowish brown, or reddish brown, skins and dark eyes, the hair being long, black, and straight. Their skulls range between the extremes of dolichocephaly and those of brachycephaly. These are the Mongol, Tibetan, Chinese, Polynesian, Esquimaux and American races.

3. The *Xanthochroic* group, with pale skins, blue eyes, and abundant fair hair. Their skulls, like those of the Mongoloid group, range between the extremes of dolichocephaly and brachycephaly. The Slavonians, Teutons, Scandinavians, and the fair Celtic-speaking people are the chief representatives of this division; but they extend into North Africa and Western Asia.

4. The dark whites, or *Melanochroi*; pale-complexioned people, with dark hair and eyes, and generally long, but sometimes broad, skulls. These are the Iberians and "black Celts" of Western Europe, and the dark-complexioned white people of the shores of the Mediterranean, Western Asia, and Persia. I am disposed to think that the *Melanochroi* are not a distinct group, but result from the mixture of Australioids and *Xanthochroi*.

Fossil remains of Men or implements of human manufacture have hitherto been found only in late Tertiary (Quaternary) deposits, and in caves, mingled with the remains of animals which lived during the glacial epoch.

INDEX.

A.

ACCIPENSER, cartilaginous cranium of, 141.
 Air sacs in birds, 317.
 Alimentary canal, 86.
 Alligator terrapene, 198.
 Amia, caudal extremity of, 17.
 — calva, reproductive organs of, 144.
 Amphibia, general characteristics, 172.
 — development, 190.
 — groups, 172.
 — heart, 183.
 — limbs, 180.
 — muscles, 47.
 — reproductive organs, 189.
 — respiratory organs, 187.
 — teeth, 182.
 Amphisbœnoida, 230.
 Ankle-joint of sloths, 331.
 Anoplotheridæ, 376.
 Antebrachium, muscles of, 51.
 Anthropidæ. *See* Man.
 Anthropomorpha, general characteristics of, 475.
 — comparison of, with man, 487.
 — divisions, 475.
 Aortic arches. *See* Arches, aortic.
 Apes. *See* Simiadæ.
 Arch, pectoral, 34.
 — pelvic, 37.
 — pectoral and pelvic, of che-
 lonia, 206.
 — pectoral and pelvic, of ple-
 siosauria, 213, 214.
 Arches, aortic, 91, 92.
 — number of, belonging to
 skull, 77.
 — pectoral, and sternum, of a
 frog, 181.

Arches, visceral, skeletons of, 85.
 Arctopithecini (marmosets), gene-
 ral characteristics of, 462.
 — brain, 464.
 — limbs, 463.
 — muscles, 464.
 — skull, 463.
 — teeth, 463.
 — vertebræ, 463.
 Armadillos, general characteristics
 of, 339.
 Artiodactyla, non-ruminantia,
 367.
 — ruminantia, 377.
 Ascalabota, 225.
 Australians, peculiarities of, 495.
 Aves. *See* Birds.
 Axolotl (*Siredon*), 186.
 — aortic arch of, 92.

B.

BALÆNOIDEA, general character-
 istics of, 395.
 Baleen plates, or whalebone, 398.
 Bats. *See* Cheiroptera.
 Birds, general characteristics of,
 194.
 — air sacs of, 317.
 — brain of *Meleagris gallo-*
pavo, 303.
 — classification, 272.
 — digits, 292, 297.
 — ear, 306.
 — heart, 312.
 — larynx and syrinx, 313.
 — limbs, 291, 295.
 — lungs, 316.
 — muscular system, 300.
 — organs of copulation, 318.
 — pectoral arch, 289.

- Birds, pelvis, 293.
 — sacrum of a chick, 278.
 — skull, 282.
 — spur, 297.
 — sternum, 280, 281.
 — vertebræ, 275.
See also Fowl.
 Bears, teeth of, 422.
 Blood, circulation of, in frog, 185.
 — corpuscles, 99.
 Bloodsucking bats, 456.
 Bones of cetacea, 394.
 — cynomorpha, 470.
 — delphinoidea, 399.
 — elephant, 430.
 — the face, 25.
 — fishes, 28, 85.
 — galeopithecus, 450.
 — hedgehog, 443.
 — pig, 369.
 — rhinoceros, 361.
 — the skull, 22, 23.
See also Os, Ossa.
 Bosjesmen, fat of, 494.
 Brain of anthropomorpha, 484.
 — carnivora, 413.
 — chimpanzee, 64-69.
 — cynomorpha, 474.
 — divisions of, 59.
 — dog, 420.
 — frog, 188.
 — hedgehog, 447.
 — horizontal section, 60.
 — lemuridæ, 459.
 — longitudinal and vertical section, 61.
 — man, 492.
 — marmoset, 464.
 — modifications of, 63.
 — pig, 64-69.
 — pike, 164.
 — platyrrhini, 468.
 — porpoises, 410.
 — rabbit, 64-69, 440.
 Brain-case. *See Skull.*
 Bruta, or Edentata. *See Edentata.*

C.

- CACHALOT, skull of, 401.
 Cainozoic formation, crocodiles in, 258.
 Camelidæ or tylopoda, 385.
 Canal, alimentary, 86.
 — spinal, and cord, 69.
 Canals of Stenson, 79.
 Carnivora, general characteristics of, 412.
 — classification, 421.
 — divisions, 413.
 Carpus, skeletal elements of, 31.
 Catarrhine monkey, skeleton of 462.
 Catarrhini, characteristics of, 469.
 Cats, teeth of, 422.
 Caudal extremities of polypterus, amia, and salmo, 17.
 — vertebræ, 16.
 Cerebral nerves, 71.
 Cetacea, general characteristics, 392.
 — groups, 395.
 Characters, distinctive, of vertebrata, 1.
 Chalk, ichthyosauria in, 249.
 — lizards found in, 228, 229.
 Chamælonida, 231.
 Cheiroptera, general characteristics of, 454.
 — digits, 34.
 — position of limbs of bats, 33.
 Chelone midas, carapace of, 200.
 — section of skeleton of, 199.
 Chelonia, general characteristics, 197.
 — divisions, 207.
 — heart, 308.
 — lungs, 316.
 — muscular system, 300.
 — organs of copulation, 318.
 — pectoral and pelvic arches, 206.
 — plastron, 201.
 — skull, 203-205.
 Chelydra, forefoot of, 32.
 Chimæra monstrosa, section of skull, 127, 128.
 Chimpanzee, 476.
 — brain of, 64-69.
 Circulatory organs, 90.
 Cochlea, development of, 82-84.
 Comparison of man with anthropomorpha, 487.
 Corpuscles, blood, 99.
 — lymph, 101.
 Corpus callosum in mammalia, 63.

- Cotylophora, 383.
 Cranial nerves, 75.
 — system, 18.
 Cranio-facial angle, 490, 496.
 Crocodile, segment of endoskeleton
 in thoracic region of, 15.
 Crocodilia, 249.
 — dermal armour, 250.
 — ear, 306.
 — groups, 258.
 — heart, 311.
 — lungs, 316.
 — pelvis and hind limb, 260.
 — reproductive organs, 318.
 — skull, 254.
 — teeth, 258.
 — vertebræ, 250.
 Crus, muscles of, 51.
 Cutaneous muscle of hedgehog,
 444.
 — porpoise, 406.

D.

- DEER, horns of, 384.
 Delphinoidea, characteristics of,
 399.
 Dental formulæ. *See* Teeth.
 Dentition. *See* Teeth.
 Development of amphibia, 189.
 — cochlea, 82-84.
 — egg, 3.
 — fowl, stages of, 6, 8, 12, 20.
 — lamb, 27.
 — skull of fishes, 21.
 — vascular system, 93-96.
 — vertebrata, 3.

DIAGRAMS :—

- Accipenser, skull, 141.
 Alligator terrapine, 198.
 Amia, caudal extremity, 17.
 Amia calva, reproductive
 organs, 144.
 Amphioxus lanceolatus, 117,
 118.
 Aortic arches, 91.
 Axolotl, 186.
 Bird and lizard, brain, 302,
 303.
 Cachalot, skull, 401.
 Catarrhine monkey, 462.
 Chelone, skeleton, shell, 199,
 200.

DIAGRAMS—*continued.*

- Chelydra, foot, 32.
 Chimæra, skull, 128.
 Chimpanzee, brain, 65, 67.
 Crocodile, anterior thoracic
 region, 15.
 — pelvis and hind limb, 260.
 — skull, 254.
 Cyclodus (*lacertilia*), skull,
 219, 221.
 Dromæus, pelvis and hind
 limb, 260.
 Dugong, heart, 390.
 Elephant, skeleton, 429.
 Fish, visceral arch, 85.
 Fœtus, human, principal
 vessels, 94.
 Fowl, development, 6, 8, 12, 20.
 — fore limb, 292.
 — leg, 295, 296.
 — pelvis, 293.
 — sacrum of chick, 278.
 — scapula and coracoid,
 289.
 — skull, 283.
 — spur, 297.
 — sternum, 281.
 Flying fox, skeleton, 453.
 Frog, nervous system, 70.
 — skull and brain, 176, 188.
 — sternum and pectoral
 arch, 181.
 Holoptychus, 145.
 Homo, pregnant uterus, 4.
 Horse, carpus, 350.
 — cervical vertebræ, 346.
 — femur, 352.
 — foot, 345, 349.
 — ossa innominata, 351.
 — skeleton, 347.
 — tarsus, 343.
 Ichthyosaurus, 243, 244.
 Iguanodon, pelvis and hind
 limb, 260.
 Lamb, fœtal, head, 27.
 Lamprey, skull and brain, 122,
 124, 125.
 Lepidosteus, 138.
 Lion, skeleton, 414.
 Lizards, pectoral arch and
 sternum, 35, 36.
 — visceral arch, 85.
 Mammal, visceral arch, 85.

DIAGRAMS—*continued.*

- Monkfish (*squatina*), pectoral member, 39.
 — skull, 130.
 Mudfish, skull, 168, 169.
 Orang, digit, 53.
 Os innominatum of man, 37.
 Ostrich, skull, 284.
 Ox, skeleton, 377.
 Pig, brain, 65, 67.
 Pike, brain, 164.
 — outline, 42.
 — pectoral arch and fore limb, 158.
 — skull, 151, 152, 154, 155.
 Plaice, skull, 29.
 Plesiosaurus, skeleton, 210.
 Polypterus, caudal extremity, 17.
 Protractylus, skeleton, 267.
 Python, dorsal vertebræ, 234.
 — skull, 236, 239.
 Rabbit, brain, 65, 67.
 Rattlesnake, skull, 240.
 Reproductive organs in higher vertebrata, 108.
 Salamander, foot, 32.
 Salmo, caudal extremity, 17.
 Secretary bird, skull, 287.
 Shark, aortic bulb, 132.
 Sheep, stomach, 379.
 Skate, brain, 134.
 Spatularia, skull, 140.
 Sturgeon, skull, 141.
 Tadpoles, 191.
 Torpedo, 58.
 Trematosaurus, skull, 179.
 Turtle, heart, 310.
 — plastron, 202.
 — skull, 203, 204, 205.
 Vertebrate brain, sections, 60, 61.
 Whale, skull, 396, 397.
 Dicynodontia, 259.
 Didelphia, characteristics of, 323.
 — peculiarities of, 324.
 — stomach of, 327.
 Digits of anthropomorpha, 479, 481.
 — bat, 34, 454, 456.
 — birds, 297.
 — cynomorpha, 473.
 — dog, 416.
 Digits of lacertilia, 223.
 — lemuridæ, 458.
 — man, 31, 488.
 — marsupialia, 326.
 — muscles of, 52.
 — rabbit, 437.
 — seal and turtle, 34, 426.
 Dinotherium, 431.
 Dipnoi, 167.
 Dog, anatomy of, 415.
 — digits, 416.
 Dolichosauria, 228.
 Dromæus, pelvis and hind limb, 260.
 Dugong, heart of, 390.

 E.

 EAR, 81.
 — bones of whale, 397.
 — in sauropsida, 306.
 See Hearing, organs of.
 Edentata entomophaga, groups and characteristics of, 335.
 — extinct, 335.
 — loricata 338.
 — mutica, 335.
 — phytophaga, characteristics of, 330.
 — squamata, 337.
 — teeth of, 330, 335.
 — tubulidentata, 337.
 Egg, development of, 3.
 Elasmobranchii, 126.
 Electrical organs, 57, 58.
 Elephant, skeleton of, 429.
 See Proboscidea.
 Embryo of vertebrata, development of, 5.
 Encephalon, 59.
 Endoskeleton, segment of, in thoracic region of a crocodile, 15.
 — of vertebrata, 10.
 Entomophaga, 335.
 Eocene strata, didelphidæ in, 328.
 — extinct mammals of, 376.
 — fossils of equidæ in, 358, 359.
 — fossil rodents of, 442.
 Episkeletal muscles, 45.
 Equidæ, fossil, 358.

Equidæ (horses and asses), general characteristics of, 343.

See Horse.

Exoskeleton, 40.

— in birds, fishes, reptiles, and mammals, 41, 42, 43, 44, 194, 274.

— of reptilia, 193.

Eye muscles of sauropsida, 304.

— structure of, 79.

F.

FACE, bones of, 25.

— of man, 489, 496.

Facial muscles, 73.

Feathers, 274.

Femur of the horse, 352.

Fins of fishes, 39, 40.

Fishes, electrical organs of, 57.

— groups in class, 115.

— limbs, 38.

— muscular system, 46.

— raylike bones, 28.

— skeleton of visceral arches of osseous fish, 85.

— skull, 21, 30.

Fissipedia, general characteristics of, 413.

Flatfishes (*pleuronectidæ*), 30.

Flying fox, skeleton of, 453.

Fœtal appendages of vertebrata, 7.

Fœtus, human, arrangement of principal vessels in, 94.

Foot of anthropomorpha, 480, 484.

— horse, 345, 349.

— man, 490.

Fossils in chalk, 228, 229, 249.

— eocene strata, 328, 358, 359, 376, 442.

— lias, 208, 249.

— human, 497.

— mesozoic formation, 215, 217, 226, 258, 265, 266, 328.

— miocene formation, 358, 359, 363, 365, 375, 376, 385, 386.

— permian formation, 226.

— post-triassic formation, 215.

— triassic formation, 226, 249, 258, 261, 328.

Fowl, stages of development of, 6, 12, 18, 20.

— pelvis, 293.

Fowl, scapula and coracoid, 289.

— skull, 283.

— sternum, 281.

— tibia and fibula, 295, 296.

Frog, aortic arch of, 92.

— brain, 188.

— cerebro-spinal and sympathetic nervous system, 70.

— circulation of blood, 185.

— larva, 191.

— skull, 175, 176.

— sternum and pectoral arches, 181.

G.

GALEOPITHECUS, general characteristics of, 450.

Ganoidei, existing and fossil, 145.

— genera of, 137.

Gibbons, 475.

Glyptodon, peculiar character of, 340.

Gorilla, 477.

Growth in man, laws of, 493.

H.

HAGS (*marsipobranchii*), optic nerves of, 71.

Hand of anthropomorpha, 476, 483.

Head and trunk, muscular system of, 45.

— of sperm whale, 400.

Hearing, organs of, cases, 24.

— in cetacea, 410.

Heart of amphibia, 183.

— bat, 455.

— birds, 312.

— crocodiles, 311.

— modifications of, 97.

— porpoise, 407.

— sauropsida, 308.

— teleostei, 161.

— turtle, 309, 310.

Hedgehog, 442.

Hippopotamidæ, general characteristics of, 374.

Homœosauria, 226.

Horns of deer, &c., 384.

Horse, general characteristics of, 343.

- Horse, cervical vertebra, 346.
 — femur, 352.
 — forefoot and hindfoot, 345, 349.
 — limbs, 348.
 — muscles, 353.
 — ossa innominata, 351.
 — skeleton, 347.
 — skull, 348.
 — teeth, 344, 354.
 — viscera, 356.
 Hyposkeletal muscles, 45.
 Hyracoidea, characteristics of, 432.

I.

- ICHTHYOPSIDA, characteristics of, 112.
 Ichthyosauria, 242.
 — pectoral arch, 247.
 — pelvis, 249.
 — skeleton, 244.
 — skull, 245.
 — vertebræ, 243.
 Impregnation of vertebrata, 3.
 Insectivora, characteristics of, 442.

J.

- JACOBSON, organs of, 79.

K.

- KIONOCRANIA, 228.

L.

- LACERTILIA, 216.
 — groups, 224.
 — organs of copulation, 318.
 — skull, 219.
 Lamb, development of, 27.
 Lamprey, optic nerves of, 71, 73.
 — sections of skull, 122, 125.
 — skull, 21.
 — teeth, 87.
 Larva of frog, 191.
 Larynx, 103.
 — platyrrhini, 467.
 — sauropsida, 313.
 Leiotrichi, 497.

- Lemuridæ, general characteristics of, 458.
 — brain, 459.
 — limbs, 458.
 — organs of reproduction, 460.
 — skull, 459.
 — teeth, 460, 461.
 Lepidosiren, aortic arch of, 92.
 Lepidosteus semiradiatus, brain of, 138.
 Lias, chelonia in, 208.
 — ichthyosauria in, 249.
 Limbs of amphibia, 180.
 — birds, 291.
 — carnivora, 412.
 — fishes, 38.
 — galeopithecus, 450.
 — hedgehog, 446.
 — horse, 348.
 — hyrax, 433.
 — lemuridæ, 458.
 — man, 488.
 — marmoset, 463.
 — muscular system of, 48.
 — pig, 369.
 — porpoise, 405.
 — position of, 32.
 — seal, 425.
 — vertebrated animals, 30.
 Lion, skeleton of, 414.
 Liver, 87.
 — in sauropsida, 308.
 Lizard, brain of, 302, 303.
 — pectoral arch and sternum, 35, 36.
 — skeleton of visceral arches, 85.
 Lymphatic system, 100.
 Lymph corpuscles, 101.

M.

- MACRAUCHENIDÆ, 366.
 Mammalia, general characteristics of, 114.
 — classification, 319.
 — deciduate, 411.
 — dental formulæ, 89.
 — development of heart, 99.
 — skeleton of visceral arches of mammal, 85.
 — teeth, 355.

Man, arrangement of principal vessels in human foetus, 94.
 — general characteristics of, 488.
 — comparison of anthropomorpha with, 487.
 — digits of, 31.
 — divisions of :—
 Leiotrichi, 497.
 Ulotrichi, 497.
 — fossil, 497.
 — laws of growth in, 493.
 — muscles of digits, 52, 53, 54, 55, 56.
 — muscles of limbs, 48.
 — os innominatum, 37.
 — position of limbs, 33.
 — 'races' of, 494.
 — section of pregnant uterus of a deciduate placental mammal, 4.
 — sexual differences, 493.
 — teeth, 89.
 Marmosets. *See* Arctopithecini.
 Marsipobranhii, 121.
 Marsupialia, digits of, 326.
 Mastodon, 431.
 Mesozoic formation, crocodiles in, 258.
 — didelphidæ, &c., in, 328.
 — lizards in, 226.
 — ornithoscelida in, 265.
 — plesiosauria confined to, 215.
 — pterosauria in, 266.
 Miocene epoch, cotylophora of, 385.
 — extinct mammals, 376.
 — fossil camelidæ, 386.
 — fossil equidæ, 358, 359.
 — fossil hippopotamidæ, 375.
 — fossil rhinoceros, 363.
 — fossil tapirs, 365.
 — genus of sirenias, 391.
 Modifications of the brain, 63.
 — of the heart, 97.
 — of reproductive organs, 109.
 Moles (*talpinæ*), 452.
 Monkeys. *See* Simiadæ.
 Monkfish (*squatina*), pectoral member of, 39.
 — sections of skull, 130.
 Monodelphia, characteristics of, 328.
 Mosasauria, 228.
 Mudfish, 168.

Muscles of amphibia, 47.
 — antebrachium, 51.
 — anthropomorpha, 482.
 — crus, 51.
 — cynomorpha, 472.
 — the digits, 52.
 — dog, 417.
 — eye in sauropsida, 304.
 — fishes, 46.
 — hedgehog, 444-446.
 — horse, 353.
 — the limbs, 48.
 — man, 491.
 — marmoset, 464.
 — ophidia, 299.
 — pig, 369.
 — platyrrhini, 467.
 — rabbit, 439.
 — seal, 426.
 — system of, in ophidia, che-
 lonia, and aves, 299.
 — trunk and head, 45.
 Musk deer, stomach of, 379.
 Myelon, 69.
 Myxine, 123.

N.

NEGROES, peculiarities of, 495.
 Nerves, cerebral, 71.
 — of the eye, 79-81.
 — sauropsida, 301.
 — spinal, 69.
 — sympathetic, 77.
 Nervous system of frog, 70.
 Non-ruminating animals, 367.

O.

OLFACTORY apparatus, 78.
 — nerves, 71.
 Ophidia, groups of, 233.
 — fossil, 242.
 — muscular system, 299.
 — organs of copulation, 318.
 — skull, 235.
 — teeth, 242.
 — vertebræ, 233.
 Optic nerves, 71, 80, 81.
 Orangs, 476.
 — middle digit of, 53.

- Organs, circulatory, 90.
 — of hearing, 81.
 — renal, 105.
 — reproductive. *See* Reproductive organs.
 — respiratory, 101. *See also* Respiration.
 — of sight, 79.
 — of taste, 86.
 — of touch, 86.
 — of voice, 103.
 Ornithodelphia, characteristics of, 320.
 Ornithoscelida, 261.
 — transitional character of skeleton of, 261.
 Os innominatum of man, 37.
 Ossa innominata of the horse, 351.
 Ossification of facial apparatus, 25.
 — skull, 21.
 — vertebræ, 13.
 Ostrich, reproductive organs of, 318.
 — skull, 284.
 Otariidæ (eared-seals), 423.
 Ox, skeleton of, 377.

P.

- PALÆOTHERIDÆ, 365.
 Palate of cetacea, 395.
 Pectoral arch, 34.
 — in birds, 289.
 — chelonia, 206.
 — crocodiles, 256.
 — and fore limb of pike, 158.
 — of plesiosauria, 213.
 Pectoral fins, 40.
 — member of monkfish (*squatina*), 39.
 Pelvic arch, 37.
 — of chelonia, 206.
 — of plesiosauria, 214.
 Pelvis of anthropomorpha, 480.
 — bat, 455.
 — birds, 293.
 — cetacea, 394.
 — crocodiles, 257.
 — cynomorpha, 471.
 — hedgehog, 444.
 — man, 490; lower races of man, 495.

- Pelvis of platyrrhini, 466.
 — porpoise, 405.
 — pterosauria, 269.
 — sirenia, 389.
 Permian formation, lizards of, 226.
 Perissodactyla, 342.
 Pharyngobranchii, 116.
 Phocidæ, general characteristics of, 424.
 Phocodontia, 411.
 Phytophaga, 330.
 Pig, anatomy of, 367.
 — brain, 64-69.
 — digital muscles, 56.
 Pike, brain of, 164.
 — fins, 42.
 — pectoral arch and fore limb, 158.
 — skull, 151, 152, 154, 155.
 Pinnipedia, characteristics of, 423.
 — groups, 423.
 Pisces. *See* Fishes.
 "Placoid exoskeleton," 126.
 Plaice, skull of, 29.
 Plastron of the chelonia, 201.
 Platyrrhini, general characteristics of, 465.
 Plesiosauria, 208, 215.
 — pelvic arch of, 214.
 — skeleton, 210.
 — extinct, confined to Mesozoic rocks, 215.
 Pleuronectidæ (flat fishes), 30.
 Polypterus, caudal extremity of, 17.
 Porpoise, general characteristics of, 402.
 — heart, 407.
 — muscles, 406.
 — pelvis, 405.
 — respiratory apparatus, 408.
 — skull, 403.
 — stomach, 407.
 — teeth, 407.
 — vertebræ, 403.
 Post-Triassic group of plesiosauria, 215.
 Poupert's ligament, 38.
 Primates, characteristics of, 457.
 — divisions of, 458.
 Proboscidea, general characteristics of, 428.
 — bones, 430.
 — fossil, 432.

- Proboscidea, reproductive organs, 431.
 — skull, 428.
 — stomach, 431.
 — teeth, 430.
 — vertebræ, 428.
 Protosauria, 226.
 Protovertebræ, 11.
 Psalterium of ruminants, 379.
 Pterodactylus, skeleton of, 267.
 Pterosauria, 266.
 — groups of, 270.
 — skull, 268.
 — vertebræ, 267.
 Python, dorsal vertebra of, 234.
 — skull, 236, 239.

R.

- RABBIT, anatomy of, 437.
 — brain, 64-69, 440.
 — digital muscles, 56.
 — limbs, 439, 440.
 — muscles, 439.
 — reproductive organs, 441.
 — skull, 438.
 — teeth, 441.
 — vertebræ, 437.
 — viscera, 441.
 Races of man, 494.
 Rana esculenta, cerebro-spinal and sympathetic nervous system of, 70.
 Rattlesnake, skull of, 240.
 Rays, pectoral arch of, 34.
 — skull, 21.
 Renal organs, 105.
 Reproductive organs, 106.
 — of amia calva, 144.
 — amphibia, 189.
 — anthropomorpha, 487.
 — bat, 455.
 — birds, 318.
 — dog, 421.
 — hedgehog, 449.
 — lemuridæ, 460.
 — man, 490, 492.
 — modifications of, 109.
 — ostrich, 318.
 — porpoise, 410.
 — sauropsida, 318.
 Reptilia, characteristics of, 193.
 — groups, 195.

- Respiration, mechanism of, 104.
 — organs of, 101.
 — in amphibia, 187.
 — porpoises, 408.
 — sauropsida, 315.
 — teleostei, 162.
 Rhinoceros, general characteristics of, 360.
 — bones, 361.
 — fossil, 363.
 — reproductive organs, 362.
 — skin, 360.
 — skull, 360.
 — teeth, 360, 362.
 — vertebræ, 360.
 — viscera, 362.
 Rhynchocephala, 225.
 Rodentia, general characteristics of, 434.
 — brain, 435.
 — digits, 436.
 — reproductive organs, 436.
 — teeth, 434, 435.
 — vertebræ, 435.
 Ruminating animals, 377.
 — act of feeding, 380.
 — act of rumination, 381.
 — groups of, 382.

S.

- SALAMANDRA, hindfoot of, 32.
 Salmo, caudal extremity of, 17.
 Sacrum of birds, 278.
 Sauropsida, general characteristics of, 113.
 — alimentary canal of, 307.
 — brain, 302, 303.
 — ear, 306.
 — eye muscles, 304.
 — heart, three forms of, 308.
 — larynx, 313.
 — liver, 308.
 — muscles and viscera, 299.
 — nerves, 301.
 — reproductive organs, 318.
 — respiratory organs, 315.
 — stomach, 308.
 — tongue of, 307.
 Seals. *See* Otariidæ, Phocidæ, Pinnipedia.
 Secretary bird, skull of, 287.

- Sensory organs, 78.
Sexual differences in man, 493.
Sharks, aortic arch of, 92.
— aortic bulb, 132.
— pectoral arch, 34.
Sharks, skull, 21.
Sheep, stomach of, 379.
Shrews (*sorices*), 452.
Simiadae, general characteristics of, 461.
— divisions of, 462.
— skull, 461.
— teeth, 461.
Sirenia, characteristics of, 387.
Skate, brain of, 134.
Skeleton, amphibian, 174, 175.
— of anthropomorpha, 477.
— catarrhine monkey, 462.
— chelone midas, section of, 199.
— elephant, 429.
— flying fox, 453.
— fossil equidae, 358, 359.
— horse, 347.
— ichthyosauria, 244.
— limbs, 31.
— lion, 414.
— ornithoscelida, transitional character of, 261.
— ox, 377.
— plesiosaurus, 210.
— porpoise, 403.
— pterodactylus, 267.
— the skull, 19.
— visceral arches of lizard, mammal, and fish, 85.
See also Endoskeleton, Exo-skeleton.
Skull of accipenser, 141.
— amphibian, 177.
— of anthropomorpha, 478.
— arches belonging to, 77.
— of bat, 455.
— birds, 282.
— carnivora, 412.
— common fowl, 283.
— cetacea, 392.
— chelonia, 203-205.
— cranial system, 18.
— crocodile, 254.
— cynomorpha, 469.
— dog, 415.
— elephant, 428.
Skull of fishes, 30.
— foetal cachalot, 401.
— frog, 175, 176.
— hedgehog, 443.
— horse, 348.
— lacertilia, 219, 221.
— lemuridae, 458.
— man, 489; differences in, 495.
— marmoset, 463.
— modifications of, 21.
— mudfish, 168, 169.
— nerves of, 71-77.
— ophidia, 235.
— ornithoscelida, 265.
— ostrich, 284.
— osseous brain-case, 21-23.
— pig, 368.
— pike, 151, 152, 154, 155.
— plaice, 29.
— platyrrhini, 466.
— plesiosauria, 212.
— porpoise, 403.
— pterosauria, 268.
— rabbit, 438.
— rattlesnake (*crotalus*), 240.
— rhinoceros, 360.
— seal, 425.
— secretary bird, 287.
— sirenia, 388.
— spatularia, 140.
— sturgeon, 141.
— trematosaurus, 179.
— typical segment of, 23.
— walrus, 424.
— whale, 396, 397.
Slots, characteristics of, 331.
— ankle-joint, 331.
— limbs, 331.
— pelvis, 331.
— tongue, 335.
— vertebrae, 331.
Snakes. *See* Ophidia.
Sorices (shrews), 452.
Spatularia, skull of, 140.
Spinal canal and cord, 69.
— system, 11.
Spleen, 101.
Spotting, mechanism of, in cetacea, 409.
Spur of birds, 297.
Squatina (monkfish), pectoral member of, 39.
— sections of skull, 130.

- Stenson, canals of, 79.
 Sternum in birds, 280, 281.
 — of frog, 181.
 — of lizard, 35, 36.
 Stomach, 87.
 — of camels, &c., 385.
 — carnivora, 413.
 — musk deer, 379.
 — porpoise, 407.
 — ruminating animals, 378, 379.
 — sauropsida, 308.
 — sheep, 379.
 — teleostei, 160.
 Sturgeon, skull of, 21, 141.
 Suidæ, 367.
 — variations in, 373.
 Sympathetic nerves, 77.
 Syrinx, 103.
 — of birds, 313.

T.

- TADPOLES, 191, 192.
 Tapirs, characteristics of, 363.
 Tarsus, skeletal elements of, 31.
 Taste, organ of, 86.
 Teeth, 87.
 — of amphibia, 182.
 — anthropomorpha, 485.
 — bat, 455, 456.
 — carnivora, 412.
 — cats, 422.
 — cetacea, 394.
 — crocodiles, 258.
 — cynomorpha, 473.
 — delphinoidea, 399.
 — didelphia, 325.
 — dog, 418, 422.
 — edentata, 330, 335.
 — edentata tubulidentata, 337.
 — elephant, 430.
 — extinct mammals, 376.
 — fishes, 129, 159.
 — galeopithecus, 451.
 — hedgehog, 446.
 — hippopotamus, 374.
 — horse, 344, 354.
 — hyrax, 433.
 — lacertilia, 224.
 — lemuridæ, 460.
 — macrauchenidæ, 366.
 — man, 492, 496.
 — marmoset, 463.

- Teeth of ophidia, 242.
 — ornithoscelida, 265.
 — palæotheridæ, 366.
 — pig, 371.
 — platyrrhini, 467.
 — porpoise, 407.
 — rabbit, 441.
 — rhinoceros, 360.
 — rodentia, 434.
 — seal, 427.
 — sirenia, 389.
 — suidæ, 367, 373.
 — tapirs, 363.
 — toxodontia, 386.
 — walrus, 424.
 — whale, or whalebone, 398.
 Teleostei, 148.
 — aortic arch of, 92.
 Tertiary epoch, extinct cetaceans of, 411.
 — late, fossil man in, 497.
 Thymus, 101.
 Tongue of amphibia, 183.
 — sauropsida, 307.
 — sloths, 336.
 Torpedo, electrical apparatus of, 58.
 Tortoises, 197.
 Touch, organs of, 86.
 Toxodontia, extinct, characteristics of, 386.
 Tragulidæ, 382.
 Transition of skeleton of ornithoscelida, 261.
 Trematosaurus, skull of, 179.
 Triassic formation, crocodiles of, 258.
 — extinct lizards, 226.
 — dicynodontia, 261.
 — ichthyosauria, 249.
 — macropodidæ, &c., 328.
 Triassic groups of plesiosauria, 215.
 Trichechidæ (walruses), 424.
 Trigeminal nerves, 74, 76.
 Trunk and head, muscular system of, 45.
 Turkey, brain of, 302.
 Turtles, 197.
 — heart, 309, 310.
 — plastron, 202.
 — skull, 203-205.
 Tylopoda or camelidæ, 385.

U.

- ULOTRICH, 497.
 Ungulata, characteristics of, 341.

V.

- VAMPIRE bat, 457.
 Vascular system, 93-96.
 Veins, 93.
 Ventral fins, 40.
 Vertebrae of anthropomorpha, 477.
 — bat, 454.
 — birds, 275.
 — caudal, 16.
 — of carnivora, 412.
 — cetacea, 392.
 — crocodiles, 250.
 — cynomorpha, 469.
 — dog, 415.
 — hedgehog, 443.
 — horse, 346.
 — hyrax, 432.
 — ichthyosauria, 243.
 — lacertilia, 217.
 — lemuridæ, 459.
 — man, 488 ; lower races of, 495.
 — marmoset, 463.
 — ornithoscelida, 265.
 — ossification of, 13.
 — of pig, 367.
 — platyrrhine, 465.
 — porpoise, 403.
 — proboscidea, 428.
 — pterosauria, 267.
 — rabbit, 437.
 — rhinoceros, 360.
 — rodentia, 435.
 — seal, 425.
 — sirenia, 388.

- Vertebrae of snakes, 233.
 — tapirs, 363.
 — whales, 395.
 Vertebrata, distinctive characters of, 1.
 — development, 3.
 — foetal appendages, 7.
 — impregnation, 3.
 — limbs, 30.
 — provinces or groups, 112.
 Vertebrate endoskeleton, 10.
 — exoskeleton, 40.
 Vesicles of the brain, 59.
 Viscera of anthropomorpha, 486.
 — camelidæ, 386.
 — cynomorpha, 473.
 — elephant, 431.
 — hedgehog, 448.
 — horse, 356.
 — hyrax, 434.
 — lemuridæ, 459.
 — pig, 372.
 — platyrrhini, 467, 468.
 — rabbit, 441.
 — rodentia, 436.
 — seal, 427.
 — tapirs, 365.
 Visceral arches and clefts, 9.
 — arches, skeletons of, 85.
 Voice of birds, 313.
 — organs of, 103.

W.

- WHALEBONE, 398.
 Whale, ear-bones of, 397.
 — skull of, 397.
 — skull of foetal, 396.
 — sperm, head of, 400.


By the same Author,


INTRODUCTION TO THE CLASSIFICATION
OF ANIMALS.

With Engravings. 8vo. 6s.

AD1710







BOUND BY
EDMONDS & REMNANTS
LONDON

