

fQ
115
N86X
Bd. 4
v. 3
NH





DEN NORSKE NORDHAVS-EXPEDITION

1876—1878.


ZOOLOGI.

GEPHYREA,

VED

D. C. DANIELSSEN OG JOHAN KOREN.

MEÐ 6 PLANCHER OG 1 KART.



CHRISTIANIA.

GRØNDAHL & SØNS BOGTRYKKERI.

1881.

1/2
f9
115
NEX
P. 4
v. 3
NH

115
11872

THE NORWEGIAN NORTH-ATLANTIC EXPEDITION

1876—1878.

ZOOLOGY.

GEPHYREA,

BY

D. C. DANIELSSEN AND JOHAN KOREN.

WITH 6 PLATES AND 1 MAP.



426 228
SEP 20 1888

SMITHSONIAN INSTITUTION
CHRISTIANIA.

PRINTED BY GRØNDAHL & SØN.

1881.

7

Idet vi forelægge Resultaterne af vore kritiske Undersøgelser over de paa den norske Nordhavsexpedition fundne Gephyreer, skulle vi bemærke, at for flere af de for denne Klasse nye Dyrs Vedkommende, have vi kun havt et enkelt Exemplar at raade over, saa at den anatomisk-histologiske Bearbejdelse har været forbunden med store Vanskeligheder.

Af de 10 Slægter og 16 Arter, som ere indsamlede, findes to nye Familier, 4 nye Slægter og 7 nye Arter, og er end ikke Antallet meget stort, saa kan det dog med Rette siges, at de deriblandt fremtrædende nye Former ere i flere Henseender af stor videnskabelig Interesse.

Paa den følgende Side findes en Tabel over de Stationers geographiske Beliggenhed, hvilke ere omtalte i Arbeidet over Gephyreerne.

In laying before the scientific world the results of our critical examination of the *Gephyrea* obtained on the Norwegian North-Atlantic Expedition, we take occasion to notice, that, as regards several of the unknown animals belonging to this Class, a single specimen only was before us; and hence the anatomical-histological investigation has necessarily been attended with very considerable difficulty.

The 10 genera and 16 species collected on the Expedition, comprise 2 new families, 4 new genera, and 7 new species, — a number in itself, perhaps, not particularly great; but we may safely affirm, that the new and interesting forms here recorded will prove valuable acquisitions to science.

On the next page we give a Table showing the Geographical Position of the Stations referred to in this Memoir.

Tempereret Area. (Warm Area.)							
Station No.	Nordlig Bredde. (North Latitude).	Længde fra Greenwich. (Longitude).	Dybde. (Depth).		Bundens Tempe- ratur. (Tempera- ture at Bottom) C.	Bunden.	Bottom.
			Engl. Favne. (Fathoms).	Meter. (Metres).			
1	61° 13'	6° 36' E.	650	1189	6.6	Sandler.	Sabulous Clay.
2	61° 10'	6° 32' E.	672	1229	6.7	Sandler.	Sabulous Clay.
9	61° 30'	3° 36' E.	206	377	5.9	Ler.	Clay.
10	61° 41'	3° 18' E.	220	402	6.0	Slik, Ler.	Ooze, Clay.
79	64° 48'	6° 36' E.	155	283	6.9	Sandler.	Sabulous Clay.
147	66° 49'	12° 8' E.	142	260	6.2	Blødder, lidt Sand.	Soft Clay. A little Sand.
149	67° 52'	13° 57' E.	135	247	4.9	Ler.	Clay.
252	Vestfjorden (Lofoten)		170	311			
255	68° 12'	15° 40' E.	341	624	6.5	Blaat Ler.	Blue Clay.
257	70° 4'	23° 2' E.	160	293	3.9	Grønlige Ler.	Greenish Clay.
260	70° 55'	26° 11' E.	127	232	3.5	Ler.	Clay.
261	70° 47'	28° 30' E.	127	232	2.8	Ler.	Clay.
262	70° 36'	32° 35' E.	148	271	1.9	Ler.	Clay.
280	74° 10'	18° 51' E.	35	64	1.1	Haard Bund.	Hard Bottom.
290	72° 27'	20° 51' E.	191	349	3.5	Sandholdigt Ler.	Sabulous Clay.
326	75° 31'	17° 50' E.	123	225	1.6	Mørkt Ler.	Dark Clay.
336	76° 19'	15° 42' E.	70	128	0.4	Haard Bund.	Hard Bottom.
357	78° 3'	11° 18' E.	125	229	1.9	Mørkt grønt Ler.	Dark-green Clay.

Kolde Area. (Cold Area.)							
Station No.	Nordlig. Bredde. (North Latitude).	Længde fra Greenwich. (Longitude).	Dybde. (Depth).		Bundens Tempe- ratur. (Tempera- ture at Bottom) C.	Bunden.	Bottom.
			Engl. Favne. (Fathoms).	Meter. (Metres).			
18	62° 44'	1° 48' E.	412	753	-1.0	Ler.	Clay.
34	63° 5'	0° 52' E.	587	1073	-1.0	Slik.	Ooze.
40	63° 22'	5° 20' W.	1215	2222	-1.2	Sandler.	Sabulous Clay.
48	64° 36'	10° 22' W.	299	547	-0.1	Sand og Slik.	Clay and Ooze.
51	65° 53'	7° 18' W.	1163	2127	-1.1	Biloculinler.	Biloculina Clay.
87	64° 2'	5° 35' E.	498	911	-1.1	Ler.	Clay.
176	69° 18'	14° 32' E.	536	980	-0.2	Ler.	Clay.
190	69° 41'	15° 50' E.	870	1591	-1.2	Sandblandet Ler.	Sandy Clay.
192	69° 46'	16° 15' E.	649	1187	-0.7	Sandler.	Sabulous Clay.
200	71° 25'	15° 40' E.	620	1134	-1.0	Ler.	Clay.
223	70° 54'	8° 24' W.	70	128	-0.6	Sort Sand og Ler.	Black Sand and Clay.
224	70° 51'	8° 20' W.	95	174	-0.6	Sort Sand og Ler.	Black Sand and Clay.
225	70° 58'	8° 4' W.	195	357	-0.6	Ler og Sand.	Clay and Sand.
237	70° 41'	10° 10' W.	263	481	-0.3	Brunt, sandholdigt Ler.	Brown sabulous Clay.
240	69° 2'	11° 26' W.	1004	1836	-1.1	Biloculinler.	Biloculina Clay.
248	67° 56'	4° 11' E.	778	1423	-1.4	Biloculinler.	Biloculina Clay.
251	68° 6'	9° 44' E.	634	1159	-1.3	Blaat Ler.	Blue Clay.
267	71° 42'	37° 1' E.	148	271	-1.4	Ler. Sten.	Clay. Stones.
270	72° 27'	35° 1' E.	136	249	0.0	Brunt Ler.	Brown Clay.
275	74° 8'	31° 12' E.	147	269	-0.4	Grønlige Ler.	Greenish Clay.
283	73° 47'	14° 21' E.	767	1403	-1.4	Biloculinler.	Biloculina Clay.
295	71° 59'	11° 40' E.	1110	2030	-1.3	Biloculinler.	Biloculina Clay.
338	76° 19'	18° 1' E.	146	267	-1.1	Haard Bund.	Hard Bottom.
366	79° 35'	11° 17' E.	37	68	-0.2	Mørkt, graat Ler.	Dark-grey Clay.

Fam. **Sipunculidæ**, Baird.

▪ **Phascolosoma Lilljeborgii**, n. sp.

Tab. I., Fig. 1—4.

Hele Legemets Længde udgjør paa de største Exemplarer 80^{mm} . Kroppen, Fig. 1, *a*, der er cylindrisk, 40^{mm} lang, 2^{mm} tyk, med en lidt konisk tilspidset Bagende, har en glat perlemorglindsende, næsten vandklar Hud, som kun sparsomt er besat med Papiller, der ere saa smaa, at de vanskeligen kunne sees med stærk Loupe, dog staa disse Papiller noget tættere mod Snabelens Grund og paa den bagerste Del af Kroppen.

Snabelen, Fig. 1, *b*, som neppe kan trækkes fuldkommen ind i Kroppen, er 40^{mm} lang, ligeledes glat, perlemorglindsende, forsynet med mere tætstaaende yderst smaa Papiller, og har paa Enden en Krands af 8—10 korte, temmelig brede Tentakler, Fig. 1, *c*, der omgiver den runde Mundaabning.

Analaabningen rund ved Snabelens Grund, Fig. 1, *d*.

Huden dannes af et meget tykt, finstribet Chitinlag (Cuticula), Fig. 3, *a*, 4, *a*, indenfor hvilket Epithelet (Matrix) findes, Fig. 3, *b*, 4, *b*, der bestaar af et Lag temmelig store Cylinderceller.

I Epithellaget sees fornemmelig paa Snabelen en Mængde Kjertler, som have en bred Grunddel, Fig. 3, *c*, 4, *c*, og en afsmalnende Udførselskanal, Fig. 3, *d*, 4, *d*, der gaar igjennem den tykke chitinøse Cuticula, paa hvis Overflade den aabner sig i en tragtformig Fordybning, Fig. 3, *e*, 4, *e*. Kjertelen dannes af en temmelig tynd Bindevævs-kapsel, Fig. 3, *f*, der paa den indvendige Flade er beklædt med Epithel, som ogsaa beklæder Udførselsgangen, Fig. 3, *g*, 4, *f*. Flere af Kjertlerne indeholdt en Samling af klare Moleküler (Slim). Til Matrix støder et meget tyndt Bindevævslag, Fig. 3, *h*, 4, *g*, hvortil den sædvanlige Muskelhud er bunden, Fig. 4, *h*.

Der er kun en Retractor, som tager sit Udspring lige bagenfor Kroppens Midtpunkt med to temmelig lange Rødder, Fig. 2, *a*, følger Bugfladen, Fig. 2, *b*, og fæster sig fortil strax bagenfor Tentakelkrandsen.

Fam. **Sipunculidæ**, Baird.

Phascolosoma Lilljeborgii, n. sp.

Pl. I., figs. 1—4.

Total length of the largest specimens 80^{mm} . The trunk, fig. 1, *a*, measuring 40^{mm} in length and 2^{mm} in thickness, is cylindrical, with the posterior extremity slightly acuminate; it has a smooth, nacrous, almost hyaline skin, sparingly furnished with papillæ, so minute as to be with difficulty perceptible under a strong magnifier; on the base of the proboscis, and on the posterior portion of the trunk, the disposition of these papillæ is somewhat closer.

The proboscis, fig. 1, *b*, which can hardly admit of being wholly retracted within the trunk, is 40^{mm} long, smooth, nacrous, studded with exceedingly minute papillæ, and bears at its extremity a cincture of short and rather broad tentacula, fig. 1, *c*, encircling the round buccal aperture.

Anal opening circular at the base of the proboscis, fig. 1, *d*.

The skin is composed of an extremely thick, finely striated chitinous layer (the cuticle), figs. 3, *a*; 4, *a*, underneath which lies the epithelium (the matrix), figs. 3, *b*; 4, *b*, consisting of a layer of rather large cylindrical cells.

In the epithelial layer — more especially on the proboscis — occur numerous glands, broad at the base, figs. 3, *c*; 4, *c*, and with a tapering excretory canal, figs. 3, *d*; 4, *d*, which pierces the thick chitinous cuticle, on the surface of which it opens into a funnel-shaped cavity, figs. 3, *e*; 4, *e*. Each gland consists of a somewhat thin capsule of connective tissue, fig. 3, *f*, covered on its inner surface by the epithelium, which also invests the excretory duct, figs. 3, *g*; 4, *f*. Several of the glands contained an aggregation of pellucid molecules (mucus). Contiguous to the matrix extends a very thin layer of connective tissue, figs. 3, *h*; 4, *g*, to which is webbed the ordinary muscular integument, fig. 4, *h*.

There is only one retractor, which takes its origin immediately posterior to the medial point of the trunk, with two longish roots, fig. 2, *a*, protends along the ventral surface, fig. 2, *b*, and is attached to the proboscis in close proximity to the cincture of tentacles.

Segmentalorganerne ere to, temmelig lange, der fæste sig som almindeligt lidt bagenfor Analaabningen paa hver Side af Retractoren, Fig. 2, *c*.

Spiserøret er meget tyndt og langt, og ligger ligesom i en Fure paa Retractoren lige bag til det Sted, hvor dennes Rødder forene sig, Fig. 2, *d*; her gaar det over i Tarmen, der gjør et Par løse Bøininger, Fig. 2, *e*, for derefter spiralformig at løbe bagtil, næsten imod Kropshulhedens Ende, Fig. 2, *f*, hvor den bøier om, uden at være befæstet til denne, og slynger sig saa atter spiralformig fortil imod Kroppens Midte, Fig. 2, *g*, hvor den gaar over i en lang, næsten ligeløbende Rectum, Fig. 2, *h*, der munder ud paa Ryggen.

Tarmspiralen er ved enkelte tendinøse Traade bunden til Kropsvæggen; men nogen særskilt Spindelmuskel findes ikke.

Paa Spiserøret iagttages et langt slangeformigt, retractilt Kar, der bagtil imod Retractorens tvende Rødder ender blindt; men fortil omgiver Svælget og danner Vandkarringen, hvorfra Tentakelkarrene udgaa.

Nervestrængen løber langs Midten af Bugfladen, Fig. 2, *i*, afgiver en Mængde Sidegrene i sit Løb og danner fortil omkring Spiserøret, som sædvanligt, en Svælgring, hvorfra sendes Grene til Svælg og Tentakler.

Æggestokken er fæstet til den bagerste Trediedel af Spiserøret, er i Begyndelsen baandformig, men bliver snart cylindrisk og danner ligesom et Rør, der slynger sig flere Gange om Tarmen. Den indeholder Æg i forskjellige Udviklingsstadier, ligesom fuldmodne Æg enkeltvis svømmede frit om i Kropsvædsken. De Exemplarer, vi undersøgte, vare Hunner.

Undertiden bebor den Anneliderør, men sædvanligt lever den uden noget saadant.

Findested.

Station: 34, 40, 51, 87, 176, 200, 295. Nogle faa Exemplarer paa hver Station.

Artskarakter.

Legemet cylindrisk, glasklart. Kroppen forsynet med spredte, fine Papiller; dens Bredde i Forhold til Længden som 1—20. Snabelen lige lang som Kroppen, besat med yderst smaa spidse Papiller. Tentaklerne 8—10. En Retractor.

Aspidosiphon armatum, n. sp.

Tab. I, Fig. 5, 6; Tab. II, Fig. 7—14.

Kroppen cylindrisk, 8^{mm} lang; den bagerste Ende er tvært afskaaren og forsynet med et rundt Chitinskjold, Fig. 5, der er sammensat af Plader, af hvilke de, som danne

The segmental organs — 2 in number — are comparatively long, and, as in other species, attached to the body a little posterior to the anal opening, on either side of the retractor, fig. 2, *c*.

The œsophagus is exceedingly thin and long, and extends, as it were, down a furrow in the retractor, back to the point at which the roots of the latter unite, fig. 2, *d*, where it passes on into the intestine, which, after one or two lax convolutions, twists spirally back almost to the end of the perivisceral cavity, fig. 2, *f*; here it bends over, but without being attached to the latter, winding spirally on towards the middle of the body, fig. 2, *g*, where it enters a long and almost straight rectum, fig. 2, *h*, which disembogues on the back.

A few tendinous filaments web the spiral of the intestine to the walls of the body; but there is no separate fusiform muscle.

On the œsophagus is seen a long, sinuous, retractile vessel, with a cæcal termination in close proximity to the roots of the retractor, but anteriorly encircling the gullet as the vascular ring, from which issue the tentacular vessels.

The nervous chord extends along the middle of the ventral surface, with numerous subsidiary branches, forming, as usual, round the œsophagus anteriorly a pharyngeal ring, from which branches proceed to the gullet and the tentacles.

Anteriorly, the ovary is webbed to the posterior third of the œsophagus; at first riband-shaped, it soon becomes cylindrical, constituting, as it were, a tube, that winds repeatedly round the intestine. It contained ova in various stages of development; also mature ova, floating here and there in the perivisceral fluid. The specimens we examined were all of them females.

This animal sometimes takes up its abode in the house of an Annelid, but is generally found to dispense with such an habitation.

Locality.

At Stations 34, 40, 51, 87, 176, 260, 295; a few specimens at each station.

Specific Character.

Body cylindrical, hyaline. Trunk furnished with minute, distant papillæ; its breadth compared to its length as 1 to 20. Proboscis, equal in length to trunk, studded with exceedingly minute pointed papillæ. From 8 to 10 tentacles. One retractor.

Aspidosiphon armatum, n. sp.

Pl. I, figs. 5, 6; Pl. II, figs. 7—14.

Body cylindrical, 8^{mm} long; posterior extremity truncate, and furnished with a round chitinous shield, fig 5, composed of plates, those forming the rim oval (petaloid), with the

Randen, ere bladformige med den smalere Del vendt indad imod Midtpartiet, og have paa deres Overflade 2—3 Korn, Fig. 7 *a*. Skjoldets Centrum derimod dannes af smaa næsten runde, og paa den ydre Flade ophøiede Plader, hvoraf en sidder i Centrum, Fig. 7, *b*. Der, hvor Skjoldets Rånd ender, har Kroppen 5—6 Ringe, der ere besatte med større og mindre Chitinplader, som dels ere flade, dels runde og ordnede saaledes, at de runde, der ere meget smaa, altid sidde imellem de større flade, Fig. 7, *c*.

Omtrent 3^{mm} foran Endeskjoldet er en Indsnøring rundt Kroppen, Fig. 5, *a*, hvorefter denne aftager lidt i Tykkelse imod Snabelens Grund, hvor der paa Rygsiden findes det forreste Chitinskjold, Fig. 5, *b*. Dette er lidt hvælvet, 4^{mm} langt, 3^{mm} bredt ved Basis, 1.2^{mm} i Spidsen, Fig. 8.

Skjoldets Rand, der især bagtil er meget ophøiet over Hudfladen, er kraveformigt sammensat af temmelig regelmæssige, aflange, hvælvede, fortil tilrandede Plader, som ere smalere ved Grunden, Fig. 8, *a*, og forlænge sig et lidet Stykke indover Skjoldets Rand. Imellem disse Plader, det vil sige der, hvor den ene Plade nærmer sig den anden, er en lille Fure, Fig. 8 *b*, hvorved Randpladerne blive saameget desto tydeligere. Den centrale Del af Snabelskjoldet bestaar af runde, ophøiede Plader, som ere ordnede i Rækker, der gaa fra Peripherien imod Centrum, Fig. 8 *c*. Imellem disse Pladerækker findes ligeledes fine Furer.

Kroppens Overflade er besat med større og mindre Chitinplader, der ere grupperede omkring Aabningerne for Hudkjertlerne, Fig. 11, 12, 13, dog saaledes, at imedens de paa Kroppens Midtparti ere uregelmæssig leirede, sidde de i temmelig regelmæssige Ringe strax bagenfor det forreste, og foran det bagerste Skjold. Den runde Analaabning findes strax bagenfor det forreste Chitinskjold.

Snabelen er 16^{mm} lang, Fig. 5, og besat lige fra Grunden til dens forreste Ende med en stor Mangfoldighed af Hager, der sidde paa omtrent 600 Ringe, Fig. 9. Hagerne ere stærkt krumboiede, hule langs den krumme Rand, Fig. 10.¹ Basaldelen er 0.028^{mm} og Høiden er 0.020^{mm} , Fig. 10.

Tentaklerne, Fig. 5 *c*, ere fra 10—12, temmelig smaa og sidde i Krands omkring den runde Mundaabning.

Hudens Cuticula er tynd, vandklar og strukturløs, Fig. 12, *a*, 13, *a*, og dækker Chitinpladerne, Fig. 12, *b*, 13, *b*, der ere leirede i den cellulære Matrix, Fig. 12, *c*, hvori findes mange Kjertler, som ere lidt langstrakte med en bred Basis, Fig. 12, *d*, og en kort Udførselsgang, Fig. 12, *e*, som aabner sig paa Kroppens Overflade med en liden Pore, Fig. 11, *a*, 13, *c*, omgivet af uregelmæssig grupperede Chitinplader, Fig. 11, 12, 13.

Indenfor Matrix er et tyndt Bindevævslag, Fig. 12, *f*, der støder til Muskelhuden, som er sammensat af Ring- og Længdemuskler. Ringmusklerne Fig. 12, *g*, bestaa af

slender part turned towards the middle of the plate, and having on their surface 2 or 3 granules, fig. 7, *a*. The centre of the shield consists of exceedingly minute, almost circular laminæ, raised on the outer surface, one of which occupies the centre, fig. 7, *b*. Where the rim of the shield terminates, the body exhibits 5 or 6 rings, covered with chitinous plates, varying in magnitude, some flat, some raised, and so disposed, that the raised plates, which are very minute, invariably occupy a position between the comparatively large flat ones, fig. 7, *c*.

About 3^{mm} in advance of the terminal shield is seen a constriction of the body, fig. 5, *a*, from whence the latter diminishes in thickness to the base of the proboscis, where, on the dorsal surface, occurs the foremost chitinous shield, fig. 5, *b*.

This shield, which is slightly arcuate, measures 4^{mm} in length, 3^{mm} in breadth, and 1.2^{mm} across at the apex, fig. 8. The rim of the shield, posteriorly projecting to a considerable extent above the surface of the skin, is jugal in form, and built up of comparatively uniform, oval, arcuate plates, rounded off anteriorly; being narrower at the base, fig. 8, *a*, they are produced a little within the rim of the shield. Between these plates, occurs a small groove, fig. 8 *b*, by reason of which the rim-plates are easier to distinguish. The central portion of the shield on the proboscis is composed of raised circular plates, proceeding in rows from the circumference to the centre, fig. 8, *c*. Here, too, minute furrows extend between the series of plates.

The surface of the body is furnished with chitinous plates, of varying magnitude, grouped round the apertures of the glands of the skin, figs. 11, 12, 13, — irregularly on the medial region of the body, but immediately posterior to the foremost and anterior to the hindmost shield, in comparatively uniform annular series. The round anal opening is placed immediately posterior to the foremost chitinous shield.

The proboscis measures 16^{mm} in length, fig. 5, and is studded from its base to its anterior extremity with a multitude of chitinous hooks, affixed to about 600 annulets, fig. 9. These chitinous hooks are much bent, and hollowed out along their curved margins, fig. 10. Width of basal portion 0.028^{mm} , height 0.020^{mm} , fig. 10.

The tentacles, fig. 5, *c*, from 10 to 12, are comparatively small; they encircle, cincture-like, the round buccal aperture.

The cuticle, thin, translucent, and structureless, figs. 12, *a*; 13, *a*, invests the chitinous plates, figs. 12, *b*; 13, *b*, disposed throughout the cellular matrix, fig. 12, *c*, which is furnished with numerous glands, somewhat elongate in form, with the base broad, fig. 12, *d*, and a short excretory duct, fig. 12, *e*, opening on the surface of the body through a small pore, fig. 11, *a*; 13, *c*, round which chitinous plates, figs. 11, 12, 13, are irregularly grouped.

Underneath the matrix extends a thin layer of connective tissue, fig. 12, *f*, contiguous to the muscular integument, which is composed of annular and longitudinal

stærke Muskelbundter, som sammenbindes ved Bindevæv til en sammenhængende Membran, hvilket ogsaa er Tilfældet med Længdemusklene, hvis Bundter dog staa længere fra hverandre, hvorved Huden paa enkelte Steder af Kroppen faar ved gennemfaldende Lys et gittret Udseende, Fig. 12, *h*.

Der, hvor det forreste Skjold danner en Fremstaaenhed paa den udvendige Flade af Kroppen, er en tilsvarende Fordybning paa den indvendige Flade, Fig. 6, *a*, og om hvilken, (egentlig om Skjoldranden), Ringmusklene danne en temmelig tyk Vold, hvorved Hullheden bliver dybere, — og paa denne Vold fæste den Del af Længdemusklene sig, hvilke løbe langs Rygfladen; thi de gaa, ligesaa lidt som Ringmusklene, over Skjoldhulen. Derimod er denné forsynet med et eget Muskelapparat, der bestaar af 20 isolerede Muskler, Fig. 6, *b*, 14, *a*, som have en sølvglindsende Farve, og tage deres Udspring lidt udenfor den førnævnte Vold, gaar dækket af denne ned i Skjoldhulheden, hvor de fæste sig dels paa Midten, dels paa den forreste Trediedel af den indre hule Skjoldvæg. De midterste ere de længste og have lige Retning, Fig. 14, *b*; men alt eftersom de tage Udspring fra Siderne og fortil, Fig. 14, *a*, *c*, blive de kortere og faa da en skraa Retning, saa at det Hele antager Formen af en Glorie, Fig. 14. Disse Muskler synes at være bestemte til at dirigere Skjoldet. Den midterste og forreste Del af Skjoldhulen er kun beklædt af Peritoneum, der forresten giver hele Muskelhudens indre Flade sit Overtræk.

Imod den bagerste Kropsende, ved den tidligere omtalte Fure, blive Ringmusklene noget tykkere og bidrage derved til at danne den før beskrevne Afdeling, Fig. 5, *c*, paa Kroppens Overflade.

Saa vel Ring- som Længdemusklene ende ved det bagerste Skjolds Rand, hvis indvendige Flade er næsten plan.

Der er kun en Retractor, der tager sit Udspring paa Endeskjoldets indre Flade, nærmere Bugsiden, med to Rødder, Fig. 6, *c*, og følger saa denne lige op til Spiserøret, Fig. 6, *d*, som den forstørstedelen omgiver som en Skede, indtil den fæster sig strax bagenfor Tentakelkransen, Fig. 6, *e*.

Spiserøret, Fig. 6, *f*, der er cylindrisk, smalt og tildels indesluttet af Retractor, gaar ved en lille Indsnøring over i den lidt bredere Tarm, som spiralformig gaar bag til Krops-hulhedens Ende, Fig. 6, *g*, bøier sig fortil fremdeles i Spiraler, indtil den gaar over i en temmelig kort Rectum, Fig. 6, *h*, der aabner sig paa Rygsiden, strax bagenfor det forreste Skjold.

Tarmspiralen er fæstet til det bagerste Skjolds indre Flade ved enkelte Bindevævstraade, og Rectum er paa sin forreste Ende bundet til Huden ved mange fine muskuløse Traade.

muscles. The former, fig. 12, *b*, are built up of powerful muscular fascicles, webbed together as a continuous membrane by connective tissue; this is likewise the case with the longitudinal muscles, the fascicles of which are, however, less closely arranged, giving to the skin, when held up to the light, in certain parts of the body a tessellated appearance, fig. 12, *h*.

On the outer surface of the body, occurs a prominence, formed by the shield; and on the inner surface, is seen a corresponding depression, fig. 6, *a*, round which (or rather, round the rim of the shield) the annular muscles constitute a thickish ridge, increasing the depth of the excavation: to this ridge are attached such of the longitudinal muscles as extend along the dorsal surface; for neither the longitudinal nor the annular muscles cross the hollow of the shield. The shield is provided with a special muscular apparatus, viz. 20 isolated muscles, figs. 6, *b*; 14, *a*, of a silvery lustre, originating a little without the aforesaid ridge, under cover of which they pass down into the hollow of the shield, and are there attached, either to the middle or to the anterior third of the hollow inner wall. The medial muscles are the longest, and protend in a right line, fig. 14, *b*; but the nearer the point of origin approaches the sides or the front part, fig. 14, *a*, *c*, the shorter and more oblique do the muscles become, causing the whole assemblage to resemble a halo, fig. 14. These muscles would seem to govern the shield. The middle and front part of the hollow is covered by the peritoneum alone, which also invests the inner surface of the whole muscular integument.

Near the posterior extremity of the body, along the groove noticed above, the annular muscles slightly increase in thickness, and thus contribute towards forming the section of the surface of the body, fig. 5, *c*, previously described.

Both the annular and the longitudinal muscles terminate at the rim of the posterior shield, the inner surface of which is almost flat.

This animal has but one retractor, which, springing from two roots, fig. 6, *c*, takes its origin on the inner surface of the terminal shield, nearest the ventral side, protending along the latter till it reaches the œsophagus, fig. 6, *d*, which it almost surrounds, in the form of a sheath, being affixed immediately posterior to the cincture of tentacles, fig. 6, *e*.

The œsophagus, fig. 6, *f*, cylindric, slender, and partially enclosed by the retractor, passes, with a slight constriction, into the somewhat wider intestine, which coils spirally back to the termination of the perivisceral cavity, fig. 6, *g*, from whence, making a bend forwards, it continues on, twisting spirally as before, till it enters a comparatively short rectum, fig. 6, *h*, which opens on the dorsal surface, immediately posterior to the foremost shield.

The spiral of the intestine is attached to the inner surface of the hindmost shield by a few filaments of connective tissue, and the rectum webbed to the skin at its anterior extremity by numbers of delicate muscular filaments.

Langs Tarmspiralen laa et langt fladt, hvidgult Legeme, som var fæstet til Spiserøret, og som ved nærmere Undersøgelse viste sig at være Æggestokken, Fig. 6, *i*, der indeholdt Æg i forskellige Udviklingsstadier; i Kropshulheden fandtes en Mængde fritsvømmende Æg. Disse vare flade, skivedannede, ovale med en noget tilspidset Pol, 0.136^{mm} længe, 0.112^{mm} brede og forsynede med Kimblære og Kimplet; forresten ligne de Æggene hos *Phascolosoma*.

To Segmentalorganer, der ere frithængende og brunfarvede, Fig. 6, *k*.

Nervestrængen løber imellem Rødderne af Retractor og følger Bugfladen lige til den forreste Ende af Spiserøret, om hvilket den danner en Ring.

Farven. Kroppen lys gulbrun med lidt mørkere Tentakler. Skjoldene mørkebrune.

Kun et Exemplar blev fundet paa 87de Station.

Artskarakter.

Kroppen cylindrisk, 8^{mm} lang, bedækket af større og mindre Chitinplader; den bagerste Ende tværs afskaaren. Snabelen dobbelt saa lang, som Kroppen, overalt besat med Hager og forsynet med 10—12 korte Tentakler. Endeskjoldet rundt, næsten fladt, sammensat af Chitinplader, den i Randen ere tungeformede, i Centrum runde. Udenom Skjoldet 6 Ringe, besatte med Plader. Det forreste Skjold omvendt hjerteformigt.

Af de hidtil beskrevne Arter af Slægten *Aspidosiphon* kommer *armatum* nærmest den af Dr. Théel¹ beskrevne *Asp. mirabilis*; men den adskiller sig fra denne derved, at Snabelen er meget længere og overalt besat med Hager, at Skjoldene have, en noget forskjellig Form, og at Chitinpladerne, hvoraf disse ere sammensatte, ere forskjellig ordnede.

Destoværre have vi kun havt 1 Exemplar til voré Undersøgelser, der som Følge deraf ikke ere blevne saa udtømmende, som vi kunde ønske; men se vi hen til de Beskrivelser, der foreligge over Slægten *Aspidosiphon* og dens Arter, ere vi tilbøielige til at tro, at ogsaa de Forskere, som tidligere have beskjeftiget sig dermed, have ligesom vi manglet Materiale; thi ellers vilde sikkerligen Beskrivelserne have været mere fuldstændige, end de ere.

Stretching along the spiral of the intestine, and attached to the œsophagus, was seen a flat, whitish-yellow body, which, on closer inspection, proved to be the ovary, fig. 6, *i*, containing ova in various stages of development; and numbers of isolated ova were found floating in the perivisceral cavity. The ova of this animal, measuring 0.136^{mm} in length and 0.112^{mm} in breadth, are flat, discoid, oval, with a slightly acuminate extremity; they have a germinal vesicle and a germinal speck, and for the rest resemble the eggs of *Phascolosoma*.

Two free depending segmental organs, brown in colour, fig. 6, *k*.

The nervous chord protends between the roots of the retractor along the ventral surface to the anterior extremity of the œsophagus, which it annulates.

Colour. — Body light yellowish-brown, with somewhat darker tentacles. The shields dark-brown.

One specimen only was brought up, at Station 87

Specific Character.

Body cylindrical, 8^{mm} long, covered with chitinous plates of varying magnitude; posterior extremity truncate. Proboscis, twice the length of the trunk, studded all over with chitinous hooks, and furnished with 10 or 12 short tentacula. Terminal shield round, almost flat, composed of chitinous plates, which at the margin of the shield are linguiform, at the centre round. Round about the shield, 6 annular bands covered with plates. Foremost shield inverted cordiform.

Of the species belonging to the genus *Aspidosiphon* as yet described, *Asp. armatum* bears the closest resemblance to *Asp. mirabilis*, described by Dr. Théel,¹ but is distinguished from it by having a much longer proboscis, studded all over with chitinous hooks; moreover, the shields in the two species differ somewhat in form, and the arrangement of the chitinous plates composing them is different.

Unfortunately, we have had only one specimen on which to base our observations; and hence they are less exhaustive than we should have wished them to be; but, calling to mind the descriptions previously furnished of the genus *Aspidosiphon* and its species, the naturalists who have made these animals the subject of investigation, would, like ourselves, appear to have lacked sufficient materials; otherwise their descriptions had certainly approached nearer to completeness.

¹ H. Théel. Études sur les Gephyriens inermes. Bihang til Kongl. Sv. Vet. Acad. Handlingar. 3 Bd. No. 6, Pag. 17.

¹ H. Théel. Études sur les Gephyriens inermes. Bihang til Kongl. Sv. Vet. Acad. Handlingar. 3 Bd. No. 6, Pag. 17.

Onchnesoma glaciale, n. sp.

Tab. I, Fig. 15—20.

Legemet's hele Længde paa de største Exemplarer er omtrent 105^{mm}.

Kroppen er 35^{mm} lang, 2^{mm} bred, cylindrisk, glat, glindsende, med en næsten tapformig Bagende og en vandklar Hud, der paa den bagerste Kropsende er yderst sparsomt besat med meget smaa uregelmæssig stillede Papiller, Fig. 15, 15¹.

Snabelen er omtrent dobbelt saa lang som Kroppen, ender knopformig med den runde Mundaabning i Midten, Fig. 15¹. Den forreste Fjerdedel af Snabelen er forsynet med mange regelmæssige, temmelig tætstaaende Rækker Hager, der tage deres Begyndelse strax bagenfor Mundaabningen og ere kun lidet krummede, Fig. 19.

Hagernes Basaldel er fra 0,040—0,060^{mm} bred og deres Høide er fra 0,045—0,064^{mm}, Fig. 18, 20. De ere bleg gulbrune, hule, have en næsten trekantet Basis og en mod Huden vendende Spids, forsynet med en fin Aabning, Fig. 18, 19. Den hule Grunddel optager for en Del Huden.

Analaaabningen er rund, noget foran Snabelgrunden, Fig. 16, *a*, og lidt bagenfor den sees en Aabning for Segmentalorganet.

Den vandklare Hud har en bred Cuticula, som er finstribet og hvis Linier løbe kredsformig om Dyrets Legeme, Fig. 17, *a*, 18, *a*; indenfor Overhuden er Epithellaget, der er smalt og dannes af en Række cylindriske Celler, Fig. 17, *b*, 18, *b*, der med et yderst smalt Bindevævsstratum, Fig. 17, *c*, ere bundne til Muskelhuden, som bestaar af de sædvanlige to Lag, Ring- og Længdemuskler, som hver for sig ved Hjælp af Bindevæv danner en sammenhængende Hud, Fig. 17, *d*, *e*.

I Epithellaget findes en Mængde temmelig store Kjertler, der have en noget konisk Figur, og hvis brede Del hviler paa det smale Bindevævsdrag, saa at det ser ud, som om den støder umiddelbart til Ringmuskelhuden, Fig. 17, *f*, 18, *c*. Den smalere, noget afrundede Del rager langt op i den klare Cuticula, Fig. 17, *g*, hvor den ender i Udførselsgangen, som aabner sig næsten tragtformig paa Huden Overflade, Fig. 17, *h*. Disse Kjertler dannes af en Kapsel, der egentlig er en Fortsættelse af det smale Bindevævsdrag, og som indvendig er beklædt med Celler, Fig. 17, *i*, 18, *d*; Kjertlerne ere opfyldte af en seig Vædske.

Der er kun en Retractor, som udspringer fra Midten af Kroppen med en noget bred Rod, der paa enkelte Exemplarer havde et lidet Indsnit, Fig. 16, *b*; den smalner da strax af og løber fortil langs Bugfladen til Mundaabningen,

Onchnesoma glaciale, n. sp.

Pl. I, figs. 15—20.

The whole length of the body in the largest specimens about 105^{mm}. Trunk 35^{mm} long, 2^{mm} broad, cylindric, smooth, lustrous, the posterior extremity having much the shape of a faucet.

Skin hyaline, at the posterior extremity of the trunk very sparingly furnished with minute, irregularly scattered papillæ, figs. 15, 15¹.

The proboscis, about twice as long as the trunk, nodular at the terminal extremity, with the round buccal aperture in the middle, fig. 15. The anterior fourth of the proboscis is furnished with numerous regular, comparatively closely arranged series of chitinous hooks, but slightly bent, which take their origin a little posterior to the buccal aperture, fig. 19.

The basal portion of these ungueal spiculæ, or hooks, measures from 0.049^{mm} to 0.060^{mm} in breadth; their height is from 0.045^{mm} to 0.064^{mm}, figs. 18, 20. They are hollow, and pale yellowy-brown in colour; the base is almost triangular, and the point, turned towards the skin, furnished with a minute orifice, figs. 18, 19. The hollow basal portion is partly occupied by the tegumentary gland.

Anal opening round, placed a little anterior to the base of the proboscis, fig. 16, *a*; and about the same distance posterior to it is seen a small opening, or pore, for the segmental organ.

The hyaline skin has a broad, finely striated cuticle, the striæ completely encircling the body of the animal, figs. 17, *a*; 18, *a*. Underneath the cuticle extends the epithelial layer, which is narrow, and built up of a series of cylindric cells, figs. 17, *b*; 18, *b*, webbed by an exceedingly narrow stratum of connective tissue, fig. 17, *c*, to the muscular integument, consisting of the two ordinary layers of annular and longitudinal muscles, each of which constitutes by means of connective tissue a continuous tegumentary covering, fig. 17, *d*, *e*.

Throughout the epithelial layer are dispersed a number of comparatively large glands, somewhat conical in form, the broad portion of which, resting on the narrow layer of connective tissue, gives them the appearance of being in direct contact with the annular muscular integument, figs. 17, *f*; 18, *c*. The narrow, somewhat rounded part projects far up into the cuticle, fig. 17, *g*, where it terminates in the excretory canal, which disembogues through an almost funnel-shaped opening on the surface of the skin, fig. 17, *h*. These glands consist of a capsule, which, strictly, is a continuation of the narrow layer of connective tissue, invested on its inner surface with cells, figs. 17, *i*; 18, *d*; the glands contain a viscous fluid.

There is only one retractor, springing from the middle of the body, with a broadish root, which in some of the specimens had a slight incision, fig. 16, *b*; it immediately begins to taper, protending along the ventral surface as

hvor den fæster sig i den Vold, som omgiver denne. Den har en hvid glindsende Farve.

Der er et Segmentalorgan, som er omtrent 3^{mm} langt, smalt, og som ved sin bredere forreste Ende er fæstet til Bugfladen noget bagenfor Analaabningen til Høire, imellem Rectum og Retractor, Fig. 16, *c*. Det har en lidt brunlig Farve og temmelig tykke Vægge.

Spiserøret er meget smalt, ligger paa den forreste Del næsten omfattet af Retractor, noget længere bag hviler det paa dennes Midte, Fig. 16, *d*, hvortil det er bundet ved Bindevæv og løber bag mod Retractors Grund, hvor det bøier sig og gaar et Stykke fortil lidt til Høire, Fig. 16, *e*; her danner det en Bøining og gaar over i Tarmen, Fig. 16, *f*, der spiralførmig slynger sig lige bag til Bunden af Krøpshulheden, Fig. 16, *g*, hvorfra den igjen vinder sig om de bagtilgaaende Tarmslynger, Fig. 16, *h*, idet den løber fortil mod det Sted, hvor Spiserøret gaar over i Tarmen; herfra har den en lige Retning og danner en lang Rectum, Fig. 16, *i*, som aabner sig lidt foran Snabelens Grund.

Saa vel Rectum som hele Tarmslyngen er ved enkelte Bindevævstraade bunden til Kropsvæggen. Den bagerste Ende er fri. Nogen Spindelmuskel findes ikke, ligesaa lidt som noget Vandkarsystem.

Nervestrængen løber som sædvanligt langs Midten af Bugfladen, Fig. 16, *k*, og lægger sig lige ved Retractors venstre Rand, som den følger til Dyrets forreste Ende, hvor den slaar sig om Spiserøret for at danne Svælgringen. Paa denne Vei afgiver den en Mængde Sidegrene til Huden og Spiserøret.

Findested.

Flere Exemplarer paa Station 51, 240, 248. Et Exemplar Stat. 251. Mange Exempl., der vare sammenflettede ved den lange Snabel, paa Stat. 283.

Artskarakter.

Kroppen cylindrisk, 35^{mm} lang, 2^{mm} bred; dens Bagende sparsomt besat med yderst fine Papiller. Snabelen dobbelt saa lang som Kroppen; dens forreste Fjerdedel forsynet med mange regelmæssige Rækker Hager. Huden glasklar.

*Stephanostoma*¹ *Hanseni*², n. g. n. sp.

Tab. II, Fig. 21—29; Tab. IV, Fig. 19.

Kroppen rund, næsten tenformig, 60^{mm} lang, 13^{mm} tyk i Nærheden af Analaabningen, Fig. 21, *a*. Den ba-

¹ Στέφανος, Krands, στόμα, Mund.

² Benævnt efter Overlæge G. Armauer Hansen.

Den norske Nordhavsexpedition. Danielsen og Koren: Gephyrea.

far as the buccal aperture, to the ridge surrounding which it is attached. The retractor is lustrous white.

There is one segmental organ, about 3^{mm} long, narrow, with its broader, anterior extremity attached to the ventral surface, to the right of, and a little posterior to, the anal opening, between the rectum and the retractor, fig. 16, *c*. It is of a brownish colour, and has comparatively thick walls.

The œsophagus is very narrow, its anterior part being almost surrounded by the retractor; a little farther back, it rests on the middle of that organ, fig. 16, *d*, to which it is webbed by connective tissue, protending from thence back to the base of the retractor, where it makes a bend, and passes forward, a little to the right, fig. 16, *e*; here it makes another bend, previous to entering the intestine, fig. 16, *f*, which winds spirally back to the bottom of the perivisceral cavity, fig. 16, *g*, from whence it coils round the receding convolutions of the intestine, fig. 16, *h*; here it takes a straight course, forming a long rectum, fig. 16, *i*, which disembogues a little anterior to the base of the proboscis.

Both the rectum and the whole spiral of the intestine, are attached to the wall of the body, by a few filaments of connective tissue. Posterior extremity free. There is no fusiform muscle; neither is there any aquiferous system.

The nervous chord protends as usual along the middle of the ventral surface, fig. 16, *k*, in immediate proximity to the left margin of the retractor, which it accompanies to the anterior extremity of the animal, and there winds round the œsophagus, forming the pharyngeal ring. On its course it sends off numerous subsidiary branches to the skin and the œsophagus.

Locality.

Several specimens at Stations 51, 240, and 248. One specimen at Station 251. At Station 283 numerous examples were brought up, with their long probosces interlaced.

Specific Character.

Trunk cylindrical, 35^{mm} long, 2^{mm} broad; the posterior extremity sparingly furnished with minute papillæ. Proboscis twice as long as trunk; its anterior fourth studded with numerous regular series of chitinous hooks. Skin hyaline.

*Stephanostoma*¹ *Hanseni*², n. g. n. sp.

Pl. II, figs. 21—29; Pl. IV, fig. 19.

The trunk round, almost fusiform, 60^{mm} long, 13^{mm} thick in close proximity to the anal opening, fig. 21, *a*.

¹ Στέφανος, wreath; στόμα, mouth.

² Dedicated to G. Armauer Hansen. M. D.

gerste Ende er konisk tilspidset, Fig. 21, *b*. Den forreste Del bliver noget smalere, idet den gaar over i Snabelen.

Snabelen er cylindrisk, omtrent 64^{mm} lang, 5^{mm} tyk i dens Begyndelse, Fig. 21, *c*; men udvider sig efterhaanden lidt, saa at den op imod den forreste Ende bliver indtil 9^{mm} , Fig. 21, *d*; her bliver den i en Afstand af $3-4^{mm}$ fra Tentakelkraven noget smalere, danner en Slags Hals, Fig. 21, *e*, og ender i en temmelig bred, hvælvet, actinie-lignende Skive, Fig. 21, *f*, i hvis Midte findes den runde Mundaabning, Fig. 21, 22, *b*, og hvis Omkreds indtages for Størstedelen af Tentaklerne, Fig. 21, *g*, 22, *c*.

Tentaklerne indtage en særegen Stilling paa Mundskiven, idet den egentlige Tentakelkrave er meget stærkt bugtet, saaledes nemlig, at den danner 10 store Indbugtninger (Festons) og 10 smaa, Fig. 22, 23.

De store Indbugtninger strække sig et langt Stykke ind paa Mundskiven. Enhver saadan Feston er paa dens to Rande besat med Tentakler, 8 paa hver Rand, Fig. 22, 23, *a*, og faar derved et fryndset Udseende. De 4 inderste Tentakler ere de største, derefter aftage de betydeligt i Størrelse, saa at de to yderste ere temmelig smaa, og faa Udseende af at gaa over paa den lille Indbugtnings Rand, naar Tentakelkrandsen ikke er fuldt udstrakt, Fig. 23.

De 10 smaa Indbugtninger ere egentlig Fortsættelser af de store; men strække sig kun lidt indenfor Mundskivens Rand, og ere kun forsynede med hver sine to Tentakler, Fig. 23, *b*, der ere i Størrelse som de 5te (indefra) paa de store Festons.

Alle Tentaklerne ere flade, konisk tilspidsede, og have paa den ene Flade ligesom en Fure, der fremkommer derved, at Randene bøje sig lidt imod hinanden. Der er ialt 180 Tentakler.

Analaabningen er rund og findes i Centrum af en temmelig fremstaaende Papille paa Rygsiden, omtrent 10^{mm} fra Snabelens Grund, Fig. 21, *h*.

Kroppens Overflade er forsynet med fine Tværlinier, der blive tydeligere paa Snabelen, Fig. 21, og paa disse Linier iagttages yderst smaa Papiller, der især paa den forreste Del af Snabelen staa i temmelig regelmæssige Grupper, Fig. 22, *d*, 24. Tydeligst ere dog disse Papiller paa den bagerste Kropsende.

Huden er meget fast, læderagtig, tyk og stærkt contractil. Den bestaar af en tyk, gjennemsigtig, glasklar Cuticula, der er stribet baade efter Længden og Bredden, Fig. 25, *a*, 26, *a*. Paa den ydre Flade af Cuticula iagttages en stor Mængde fine Porer, Fig. 25, *b*, 26, *b*, der ere Aabninger for Slimkjertlernes Udførselsgange.

Indenfor Cuticula er den egentlige Matrix, bestaaende af Epithel- og Pigmentceller, Fig. 25, *c*, 26, *c*, og i dette Lag er en stor Mængde Slimkjertler leirede, Fig. 25, *d*. Disse have en konisk Form med en temmelig bred Grunddel, Fig. 26, *d*, og fra hvis noget afstumpede Spids, Fig.

Posterior extremity acuminate, fig. 21, *b*. The anterior part diminishes somewhat in circumference where it is produced into the proboscis.

The proboscis is cylindrical in form, about 64^{mm} long, and 5^{mm} thick at origin, fig. 21, *c*, but gradually expands to 9^{mm} , near the anterior extremity, fig. 21, *d*; here, 3 or 4^{mm} from the tentacular collar, it becomes a trifle slenderer, constituting a kind of neck, fig. 21, *e*, and terminates in a comparatively broad, arcuate disk, somewhat like the oral disk of an Actinia, fig. 21, *f*, in the middle of which is the round buccal aperture, figs. 21; 22, *b*, the greater part of the peripheral margin being taken up by the tentacles, figs. 21, *g*; 22, *c*.

The position of the tentacles on the buccal disk is peculiar, the collar itself being remarkably waved, forming as it does a series of undulations, 10 long (festoons) and 10 short, figs. 22; 23.

The long undulations extend far out on the buccal disk. Each of these festoons is studded along its two margins with tentacles, 8 on either margin, figs. 22; 23, *a*, which gives them a fringed appearance. The 4 innermost tentacles are the largest; the others diminish considerably in size, the two outermost being comparatively small, and when the whole assemblage forming the collar are not fully exerted, seemingly placed on the margin of the nearest short undulation, fig. 23.

The 10 short undulations are strictly continuations of the large ones, but reaching very little, within the margin of the oral disk, and furnished with only two tentacles each, fig. 23, *b*, in magnitude equal to the fifth (counting from within) of those forming the festoons.

All of the tentacles are flat, acuminate; and the margins slightly inclining towards each other, a grooved depression extends along one of the surfaces. Total number of tentacles 180.

The anal opening is round, and placed in the centre of a rather prominent papilla on the dorsal side, about 10^{mm} from the base of the proboscis, fig. 21, *h*.

The surface of the body is transversely striate, the fine striæ being most conspicuous on the proboscis, fig. 21; and, dispersed along them, extend a multitude of exceedingly minute papillæ, which, more especially on the anterior part of the proboscis, are arranged in comparatively regular groups, figs. 22, *d*; 24; the papillæ are most conspicuous, however, on the posterior extremity of the trunk.

The skin is exceedingly firm, coriaceous, thick, and highly contractile. It consists of a thick, hyaline, translucent cuticle, transversely and longitudinally striate, figs. 25, *a*; 26, *a*. On the outer surface of the cuticle, are seen a multitude of minute pores, figs. 25, *b*; 26, *b*, — openings for the excretory canals of the mucous glands.

Underneath the cuticle, extends the true matrix, consisting of the epithelium and pigmentary cells, figs. 25, *c*; 26, *c*. Throughout this layer are disposed numbers of mucous glands, fig. 25, *d*, conical in form, with a comparatively broad base, fig. 26, *d*, and a somewhat obtuse sum-

26, *e*, løber en Udførselsgang, Fig. 26, *f*, op igjennem Cuticula for at aabne sig paa dennes Overflade.

Kjertelen er paa den indre Flade beklædt med et Epithel, Fig. 26, *g*, der afsondrer en seig, grønlig Slim, som tildels ganske udfyldte Kjertelen, og som fandtes baade i Udførselsgangen og paa Kroppens ydre Flade.

Matrixen er bundet til et meget smalt Bindevævslag, Fig. 26, *h*, der fæster sig til Muskelhuden. Denne er meget tyk og bestaar af et Lag Ringmuskler, Fig. 25, *e*, som ikke er meget bredt i Forhold til det andet Lag, nemlig Længdemusklerne, Fig. 25, *f*, der ere meget tykke med særdeles stærke Fibre. Indenfor Længdemusklerne er det flimrende Peritonealovertræk.

Fordøielsesapparatet.

Svælget er temmelig vidt og foldet, og gaar over i det smale, lange, muskuløse Spiserør, der er lidt indknebet ved Overgangen til Tarmen, Fig. 27, *a*. Denne danner først et Par smaa Bøininger, derefter slaar den sig paa tværs imod høire Side, Fig. 27, *b*, gjør nu en Slynkning om Spiralmuskelen, Fig. 27, *c*, for derefter omkring denne spiralformig at løbe bagimod Kropshulhedens bagerste Ende, Fig. 27, *d*, hvorfra den atter i Spiral løber fortil, for at gaa over i Endetarmen, Fig. 27, *e*, der udmunder i den førnævnte Rygpapille.

Tarmspiralen, der ligger omtrent i Midten af Kropshulheden, bestaar af omkring 54 Slynninger, Fig. 27.

Spindelmuskelen tager sin Begyndelse strax bagenfor den yderste Ende af Rectum, lidt til Siden, løber langs Rectum til Midten af Kropshulheden, hvor den gaar ind i Tarmspiralen, og løber i denne lige ned til den bagerste Ende af Kropshulheden, hvor den fæster sig, Fig. 27, *c*.

Svælget og Spiserøret er bundet ved meget stærke muskuløse Baand til den forreste Del af Snabelens indre Flade, og Tarmen er ved et stærkt Mesenterium, bestaaende af Bindevæv og tildels Muskelfibre, bundet til Bugfladen.

Rectum er ved mange, temmelig brede, stærke tendinøse Baand fæstet til Kroppsvæggen, og fra dens forreste Del udgaar en lang Muskeltraad, som fæster sig paa den første Tarmslynge, Fig. 27.

Paa Bugsiden af Spiserøret iagttages et gulagtigt Kar, der er yderst fint, men bliver tykkere alt eftersom det løber længere bag over Tarmen, hvor det ender blindt paa den første Tarmslynge, Fig. 27, *f*, efter at det har givet nogle temmelig tykke Grene til Tarmen. Hvorledes dette Kar forholder sig fortil, kunne vi ikke afgjøre; thi paa Spiritusexemplarerne saa det ud, som om det forsvandt i Svælgvæggen. Indholdet bestod af en Mængde smaa runde Legemer med en Kjerne, og havde noget tilfælles med sammenløbet Kroppsvædske.

Paa Rygfladen af Svælget, lidt til høire Side, findes

mit, fig. 26, *e*, from which an excretory canal, fig. 26, *f*, passes up through the cuticle, to disembogue on its surface.

Each of these glands is invested on its inner surface with epithelium, fig. 26, *g*, that secretes a viscid, greenish coloured mucus, with which some of the glands were entirely filled; it occurred, too, in the excretory canal, and on the outer surface of the body.

The true matrix is webbed to an extremely narrow layer of connective tissue, fig. 26, *h*, attached to the muscular integument. The latter is exceedingly thick, and consists of a layer of annular muscles, fig. 25, *e*, not particularly broad compared to the other layer, viz. that of the longitudinal muscles, fig. 25, *f*, which are very thick, with exceedingly strong fibres. Underneath the longitudinal muscles extends the ciliated peritoneal tunic.

Digestive Apparatus.

The gullet is comparatively wide, and folded; it opens into the long, narrow, muscular œsophagus, which is somewhat constricted at the entrance to the intestine, fig. 27, *a*. The latter, after a slight bend or two, strikes off, in a transverse direction, to the right, fig. 27, *b*, makes a twist round the spiral muscle, fig. 27, *c*, and then winds about it back to the posterior termination of the perivisceral cavity, fig. 27, *d*, from whence it passes forwards, coiling spirally as before, into the rectum, fig. 27, *e*, which disembogues through the aforesaid dorsal papilla.

The spiral portion of the intestine, lying as near as may be in the middle of the perivisceral cavity, consists of about 54 circumvolutions, fig. 27.

The fusiform muscle originates — a little on one side — immediately posterior to the outer extremity of the rectum, along which it protends to the middle of the perivisceral cavity, where it enters the spiral of the intestine, and passes straight down it to the posterior termination of the perivisceral cavity, to which it is attached, fig. 27, *c*.

The gullet and the œsophagus are webbed by strong muscular bands to the anterior portion of the inner surface of the proboscis; and a strong mesentery, consisting of connective tissue, and, in part, of muscular fibres, webs the intestine to the ventral surface.

The rectum is webbed to the wall of the body by numerous strong and rather broad tendinous bands; and from its anterior part issues a long muscular filament, attached to the first convolution of the intestine, fig. 27.

On the ventral surface of the œsophagus is seen a yellowish coloured vessel, exceedingly slender, but increasing in thickness as it passes farther back along the intestine, where, after sending off a few thickish branches to the intestine, it terminates cæcally, on the first convolution of the intestine, fig. 27, *f*. Anteriorly, we are unable to describe this vessel, coalescing as it apparently did, in the spirit-specimens, with the pharyngeal wall. Its contents, which bear a close resemblance to coagulated perivisceral fluid, consisted of numerous globular nucleal corpuscles.

On the dorsal surface of the gullet, a little to

et langt, rørformigt, gjennemsigtigt Legeme (det contractile Kar), der gaar et Stykke bag paa Tarmen, hvor det ender i en kolbeformig Blindsæk, Fig. 27, *g*; fortil løber det til Snabelens forreste Ende, hvor det deler sig, og danner Karringen, som følger Tentakelkraven i alle dens Bugtninger for at afgive Grene til Tentaklerne.

Retractorerne ere 4, hvoraf de to Bugretractorer ere meget lange og tage deres Udspring med 3 Rødder fra den forreste Del af Kropshulhedens bagerste Trediedel, Fig. 27, *l*, imedens Rygretractorerne udspringe fra det forreste Parti af Kropshulhedens midterste Trediedel, Fig. 27, *h*. Strax bagenfor Spiserørets forreste Ende forene de sig og danne ligesom en Skede om dette, idet de fæste sig som sædvanligt paa Mundskivens Rand.

To Segmentalorganer, Fig. 27, *i*, der ere meget små, omtrent 6^{mm} lange og 2^{mm} brede ved deres Tilhæftningssted. Lidt bagenfor dette og paa den Side, som vender imod Kropsvæggen, sees en liden oval, tragtformig Aabning, Fig. 28, *a*, der fører ind til Hulheden.

Centralnervestrængen ligger langs Midten af Bugfladen imellem begge Retractorerne og er temmelig tyk, Fig. 27, *k*, 29, *a*. Den afgiver paa sit hele Løb en Mængde Sidegrene, der som oftest udgaa afvxlende og tabe sig i Huden. Strax bagenfor Mundaabningen deler den sig i to Grene, Fig. 29, *b*, *b*, der slaa sig om Svælget for at komme op paa Rygsiden, hvor de tabe sig i et aflangt Ganglion (Hjerne), der er ligesom indsnøret paa Midten, Fig. 29, *c*, og som ligger imellem begge Rygretractorerne, just paa det Sted, hvor disse forene sig. Saavel fra Svælgringen som fra Gangliet udgaa flere Grene, Fig. 29.

Centralnervestrængen og dens Grene ere omgivne af en Bindeævsskede, der danner det egentlige Neurilem.

Paa hver Side af Nervestrængen iagttages et Muskelbaand, der er omtrent ligesaa bredt, som selve Nervestammen; det strækker sig fra Svælgringen op til Nervestrængens bagerste Ende og er fast forenet til den udvendige Sideflade af Neurilemmet. Dette Muskelbaand bestaar af stærke Muskelfibre, hvoraf enkelte strække sig ud over den Del af Sidegrenene, der ligger frit i Kropshulheden, men forsvinde efterhaanden som Grenene gaa ind i Muskellagene eller tabe sig i Huden.

Dr. Théel¹ har iagttaget og beskrevet lignende Muskelbaand hos *Phascolosoma Strombi*.

Intet Spor til Kjønorganer har været at opdage.

Farven.

Selve Kroppen olivengrøn, mørkere paa den forreste og bagerste Del. Snabelen noget lysere; dens forreste

¹ Hjalmar Théel. Recherches sur le *Phascolion Strombi*. Kongl. Svenska Vetenskaps-Akademiens Handlingar, B. 24, No. 2.

the right, is seen a long, tubular, translucent body (the contractile vessel), protending a short distance back on the intestine, where it terminates in a cæcum, cucurbit-like in form, fig. 27, *g*; anteriorly, it passes forwards to the extremity of the proboscis, forming there the vascular ring, which accompanies the tentacular collar in all its windings, and sends off branches to the tentacles.

Number of retractors 4; two of them, the ventral retractors, which are exceedingly long, take their origin, with 3 roots, on the anterior portion of the posterior third of the perivisceral cavity, fig. 27, *l*, whereas the dorsal retractors originate on the anterior portion of the medial third of the perivisceral cavity, fig. 27, *h*. Immediately posterior to the anterior extremity of the œsophagus, the 4 retractors unite, and form, as it were, a sheath for that organ, being as usual attached to the margin of the oral disk.

Two segmental organs, fig. 27, *i*, exceedingly small, about 6^{mm} long and 2^{mm} broad at the point of attachment. A little posterior to the latter, and on the side facing the wall of the body, occurs a small, ovate, funnel-shaped aperture, fig. 28, *a*, leading down into the cavity.

The central nervous chord, which is comparatively thick, extends along the middle of the ventral surface, between the two ventral retractors, figs. 27, *k*; 29, *a*. Throughout its entire course it sends off numerous subsidiary branches, which, as a rule, issue alternately, and coalesce with the skin. Immediately posterior to the buccal aperture, it divides into two branches, fig. 29, *b*, *b*, which, winding round the gullet, reach up to the dorsal surface, and are there lost in an oval-shaped ganglion (brain), — constricted, as it were, in the middle, fig. 29, *c*, — lying between the two dorsal retractors, in the exact spot where they unite. Both from the pharyngeal ring and from the ganglion, proceed several branches, fig. 29.

The central nervous chord and its branches are invaginated in a sheath of connective tissue, which constitutes the true neurilem.

On either side of the nervous chord is observed a muscular band, about equal in breadth to the nervous trunk itself, extending from the pharyngeal ring to the posterior extremity of the nervous chord, and firmly affixed to the exterior lateral surface of the neurilem. These muscular bands consist of strong muscular fibres, some of which protend beyond the portion of the subsidiary branches lying free in the perivisceral cavity, but are gradually lost, as the branches pass into the muscular layers, or coalesce with the skin.

Dr. Théel¹ has observed and described similar muscular bands in *Phascolosoma Strombi*.

Of generative organs no trace could be detected.

Colour.

Trunk olive-green, both extremities of a darker shade. Proboscis somewhat lighter; its anterior extremity, for

¹ Hjalmar Théel. Recherches sur le *Phascolion Strombi*. Kongl. Svenska Vetenskaps-Akademiens Handlingar, B. 24, No. 2.

Ende fra Mundskiven og i en Strækning af omtrent 5^{mm} bagover smuk rosenrød, hvorefter følger et bredt mørkt brunliggrønt Belte. Mundskiven bleg, næsten hvid, med 10 røde Striber, der gaa fra Mundaabningen imod Tentakelbundterne. Tentakler rosenrøde, som Halsen.

Findested.

Et helt Exemplar og mange større og mindre Stumper paa Station 223. Et næsten helt Exemplar paa Station 267.

Slægtskarakter.

Mundskiven meget bred med 10 store Tentakelgrupper, mellem hvilke sidde enkelte Tentakler. Analaabningen strax bagenfor Snabelens Grund.

Artskarakter.

Legemet cylindrisk. Snabelen omtrent lige saa lang som Kroppen. Huden fast, læderagtig. Analaabningen paa en fremragende Papille. Tentaklerne sidde i 10 Grupper, 16 i hver Gruppe, og imellem hver to Grupper sidde et Par Tentakler, ialt 180. 4 Retractorer. Tarmen danner en Spiral. Spindelmuskel. Farven paa Kroppen olivengrøn, Snabelen lysere med en rosenrød Hals. Mundskiven næsten hvid med 10 røde Striber. Tentaklerne rosenrøde.

Fam. **Priapulidæ**, Baird.

Priapuloides typicus, Kor. & Dan.

Tab. III.

Fauna littoralis Norvegiæ. 3 Hefte, p. 147, Tab. XVI.

Priapulus bicaudatus, Dan.

Forhandlinger ved de skandinaviske Naturforskernes Møde, Christiania 1868, pag. 542.

Idet vi henvise til vor Beskrivelse af *Pr. typicus* i 3die Hefte af "Fauna littoralis Norvegiæ," skulle vi her meddele Resultaterne af vore yderligere Undersøgelser, som et paa Nordhavsexpeditionen indsamlet Materiale har sat os istand til at anstille.

Huden dannes af en halv gjennemsigtig, temmelig tyk, hvidgul Cuticula, der paa den udvendige Fladé er tæt besat med Chitinpapiller, Fig. 3, *a*. Indenfor dette Chitin-pantser er et smalt Epithellag, Fig. 3, *b*, som bestaar af korte, i en Række liggende Cylinderceller, der hvile paa et fibrillært Bindevævs-lag, Fig. 3, *c*. Dette er især bredt hvor det omgiver Centralnervestrængen, altsaa paa Midt-

about 5^{mm}, measuring backwards from the oral disk, a bright rosy-red, after which comes a broad belt of dark brownish-green. Oral disk pallid, almost white, with a series of 10 red stripes, stretching from the buccal aperture towards the tentacular fasciculi. Tentacles and throat rosy.

Locality.

A perfect specimen, and numerous fragments, varying in size, at Station 223. An almost perfect specimen at Station 267.

Generic Character.

Oral disk exceedingly broad, bearing 10 large tentacular groups, dispersed between which are a few isolated tentacles. Anal opening immediately posterior to the base of the proboscis.

Specific Character.

Body cylindrical. Proboscis and trunk about equal in length. Skin firm, coriaceous. Anal opening on a prominent papilla. Tentacles arranged in 10 groups, or fascicles, 16 in each group, and between every two groups a couple of isolated tentacles: total number accordingly 180. Retractors 4. The intestine forming a spiral. Fusiform muscle present. Colour of trunk olive-green; proboscis lighter; throat rosy-red. Oral disk almost white, traversed by 10 red-coloured stripes. Tentacles rosy.

Fam. **Priapulidæ**, Baird.

Priapuloides typicus, Kor. & Dan.

Pl. III.

Fauna littoralis Norvegiæ. Part III, p. 147, Pl. XVI.

Priapulus bicaudatus, Dan.

Forhandlinger ved de skandinaviske Naturforskernes Møde, Christiania, 1868, p. 542.

Referring to our description of *Pr. typicus* in Part III of "Fauna littoralis Norvegiæ," we will here record the results of further investigation, which additional materials, collected on the North-Atlantic Expedition, have enabled us to institute.

The skin consists of a semi-translucent, comparatively thick, whitish-yellow cuticle, densely studded over its outer surface with chitinous papillæ, fig. 3, *a*. Underneath this chitinous armature, extends a narrow epithelial layer, fig. 3, *b*, consisting of short cylindrical cells, arranged in a row, on a fibrillous layer of connective tissue, fig. 3, *c*. This layer is broadest where it envelops the central ner-

partiet af Bugfladen; men er paa den øvrige Del af Kroppen betydelig smalere.

Fra den ydre Flade af Bindevævslaget paa Glans udgaa Chitinpigge, Fig. 4, 5, der ere cylindriske, hule med en noget bredere Grunddel, Fig. 4, *a*, 5, *a*, og en lidt krumbøiet, smalere tilspidset fri Ende, Fig. 4, *b*, 5, *b*, forsynet med en fin rund Aabning. Indvendig ere de beklædte med Epithel, Fig. 4, *c*, 5, *c*, der forlænger sig op imod Spidsen, og udvendig ere de forsynede med en Skede, Fig. 4, *d*, 5, *d*, som er Fortsættelsen af Cuticula, der her er uden Chitinpapiller.

Ved Grunden af enhver Pig, og omfattet af denne, sees en næsten rund, temmelig stor Kjertel, Fig. 4, *e*, 5, *e*, der bestaar af en Bindevævsmembran, indvendig beklædt med runde Celler, Fig. 4, *f*, 5, *f*, og fra hvis hvælvede Del udgaa Udførselsgangen, Fig. 4, *g*, der løber op igennem Piggens Hulhed, Fig. 4, *h*, 5, *g*, og munder ud just der, hvor dennes Epithelbeklædning ophører, Fig. 4, *i*, 5, *h*. Kjertelens Indhold var en seig, kornet, vandklar Masse, som vi et Par Gange saa i Piggens Aabning.

Paa den indvendige Flade af Piggens Skede, ved dennes Grund, insererer sig mange Muskelfibre, Fig. 4, *k*, 5, *i*, der have en skraa Retning nedefra opad, indenfra udad, og som ere Grene af Ringmusklerne, Fig. 4, *l*.

Umiddelbart til Bindevævslagets indre Flade støder Muskellaget, der dannes af Ring- og Længdemuskler.

Ringmusklerne, Fig. 3, *d*, ere distinkt adskilte fra hverandre, staa tættere sammen i Glans, end paa den øvrige Kroppsdel, og ligge nærmest Corium.

Længdemusklerne, Fig. 2, *a*, ligge indenfor Ringmusklerne, ere stærkere end disse og udgjøre 25 i Glans; men dele sig i to paa det Sted, hvor denne gaar over i Kroppen, saaledes at denne Del af Legemet bliver forsynet med 50.

I ethvert af de haleformige Appendices derimod er der kun 14 Længdemuskler, Fig. 2, *b*, der ere Fortsættelser fra enkelte af Kroppens saaledes, at i Regelen hver 3die eller 4de Længdemuskel afgiver en til Appendicet.

Saa vel Ring- som Længdemusklerne ere omgivne af en temmelig fast Bindevævsskede, hvori spindelformige Bindevævslegemer ere leirede. Enhver af disse Muskler er sammensat af mange Bundter, 12—20, Fig. 3, *f*, der hver for sig er omgivet af en egen tynd Bindevævsmembran, Fig. 3, *g*, ligesom der imellem Bundterne er et med Kjerner forsynet Bindevæv, som egentlig er en Fortsættelse af den fælles Skede. I enhver Bundt er der en Mængde Fibriller, som ere stribede paa skraa, hvorved de faa et ganske eiendommeligt Udseende, naar de ere overskaarne, Fig. 3, *h*.

Paa store Exemplarer med udspændt Hud er denne gittret og ligner Sipunculushuden. Den indvendige Flade af Kroppshulheden beklædes af et flimrende Peritoneum, der væsentlig bestaar af Bindevæv, hvori sees enkeltløbende Muskelfibre.

vous chord, accordingly in the middle of the ventral surface; elsewhere on the body it is much narrower.

From the outer surface of the layer of connective tissue on the glans (proboscis), spring a number of chitinous spikes, figs. 4, 5, cylindrical in form, hollow, broadest at base, figs. 4, *a*; 5, *a*, and with a slightly curved, acuminate free extremity, figs. 4, *b*; 5, *b*, in which is seen a minute circular opening. Internally, these spikes are invested with epithelium, figs. 4, *c*; 5, *c*, produced towards the point; externally, they are furnished with a sheath, figs. 4, *d*; 5, *d*, the continuation of the cuticle, which is destitute here of chitinous papillæ.

In the hollow of every spike, at the base, is seen an almost round, comparatively large gland, figs. 4, *e*; 5, *e*, composed of connective tissue, covered internally with round cells, figs. 4, *f*; 5, *f*; and from the arcuate portion of these issues the excretory canal, fig. 4, *g*, which, passing up through the hollow of the spike, figs. 4, *h*; 5, *g*, disembogues exactly where the epithelial integument of the latter terminates, figs. 4, *i*; 5, *h*. The gland contained a viscid, granulous, pellucid substance, which we observed once or twice in the aperture at the free extremity of the spikes.

On the inner surface of the sheath, at its base, are inserted numerous muscular fibres, figs. 4, *k*; 5, *i*, protending obliquely — upwards from below, outwards from within; they are branches of the annular muscles, fig. 4, *l*.

Contiguous to the inner surface of the connective membrane, extends the muscular layer, composed of annular and longitudinal muscles.

The annular muscles, fig. 3, *d*, are distinctly separate, each from each, more closely arranged in the glans than elsewhere throughout the trunk, and adjoin the corium.

The longitudinal muscles, fig. 2, *a*, lying underneath the annular muscles, are stronger than the latter. They number 25 in the glans, dividing dichotomously where that organ meets the trunk, which is furnished therefore with 50.

Each of the caudiform appendages has only 14 longitudinal muscles, fig. 2, *b*, continuations of those in the trunk, every 3rd or 4th of which is as a rule produced to an appendix.

Both the annular and the longitudinal muscles are invested with a sheath of comparatively firm connective tissue, throughout which are dispersed fusiform corpuscles of connective tissue, fig. 3, *a*. These muscles are all of them built up of numerous fascicles, from 12 to 20, fig. 3, *f*, each enveloped in a separate covering of thin connective tissue, fig. 3, *g*; and in between the fascicles extends, too, a layer of nucleal connective tissue, which, in a strict sense, is a continuation of the common sheath. In each fascicle are numbers of fibrils, transversely striate, which gives them, on being cut through, a most characteristic appearance, fig. 3, *h*.

In large examples, the skin, when distended, is tessellated, and resembles the skin in *Sipunculus*. The inner surface of the perivisceral cavity is invested with a ciliated peritoneum, consisting chiefly of connective tissue, in which protend isolated muscular fibres.

I vor Beskrivelse over *Priapuloides typicus* ("Fauna littoralis. Norvegiæ") omtalte vi, at der i Mundhulheden var 8 Rækker Tænder; dette maa vi nu berigtige.

Hele Mundhulheden er besat med Tænder, Fig. 2, *c*, der staa i ringformige Rækker i hele den forreste Del, imedens Rækkerne i den bagerste Del antage en mere skraa Retning.

I den første Række er der 5 store Tænder, som staa temmelig langt fra hverandre; men imellem hver 2 af disse findes paa fuldt udvoxede Individuer to mindre Tænder, der paa det af os i "Fauna littoralis Norvegiæ" beskrevne Exemplar ikke vare fremkomne.

Bagenfor den 10de Række blive Tænderne saa smaa, at de ikke kunne sees med blotte Øine, og jo mere de nærme sig Indgangen til Spiserøret, jo mindre blive de, ligesom de antage en simplere Form. Disse Tænder, Fig. 6, 7, ere pyramideformede, have en bred, næsten firkantet Basaldel, Fig. 6, *a*, ere lidt krumboiede og løbe ud i en noget bøiet Spids, Fig. 6, *b*, 7, der vender indad og lidt nedad mod Mundhulheden. Den Del af Tænderne, der vender imod Hulhedens Væg, er næsten flad. Disse Tænder udgjøre altsaa den tredje Form, der af os tidligere var overseet.

Samtlige Tænder ere hule og beklædte med et lidt forskjelligt formet Cylinderepithel. I de store Tænder, der indtage Mundhulens forreste Del, Fig. 8, bestaar Epithelet af Cylinderceller, som have en lidt langstrakt Form; men i de smaa enkle Tænder, som vi ovenfor have beskrevet, ere Cylindercellerne overmaade lange, Fig. 7, *a*, og ligne meget de Celler, der udgjør Epithelbeklædningen paa Tarmens Tverfolder, Fig. 10, og som senere skulle omtales.

Ligesom Tænderne egentlig ere Fortsættelser og Omdannelser af det almindelige Chitinovertræk, saaledes er deres indre Epithelialbeklædning en Fortsættelse af Hudens eller Tarmens Epitheliallag. Selve Tandspidsen er aldrig hul; men altid kompakt og fast, Fig. 7, *b*.

Svælg hovedet, Fig. 9, har paa den ydre aflange Flade en hel Del Muskler, der ligge i 2 Lag.

Det ydre Lag bestaar af 8 temmelig brede, 8—10^{mm} lange Muskler, Fig. 9, *a*, som tage deres Udspring paa Svælg hovedets bagerste Del med en lidt bredere Basis, og som fæste sig omkring Mundaabningen, indenfor Retractorerne.

Det indre Lag er sammensat af flere, men noget smalere Muskler, Fig. 9, *b*, der have samme Udspring og Fæstepunkt som det ydre Lags Muskler. Disse Muskler tjene sikkerlig til at presse Mundhulheden sammen og forkorte den. Bagenfor disse Musklers Udspring, hvor Svælg hovedet gaar over i Spiserøret, har dette paa dets ydre Flade en stærk Indsnøring, Fig. 9, *c*; denne er omgivet af en Mængde Muskler, der fæste sig strax bagenfor de nysbeskrevne Svælgmuskler; men forene sig noget bagtil til en næsten tendinøs Membran, Fig. 9, *e*, som insererer sig paa en Vold, der omgiver Spiserørets ydre Flade, Fig. 9, *f*.

In our description of *Priapuloides typicus* ("Fauna littoralis Norvegiæ"), the cavity of the mouth is stated to have 8 rows of teeth. This was an error, which we must now rectify.

The whole cavity of the mouth is dentiferous, fig. 2, *c*. Anteriorly, the teeth are disposed in annular series; posteriorly, in series somewhat oblique.

The first row consists of 5 large teeth, rather far apart; but in the space between, full-grown individuals have two smaller ones, 8 in all, which had not developed in the specimen described in "Fauna littoralis Norvegiæ."

Posterior to the 10th series, the teeth are so minute as to be invisible to the naked eye, and the nearer they approach the entrance to the œsophagus, the more minute do they become, assuming at the same time a simpler form. These teeth, figs. 6; 7, are pyramidic, having a broad and almost quadrangular base, fig. 6, *a*, somewhat arcuate and slightly bent at the point, figs. 6, *b*; 7, which is turned inwards, and a little downwards, towards the cavity of the mouth. The part of the teeth that faces the wall of the cavity is very nearly flat. These teeth constitute accordingly the third form, overlooked in our previous description.

The teeth are all hollow, and invested with cylindric epithelium, varying in form. On the large teeth, occupying the anterior portion of the cavity of the mouth, fig. 8, the epithelium consists of cylindric cells, somewhat elongate in form; but on the minute, simple teeth, described above, the cylindric cells are exceedingly large, fig. 7, *a*, and bear considerable resemblance to the cells of the epithelial integument on the transverse folds of the intestine, fig. 10, to be described in due course.

Precisely as the teeth, in a strict sense, are transformed continuations of the common chitinous integument, so too is the inner epithelial tunic simply a continuation of the skin, or of the epithelial layer of the intestine. The points of the teeth are never hollow, but invariably firm and compact, fig. 7, *b*.

The gullet, fig. 9, is furnished on its exterior oblong surface with numerous muscles, arranged in 2 layers.

The outer layer consists of 8, comparatively broad muscles, 8—10^{mm} in length, fig. 9, *a*, which have their origin on the gullet, with a somewhat broader base, and are attached round the buccal aperture, underneath the retractors.

The inner layer is built up of several muscles, a trifle narrower, fig. 9, *b*, having the same point of origin and attachment as those of the outer layer. These muscles must assuredly serve to close up and shorten the cavity of the mouth. Posterior to the origin of these muscles, where the gullet opens into the œsophagus, is seen, on the outer surface of the latter, a deep constriction, fig. 9, *c*, surrounded by numbers of muscles, which are attached immediately posterior to the pharyngeal muscles just described; they unite however a little farther back, forming an almost tendinous membrane, fig. 9, *e*, which is inserted

Imellem denne Muskelmembran og selve Spiserøret opstaa saaledes et Rum, Fig. 9, *g*, der udfyldes af Kropsvædsken. Dette Muskelapparat, som ogsaa findes hos *Priapulus caudatus*, men i en noget forandret Form, tjener til at holde Indsnøringen paa Spiserøret og den paa dettes indre Flade derved fremkomne Fold i Situs.

Men foruden det nævnte Muskelapparat findes endnu et andet og mere særegent, der er endnu mærkeligere, og som ikke *Pr. caudatus* har. Strax bagenfor den Vold, hvorpaa den førnævnte Muskelmembran fæster sig, sees en kredsformig Række af Muskler, Fig. 9, *h*, der omgive Spiserøret, som just her atter har en Indsnøring; men meget mindre end hin. Disse Muskler ere egentlig Grene af Tarmens Længdemuskler, hvilke her optræde selvstændigt, idet de danne egne isolerede Muskler, som fæste sig paa den oftere omtalte Vold, Fig. 9, *f*, og tjene til at dirigere den anden mindre Fold paa Spiserørets indre Flade. Og, saa her er et Rum imellem denne Søilekreds af Muskler og Spiserørets ydre Flade, der beskylles af Kropsvædsken.

Hvor Mundhulheden gaar over i Spiserøret er der paa den indre Flade en stærkt fremragende, kredsformig Fold, Fig. 2, *d*, der er tæt besat med de smaa ovenfor beskrevne Tænder; strax bagenfor denne Fold er atter en anden lignende, der dog ikke er saa fremtrædende, som hin, og er uden Tandbeklædning. Imellem disse Folder er en Fordybning, hvor Spiserøret egentlig tager sin Begyndelse. Tandvævningen ophører med den første Fold.

Spiserøret er temmelig kort, og paa den indre Flade forsynet med stærke Længdefolder, Fig. 2, *e*, som ligger tæt ved Siden af hverandre og sende tildels ligesom Broer over fra den ene til den anden; det udvider sig noget, idet det gaar over i Tarmen, Fig. 2, *f*, som er temmelig vid med meget tykke Vægge, og paa hvis indre Flade findes tæt i hverandre staaende Tværfolder, der rage noget ind i Lumenet, Fig. 2, *g*. Mod den bagerste Ende bliver Tarmen smal og ender i en kort Rectum, Fig. 2, *h*, med sin runde Analaabning, der er forsynet med en meget stærk Sphincter.

Langs Tarmens udvendige Flade, saavel paa Rygsom Bugsiden, løber en Muskelstræng fra Anus fortil og fæster sig paa Svælg hovedet; den er bundet til Tarmen ved et yderst smalt Mesenterium, der dannes væsentligst af Bindevæv, og hvori sees enkelte Muskelfibre.

Den histologiske Bygning af Fordøielseskanalen er følgende: Svælg hovedets Vægge kunne betragtes som en Indkrængning af Kropshuden. Den indre Flade er en temmelig tyk Chitinhud forsynet med Tænder, Fig. 8, *a*, udenfor den er Epithellaget, der bestaar af temmelig korte Cylinderceller, Fig. 8, *b*, lig dem der danne Hudens Subcuticularlag. Epithelet er bundet til et temmelig tykt, fibrillært Bindevævslag, der støder umiddelbart til Muskelhuden, som bestaar af Længde- og Ringmuskler, hvilke ere

into a ridge surrounding the outer surface of the œsophagus, fig. 9, *f*. Between this muscular membrane and the œsophagus, there extends accordingly a space, fig. 9, *g*, which is filled up by the perivisceral fluid. This muscular apparatus, with which *Priapulus caudatus* is also furnished, but in a somewhat different form, serves to keep *in situ* alike the indistincture of the œsophagus and the fold it occasions on the inner surface of the latter.

But, exclusive of this apparatus, there is another, much more remarkable and characteristic, not met with in *Pr. caudatus*. Immediately behind the ridge to which the aforesaid muscular membrane is attached, occurs a circular series of muscles, fig. 9, *h*, surrounding the œsophagus, which at this point exhibits another indistincture, much less deep however than that previously described. These muscles are strictly branches, proceeding from the longitudinal muscles of the intestine, which occur here as isolated independent muscles, affixed to the aforesaid ridge; fig. 9, *f*, and serve to govern the smaller fold on the inner surface of the œsophagus. Here, too, a space intervenes between the columnar circle of muscles and the outer surface of the œsophagus, which is washed by the perivisceral fluid.

Where the cavity of the mouth opens into the œsophagus, is seen, on the inner surface, an exceedingly prominent circular fold, fig. 2, *d*, densely studded with the minute teeth described above; immediately posterior to this fold, occurs another, but less prominent, and not dentiferous. Extending between these folds is a depression, in which the œsophagus strictly originates. The dentition terminates with the first fold.

The œsophagus is comparatively short, and furnished on its inner surface with longitudinal folds, fig. 2, *e*, protending side by side, with bridges, as it were, thrown across in places from one to the other; it slightly expands as it enters the intestine, fig. 2, *f*, which is comparatively wide, with exceedingly thick walls, and has on the inner surface a number of closely arranged transverse folds, jutting out a little into the lumen, fig. 2, *g*. Near its posterior extremity, the intestine narrows, terminating in a short rectum, fig. 2, *h*, with a round anal aperture, which is furnished with an exceedingly powerful sphincter.

Along the outer surface of the intestine, alike on the dorsal and on the ventral side, a muscular chord protends anteriorly from the anus, and is attached to the gullet; it is webbed to the intestine by an exceedingly narrow mesentery, composed chiefly of connective tissue, and in which are seen a few muscular fibres.

The histological structure of the alimentary canal is as follows: — The walls of the gullet may be regarded as an invagination of the skin of the body. A thickish chitinous membrane, furnished with teeth, fig. 8, *a*, forms the inner surface; above it, extends the epithelial layer, consisting of comparatively short cylindric cells, fig. 8, *b*, similar to those which constitute the subcuticular layer of the skin. The epithelium is webbed to a thickish layer of fibrillous connective tissue, directly adjoining the

meget stærke. Udenpaa Ringmuskellaget er Peritonealbeklædningen bunden ved Bindevæv.

Spiserørets og Tarmens Vægge ere noget forskellige fra Svælgets. Epithellaget, der beklæder den indre Flade, er temmelig bredt og dannes af meget lange Cylinderceller, hvis bredere Del vender mod Tarmhulheden. Mangfoldige af disse Cylinderceller vare fyldte med en finkornet, gulagtig Protoplasmamasse, og adskilte sig fra de andre, der vare ganske vandklare og havde et mere grovkornet Indhold. Om disse gulagtige Cylinderceller fungere som Kjertler, der afsondrede den store Mængde Slim, som sammenskittete Tarmindholdet, skulle vi ikke afgjøre med nogen Bestemthed, ihvortvel det forekommer os sandsynligt. Dette Slim var altid i størst Mængde tilstede i den egentlige Tarm, hvor den paa enkelte Exemplarer dannede ligesom et membranøst Overtræk, der formentlig var dannet af det i Alcohol coagulerede Slim.

I det omtalte membranøse Overtræk saaes en stor Mængde yderst fine, lange Folder, der havde en saa skuffende Lighed med lange Haar eller Cilier, at vi i Begyndelsen antog dem derfor, en Antagelse, der tilsyneladende var begrundet i den Omstændighed, at Prof. Ehlers i sit Arbejde over Slægten *Priapulus*¹ beskriver netop en Chitinhud paa Tarmfladen, hvorfra mange fine, stive Haar udgaa.

Epithellaget, der paa sin indre Flade synes at være forsynet med Cilier, er fæstet til et stærkt Bindevævslag, Fig. 10, *b*, der sender listeformige Forlængelser ind i Epithellet og danner derved de paa den indre Væg af saavel Spiserøret som Tarmen fremragende Folder, Fig. 10, *c*. Disse Bindevævslister ere rigere paa Bindevævslegemer, end det øvrige Bindevæv. Udenpaa Bindevævet er nu Muskelhuden med sine to bestemte Lag, nemlig Længde- og Ringmuskler, hvilke sidste ere bundne til Peritonealovertrækket ved et smalt Bindevævslag.

Centralnervestrængen løber langs Midten af Bugfladen, Fig. 1, *a*, ikke som hos *Gephyreerne* ialmindelighed paa dennes indre Flade; men i Hudens Bindevæv, imellem Muskel- og Epithellaget, Fig. 3, *k*. Hvor Nervestammen ligger, er det fibrillære Bindevæv stærkt udvidet og omgiver den paa en beskyttende Maade, Fig. 3, *c*.

Centralnervestrængen er indesluttet i en tyk Bindevævsskede, Fig. 3, *l*, der sender en Forlængelse fra den ene Væg til den anden, tværs igjennem Nervestammen, Fig. 3, *m*. Denne bliver derved delt i to Dele, hvoraf den indre er bredest, Fig. 3, *n*, og har en lidt mørkere Farve. Saavel fra denne Skillevæg, som fra Skedens indre Flade

muscular integument, which consists of longitudinal and annular muscles, exceedingly strong. The peritoneal tunic is webbed on to the layer of annular muscles by connective tissue.

The walls of the œsophagus and the intestine differ slightly from those of the gullet. The epithelial layer investing the inner surface is comparatively broad, and consists of exceedingly long cylindric cells, with the broader portion facing the intestinal cavity. Many of these cylindric cells were full of a finely granulous, yellowish protoplasmatic mass, and differed from the others, which were perfectly hyaline, and contained a more coarsely granulous substance. Whether these yellowish cylindric cells serve the purpose of glands, whose function is to secrete the abundant supply of mucus that glues together the contents of the intestine, we shall not venture to decide, though such, we conceive, is highly probable. Most of this mucus was met with in the intestine itself, where, in some of the specimens, it actually formed a kind of membranous tunic, the mucus having probably been coagulated by the action of the alcohol.

In this membranous tunic were seen a great number of long and exceedingly narrow folds, presenting so illusive a resemblance to long capillaments, or cilia, that at first we regarded them as such; and more especially, since Professor Ehlers, in his Memoir on the genus *Priapulus*,¹ describes such a chitinous membrane on the surface of the intestine, from which proceed numerous stiff, slender capillaments.

The epithelial layer, which would appear to be furnished on its inner surface with vibratile cilia, is webbed to a layer of strong connective tissue, fig. 10, *b*, from which cornice-like prolations of connective tissue are produced into the epithelium, thus occasioning the prominent folds, fig. 10, *c*, on the inner wall of both the œsophagus and the intestine. These cornice-like prolations are more abundantly furnished with corpuscles of connective tissue than any other part of the connective membrane. Next above the connective tissue comes the muscular integument, with its two layers of longitudinal and annular muscles, the latter webbed to the peritoneal tunic by a narrow layer of connective tissue.

The central nervous chord protends along the middle of the belly, fig. 1, *a*, not on the inner surface, as in most of the *Gephyrea*, but in the connective tissue of the skin, between the muscular and epithelial layers, fig. 3, *k*. Round the nervous trunk, the fibrillous connective tissue, which invests it with a protective covering, fig. 3, *c*, is greatly distended.

The central nervous chord is enclosed in a thick membranous sheath, fig. 3, *l*, which sends a filament from one wall to the other, piercing the nervous trunk, fig. 3, *m*. Hence the latter is divided into two sections, the inner, of a darker colour, being the broader, fig. 3, *n*. Both from this partition-wall and from the inner surface of the sheath,

¹ E. Ehlers. Ueber die Gattung *Priapulus*. Zeitschrift f. wiss. Zoologie. 11 Band, pag. 205.

Den norske Nordhavsexpedition. Danielssen og Koren: *Gephyrea*.

¹ E. Ehlers. Ueber die Gattung *Priapulus*. Zeitschrift f. wiss. Zoologie. 11 Band, pag. 205.

udgaa Prolongationer af Bindevæv imellem Nervefibrillerne, hvilke ere forsynede med Bindevævslegemer i stor Mængde. Man har her aabenbart et Perineurium svarende til det hos de høiere Dyr.

Nervestrængen er sammensat af Nervefibriller i dens centrale Dele; og i dens Peripheri, altsaa nærmest Skeden, er et celluløst Lag, hvis enkelte Celler vare lidt aflange og forsynede med en Kjerne, uden at det var muligt at iagttagende noget Protoplasmaindhold.

Uagtet Centralnervestrængen ligger særdeles nær Legemets ydre Flade, synes den dog at være godt beskyttet mod ydre Indvirkninger ved det stærke Bindevævslag, som omgiver den, ved den tykke Bindevævsskede og endelig ved dennes mange Prolongationer imellem Fibrillerne.

Fra Centralnervestrængen udgaa mange Grene til Hud og Muskler. Naar den er kommen fortil imod Svælget deler den sig i to Grene, der slaa sig omkring Spiserøret og danne derved Svælgringen, som er indsluttet i en Bindevævsskede.

Kjønnet er adskilt. Æggestokkene ligge en paa hver Side af Endetarmen, ere langstrakte med bladformige Indskjæringer, Fig. 2, *i*, og have en temmelig tyk, fast Udførselsgang, Fig. 2, *k*, der ligger overfladisk paa Rygsiden, tager sin Begyndelse et lidet Stykke bagenfor Æggestokkens frie afrundede Ende, Fig. 2, *l*, og aabner sig udad strax ovenfor Appendicet, Fig. 2, *k*.

Paa hele Bugsidens Midtparti er et stærkt, bredt Mesenterium, der binder Æggestokken til Kropsvæggens indre Flade. Dette Mesenterium strækker sig langt fortil, bliver smalere og ender omtrent der, hvor Kropshulhedens bagerste Trediedel tager sin Begyndelse.

Æggestokken dannes af en stor Mængde aflange, blæreformige Legemer med deres Udførselsgange, der aabne sig i den store Udførselskanal, hvis Lumen er temmelig vidt. Blærerne bestaa af en tynd Bindevævshud, der paa den indre Flade har et kjernerigt Epithel, hvori Æggene udvikle sig, og paa hvis ydre Flade saaes spredte Muskel-fibre, beklædte af Peritoneum.

Udførselsgangene havde et meget stærkere Bindevævslag; Epithellet, som beklæder den indre Flade, bestod af Cylinderceller, og paa Bindevævet ydre Flade var en rigere Mængde Muskelfibre.

I mange af Blærerne vare næsten fuldt udviklede Æg, i andre vare Æg i tidligere Stadier, og i atter andre saaes ingen Æg, men kun Epithelbeklædningen.

Hvad nu Hannens Kjønnsorganer betræffer, saa kunne vi ikke meddele noget Væsentligt derom; thi Testiklerne paa det Exemplar, vi undersøgte, vare temmelig beskadigede; vi bleve dog overbeviste om, at vi havde med en Han at gøre, saasom en Mængde ret vel vedligeholdte Spermatozoer med deres korte Haler iagttoges.

produced filaments of connective tissue pass between the nervous fibrils, which are abundantly furnished with corpuscles of connective tissue. We have here indubitably a true *perineurium*, the analogue of that organ in more highly developed animals.

The centre of the nervous chord consists of nervous fibrils, whereas the peripheral part, or that nearest the sheath, is a cellular layer, the cells composing it being slightly oblong in form, and furnished with a nucleus; we failed however to detect any protoplasmatic contents.

Although the central nervous chord protends in close proximity to the outer surface of the body, it would nevertheless appear to be sufficiently well protected, viz. by the strong layer of connective tissue that surrounds it, by its thick membranous sheath, and by the numerous filaments produced from the latter between the fibrils.

The central nervous chord sends off a great many branches to the skin and the muscles. Anteriorly, a short distance from the gullet, it divides into two branches, which, winding round the œsophagus, form the pharyngeal ring, sheathed in connective tissue.

The sexes separate. The ovaries — one on either side of the rectum — are elongate in form, with petaloid incisions, fig. 2, *i*, and have a firm-textured and comparatively thick eferent duct, fig. 2, *k*, protending close to the surface on the dorsal side; it takes its origin a little posterior to the free rounded extremity of the ovary, fig. 2, *l*, and opens externally, immediately above the appendix, fig. 2, *k*.

The medial portion of the ventral surface is wholly invested with a broad and strong mesentery, which webs the ovaries to the inner surface of the wall of the body. This mesentery, reaching a considerable distance forwards, gradually narrows, and terminates at the commencement of the posterior third of the perivisceral cavity.

The ovary is built up of numbers of elliptical, vesicular corpuscles, each with an eferent duct, opening into the great excretory canal, the lumen of which is comparatively wide. The vesicles consist of thin connective tissue, having its inner surface covered by nucleal epithelium, wherein the ova develop, and on the outer surface of which were seen isolated muscular fibres, invested with a peritoneal tunic.

The eferent ducts had a much stronger layer of connective tissue; the epithelium clothing the inner surface, consisted of cylindrical cells; and on the outer surface of the connective tissue, the number of muscular fibres, too, was greater.

Many of the vesicles contained almost fully mature ova; in some, the egg was in various stages of development; others exhibited no traces whatever of ova, being quite empty: nothing was seen but the epithelial covering.

As regards the generative organs in the male, we have nothing essential to communicate, since the testes in the specimen examined had been much injured; we felt convinced, however, that the individual in question was a male, having observed a considerable number of spermatozoa, with their short caudæ, comparatively perfect.

Professor Ehlers har i det nys citerede Tidsskrift leveret en særdeles god monographisk Bearbejdelse af Slægten *Priapulus*, hvortil *Priapuloides* i mange Henseender slutter sig. Vore histologiske Undersøgelser over begge disse Slægter have i enkelte Punkter ledet til Resultater, der ere noget forskellige fra dem, Ehlers er kommen til over *Priapulus*, og om end Afvigelserne ikke ere meget store, skulle vi dog fremhæve dem.

Ved Huden omtaler Ehlers et subcuticular Lag, der ligger indenfor Chitinlaget, og som efter ham bestaar af et finkornet Lag, hvori ingen Celler tydelig kunde sees, og som ligger imellem Ringmusklerne og Chitinhuden. Vi have fundet constant et temmelig udpræget Epithellag indenfor Chitinhuden, bestaaende af Cylinderceller; dette Epithellag er fæstet til et stærkt Bindevævslag, hvortil Muskelhuden er bunden. Det synes, som om Prof. Ehlers ganske har overseet dette Bindevævslag, hvis ikke han har antaget det finkornede Subcuticularlag derfor.

De paa Snabelens ydre Flade siddende Pigge ere omgivne af en Skede, Fig. 11, *a*, 12, *a*, der er en Forlængelse af Chitinhuden; kun er Skeden kortere hos *Priapulus* end hos *Priapuloides*. Den hule Pig har i Spidsen en Aabning, Fig. 11, *b*, 12, *b*, og er indvendig beklædt med et Epithel, Fig. 11, *c*, Continuation af Hudens Epithellag, ligesom der ved Grunden af Piggen er en Kjertel med sin Udførselsgang, Fig. 11, *d*. Ehlers omtaler hverken Skeden eller Kjertelen, ei heller Aabningen i Piggens Ende, hvorigjennem Kjertelsekretet udføres.

Cuticula (Chitinlaget) er hos *Priapuloides* tæt besat med koniske Chitinpapiller, imedens den hos *Priapulus* er glat.

Folderne paa Tarmrørets indre Flade dannes af frempringende Bindevævslister, hvortil Epithelet er fæstet. Dette bestaar af meget lange Cylinderceller, der sandsynligvis ere forsynede med Cilier. Imellem Cylindercellerne saaes særegne Celler, som vi have antaget for Slimkjertler. Ehlers angiver, at den indre Flade af Tarmen paa *Priapulus* har et Chitinovertræk, der efter ham skal være en Fortsættelse af den ydre Huds Chitinlag, og at dette Chitinovertræk ikke alene danner Tarmfolderne; men at det i den midterste Tarmdel er forsynet med lange, stive Chitinhaar.

Vi have tidligere angivet, at vi paa Tarmens indre Flade af et Exemplar af *Priapuloides*, ligesom vi ogsaa paa et Exemplar af *Priapulus* saa noget, der kunde antages for en tynd Chitinhud med de nævnte Haar; men det viste sig ved nærmere Undersøgelse at være et Overtræk dannet af coaguleret Slim. De Cilier, vi have iagttaget paa Tarmepithelet, vare indenfor den omtalte og af Ehlers antagne Chitinhud, hvilket end mere bestyrker os i, at denne ikke kan være andet end en Tilfældighed.

Professor Ehlers has lately furnished, in the Journal cited above, a most excellent monographic review of the genus *Priapulus*, with which *Priapuloides* in many respects is found to congrue. Our histological investigation of both genera has been attended with results deviating slightly in certain points from those of Ehlers for *Priapulus*; and though the difference is not considerable, it will be well to point out wherein the observations that have led to it diverge.

Professor Ehlers describes a subcuticular layer in the skin, underlying the chitinous layer, and which consists of a finely granulous stratum — in which no cells could be readily distinguished — extending between the annular muscles and the chitinous cuticle. We have found, as a constant feature, underneath the chitinous integument a comparatively well developed epithelial layer, consisting of cylindrical cells; this epithelial layer is attached to a layer of strong connective tissue, webbed to the muscular integument. Professor Ehlers would appear to have overlooked altogether this layer of connective tissue, unless indeed it is this which he terms the finely granulous subcuticular layer.

The spikes on the outer surface of the proboscis are enclosed in a sheath, figs. 11, *a*; 12, *a*, — the chitinous integument produced; but the sheath is shorter in *Priapulus* than in *Priapuloides*. The hollow spikes have each an aperture at the point, figs. 11, *b*; 12, *b*, and are invested on the inner surface with epithelium, fig. 11, *c*, — a continuation of the epithelial layer of the skin; and moreover, there is at the base of every spike a gland, furnished with an excretory duct, fig. 11, *d*. Ehlers mentions neither the sheath, the gland, nor the aperture at the pointed extremity of the spike through which exudes the glandulous secretion.

The cuticle (chitinous layer) in *Priapuloides* is densely studded with conical chitinous papillæ, whereas it is smooth in *Priapulus*.

The folds on the inner surface of the intestinal canal consist of prominent membranous fillets, attached to the epithelium. The latter consists of exceedingly large cylindrical cells, furnished probably with vibratile cilia. Between the cylindrical cells were seen other cells, possibly mucous glands. According to Ehlers, the inner surface of the intestine in *Priapulus* is invested with a chitinous tunic, a continuation, as he conceives, of the chitinous layer in the outer integument; and in his opinion, this chitinous tunic not only produces the folds of the intestine, but is furnished on the medial portion of the latter with long, bristly chitinous capillaments.

We have previously stated, that we, too, detected on the inner surface of the intestine in a specimen of *Priapuloides*, and also in a specimen of *Priapulus*, what might be taken for a thin chitinous skin, bearing such capillaments; but, on closer examination, it proved to be coagulated mucus. The cilia we have observed on the intestinal epithelium, occurred underneath Ehlers' supposed chitinous integument, a circumstance affording additional proof of the feature in question being strictly casual.

Det er heller ikke godt at forstaa, hvorledes Fordøielsen og Ernæringen skulde kunne foregaa med Lethed, naar hele Tarmens indre Flade var overtrukket med en Chitinhud, der jo under almindelige Forhold er uigjennemtrængelig for Vædske, medmindre den var forsynet med en Mangfoldighed af Porer, og noget saadant omtaler ikke Prof. Ehlers. Vore Undersøgelser have overbevist os om, at Chitinovertrukket ophører ved Spiserørets Begyndelse.

Saa vel hos *Priapuloides* som hos *Priapulus* have Muskelfibrillerne en skraa Stribning.

Professor Ehlers er den første, der har paavist Nervesystemet hos *Priapulus*, og vi have ved vore Iagttagelser saavel over denne Slægt som over *Priapuloides* ikke alene stadfæstet hans Observationer, men ogsaa i histologisk Henseende fuldstændiggjort dem.

Fam. **Bonellidæ**, Baird.

Hamingia¹ *arctica*, n. g. n. sp.

Tab. IV, V.

Lacaze-Duthiers omfatter kun 2 Slægter henhørende til denne Familie, nemlig *Bonellia*, Rolando, og *Thalassema*, Cuvier. Den af os nu opstillede 3die Slægt, *Hamingia*, have vi troet at maatte henføre til nævnte Familie, omendskjøndt den mangler baade Snabel og Børster, der jo ere angivne som Mærker for Familien. Men som vi senere skulle paavise, nærmer *Hamingia* sig i sin Organisation ikke alene til *Thalassema*, men i væsentlig Grad ogsaa til *Bonellia*, saa at vi ikke have kunnet opgive Familieforholdet til disse, trods de nævnte Mangler.

Bonellia viridis, der først er beskrevet af Rolando, tiltrak sig snart Zoologernes Opmærksomhed ved sine Besynderligheder baade i Form og Organisation; men desuagtet hengik omtrent et halvt hundrede Aar, inden dette mærkelige Dyrs Organisation blev fuldstændig opklaret. Aarsagen laa hovedsagelig i Vanskeligheden ved at erholde Dyret levende og i tilstrækkelig Mængde, omendskjønt det var temmelig almindeligt endog paa ringe Dybde i Middelhavet og paa de korsikanske Kyster.

Her i Norden er en af os (Koren), den første, der for omtrent 40 Aar siden fandt *Bonellia viridis* ved Bergen paa en Dybde af 50 Favne, og han paabegyndte dengang en anatomisk Undersøgelse af den, hvilken han af Mangel paa fornødent Materiale maatte opgive; thi *Bonellia viridis* er i det Hele taget sjelden ved de norske Kyster,

¹ Hamingja, Lykkegudinde i den nordiske Mythologie.

Indeed, it is hard to conceive how the animal could digest and assimilate its food with facility, were the whole of the inner surface of the intestine invested with a chitinous skin, impermeable as is the latter, under ordinary conditions, to all fluid substances, unless abundantly furnished with pores, of which no mention is made by Prof. Ehlers. Our examination of the new specimens has fully convinced us, that the chitinous tunic terminates at the origin of the œsophagus.

The muscular fibrils both in *Priapuloides* and *Priapulus* are obliquely striate.

Professor Ehlers was the first to show the existence of a nervous system in *Priapulus*; and our investigation alike of this genus and of *Priapuloides* bears out and, histologically, completes his observations.

Fam. **Bonellidæ**, Baird.

Hamingia¹ *arctica*, n. g. n. sp.

Pl. IV, V.

According to Lacaze-Duthiers, 2 genera only are comprised in the family *Bonellidæ*, viz. *Bonellia*, Rolando, and *Thalassema*, Cuvier. The animal representing the new genus established here, we have seen fit to class under this family, though wanting in two important characters assigned to the latter: bristles and a proboscis. *Hamingia*, however, as will afterwards appear, not only resembles *Thalassema* in its general organisation, but *Bonellia* too, and closely; wherefore we could not but regard the animal as a nearly related congener, in spite of defective characteristics.

Bonellia viridis, first described by Rolando, soon drew the attention of zoologists to its numerous peculiarities of form and organisation; but well nigh half a century was nevertheless to elapse, ere all questions pertaining to the economy of this remarkable animal had been finally settled. The chief reason of this lay in the difficulty of obtaining live-specimens in sufficient number, although the animal is rather common than otherwise in the Mediterranean, at a trifling depth, and on the coasts of Corsica.

In Northern Europe, the first who met with an example of *Bonellia viridis* was one of ourselves (Koren), about 40 years ago, near Bergen, at a depth of 50 fathoms. He commenced an anatomical examination of this specimen, but had to break it off from lack of materials; for *Bonellia viridis* is comparatively rare on the Norwegian

¹ Hamingja, the Fortuna of Northern Mythology.

og er ikke funden nordligere, end ved Bergen. Det er nu til dette Dyr, *Hammingia arctica* slutter sig mest, idet den danner en interessant Overgangsform; kun maa vi beklage, at vi kun have havt 1 Exemplar til vore Undersøgelser.

Ydre Karakterer.

Legemet er cylindrisk med en glat, lidt slimet Overflade, er 120^{mm} langt, 20^{mm} tykt paa Midten, men smalner noget af mod begge Ender, Fig. 1.

Den forreste Ende er langstrakt, but afskaaren, og paa den findes Mundaabningen, der danner en Spalte med tykke, foldede Læber, og vender mod Bugfladen, Fig. 1, *a*, 2, *a*. Omkring Mundaabningen sees to halvmaaneformede Hudfolder, Fig. 1, *b*, 2, *b*, der paa Rygfladen ere temmelig fremspringende og staa et Stykke fra hinanden, imedens de mere og mere nærme sig hinanden mod Bugfladen, hvor den forreste Fold forener sig med den bagerste i en stump Vinkel, Fig. 2, *c*, saa at der bliver en liden Del af Munden, der ikke omfattes af de nævnte Folder. Imellem den forreste Fold og Munden er en yderst smal Indsynkning, hvorved Mundlæberne blive ligesom mere fremtrædende, Fig. 2, *d*; men imellem den forreste og bagerste Fold er Indsynkningen baade bredere og dybere, Fig. 2, *e*. Disse Folder kunne vel betragtes som en rudimentær Snabel.

Omtrent 20^{mm} fra Mundpartiet findes paa Bugsiden to lange, cylindriske, krumbojede Papiller, der staa ved Siden af hinanden, og paa hvis fri Spids, der vender mod Munddelen, iagttages en fin Aabning, Fig. 1, *c*, 2, *f*.

Kroppens bagerste Ende er afrundet, og i dens Centrum sees den runde Analaabning, Fig. 3.

Huden.

Huden er blød, halv gjennemsigtig, og dannes af en yderst tynd, strukturløs Cuticula, Fig. 4, *a*, der dækker det hyaline Bindevævslag, som er temmelig bredt, og hvori er leiret dels enkeltvis, dels i Grupper, Celler, Fig. 4, *b*, 5, *a*, imellem hvilke sees uformede Pigmenthobe. Her findes ikke noget Epithellag; men de nævnte Celler, der som oftest ere fyldte med et finkornet, grønt Pigment, saa at Kjernen ganske skjules, kunne i større Strækninger være enkeltvis sammenhængende, og faar da et epithelligende Udseende, Fig. 4, *c*, imedens tilgrænsende Steder kunne være ganske blottede for Celler. Imellem disse Pigmentceller, men som oftest dybere end dem, sees aflange Bindevævslegemer.

Indenfor det hyaline Bindevævslag er Muskelhuden, der bestaar af 3 distinkte Lag, nemlig Ringmuskler, Længdemuskler og Skraamuskler.

Ringmusklerne ere de yderste og ligge nærmest det hyaline Bindevævslag; de bestaa af smale Fibriller, der

coast, and has not been taken farther north than Bergen. Now it is this animal with which *Hammingia arctica* exhibits the closest agreement, representing a transition-form of very considerable interest: we regret however to state, that we have had but one specimen whereupon to base our observations.

External Characters.

Body cylindrical, with a smooth and slightly mucid surface, 120^{mm} long, 20^{mm} thick in the middle, but narrowing a little towards the extremities, fig. 1.

On the anterior extremity, which is elongate and obtusely truncate, occurs the buccal opening, as a slit or cleft, with thick, folded lips, facing the ventral surface, figs. 1, *a*; 2, *a*. Round the buccal opening extend two lunate cutaneous folds, figs. 1, *b*; 2, *b*, rather prominent on the dorsal surface, and a little apart, whereas they gradually converge on the ventral surface, and form an obtuse angle, fig. 2, *c*, leaving a small portion of the mouth which the said folds do not encircle. Between the anterior fold and the mouth, occurs an exceedingly narrow depression, which gives increased prominence to the buccal labia, fig. 2, *d*; between the anterior and posterior folds, the depression is broader and deeper, fig. 2, *e*. These folds may be regarded as a rudimentary proboscis.

About 20^{mm} from the buccal region, on the ventral surface, are seen two long, cylindrical, arcuate papillæ, placed side by side, the free extremity of which, facing the buccal section, is furnished with a minute aperture, figs. 1, *e*; 2, *f*.

Posterior extremity of the body rounded, with the anal orifice in the centre, fig. 3.

Skin.

The skin is soft, semi-translucent, and consists of an exceedingly thin, structureless cuticle, fig. 4, *a*, covering the hyaline layer of connective tissue, which is comparatively broad, and has dispersed throughout it, either isolated or in groups, a number of cells, figs. 4, *b*; 5, *a*, between which are seen amorphous lumps of pigment. There is no epithelial layer; but the cells are generally full of a finely granulous, green pigment, by which the nucleus is entirely hidden, and being sometimes connected, two and two together, they resemble epithelium in appearance, fig. 4, *c*, whereas spots directly adjacent will be sometimes altogether destitute of cells. Between these pigmentary cells, but, as a rule, deeper down, are seen elliptical corpuscles of connective tissue.

Underneath the hyaline layer of connective tissue, extends the muscular integument, composed of 3 distinct layers, viz. a layer of annular muscles, a layer of longitudinal muscles, and a layer of oblique muscles.

The annular layer, adjoining the hyaline layer of connective tissue, is the outermost; its muscles consist of

ved Bindevæv ere sammenbundne til en Hud, Fig. 4, *d*.

Længdemusklerne ere bredere, ligge indenfor Ringmusklerne og danne ligeledes en sammenhængende Hud, Fig. 4, *e*.

Indenfor Længdemusklerne, altsaa nærmest Kropshulheden, kun skilt fra denne ved Peritonealovertrækket, findes Skraamuskellaget, Fig. 4, *f*, hvis Muskler ere ligesaa stærke som Længdemusklerne, men ere fjernede noget længere fra hverandre, hvorved det sammenbindende Bindevæv bliver noget bredere. Ogsaa dette Lag danner en sammenhængende Hud.

Sammenlignes nu Huden hos *Hamingia* med Bonelliens, saa vil der findes baade Overensstemmelser og Afvigelser.

Efter Schmarda¹ skal der i Bonelliens Hud være et udpræget Epitheliallag, bestaaende af Cylinderceller, indenfor hvilket skal findes et maskedannende Hudlag, som dannes af stærke sammenvævede Cellevævsfibre og Kar.

I dette Lag fandt Schmarda enkelte Pigmentceller og større Hobe af samme, hvilke forenede sig til kjertelagtige Organer. Indenfor dette Lag angiver han Muskellaget bestaaende af Længde- og Ringfibre; paa den forreste Kropsdel føier sig dertil skjæve Muskelfibre.

Allerede Lacaze-Duthiers² har paavist, at der ikke findes noget særegent Kjertelapparat i Huden hos *Bonellia*, hvilket ogsaa stemmer overens med Grabers³ Undersøgelser. Denne Forsker betvivler stærkt Tilstedeværelsen af Cylinderepithellaget; derimod tror han at have fundet en af talrige Porekanaler gjennemboret Cuticula, indenfor hvilken han angiver et kornet Matrixlag, i hvilket findes kjerneagtige Indleiringer, snart enkeltvis, snart i Grupper. Indenfor dette Matrixlag har han fundet det egentlige Bindevævslag, der bestaar af hyalint Bindevæv, hvori findes sparsomt Bindevævslegemer. Sammenvævede Cellevævsfibre og Kar har Graber ikke fundet. Det vil heraf sees, at Huden hos *Hamingia* nærmer sig i histologisk Henseende meget til Bonelliens Hud ifølge Grabers Iagttagelser; men afviger dog noget fra den. Saaledes er Cuticula langt fra saa bred og heller ikke gjennemboret af Porekanaler hos *Hamingia*, som Tilfældet er hos *Bonellia*; noget Matrixlag findes ikke, derimod et hyalint Bindevævslag med indleirede, tildels pigmenterede Celler, nogenlunde svarende til hvad der findes hos *Bonellia*. Endelig har *Hamingia* et tredie Muskellag, nemlig de skraa Muskler, som Graber aldeles ikke omtaler hos *Bonellia*, imedens Schmarda angiver, at paa dennes forreste Kropsdel føier skraa Muskler

slender fibrils, which, being webbed together by connective tissue, constitute a continuous membrane, fig. 4, *d*.

The longitudinal muscles are broader, lie underneath those of the annular layer, and constitute, like the latter, a continuous membrane, fig. 4, *e*.

Underneath the longitudinal muscles — accordingly nearest the perivisceral cavity, with only the peritoneal tunic between — is seen the oblique layer, fig. 4, *f*, the muscles of which are as strong as those in the longitudinal layer, but somewhat farther apart, giving greater breadth to the connective tissue that webs them together. This layer, too, constitutes a continuous membrane.

On comparing the skin in *Hamingia* with that in *Bonellia*, it will be found to exhibit both agreement and difference.

According to Schmarda,¹ the skin in *Bonellia* has a well developed epithelial layer, consisting of cylindrical cells, underneath which is said to extend a reticulated tegumentary layer, composed of strong interwoven vessels and fibres of cellular tissue.

In this layer, Schmarda found a few isolated pigmentary cells, and agglomerations of such, which, uniting, formed glandulous organs. Underneath this layer, extends, he states, the muscular layer, composed of longitudinal and annular fibres, to which are united, on the anterior portion of the body, oblique muscular fibres.

Years ago, Lacaze-Duthiers² showed there was no special glandular apparatus in the skin of *Bonellia*; and since then, Graber³ has been led to form a similar conclusion. Indeed, that observer very much questions the existence of a cylindric epithelial layer, whereas he believes to have detected a cuticle perforated by canaliculated pores, extending underneath a granulated layer of matrix, throughout which were dispersed, both isolated and in groups, agglomerations of nucleal corpuscles. Underneath this layer of matrix, was the true layer of hyaline connective tissue, sparingly furnished with corpuscles of connective tissue. Interwoven fibres of connective tissue, and vessels, Graber did not observe. Hence it is obvious, according to Graber's investigation, that the skin in *Hamingia* bears, histologically, considerable resemblance to that in *Bonellia*, though not strictly agreeing. Thus, for instance, the cuticle is far less broad in *Hamingia* than in *Bonellia*, nor is it perforated by canaliculated pores; moreover, it has no layer of matrix; but there is a layer of hyaline tissue, with cells, in part pigmentary, much the same as in *Bonellia*. Finally, *Hamingia* is furnished with a third muscular assemblage, viz. the oblique layer, of which Graber makes no mention whatever as occurring in *Bonellia*, whereas Schmarda distinctly states,

¹ Schmarda. Denkschrift. der k. k. Akad. der Wissenschaft in Wien. Tom. IV, pag. 117, pl. 4—7.

² Lacaze-Duthiers. Recherches sur la Bonellie. Annal. des Sciences nat. III Série. Tome X, pag. 53.

³ Graber. Sitzb. der Akad. der Wissenschaften. Wien. 1te Abth. Jän. Heft. Jahrgang 1873.

¹ Schmarda. Denkschrift. der k. k. Akad. der Wissenschaft in Wien. Tom. IV, pag. 117, pl. 4—7.

² Lacaze-Duthiers. Recherches sur la Bonellie. Annal. des Sciences nat. III Série. Tome X, pag. 53.

³ Graber. Sitzb. der Akad. der Wissenschaften. Wien. 1te Abth. Jän. Heft. Jahrgang 1873.

sig til Ring- og Længdemusklerne.¹

Fra Schmardas Iagttagelser afviger derimod vore temmelig betydeligt; thi hverken have vi fundet fibrillært Bindevæv, maskeformigt sammenvævet med Kar, eller Kjertelorganer. Vi ere tilbøielige til at betragte saavel de enkelte, som de i Grupper i det hyaline Bindevæv leirede Celler, hvori indeholdes et yderst finkornet, grønligt Pigment, for egne Pigmentceller, der vel i den ydre Hud ere bundne til det hyaline Bindevæv; men som vi senere skulle se træffes baade i fibrillært Bindevæv og i Muskellagene, uden at de tilkjendegive sig som Kjertelorganer.

Fordøielsesorganerne.

Mundspalten, der gaar paalangs og er begrændset af tykke muskuløse Læber, fører ind til en sækformig Udvidning (Mundhulheden), som er 9^{mm} lang og omtrent 10^{mm} i Gjennemnit paa det Videste; men smalner saa stærkt af, at der, hvor den gaar over i Svælget, er den kun 3^{mm}. Denne Mundhulhed dannes af en rørformig Forlængelse af den ydre Hud, og paa dens indre Flade sees flere stærkt fremragende, temmelig brede, circulære Folder, der dog ere mest fremspringende paa Rygfladen, og hvoraf de to nærmest Mundspalten ere de betydeligste. De aftage noget imod Svælget.

Mundhulhedens Vægge bestaa af de samme Væv, som Huden. Paa den indre foldede Flade iagttaages et tykt Lag Cylinderepithel (sandsynligvis fimrende), der rager ind i Hulheden, og er især tykt paa de fremragende Folder, som dannes af fortykket Bindevæv; udenfor Epithelaget er et temmelig bredt fibrillært Bindevævslag, hvor Fibrene anastomosere med hverandre, og hvori er leiret, dels enkeltvis, dels spredte Grupper af de samme Celler og Pigmenthobe, som findes i den ydre Hud, kun i en rigeligere Mængde. Dette Bindevævslag støder umiddelbart til Muskellaget, der bestaar af Ring-, Længde- og Skraamuskler, og i disse Lag sees ogsaa de nysnævnte Celler og Pigmenthobe, men sparsommere. Skraamuskellaget er beklædt af Peritoneum.

Hele Mundhulhedens ydre Flade er ved en Mængde stærke Bindevævstraade, hvortil enkelte Muskelfibre foie sig, bunden til den forreste Del af Kropsvæggen. Der, hvor Mundhulheden gaar over i Svælget, er paa den ydre Flade en meget stærk Indsnøring, og paa den tilsvarende indre Flade er der en bred Fold, der rager cirkelformig ind i Hulheden og danner en Slags Sphincter, idet den er forsynet med stærke Ringmuskelfibre. Folden dannes af fortykket Bindevæv.

¹ Dr. J. W. Spengel har fundet et Skraamuskellag overalt i Huden hos *Bonellia viridis*. Mittheilungen aus der zoologischen Station zu Neapel, 1te B. 3te Heft, 1879.

that on the anterior portion of the body; oblique muscles adjoin the annular and longitudinal layers.¹

Meanwhile, Schmarda's observations differ materially from the results of our own examination; for neither did we remark any fibrillous connective tissue interlaced with vessels, nor any description of glandular organs. The cells scattered throughout the hyaline tissue, whether isolated or in groups, we are disposed to regard as special pigmentary cells (they contain a minutely granulous, greenish pigment), webbed indeed, in the outer skin, to the hyaline connective tissue, but which, as will afterwards appear, are met with alike in the fibrillous tissue and in the muscular layers, though not as glandulous organs.

Digestive Organs.

The buccal cleft, extending lengthwise, and margined by thick muscular labiæ, passes into a sac-like expansion (the buccal cavity), 9^{mm} long and about 10^{mm} in diameter where it is thickest, but narrowing so rapidly as to measure only 3^{mm} in diameter at the gullet. This buccal cavity is the result of a tubular elongation of the outer integument; and on its inner surface occur several broad, circular, exceedingly prominent folds, most protuberant on the dorsal surface, the two in immediate proximity to the buccal cleft being the largest. These folds become less salient in the vicinity of the gullet.

The walls of the buccal cavity consist of the same tissue as that in the skin. On the inner, folded surface, is seen a thick layer of cylindric epithelium (probably furnished with vibratile cilia), which extends into the cavity, and is thickest on the prominent folds, consisting of inspissated connective tissue. Above the epithelial layer lies a broadish layer of fibrillous connective tissue, with anastomosing fibres, throughout which are dispersed, isolated and in scattered groups, cells and amorphous lumps of pigment, similar to those in the outer skin, only in greater abundance. This layer of connective tissue directly adjoins the muscular integument, which is built up of annular, longitudinal, and oblique muscles; and these layers, too, are furnished with the aforesaid cells and pigmentary lumps, but more sparingly. The oblique muscular layer is invested with a peritoneal tunic.

The entire outer surface of the buccal cavity is webbed by numbers of strong filaments of connective tissue and a few muscular fibres to the anterior portion of the wall of the body. At the commencement of the gullet, is seen on the outer surface of the buccal cavity a very deep indistinction, and on the inner surface occurs a broad fold, projecting with a circular sweep into the cavity, where it forms a kind of sphincter, being furnished with strong annular muscular fibres. The fold consists of incrassated connective tissue.

¹ Dr. J. W. Spengel has invariably observed a layer of oblique muscles in the skin of *Bonellia viridis*. Mittheilungen aus der zoologischen Station zu Neapel, 1te B. 3te Heft, 1879.

Svælget, Fig. 6, *b*, er yderst trangt, knapt 2^{mm} i Gjennemsnit, har en straagul Farve, løber i Bugtninger fra Høire til Venstre, og er bunden saavel paa Ryg- som Bugsiden ved et Mesenterium til Kropsvæggen.

Svælgets Vægge ere tykke og dannes af et indre Epithellag (Slimhud), der er tykt, bestaar af et Lag lange Cylinderceller, Fig. 7, *a*, der paa den indadvendte Ende synes at være forsynede med Cilier. Denne Slimhud gjør dybe, regelmæssige Indsynkninger, Fig. 7, *b*, *b*, i det tilgrændsende fibrillære, meget kjernefærdige Binde-væv, Fig. 7, *c*, saaledes nemlig, at derved fremkommer ringformige Fordybninger, hvilke give Spiserøret paa dets ydre Flade et ringet Udseende, noget lig en Trachea hos de høiere Dyr, Fig. 6, *c*. I Bundten af Slimhudsindsynkningerne er Epithellaget tykkere end paa Siderne. Til dette fibrillære Binde-væv fæster sig udad Muskelhuden, der bestaar af Længdemuskler, Fig. 7, *d*, der ere de inderste, samt Ringmuskler, Fig. 7, *e*, der ere tykkere end hine. Saavel Længde- som Ringmusklerne anastomosere med hinanden indbyrdes.

Spiserøret gaar nu over i en bredere Del af Tarmrøret, Fig. 6, *c*, som paa venstre Side gjør et Par Bøininger, gaar saa lidt til Høire, Fig. 6, *d*, løber derpaa horizontalt bag til Kropshulhedens forreste Trediedel, Fig. 6, *e*, bøier sig fortil langs venstre Side i en Længde af 12^{mm}, Fig. 6, *f*, hvor den ved en Bøining løber lidt paa Skraa over til høire Side, hvorved den første Tverslyng opstaar, Fig. 6, *g*; her gjør den en let Bøining, løber saa horizontalt langs høire Side til omtrent Midten af Kropshulheden, Fig. 6, *h*, hvor den danner en anseformig Bøining, Fig. 6, *i*, idet den gaar over til venstre Side, hvorved den 2den Tverslyng fremkommer, Fig. 6, *k*. Alt hvad der af Tarmrøret ligger foran den anseformige Bøining og lige til Mundaabningen kalder Lacaze-Duthiers Buccaldelen hos *Bonellia viridis*, idet han ikke som Schmarda differentierer Mundhulhed og Spiserør fra det øvrige Tarmrør.

I anatomisk-histologisk Henseende er Tarmrøret fra Svælget til den anden Tverslyng ikke væsentlig forskjellig fra Spiserøret; det er noget videre og Væggene noget tyndere.

Den anden Tverslyng, naar den er kommen over til Venstre, gjør en Bøining og løber saa over til Høire, hvorved 3die Tverslyng opstaar, Fig. 6, *l*; her danner den en stor Anse for at gaa stærkt paaskraa over til Venstre: den 4de Tverslyng, Fig. 6, *n*, hvor den bliver noget smalere og bøier sig atter for at komme over paa høire Side, hvorved den 5te Tverslyng, Fig. 6, *o*, dannes.

De 4 sidste Tverslynger svarer til Lacaze-Duthiers Leverdel hos *Bonellia viridis*. De ere i anatomisk-histologisk Henseende noget forskellige fra det øvrige Tarmrør, idet Væggene ere tyndere; Epithellagets (Slimhudens) Ind-

The gullet, fig. 6, *b*, is exceedingly narrow, hardly 2^{mm} in diameter, straw-coloured, winds from right to left, and is webbed, both on the dorsal and the ventral side, to the wall of the body by a mesentery.

The pharyngeal walls are thick, and consist of an inner layer of epithelium (mucous integument), which is also thick; it consists of a layer of long cylindrical cells, fig. 7, *a*, furnished apparently, on the side turning inwards, with vibratile cilia. This mucous skin corrugates the fibrillous, nucleal tissue adjacent, fig. 7, *c*, with a number of deep, regular troughs, fig. 7, *b*, *b*, in such wise as to produce annular depressions, which give to the outer surface of the œsophagus an annulated appearance, not unlike that of the trachea in more highly organised animals, fig. 6, *c*. At the bottom of the troughs in the mucous skin, the epithelial layer is thicker than at the sides. To this fibrillous connective tissue, is webbed from without the muscular integument, composed of longitudinal muscles, fig. 7, *d*, — the innermost layer, — and of annular muscles, fig. 7, *e*, somewhat thicker than the former. Both the longitudinal and annular muscles anastomose reciprocally.

The œsophagus now opens into the broader portion of the intestinal canal, fig. 6, *c*, which, on the left side, makes a twist or two, passes a little to the right, fig. 6, *d*, protends from thence horizontally back to the anterior third of the perivisceral cavity, fig. 6, *e*, winds forwards along the left side for about 12^{mm}, fig. 6, *f*, where, after making a twist, it takes a somewhat oblique direction across to the right, thus completing the 1st transverse circumvolution, fig. 6, *g*. Here it makes a slight twist, protends horizontally along the right side about to the middle of the perivisceral cavity, fig. 6, *h*, where, after making an ansiform twist, fig. 6, *i*, it passes across to the left side, and terminates the 2nd transverse circumvolution, fig. 6, *k*. The whole of the intestinal canal extending forwards from the ansiform twist to the oral aperture, Lacaze-Duthiers terms the buccal region, that naturalist not having, like Schmarda, distinguished the oral cavity and the œsophagus from the remainder of the intestinal canal.

As regards its anatomical-histological structure, the section of the intestinal canal extending between the gullet and the second transverse circumvolution, does not differ materially from the œsophagus, being merely a little wider, and with somewhat thinner walls.

On reaching the left side, the second transverse circumvolution makes a twist, and then passes across to the right side, thus producing the 3rd transverse circumvolution, fig. 6, *l*. At this point it protends, with a wide bend, very obliquely across to the left side (4th transverse circumvolution, fig. 6, *n*), where its thickness has slightly diminished. It now makes another twist, across to the right side, and forms the 5th transverse circumvolution, fig. 6, *o*.

The 4 last transverse circumvolutions represent the liver-section in *Bonellia viridis*, according to Lacaze-Duthiers. Their anatomical-histological structure differs somewhat from that distinguishing the remainder of the intestinal

synkninger i Bindevævet ere ikke saa dybe, og staa heller ikke saa tæt i hinanden, og foruden de almindelige Cylinder-celler, som i Spiserøret, findes der i Epithelet en stor Mængde pæreformige encellede Kjertler, Fig. 11, *f* (Lever-celler), der svare fuldkommen til Tarmkjertlerne hos *Bonellia*. Disse Kjertler ligge tildels i Grupper, der kunne sees med en stærk Loupe igjennem Tarmvæggen, Fig. 6, *k, l, m, o*.

Naar den 5te Tverslynge har naaet hen til høire Side, bliver den meget smalere. Tarmrøret løber nu i flere Bøininger skraa fortil under de tidligere omtalte paatversgaaende Slynger, lige henimod den første Tverslynge. Paa denne Strækning gjør den en Mangfoldighed af smaa Circumvolutioner, Fig. 6, *p, p*. Nu bøier den sig hen mod venstre Side, hvor den gjør en Bøining for at løbe langs denne i en horizontal Retning mod Kropshulhedens bagerste Trediedel, Fig. 6, *q, q*, hvor den danner en Slynge, Fig. 6, *r*, for i samme horizontale Retning at gaa fortil imod Midten af Kropshulheden, Fig. 6, *s*, her skraar den over mod høire Side under de øvrige Tarmslynger; den bøier sig nu i en skraa Retning mod Midtlinien af Kropshulheden, Fig. 6, *t*, og gjør atter en Mængde Circumvolutioner, indtil den gaar over i en paaskraa løbende Rectum, Fig. 6, *u*, der først udvider sig lidt, men bliver saa smalere, idet den munder ud i Kloaken.

Fra den 5te Tverslynge og indtil Analaabningen, — der svarer til den Del hos *Bonellia viridis*, som Lacaze-Duthiers har kaldet Analdelen, — har Tarmrøret den samme Bygning, som tidligere er angivet for den Del, der strækker sig fra Spiserøret til 2den Tverslynge, og er følgelig uden noget Kjertelapparat.

Langs Tarmrørets Bugflade, især paa den forreste Del, sees et Bindevævsbaand, hvortil Bugmesenteriet er fæstet, og hvori et Blodkar iagttages; paa den bagerste Del er dette Bindevævsbaand tyndere. Det synes paa enkelte Steder at stramme Tarmen saaledes, at dennes Bugflade bliver foldet; men det er kun paa et Par Slynger, at saa er Tilfældet.

Bugmesenteriet bestaar af en stor Mængde smalere og bredere Bindevævsstraade, hvori tildels findes Muskel-fibre, hvilke fæste Tarmrøret til Kropshulheden. Et lignende Mesenterium, men langt zartere, iagttages ogsaa langs Tarmens Rygflade, der fæster denne til Kropshulhedens Rygflade.

Kloaken er bunden ved en Mængde stærke fibromuskuløse Baand til Kropsvæggen, hvilke udbrede sig straaleformigt paa denne og danne derved ligesom et Telt, Fig. 6, *v*, under hvilket 2de busede Organer ere placerede, et paa hver Side af Rectum. Tarmrørets ydre Flade er forsynet med et flimrende Peritonealovertræk.

Den norske Nordhavsexpedition. Danielssen og Koren: Gephyrea.

canal, the walls are thinner; the depressions of the epithelial layer (mucous membrane) in the connective tissue are not so deep, or so close together; and exclusive of the ordinary cylindrical cells (those in the skin of the oesophagus, for instance), numbers of pyriform, unicellular glands, fig. 11, *f* (hepatic cells), occur dispersed throughout the epithelium — the exact analogue of the intestinal glands in *Bonellia*. Part of these glands are arranged in groups, which may be seen, under a strong magnifier, through the wall of the intestine, fig. 6, *k, l, m, o*.

On reaching the right side, the 5th transverse circumvolution diminishes very considerably in thickness. The intestinal canal now passes obliquely forward, twisting repeatedly, beneath the transverse circumvolutions described above, to the first circumvolution. On its course it forms a great many small convolutions, fig. 6, *p, p*. It now bends across to the left side, along which it protends, after making a twist, in a horizontal direction, to the posterior third of the perivisceral cavity, fig. 6, *q, q*, where it forms a circumvolution, fig. 6, *r*, and then passes on, horizontally as before, to the middle of the perivisceral cavity, fig. 6, *s*; here it takes an oblique direction across to the right side, beneath the other circumvolutions, and then bends obliquely on towards the mesial line of the perivisceral cavity, fig. 6, *t*, again forming a number of convolutions, till it enters an obliquely protending rectum, fig. 6, *u*, which expands a little at its commencement, but grows narrower where it disembogues into the cloacum.

From the 5th transverse circumvolution to the anal opening, — which represents the part in *Bonellia viridis* termed by Lacaze-Duthiers the anal region, — the intestinal canal exhibits the structure described above as characterising the part that extends from the oesophagus to the 2nd transverse circumvolution: hence it has no glandular apparatus.

On the ventral surface of the intestinal canal — more particularly the anterior part — is seen a membranous band (webbed to the ventral mesentery), in which there is a blood-vessel: this membranous band has its posterior portion thinner than the remainder. In some places, it would appear to stretch the intestine, corrugating the ventral surface of the latter; this is the case, however, only with one or two of the convolutions.

The ventral mesentery consists of numerous filaments of connective tissue, in some of which are muscular fibres, that serve to attach the intestinal canal to the perivisceral cavity. A similar mesentery, but far more delicate in structure, is seen, too, on the dorsal surface of the intestine, which it webs to the dorsal surface of the perivisceral cavity.

The cloacum is webbed to the wall of the body by numerous strong fibro-muscular bands, which, radiating on the latter, form, as it were, a tent-like enclosure, fig. 6, *v*, under which are placed two bunchy organs, one on either side of the rectum. The outer surface of the intestinal canal is invested with a ciliated peritoneal tunic.

Man vil af ovennævnte Beskrivelse se, at Tarmrøret vel danner Slyngninger, men ikke, som hos *Bonellia viridis* (efter Lacaze-Duthiers), danner nogen Spiral omkring den lange Æggebeholder (matrix, la poche génitale).

Hele Mundhulheden var udfyldt af sandholdigt Lær, hvori fandtes forskellige Foraminiferer, Diatomeer, Alger og Ascarider. Svælget var tomt; men strax bagenfor dette havde det sandholdige Indhold for endel formet sig til cylindriske, langstrakte Boli med afrundede Ender, 3—4^{mm} lange og 1.5—2^{mm} tykke, og jo længere bag i Tarmen, desto hyppigere bleve disse, saa at hele den Del, der strækker sig fra 5te Tverslynge og til Anus, var ganske opfyldt af disse Excrementer.

De to buskede Organer ere næsten kugledannede, 3—4^{mm} store, og ere fæstede et paa hver Side af Rectum, strax foran Kloakaabningen, Fig. 8, *a, a*. De have en cylindrisk Stamme, der danner et Rør, som ved Udspringet er nøgent i en Længde af omtrent 1^{mm}, Fig. 8, *b*; men fra den øvrige Del af Stammen udgaar en Mængde rørformige Grene, Fig. 9, *a*, hvorfra udspringer en stor Mangfoldighed af lange, smale, slangeformige Rør, Fig. 9, *b, b*. Disse have paa deres frie Ende en tragtformig Aabning, som fører ind til Rørets Hulhed, og hvis Rand er forsynet med lange Cilier, Fig. 9, *c, c*, 10.

I histologisk Henseende dannes de nævnte Organer væsentligst af de samme Elementer, som Tarm- eller Kløkvæggen, hvoraf de egentlig kunne betragtes som en Udstylpning. Den indre Flade er tapetseret af et rigt flimrende Epithel, der rager ind i Hulheden, og hvis Celler ere store, dels runde, dels mere eller mindre aflange; de have en temmelig stor Kjerne og et yderst finkornet brungrønt Pigment, der ofte er saa tæt og tykt, at det ganske skjuler Kjernen, Fig. 12; *a, a*; 13, *b, b*. Epithellet er fæstet til et fibrillært Bindevævslag, hvortil Muskelhuden støder, hvilken bestaar af Længde- og Ringfibre, som beklædes af det flimrende Peritoneum, som altsaa danner den ydre til Kropshulheden vendende Flade. Indeni Rørenes Lumen iagttoges en hel Del smaa fritliggende runde Legemer, der vare noget sammenskrumpede, forsynede enten med Kjerne eller nogle faa Moleculer, Fig. 13, *c*, og som lignede de Legemer, Kropsvædsken indeholdt, hvilke tildels vare koagulerede i Klumper. Hovedstammen aabner sig paa Kloakens indre Flade imellem et Par af dens stærke Folder.

Af den her givne Beskrivelse af de buskede Organer, vil det sees, at de saagodtsom ganske svare til de, der findes paa samme Sted hos *Bonellia viridis*, og som Schmarda har antaget for Respirationsorganer, idet han finder dem analoge med Holothuridernes.

Lacaze-Duthiers har underkastet de nævnte Organer en nøiere Granskning, og derved paavist, at de først og fremst maa betragtes som et Kjertelapparat, som han kalder Analsække (poches anales), imedens han dog opstiller som en Mulighed, at de tillige kunne staa i Respirationens

From the description given above, it will be seen, that the intestinal canal does indeed form numbers of circumvolutions, but not, as in *Bonellia viridis* (according to Lacaze-Duthiers), a spiral coil round the elongated uterus (matrix, la poche génitale).

The whole of the buccal cavity was distended with sabulous clay, containing divers Foraminifera, Diatoms, Algæ, and Ascaridæ. The gullet was empty; but immediately posterior to that organ, part of the sabulous contents had become moulded into cylindrical, elongated boli, rounded at the extremities; and these fæcal pellets — 3.4^{mm} long and 1.5—2^{mm} broad — were found to increase in number, the farther they extended down the intestine, the part between the 5th transverse circumvolution and the anus being entirely filled with them.

The two bunchy organs, almost globular in form and 3—4^{mm} in diameter, are attached to the rectum, one on either side, immediately in front of the cloacal opening, fig. 8, *a, a*. They have a cylindrical trunk, forming a tube, which at the point of origin is smooth for about 1^{mm} of its length; but the remaining portion of the trunk sends off numbers of tubular branches, from which issue a multitude of long, slender, serpentine tubes, fig. 9, *b, b*. These tubes have at their free extremity a funnel-shaped aperture, leading to the hollow of the tube; the margin of the aperture is furnished with long cilia, fig. 9, *c, c*; 10.

As regards their histological structure, these organs are built up chiefly of the same elements as the intestinal and cloacal walls, of which indeed they may be regarded as a bossed expansion. The inner surface is clothed with vibratile epithelium, projecting into the hollow of the tube; and the cells, which are large, and in part round, in part elliptical, contain a largish nucleus and a minutely granulated brownish-green pigment, frequently so dense and opaque as to entirely conceal the nucleus, figs. 12, *a, a*; 13, *b, b*. The epithelium is webbed to a layer of fibrillous connective tissue, adjoining the muscular integument, which consists of longitudinal and annular fibres invested with the vibratile peritoneum; the latter accordingly constitutes the exterior surface facing the perivisceral cavity. In the lumen of the tubes were seen numbers of free globose corpuscles, somewhat shrunk or shrivelled, containing a nucleus or a few granular molecules, fig. 13, *c*, and which resembled the corpuscles in the perivisceral fluid, whereof part had coagulated into clots. The trunk itself opens on the inner surface of the cloacum, between two of its prominent folds.

From the above description, it is obvious that these bunchy organs almost perfectly correspond with the organs similarly located in *Bonellia viridis*, which Schmarda held to be respiratory tubes, analogous to the "trees" in Holothurians.

Lacaze-Duthiers, who subjected these organs to a more rigorous investigation, has shown them to be fundamentally a glandular apparatus — anal sacs (poches anales), though they may likewise, he thinks, in some way, be subservient to respiration. If so, one part would, in

Tjeneste. Han formener da, at et Parti af dem skulde udføre Secretionsorganets Rolle, imedens et andet kunde fungere som Lunger.

Ifølge vore Undersøgelser, som rigtignok ere foretagne paa et enkelt Exemplar, opbevaret i Spiritus, hvilket dog blev observeret og tegnet i levende Liv, antage vi, at de heromhandlede Organer hos *Hamingia* ere analoge med Holothuridernes saakaldte Lunger; men som vi for *Molpadidernes* Vedkommende have paavist at være Tarmappendices (Secretionsorganer), der intet have med Respirationen at bestille. At disse Organer hos *Hamingia* ogsaa ere Afsondringsapparater og ikke Lunger, synes at fremgaa ikke alene af deres Bygning, men ogsaa af den Omstændighed, at de ikke staa i nogen Forbindelse med Blodeirculationen.

I det Døgn, Dyret blev observeret i levende Liv, aabnede Kloakaabningen sig kun saa ofte Excrementerne bleve udstødte; noget Søvand kunde ikke trænge ind igjennem den ved en stærk Sphincter lukkede Aabning, ligesom Endetarmen og Kloaken viste sig at være propfulde af de før beskrevne Excrementer. Men det staaer ikke til at nægte, at de her omtalte Organer ere noget forskjellige fra Holothuridernes benævnte Lunger. Disse, der hovedsagelig bestaa i større og mindre Samlinger af blæreformede Blind-sække, staa ikke i nogen directe Communication med Krops-hulhedens Fluidum. Sagens yttre Semper, at han formener at have iagttaget en Aabning paa Blærene; men ingen anden Forsker har observeret dette.

Hos vor nye Slægt er der ligesom hos *Bonellia* en tragtformig, vid Aabning paa de beskrevne slangeformede Rør, forsynet med lange Cilier, hvori Kropsvædsken efter al Sandsynlighed optages; men om den saaledes optagne Kropsvædske undergaar paa denne Vei nogen Forandring, eller om den atter jages ud i Hulheden, se det er et Spørgsmaal, vi ikke kunne besvare, da vi dertil ikke have haft Materiale nok. Men skulle vi indlade os paa en Hypothese, saa var det den, at disse Organer, som vi antage for Secretionsorganer, tjene til at rense og forsaavidt ogsaa til at fornye Kropsvædsken; de virke, om man saa vil, som et Slags Nyrer.

Circulationssystemet.

Vore Undersøgelser over Kredsløbet ere vistnok ufuldstændige; men Skylden herfor tør mest ligge i det mangelfulde Materiale.

Naar Dyret er aabnet fra Rygsiden, iagttages paa Mundhulhedens ydre Flade en korktrækkerformig, hvid, glindsende Kanal, der er Rygkarret, Fig. 6, *x*. Dette løber fortil langs Mundhulhedens Rygflade, lige til dennes forreste Ende, hvor det deler sig i to Grene, en til hver Side. Det tiltager i Tykkelse, alt eftersom det kommer længere bag mod Svælget, og er slangeformig bugtet, saalænge det løber paa Mundhulheden, Fig. 14, *a*. Naar det forlader denne, bliver det tykkere, næsten lige, gaar under

his opinion, perform the office of a secretory organ, and the other that of lungs.

Our own results, based, it is true, on the examination of a single specimen, preserved in spirits, which was however observed and figured while alive, lead us to regard the aforesaid organs in *Hamingia* as the analogue of the so-called "lungs," or "respiratory trees," in the *Holothuriidæ*, but which, in the case of the *Molpadidæ*, we have shown to be intestinal appendages (a secretory apparatus); having nothing whatever to do with respiration. And that these organs in *Hamingia* are in like manner endowed with a secretory, and not a respiratory function, may be inferred, not only from their structure, but also from the fact of their being nowise connected with the circulation of the blood.

During the 24 hours the animal was kept alive, the cloacum was never once seen to open, save for the discharge of the fæces. A powerful sphincter, which closes up the aperture, effectually prevented the ingress of sea-water; and besides, the rectum and the cloacum were both found to be full of the fæcal pellets described above. Meanwhile, it is not to be denied, that the organs in question differ somewhat from those termed "lungs," or "respiratory trees," in the *Holothuriidæ*. The latter, chiefly consisting of larger and smaller assemblages of vesicular cæca, have no direct communication with the fluid of the perivisceral cavity. True, Semper alleges to have observed an opening on the surface of the vesicles, but no other zoologist has recorded its occurrence.

In our new genus, as in *Bonellia*, the sinuous tubes described above exhibit a wide, funnel-shaped aperture, furnished with long cilia, in all probability for the reception of the perivisceral fluid; but whether this fluid undergo any change on its passage, or be again ejected into the hollow of the body, is a question we are not at present prepared to answer, having lacked sufficient materials for conclusively deciding it. But were we to venture an hypothetical explanation, it would be this, that the organs in question, whose function we regard as secretory, serve to purify, and so far therefore to renew, the perivisceral fluid; their action being, we may say, nephritic.

Circulatory System.

Our investigation of this system in *Hamingia* is decidedly incomplete; but this will, we trust, be found to arise chiefly from insufficiency of materials.

On opening the animal on the dorsal side, a white, glistening, spirally twisted canal is seen extending along the outer surface of the buccal cavity. This is the dorsal vessel, fig. 6, *x*, which passes forward along the dorsal surface of the buccal cavity straight to its anterior termination, where it divides into 2 branches, one on either side. It increases in thickness the nearer it approaches the gullet, and retains a sinuous course on the buccal cavity, fig. 14, *a*, after crossing which it grows thicker, and

Svælget, Fig. 6, *x*, i Dybden og løber bagtil over venstre Æggebeholder, hvor det tiltager temmelig betydeligt i Tykkelse, Fig. 14, *b, c*. Herfra løber det hen til den venstre horizontale Tarmslynge, Fig. 14, *d*, paa dennes Rygflade, hvortil det er bundet ved Bindevævstraade ved Siden af Rygmesenteriet; naar det er kommet et Stykke bag paa Tarmslyngen, deler det sig i 2 Hovedstammer, Fig. 14, *e*, hvoraf den ene nu følger Tarmrørets Rygflade langt bagtil, hvor det synes at ophøre, efterat have forladt den 5te Tverslynge. Karret er overalt tæt bundet til Tarmen, og afgiver hist og her enkelte Grene til denne; hvorvidt disse igjen fordele sig og danne Anastomoser, kunne vi ikke afgjøre, da vi ikke have fundet noget saadant.

Den anden Hovedstamme deler sig derimod i mange Grene, som igjen forgrene sig og danne ligesom et bredt Belte, der dækker næsten hele Tarmens Rygflade, idet disse mangfoldige Smaagrener, som ere bundne sammen ved et tyndt Bindevæv, gaar over mod Bugfladen, Fig. 14, *g*, og træffe her paa lignende Smaagrener fra Bugkarret, hvormed de synes at forene sig. Disse Karbundter ere fæstede til Tarmen, have en skidden gulhvid Farve, ere samlede et Par Millim. brede og 4—5^{mm} lange.

Bugkarret er tykkere end Rygkarret, løber paa den horizontale Tarmslynges Bugside, Fig. 14, *h*, hvor det ogsaa deler sig i to Hovedstammer, hvoraf den ene ligesom ved Rygkarret løber langs Tarmens Bugflade bagtil, hvor den ender omtrent paa samme Sted, som Rygkarret — kun paa Tarmens Bugside, Fig. 14, *i*. Den anden Hovedstamme, Fig. 14, *k*, forgrener sig paa samme Vis som Rygkarret, og hjælper til at danne den føromtalte Karudbredning.

Fortil løber Bugkarret lidt tilhøire, Fig. 14, *l*, 15, *b*, efterat have afgivet en stærk Gren til det forreste Parti af Tarmrøret og Svælget, Fig. 15, *c*, en Gren, der gaar bagtil langs Nerven, Fig. 15, *d*, og endelig en Gren, der gaar over paa en anden Tarmslynge, Fig. 15, *e*. Naar det har afgivet disse Grene, løber det lidt i Dybden, krydser sig med Rygkarret, gaar nu langs Nerven, imellem begge Æggebeholderne, Fig. 14, *m*, og fortsætter sit Løb paa Mundhulhedens ydre Bugflade indtil dennes forreste Ende, strax bagenfor Mundaabningen, hvor det deler sig i to Grene, Fig. 15, *g*, der omgive Spiserøret, for, efter alt hvad vi kunde se, at forene sig med Rygkarrets tvende Grene, hvorved en Ringkanal fremkommer.

Den venstre Gren er temmelig tynd; men den høire udvider sig strax, Fig. 15, *h*, og fra denne Udvidning gaar et tykt Kar lidt bagover, bliver et kort Stykke smalere, Fig. 15, *i*, og taber sig i et stærkt muskuløst, aflangt, ægformigt, hult Legeme (Hjerte?), der var opfyldt med Blod og flotterede frit i Kropshulheden, Fig. 15, *k*. Fra Ringkanalen gik flere korte Grene ind imellem Hudens Muskellag.

becomes almost straight, passes under the gullet, at some depth beneath it, fig. 6, *x*, and then protends backward across the left uterus, where it increases considerably in thickness, fig. 14, *b, c*. Here it makes for the left horizontal circumvolution of the intestine, fig. 14, *d*, to the dorsal surface of which it is webbed by membranous filaments of connective tissue, alongside of the dorsal mesentery; it now passes some distance back on the said circumvolution, and then divides into 2 trunk-like stems, fig. 14, *e*, one of which protends far back along the dorsal surface of the intestinal canal, where, after quitting the 5th transverse circumvolution, it apparently terminates. The vessel is closely webbed to the intestine, to which it sends off every here and there a few branches; but whether these branches also ramify, forming anastomoses, we are unable to state.

The other trunk-like stem divides into a number of branches, which ramify in turn, and form, as it were, a broad cincture, covering almost the whole dorsal surface of the intestine; for these numerous branchlets, which are webbed together by a thin connective membrane, stretch across to the ventral surface, fig. 14, *g*, meeting there similar branchlets from the ventral vessel, with which they apparently unite. These vascular fascicles, dirty yellowish-white in colour, are attached to the intestine, and measure collectively about 2^{mm} in breadth and 4—5^{mm} in length.

The ventral vessel, which is thicker than the dorsal, protends along the ventral surface of the horizontal circumvolution of the intestine, fig. 14, *h*, where it likewise divides into 2 trunk-like stems, one of which passes backward, as does that of the dorsal vessel, along the ventral surface of the intestine, where it terminates in the same place about as the dorsal vessel, — but on the ventral surface of the intestine, fig. 14, *i*. The other trunk-like stem, fig. 14, *k*, divides in the same manner as the corresponding stem of the dorsal vessel, and helps to form the aforesaid vascular expansion.

Anteriorly, the ventral vessel swerves a little to the right, fig. 14, *l*; 15, *b*, after sending off a thick branch to the anterior portion of the intestinal canal and the gullet, fig. 15, *c*; a branch protending backwards along the nerve; and a branch passing over to the 2nd circumvolution of the intestine, fig. 15, *e*. It now runs on at some depth, intersecting the dorsal vessel, then strikes off along the nerve, between the two uteri, fig. 14, *m*, and, continuing its course along the outer ventral surface of the buccal cavity to the anterior termination of the latter, divides into two branches, fig. 15, *g*, which encompass the œsophagus, and unite, so far as we could distinguish, with the two branches from the dorsal vessel, forming an annular canal.

The left branch is comparatively thin, but the right one immediately expands, fig. 15, *h*, and from this expansion issues a thick vessel, which, after passing backwards a little, becomes for a short space somewhat narrower, fig. 15, *i*, and then coalesces with an exceedingly muscular, oblongo-ovate, hollow body (heart?), filled with blood, and floating freely in the perivisceral cavity, fig. 15, *k*.

Vi have vel seet, at baade Ryg- og Bugkarret afgive Grene til Tarmen, Mesenteriet og til Æggestokken; men vi have ikke kunnet iagttage nogen Forbindelse imellem dem, og langt fra den netformige Karudbredning paa Tarmen, som Schmarda angiver at være tilstede hos *Bonellia viridis*.

Der er hos *Hamingia* vistnok et afsluttet Kredsløb; men det er et Spørgsmaal, om dette ikke er dobbelt, saaledes nemlig, at den Gren af Ryg- og Bugkarret, Fig. 14, *i, e*, der fra den forreste store udbredte Karforgrening, Fig. 14, *g*, løber langs Tarmens Sider til bag imod de sidste Circumvolutioner, — om ikke disse Kar paa en lignende Maade udbrede og forene sig som ved den store Karforgrening; er dette Tilfældet, saa er der et andet Kredsløb, der jo er meget længere end det første. Men, hvilket af disse Kar, der virker som Arterie eller Vene, det lader sig vanskelig afgjøre. Kan det antages, at det flotterende, muskuløse Legeme virker som et Hjerte, kan dette betragtes som et Centralorgan, da forekommer det os, at Bugkarret, med hvilket Hjertet staar saagodtsom i umiddelbar Forbindelse, maa repræsentere det arterielle System, og følgelig Rygkarret Venesystemet. Dette synes yderligere at bekræftes derved, at Bugkarret, der er tykkere, har fastere muskuløse Vægge, end Rygkarret.

Sammenligner man nu Circulationsorganerne hos vort Dyr med *Bonelliens*, saa viser det sig, at de afvige noget, hvilket ogsaa var at vente, alene af den Grund, at *Hamingia* ingen Snabel har; men Fællesskabet er ikke destomindre temmelig iøinefaldende. Hos *Bonellien* er den sækformige Udvidning af Bugkarret, der flotterer i den midterste Del af Kropshulheden, udtydet som muligens et pulserende Centralorgan (Hjerte, Lacaze-Duthiers), og forsaa vidt kan det ansees som et Analogon til det særegne Organ hos *Hamingia*, som vi have fundet flotterende i den forreste Ende af Kropshulheden, og som staar i Forbindelse med Bugkarret. Men omtrent paa det Sted, hvor Lacaze-Duthiers har fundet den sækformige Udvidning af Bugkarret, der findes hos *Hamingia* den særegne Karforgrening, der danner Foreningen imellem Ryg- og Bugkar, hvilken ikke kan betragtes som nogen Centraldel, men snarere som et peripherisk Afsnit af Circulationen.

Nervesystemet.

Hos *Gephyreerne* ialmindelighed er Nervesystemet temmelig let tilgængeligt, og anderledes er det heller ikke hos vor nye Slægt.

Naar Tarmrøret er borttaget eller skudt til Side, saa fremtræder tydeligt Centralnervestrængen, der langs Midten af Bugfladen strækker sig fra Munden til Anus, Fig. 16, *a*. Den har en hvid glindsende Farve, er bundet til Bugmesenteriet, og er beklædt paa sin indre i Kropshulheden fremragende Flade af Peritoneum. Den ligger altsaa imellem dette og Skraamuskelaget.

Branches proceeding from the dorsal and ventral vessels to the intestine, the mesentery, and the ovarium, we have observed, but have failed to detect any connexion whatever between them; we certainly did not observe the reticulating vascular expansion on the intestine alleged by Schmarda to occur in *Bonellia viridis*.

Hamingia is unquestionably furnished with a true circulatory system; but the question arises, whether that system be not bifold, inasmuch as the branches of the dorsal and ventral vessels, fig. 14, *i, e*, which, issuing from the greatly expanded anterior vascular ramification, fig. 14, *g*, protend backwards along the sides of the intestine to the last circumvolutions, may possibly in turn expand and unite, precisely as do the vessels at the great vascular ramification. Now, assuming this to be the case, a new circulation will commence, taking another and much longer course. But which of the said vessels conveys venous, and which arterial blood, is indeed difficult to decide. If, however, the floating muscular body be assumed to perform the function of a heart — be regarded as a central organ, the ventral vessel, with which it directly communicates, might, we think, with good reason be held to represent the arterial system, and the dorsal vessel the venous. And this view would seem to derive additional support from the fact of the ventral vessel, which is thicker, having more compact and muscular walls than the dorsal.

On comparing the circulatory organs in *Hamingia* with those in *Bonellia*, they are certainly found to differ somewhat, which was indeed to be expected, if for no other reason, because of the former not having a proboscis; but their mutual resemblance is nevertheless striking. The sac-like expansion of the ventral vessel floating in *Bonellia* in the middle of the perivisceral cavity, has been held to represent, possibly, a pulsating central organ (heart, Lacaze-Duthiers), and in that sense it may be regarded as the analogue of the organ in *Hamingia* found floating at the anterior extremity of the perivisceral cavity, and which is connected with the ventral vessel. Now, about in the place where Lacaze-Duthiers observed the sac-like expansion of the ventral vessel, occurs in *Hamingia* the vascular ramification, connecting together the dorsal and ventral vessels, — which can hardly be a central part, but should rather be regarded as a peripheral section of the circulatory system.

Nervous System.

In the *Gephyreæ*, the nervous system is as a rule easily accessible, — an assertion which also holds good of our new genus.

On removing or pushing aside the intestinal canal, the central nervous chord — of a lustrous white — is distinctly visible, protending along the middle of the ventral surface from mouth to anus, fig. 16, *a*. It is webbed to the ventral mesentery, and invested on its inner surface, which projects into the perivisceral cavity, with peritoneal membrane. It extends accordingly between the peritoneum and the oblique muscular layer.

Den midterste Del af Centralstrængen er noget tyndere end den forreste og bagerste Del, og udsender til begge Sider en Mængde Grene, hvoraf enkelte staa næsten lige overfor hinanden, medens andre alternere, endog med temmelig lange Mellemrum, Fig. 16, *a*. De fleste af disse Grene gaa meget snart ind imellem Hudens Muskellag, hvor de dele sig, enkelte andre kunne forfølges noget længere, førend de tabe sig i Huden. De have ved deres Udspring en næsten horizontal Retning.

Efterhaanden som Centralstrængen kommer længere fortil, bliver den noget tykkere, Fig. 16, *b*; den løber imellem begge Æggebeholderne, Fig. 16, *h, h*, ved Siden af Bugkarret, og afsender lignende Grene til Huden og Mesenteriet, som dens midterste Del, kun have de her en mere skraa Retning. Naar den er kommen lidt foran Æggebeholderne, afgiver den paa hver Side en fin Gren, Fig. 16, *c*, der gaar bag til Udførselskanalen for Æggebeholderne. Den afgiver fremdeles mange fine Grene til Mesenteriet og Huden, indtil den omtrent 3^{mm} fra Mundaaabningen deler sig i to Stammer, Fig. 16, *d*, der gaar hver til sin Side og omfatter den forreste Del af Svælget, hvorefter de forene sig paa dettes Rygside, og danner derved en temmelig vid Ring, hvorfra udgaar Grene til Huden, Mundhulheden og Spiserøret, Fig. 16, *e*.

Bagtil fortsætter Centralstrængen sit Løb ved Siden af Æggestokken, Fig. 16, *f*, som for endel dækker den, og afgiver en Mængde Smaagrener til Huden, samt flere Grene til Mesenteriet og Æggestokken; henimod Anus deler den sig, Fig. 16, *g*, og slaar sig om Endetarmen, hvor begge Grene tabe sig ganske i Bindevævet.

Centralstrængen er fuldstændig uden Knuder eller Ganglier; den har en temmelig fast Skede, indenfor hvilken er et peripherisk cellulært Lag, og et centralt, der er det tykkeste, og bestaar af Nervefibriller. Det periferiske Lag synes at være sammenvoxet med Skeden; noget Kar findes ikke. Grenene ere sammensatte paa lignende Maade, og det har ikke været os muligt at opdage nogen ganglionær Dannelse, ligesaa lidt paa dem, som paa Centralstrængen.

Efter Lacaze-Duthiers Undersøgelser over Nervesystemet hos *Bonellia viridis* synes dette at stemme temmelig overens med hvad vi have fundet hos *Hamingia*; den væsentligste Forskjel ligger i, at hos denne, som ingen Snabel har, nærmer Svælgringen sig mere den for Gephyreerne almindelige.

Professor Greef¹ angiver, at ifølge hans Undersøgelser skal Centralnervestrængen hos *Echiurus Pallasii*, *Thalassema Baronii* og *Bonellia viridis*, samt hos mange børsteløse Gephyreer være uden Ganglier og indesluttet i et

¹ Sitzungsberichte d. Gesellschaft zur Beförderung der gesammten Naturwissenschaften zu Marburg, No. 2, Febr. 1874.

The medial section of the central nervous chord is somewhat thinner than are the anterior and posterior sections, and sends off from either side a multitude of branches, some of which have their points of origin nearly opposite, whereas those of others alternate one with the other, sometimes at considerable intervals, fig. 16, *a*. Most of these branches very speedily pass in between the muscular layers of the skin a few can be traced somewhat farther, before they coalesce with the integument. At the point of issue, they have all of them a well nigh horizontal direction.

Gradually increasing in thickness, fig. 16, *b*, the farther anteriorly it protends, the central nervous chord passes between the two uteri, fig. 16, *h, h*, alongside of the ventral vessel, and sends off to the skin and the mesentery branches of the same kind as those issuing from its mesial section; they take, however, a more oblique direction. A little anterior to the uteri, it sends forth from either side a slender branch, fig. 16, *c*, which strikes off backward to the oviducal canal, or uterine duct. It still continues to furnish the mesentery and the skin with numerous ramifications, till it divides, about 3^{mm} from the buccal aperture, into two principal branches, one on either side, fig. 16, *d*, which, proceeding to the gullet, coil round the anterior portion of that organ, and then unite on its dorsal surface, forming a large ring, from which branches are sent off to the skin, the buccal cavity, and the oesophagus, fig. 16, *e*.

Posteriorly, the central nervous chord protends alongside of the ovarium, fig. 16, *f*, by which it is partly covered, and sends off a multitude of ramifications to the skin, and several branches to the mesentery and the ovarium; in close proximity to the anus, it divides dichotomously, fig. 16, *g*, encircling the rectum, where both branches coalesce with the connective tissue.

The central nervous chord is entirely destitute of nodes or ganglions; it is furnished with a comparatively firm-textured sheath, underneath which extends a peripheral cellular and a central layer, the latter, consisting of nervous fibrils, being the thickest. The peripheral layer would appear to be connate with the sheath: there is no vessel. The branches are built up in like manner; and we have failed to detect any trace of ganglionous organs either on these subsidiary offshoots or on the central chord itself.

The nervous system in *Bonellia viridis*, as described by Lacaze-Duthiers, would appear to agree pretty closely with what we have observed relating to that system in *Hamingia*; the principal difference lies in this, that the latter, which is not distinguished by a proboscis, has the pharyngeal ring nearer in resemblance to that generally met with in the *Gephyrea*.

Professor Greef¹ states, that, according to his observations, the central nervous chord in *Echiurus Pallasii*, *Thalassema Baronii*, *Bonellia viridis*, and in many other asetous Gephyreans, is destitute of ganglions, and enclosed

¹ Sitzungsberichte d. Gesellschaft zur Beförderung der gesammten Naturwissenschaften zu Marburg, No. 2, Febr. 1874.

Blodkar. Hos *Hamingia* have vi ikke iagttaget noget saadant Kar, uagtet vi have ved vellykkede Tversnit havt Anledning til at skjænke dette Punkt vor fulde Opmærksomhed.

Generationsorganerne.

Vi have tidligere omtalt to Æggebeholdere (Uteri), der have deres Leie i den forreste Del af Kropshulheden, Fig. 16, *h, h*. De ere ægformige, 7^{mm} lange, 4^{mm} brede; enhver af dem er forsynet med en Udførselskanal, Fig. 16, *i*, 17, *a*, som er rund, 3^{mm} lang, omtrent 1^{mm} tyk, og som gaar ud igjennem de tidligere beskrevne krumbøiede Papiller paa Bugfladen, i hvis Spids den aabner sig.

Foruden Udførselskanalen har enhver Æggebeholder en tragtformig Kanal, der ligger over Udførselsgangen, hvortil den er fastvoxet i en Strækning af omtrent 2^{mm}, Fig. 16, *k*, 17, *b*; men bliver fri idet den bøier sig indad og nedad imod Bugfladen, Fig. 16, *l*, 17, *c*, og udvider sig nu saaledes, at den frie Ende danner Tragtens brede Del, Fig. 16, *m*, 17, *d*. Denne frie Ende, hvis Rand er indskaaren, foldet og besat med Cilier, Fig. 17, *e*, danner Indgangen til Kanalen, som fører ind til Æggebeholderens Hulhed. Hele Tragtens indre Flade, ligesom Kanalen, er beklædt med et flimrende Epithel. Igjennem Tragten føres de i Kropshulheden svømmende Æg ind i Æggebeholderne, der vare fuldproppede af fuldt udviklede Æg, Fig. 16, *h, h*.

Saa vel Udførselskanalen, som Tragten med dens Indførselsgang bestaar af et fast Bindevævslag, hvis indre mod Lumenet vendende Flade er beklædt med et cilierende Epithel; men hvis ydre Flade støder til en meget stærk Muskelhud, der bestaar af Længde- og Ringfibre, hvilke strække sig udover selve Æggesækkene, der dannes af en temmelig fast, men næsten vandklar Bindevævsmembran, gjennemkrydset af Muskelfibre. Saa vel Æggesækkene, som de med dem i Forbindelse staaende Kanaler ere udvendig beklædte med Peritoneum.

Æggebeholderne ere fæstede til Bugfladen ved enkelte tynde, temmelig lange Bindevævstraade; forresten hænge de frit i Kropshulheden.

Æggestokken er fæstet til en Føld af Bugmesenteriet, Fig. 16, *n, n*, er smal, fladtrykt-baandformig, og strækker sig fra den yderste Ende af Rectum, hvortil den fæster sig, til noget foran Midten af Kropshulheden; den følger Centralnervestrængen, som den næsten ganske skjuler, Fig. 16.

Æggene udvikle sig i Follikelgrupper; saaledes fandtes i den forreste Del af Æggestokken nogle isolerede Follikler, Fig. 16, *o, o*, hvori det begyndende Æg med Kimblære og Kimflæk fandtes, — fuldkommen lig den Udviklingsmaade, der for endel er antydet af Lacaze-Duthiers;

in a blood-vessel. In *Hamingia*, we failed to detect any such vessel, notwithstanding we were happy in our transverse sections of the chord, and took advantage of the opportunity afforded to give this point our full attention.

Generative Organs.

We have previously had occasion to mention two ovarian pouches (uteri), placed in the anterior portion of the perivisceral cavity, fig. 16, *h, h*. They are ovate in form, 7^{mm} long, 4^{mm} broad, and furnished each with an eferent duct, fig. 16, *i*; 17, *a*, which is round, 3^{mm} long, and about 1^{mm} thick; it passes out through the arcuated papillæ on the ventral surface, previously described, at the point of which it opens.

Exclusive of this eferent duct, each uterus has a funnel-shaped canal, protending above the genital duct, with which it is connate for about 2^{mm}, figs. 16, *k*; 17, *l*, becoming however free as it curves inward and downward in the direction of the ventral surface, figs. 16, *l*; 17, *b*, and then expanding in such wise, that the free extremity constitutes the broad part, or mouth, as it were, of the funnel, figs. 16, *m*; 17, *d*. This free extremity which has the margin folded, incised, and furnished with cilia, fig. 17, *e*, constitutes the entrance to the canal leading to the uterine cavity. The whole inner surface alike of the funnel-shaped opening and of the canal itself, is invested with vibratile epithelium; and through this opening it is, that the egg floating in the perivisceral cavity is exuded into the uteri, which in the specimen examined were distended with fully mature ova, fig. 16, *h, h*.

Both the eferent duct and the funnel-shaped canal, with its entrance-passage, are built up of a firm-textured layer of connective tissue, the inner surface of which, facing the lumen, is clothed with ciliated epithelium; its outer surface adjoins an exceedingly strong muscular membrane, composed of longitudinal and annular fibres, protending out beyond the uterine pouches, the walls of which consist of comparatively firm-textured, but almost hyaline connective tissue, intersected by muscular fibres. The uterine pouches, and the ducts and canals with which they are connected, have, investing them externally, a peritoneal tunic.

The uteri are webbed to the ventral surface by a few slender and comparatively long filaments of connective tissue; for the rest, they depend freely in the perivisceral cavity.

The ovary, attached to a fold of the ventral mesentery, fig. 16, *n, n*, is narrow, depressed, riband-shaped, and protends from the outer extremity of the rectum, whereto it is webbed, a little anterior to the middle of the perivisceral cavity, and accompanies the central nervous chord, almost entirely concealing it, fig. 16.

The ova develop in follicular groups; in the anterior part of the ovary were seen, for instance, a few isolated follicles, fig. 16, *o, o*, containing rudimentary ova, with a germinal vesicle and a germinal speck, — their mode of development being that in part suggested by

men som senere har faaet en fuldstændigere Løsning i Vejdovsky's¹ og Spengel's² Afhandlinger over Ægdannelsen og Hannen hos *Bonellia viridis*, og hvortil vi skulle tillade os at henvise for ikke at gjøre os skyldig i Gjentagelser. Længere bag vare Follikelgrupperne talrigere, Æggene mere udviklede, Fig. 16, *p*; i enhver Follikel var et Æg, der udviklede sig af en Centralcelle. Jo længere bag man kom, desto mere ere Æggene udviklede, saa at henimod Æggestokkens bagerste Ende findes de mest udviklede Æg, der ved sin Væxt sprænger Follikelen og falder ud i Kropshulheden, hvor det fuldender sin Udvikling.

Æggestokken hos *Hamingia* lignede en Samling Drueklaser ophængte i et Baand.

Det fuldmodne Æg saaledes som det findes i Æggeholderne og tildels i Kropshulheden har kun en Hinde, som Lacaze-Duthiers og for ganske nylig Dr. Spengel har paavist hos *Bonellia viridis*; den af Schmarda beskrevne anden Hinde eller Membran, hvormed Ægget skulde være omgivet, er utvivlsomt Follikelmembranen.

Indenfor Blommemembranen ligger Kimblæren med Kimplet omgivet af Protoplasmakorn, og udenom disse store Blommekorn, dentoplasmatiske Kugler (se Vejdovsky).

Ingen Hanner have vi fundet, uagtet vi vare meget opmærksomme derpaa.

De ovenfor beskrevne Kjønsorganer afvige forsaavidt fra Bonelliens, som der hos denne kun er en Uterus, imedens *Hamingia* har to. Men derimod nærmer den sig just derved til Slægten *Thalassema*. Omendkjøndt dennes Anatomi, saavidt vi vide, ikke er tilstrækkelig bekjendt, fremgaar dog af de Undersøgelser Max Müller's³ har anstillet over *Thalassema gigas*, at den har 2 Uteri, som Müller rigtignok kalder Ovarier. Han angiver, at de findes paa Bugfladen, ere langstrakte, indtil 2 Tommer lange og have en kort Udførselsgang, der munder ud i to paa den ydre Bugflade siddende yderst smaa Vorter. Paa disse Ovarier har Müller iagttaget en lille Fremstaaenhed, hvorpaa han tror at have seet en lille Aabning.

Diesing⁴ har imidlertid opfattet Forholdet rigtigere, idet han benævner dem Uteri, uden at han dog omtaler

¹ Ueber die Eibildung und die Männchen von *Bonellia viridis*. Franz Vejdovsky. Zeitschrift f. wissensch. Zoologie, 30 B. 1878, pag. 487.

² Dr. J. W. Spengel. Beiträge zur Kenntniss der Gephyreen. Die Eibildung, die Entwicklung u. das Männchen der *Bonellia*. Mittheilungen aus der zoologischen Station zu Neapel. 1 B., 3 Heft, 1879.

³ *Thalassema gigas*, Max Müller. Observ. anat. de vermibus quibusdam maritimis. 1852, pag. 20.

⁴ Revision der Rhyngodeen, Karl Diesing, 1859, pag. 772.

Lacaze-Duthiers, but which, on a subsequent occasion, was made the subject of more exhaustive treatment in Memoirs by Vejdovsky¹ and by Spengel² on the growth of the egg, and the structure and economy of the males, in *Bonellia viridis*; and to these papers we beg leave to refer, with the object of avoiding needless repetition. Farther back, the follicular groups are more numerous, the ova in a relatively advanced stage of development, fig. 16, *p*. In every follicle was an egg, developing from a central cell. The maturity of the ova progressing with their passage down the ovarium, the posterior extremity contains of course the most developed, which, after bursting the follicle, drop through into the perivisceral cavity, and there attain the final stage of development.

The ovary in *Hamingia* resembled bunches of grapes attached to a piece of ribbon.

The fully mature egg, as found in the uteri, — and (some) in the perivisceral cavity, — is enveloped in a pellicle only, which Lacaze-Duthiers, and quite recently Dr. Spengel, have shown to be also the case with *Bonellia viridis*; the second pellicle, or membranaceous envelope, described by Schmarda as investing the egg, is unquestionably the membrane of the follicle.

Underneath the membrane of the yolk, lies the germinal vesicle, with the germinal speck, surrounded by protoplasmatic granula, and without these granula large yolk-globules, dentoplasmatic pellets (*vide* Vejdovsky).

No males were met with, though carefully looked for.

The generative organs described above differ, we see, from those of *Bonellia*, inasmuch as the latter has but one uterine pouch, whereas *Hamingia* is furnished with two uteri. But in thus differing from one congener, the new genus approximates another — *Thalassema*. True, the anatomy of this genus is as yet imperfectly known; but it nevertheless appears from Max Müller's³ investigation of *Thalassema gigas*, that the animal has two uterine receptacles, which Müller, however, terms ovaries. These organs, placed, he states, on the ventral surface, and elongate in form, measuring as much as 2 inches in length, are each furnished with a short eferent duct, that disembogues through 2 minute, wart-like papillæ on the outer ventral surface. On these "ovaries" Müller has observed a small prominence, in which he believes to have detected a minute opening.

Diesing,⁴ however, had a clearer apprehension of the office performed by these organs, and terms them accord-

¹ Ueber die Eibildung und die Männchen von *Bonellia viridis*. Franz Vejdovsky. Zeitschrift f. wissensch. Zoologie, 30 B. 1878, pag. 487.

² Dr. J. W. Spengel. Beiträge zur Kenntniss der Gephyreen. Die Eibildung; die Entwicklung u. das Männchen der *Bonellia*. Mittheilungen aus der zoologischen Station zu Neapel. 1 B., 3 Heft, 1879.

³ *Thalassema gigas*, Max Müller. Observ. anat. de vermibus quibusdam maritimis. 1852, pag. 20.

⁴ Revision der Rhyngodeen, Karl Diesing, 1859, pag. 772.

med et Ord selve Æggestokken, der for ham var ukjendt.

Det er neppe nogen Tvivl underkastet, at de Organer Max Müller kalder Æggestokke ere fuldstændig homologe med de af os beskrevne Æggebeholdere hos *Hamingia*, ihvorvel de i Formen afvige noget; men lægger man Mærke til, at Müller omtaler en lille Fremstaaenhed, paa hvilken han tror at have fundet en Aabning, kan dette neppe være noget andet, end den hos *Hamingia* og *Bonellia* paa Uterus værende Trag, der tjener til at opsamle og lede de i Kropshulheden frit svømmende Æg ind i Æggebeholderen.

Hos *Thalassema* foregaar, efter Semper's og Spengel's Iagttagelser, Ægdannelsen paa en aldeles lignende Maade, som hos *Bonellia*.

Vi mene saaledes at have bevist, at den af os opstillede nye Slægt staar i et nært Forhold til *Thalassema* og *Bonellia*; men ser man hen til, at der hos vor Slægt, baade i de ydre Karakterer og i Anatomien er størst Fællesskab med *Bonellia*, tørde det være et Spørgsmaal om den ikke i phylogenetisk Henseende staar i den inderligste Rapport til denne. *Hamingia* bærer virkelig Spor af en fordums Snabel, der tør være forsvunden, og ved hvis Forsvinden naturligvis saavel Circulations- som Nervesystemet maatte undergaa nogen Forandring, hvilket jo viser sig at være Tilfældet, idet den kredsformige Dannelse af de nævnte Systemer, hvilken foregaar i Snabelen hos *Bonellia*, træder op hos *Hamingia* under Form af en Nervering og Blodkar-ring, der omgive den forreste Del af Spiserøret.

Kan det antages, at *Bonellia* oprindeligt har havt to Uteri, hvilket kan være rimeligt nok, da den ene har et meget usymmetrisk Leie, og kommer dertil, at Lacaze-Duthiers har fundet hos et Exemplar 2 Uteri, som han forresten angiver som ganske exceptionelt, — saa er det ikke noget ukjendt, at det tabte Orgau atter optræder i en højere Afstamning, og vi ere tilbøjelige til at antage, at *Hamingia* staar noget højere i Organisationsrækken end *Bonellia*.

Hamingia arctica lever paa sandholdig Lerbund, bevæger sig temmelig meget ved Krumninger i forskellige Retninger, uden at gjøre nogen synderlig Fremgang.

Farven er mørk græsgrøn, naar Dyret er sammentrukket, men bliver lysere med enkelte mørkere Partier, naar det er udspændt, og da bliver Huden saa gjennemsigtig, at en Del af Tarmkanalen kan sees. Mundskiven med Mundlæberne ere næsten hvide, spillende lidt i det Gule, ligeledes de lange cylindriske, krumbøiede Papiller paa Bugfladen.

Kun et Exemplar blev fundet paa Station 290.

Slægtskarakter.

Legemet valseformigt. Munden paa den forreste Ende, nærmere Bugfladen. Analaabningen i Centrum af den

Den norske Nordhavsexpedition. Danielssen og Koren: Gephyrea.

ingly *uteri*, though he does not even allude to the true ovary, of whose existence indeed he knew nothing.

Meanwhile, it will hardly admit of doubt, that the organs by Max Müller termed ovaries are strictly homologous with the uteri, or uterine pouches, in *Hamingia*, though slightly different as to form; but calling to mind the minute papilla mentioned by Müller, and in which he believes to have detected an opening, the latter must assuredly be the funnel-shaped aperture which in *Hamingia* and *Bonellia* serves for the reception of the ova floating in the perivisceral cavity, and to afford them egress on their passage into the uterine pouch.

In *Thalassema*, according to Semper's and Spengel's observations, the ova are developed precisely as in *Bonellia*.

Hence we conceive to have shown, that the genus established in this Memoir is closely allied alike to *Thalassema* and to *Bonellia*; but whereas *Hamingia*, both as regards its habitus and anatomical structure, exhibits greatest resemblance to *Bonellia*, it is a question whether, phylogenetically too, the new genus will not prove to have most intimate relations with that animal. For *Hamingia* does indeed retain traces of a proboscis, once distinguishing the genus *Bonellia*, and the loss of which must naturally to some extent have modified the characteristics of the circulatory and nervous systems. And this is found to be the case; for the semi-circular formation of the said systems in the proboscis of *Bonellia*, occurs in *Hamingia* as a nervous ring and an annular vascular blood-vessel, which represent together the anterior portion of the œsophagus.

Now, assuming *Bonellia* to have had originally two uterine pouches, — for the single uterus with which it is now furnished is anything but symmetrical in position, — and calling to mind, too, that Lacaze-Duthiers records his having once found two *uteri* in a specimen of this genus (quite an exceptional case, however, in his opinion) — science is not without instances in point showing the organ thus lost to have developed again in a congener of higher extraction; and we are indeed disposed to regard *Hamingia* as ranking above *Bonellia* in the scale of organisation.

Hamingia arctica affects a bottom of sabulous clay, moves about a good deal in disrupted curves, without however making much progress.

Colour, when the animal is contracted, a dark grassy-green, but lighter, with a few darkish patches, when it blows itself out; the skin is then so translucent, that part of the intestinal canal may be seen through it. Buccal disk and lips almost white, with a faint tinge of yellow; likewise the long, cylindrical, arcuate papillæ of the ventral surface.

One example only, at Station 290.

Generic Character.

Body cylindrical; mouth at the anterior extremity, nearest the ventral surface. Anal opening in the centre

bagerste Ende. En halvmaaneformig, lidt fremragende Fold omkring Munden (Rudiment af Snabel). Paa Bugfladens forreste Del to cylindriske, lange Papiller, paa hvis Spids en rund Aabning for Æggebeholdernes Udførselsgang.

Ingen Børster.

Tarmrøret danner Slynger, men ingen Spiral og ender i en Kloak, fra hvis begge Sider udgaar et forgrenet Kjer-telapparat.

Centralnervestrængen glat, uden Ganglier.

En Æggestok, der ligger langs Nervestrængen i den bagerste Halvdel af Kropshulheden.

To Uteri med deres Udførselsgang og Tragt.

Hannen ukjendt.

Artskarakter.

Legemet valseformigt, glat, 120^{mm} langt, 20^{mm} tykt, antager under Kontraktioner forskellige Former. Farven lysere eller mørkere græsgrøn med hvidgul Mundskive. De krumbøiede Papiller paa Bugfladen grønne med hvidgule Ender.

*Saccosoma*¹ *vitreum*, n. g. & sp.

Tab. VI, Fig. 1—8.

Legemet kolbeformigt; den forreste smale forlængede Del, Fig. 1, 2, *a*, er cylindrisk, 12^{mm} langt, omtrent 5^{mm} bredt ved Grunden og 1.5^{mm} i Spidsen, hvor den runde, temmelig vide Mundaabning findes, Fig. 1, 2, *b*, der er omgivet med en Vold, hvorfra stærke Længdefolder strække sig ned i Spiserøret. Lidt bagenfor Mundaabningen sees paa Bugsiden en lille Papille, paa hvis Midte er en fin Aabning.

Huden er paa denne cylindriske Del uigjennemsigtig, tyk, fast og rynket. Legemets bagerste Del er næsten kuglerundt, Fig. 1, 2, *c*, 18^{mm} langt og 12—14^{mm} bredt.

Huden er overordentlig tynd, fuldkommen glasklar, saa at den af mangfoldige Slyngninger bestaaende Tarm sees som om den laa blottet; kun paa den bagerste Ende, der er konisk, Fig. 2, *d*, og paa hvis Spids den runde Analaabning, Fig. 2, *e*, findes, er Huden ligesom paa Kroppens forreste forlængede Del tyk, fast og uigjennemsigtig.

¹ Σάχος = Sæk; σῶμα = Legeme.

of the posterior extremity. A lunate, somewhat prominent fold round the mouth (rudimentary proboscis). On the anterior portion of the ventral surface two long, cylindrical papillæ, having each at the apex a round aperture for the eferent duct of the corresponding uterus.

No bristles.

The intestinal canal with numerous circumvolutions, but no spiral coil; it disembogues into a cloacum, from both sides of which issues a ramifying glandular apparatus.

The central nervous chord smooth, destitute of nodes or ganglions.

One ovary, protending along the nervous chord in the posterior half of the perivisceral cavity.

Two uteri, each with an eferent duct and funnel-shaped tube.

The male as yet unobserved.

Specific Character.

Body cylindrical, smooth, 120^{mm} long, 20^{mm} thick, repeatedly changing its form as it contracts and expands. Colour a lighter or darker grassy green. Buccal disk whitish-yellow; the arcuate papillæ on the ventral surface greenish, with whitish-yellow extremities.

*Saccosoma*¹ *vitreum*, n. g. & n. sp.

Pl. VI, fig. 1—8.

Body cucurbit-like in form; the anterior, slender, produced portion cylindrical, figs. 1; 2, *a*, 12^{mm} long, about 5^{mm} broad at the base, and 1.5^{mm} broad at the apex, which is pierced with the round and comparatively wide buccal aperture, figs. 1; 2, *b*, surrounded by a cutaneous ridge, from which prominent longitudinal folds protend downwards into the œsophagus. A little posterior to the buccal aperture on the ventral surface, is seen a small papilla, with a minute opening in the middle.

The skin covering this cylindrical portion is opaque, thick, firm-textured, and rugose. The posterior portion of the body is almost globular, figs. 1; 2, *c*, 18^{mm} long and 12—14^{mm} broad.

The skin is remarkably thin, and hyaline, giving to the numerous circumvolutions of the intestine the appearance of being denuded; only on the posterior, acuminate extremity, fig. 2, *d*, pierced at the apex with the round anal opening, fig. 2, *e*, and on the anterior produced portion of the trunk, is the integument thick, firm-textured, and opaque.

¹ Σάχος: sack; σῶμα: body.

Huden er, som tidligere angivet, opak, tyk og fast paa den forreste og bagerste Ende, imedens den paa Lege-mets næsten kuglerunde Del er yderst tynd og glasklar; men overalt har den omtrent samme histologiske Bygning. Den dannes af en tynd Cuticula, der paa et Tversnit af den tykke Hud viser sig stærkt foldet, Fig. 5, *a*, og det paa en saadan Maade, at Folderne faa et guirlandeformigt Udseende, Fig. 5. Lignende Folder findes ogsaa hos *Echiurus Palasii* efter Greeff's Angivelse¹.

Indenfor Cuticula er et Epithellag af temmelig korte, klare Cylinderceller, Fig. 5, *b*, der støde til et meget tyndt, hyalint Bindevævslag, hvori spredte Bindevævslegemer sees, Fig. 5, *c*, og hvortil Muskelhuden er fæstet. Denne bestaar af Ringmuskler, Fig. 5, *d*, og Længdemuskler, Fig. 5, *e*.

Ringmusklerne ligge som sædvanligt yderst, nærmest Bindevævslaget, ere temmelig tykke og danne en sammenhængende Hud.

Længdemusklerne ere distinct adskilte, saa at hver Muskelbundt tager sit Udspring fra Mundringen og gaar bag til den klare sækformige Kropsdel, Fig. 3, *a*; 4, *a*, hvor det deler sig for at gaa over paa denne. Imellem hver Længdemuskel er et temmelig tykt Bindevæv, der holder Muskelbundterne sammen². Dette gjælder nu den forreste Kropsdel, hvor Huden er tyk og uigjennemsigtig; men anderledes forholder det sig paa den glasklare sækformige Del. Her vige Fibrene stærkt fra hverandre, forgrene sig og danne Anastomoser paa den Vis, at Grene fra Ringmusklerne, Fig. 6, *a*, tage en skraa Retning, løbe over Længdemusklerne, Fig. 6, *b*, og danne paa større Strækninger ligesom et Skraamuskellag, Fig. 6, *c*, der ligger indenfor Længdemusklerne og synes at tabe sig i tilstødende Ringmuskelfibre.

Fra Længdemusklerne udsendes ligeledes Grene, og mange af disse anastomosere med Grene fra Ringmusklerne. Der dannes paa denne Maade et fuldkommen muskuløst Netværk, Fig. 6, der indtager hele den kugledannede Kropsdel lige til den bagerste opake, fremstaaende Ende, hvor Muskelfibrene atter ordne sig i to bestemte sammenhængende Lag ligesom paa den forreste Kropsdel, kun med den Forskjel, at Længdemusklerne ikke som der ere distinct adskilte, men danne en sammenhængende Hud.

Imellem Muskelmaskerne paa Sækken og Cuticula sees et yderst tyndt, hyalint Bindevæv, hvori Kjerner, samt et tyndt Lag Epithelceller, hvilke ere Fortsættelser af Bindevævs- og Epithellaget, som findes i den forreste, opake Kropshud. Da denne Hud, der danner Sækken, er overordentlig tynd som det fineste Silkepapir, og dertil fuldstændig glasklar, var det ikke muligt, selv ved stærk mikro-

The skin is, we say, thick, firm-textured, and opacous on the anterior and posterior extremities, and on the well nigh globular portion of the body exceedingly thin, and translucent; but everywhere it has very nearly the same histological structure. It consists of a thin cuticle, which, on making a transverse section of the thick integument, is found to be prominently folded, fig. 5, *a*, the folds presenting a wreathed or belted appearance, fig. 5. Similar folds occur, according to Greeff,¹ in *Echiurus Palasii*.

Underneath the cuticle extends an epithelial layer of comparatively short, translucent, cylindric cells, fig. 5, *b*, adjoining an exceedingly thin, hyaline layer of connective tissue, webbed to the muscular integument, and scattered throughout which are seen corpuscles of connective tissue, fig. 5, *c*. The muscular membrane is composed of annular muscles, fig. 5, *d*, and longitudinal muscles, fig. 5, *e*.

The annular muscles lie as usual outermost, nearest the layer of connective tissue, are comparatively thick, and constitute a continuous integument.

The longitudinal muscles are distinctly separate, each muscular fascicle issuing from the buccal ring, and protending backwards to the hyaline sac-like portion of the body, figs. 3, *a*; 4, *a*, where they divide, branching across on to the latter. Between every pair of longitudinal muscles extends a comparatively thick connective tissue, banding together the muscular fascicles,² i. e. on the anterior region of the body, which has the skin thick and opaque; with the hyaline sac-like portion the case is different. Here the fibres diverge very considerably, ramify, and anastomose, in such wise that branches from the annular muscles, fig. 6, *a*, protending obliquely and intersecting the longitudinal muscles, fig. 6, *b*, form an extensive oblique layer, fig. 6, *c*, lying underneath the longitudinal muscles, and apparently coalescing with the adjacent annular fibres.

Branches proceed, too, from the longitudinal muscles, many of them anastomosing with branches from the annular muscles. Thus is produced a complete muscular network, fig. 6, extending over the whole of the globular portion of the body to the posterior, opaque, projecting extremity, where they are again arranged in two distinct continuous layers, as on the anterior portion of the body, with this difference, however, that the longitudinal muscles are not distinctly separate, but constitute a continuous membrane.

Between the muscular meshes on the sac and the cuticle, is seen an exceedingly thin, hyaline web of connective tissue, with nuclei scattered throughout it, and a thin layer of cellular epithelium, prolonged from the epithelial layer and the layer of connective tissue in the anterior opaque skin of the body. The skin constituting the sac being thin as tissue-paper, and moreover perfectly hyaline, it was impossible

¹ R. Greeff. Ueber den Bau und die Entwicklung der Echiuren. Archiv für Naturgeschichte. 43 Jahrgang, 3 Heft, pag. 343, Berlin 1877.

² Hos *Thalassema Baronii* har Greeff paavist noget lignende.

¹ R. Greeff. Ueber die Bau und die Entwicklung der Echiuren. Archiv für Naturgeschichte. 43 Jahrgang, 3 Heft, pag. 343, Berlin 1877.

² Something similar to this Greeff has observed in *Thalassema Baronii*.

skopisk Forstørrelse (Gunlach Im. No. 7, Oc. 1) at iagttage nogensomhelst Organisation; først ved Farvning af en Opløsning af Picrokarmin, differentserede de forskellige Væv sig. Indenfor Muskelhuden er Peritonealovertrækket.

Fordøielsestragten tager sin Begyndelse ved den runde Mundaabning, der er omgivet af en Vold, som væsentlig dannes af Ringmusklærne, Fig. 3, *b*.

Spiserøret er cylindrisk, Fig. 3, *c*, lidt videre ved Mundatriet, omtrent 8^{mm} langt, og har en tyk, fast, hvidrøddig Hud, der dannes af de sædvanlige Lag, dog saaledes, at Muskelhuden, der bestaar af Ring- og Længdemuskler, er meget tyk; indenfor denne er et kjerneagtigt Bindevæv, der danner listeformige Fremspring, som foranlediger de paa den indre Flade af Spiserøret langsgaaende Folder. Til dette Bindevæv er Epithellaget fæstet, som bestaar af temmelig lange Cylinderceller, hvoraf mange have foruden sin Kjerne et rigt kornet Indhold, og muligens fungere som Kjertler.

Naar Spiserøret, der ved stærke Bindevævstraade er bundet til Kropsvæggen, har naaet bag imod den glasklare Kropsdel, udvider det sig og danner en aflang Sæk, der ligeledes er stærk muskuløs og kan betragtes som en Mave, Fig. 3, *d*, hvis Vægge blive tyndere, idet den gaar over i Tarmen, Fig. 3, *e*, uden at der egentlig er nogen Indsnoring.

Tarmen bliver nu temmelig smal, dreier sig mod Høire, hvorfra den bøier sig og gaar til Venstre; paa denne Vei ere dens Vægge blevne alt tyndere og tyndere; men fra nu af gjør den en Mangfoldighed af Slyngninger, saa den ganske udfylder den glasklare, kugleformige Del, Fig. 2, *f*; 3, *f*, paa samme Tid som dens Vægge blive saa tynde, at det ser ud som der ingen Tarm var. Naar den paa denne Vei har naaet den bagerste Del af Kropshulheden gaar den over i en kort Rectum, Fig. 3, *g*, der ender med sin runde Anaabning paa Midten af den lidt fremstaaende koniske Bagdel, Fig. 2, *e*.

Endetarmens Vægge ere tykke og faste, omtrent som Spiserørets, og dens ydre Flade er ved en Mængde temmelig stærke, tendinøse Baand bundet saavel til den glasklare Sæks indre Væg, som til den koniske Fremstaaenheds indre Flade, Fig. 3, *h*, imedens dens ydre Rand, der danner Anus, er omgivet af en stærk Sphincter.

Muskelhuden paa Tarmen er, naar undtages Rectum, særdeles tynd, og Muskelfibrene i begge Lag staa meget langt fra hverandre. Paa Rectum derimod ere de tykke og sammenhængende.

Tarmens indre Flade er beklædt med et lignende Epithel, som Spiserørets, kun staa Cylindercellerne længere fra hverandre; men ogsaa her havde mange det førømtalte kornede Indhold.

Tarmen var ganske opfyldt af Excrementer; disse bestode af Boli, der havde en elliptisk Form, og vare paa Midten saa tykke, at en saadan Bolus udfyldte ganske Tarmen, Fig. 3, 7.

to detect, even with a powerful microscope (Gunlach Im. No. 7, Oc. 1), any structural appearance whatever; not till a portion had been tinted in a solution of picrocarmine, could the several species of tissue be observed. Underneath the muscular membrane extends the peritoneal tunic.

The alimentary canal originates at the round buccal aperture, which is encompassed by a ridge, chiefly consisting of annular muscles, fig. 3, *b*.

The œsophagus is cylindrical, fig. 3, *c*, a trifle wider at the buccal atrium, about 8^{mm} long, and has a thick, firm-textured whitish-red skin, built up of the usual layers, the muscular integument, composed of annular and longitudinal muscles, being however very thick. Underneath this integument extends a layer of nucleal connective tissue, forming cornice-like projections, which give rise the longitudinal folds on the inner surface of the œsophagus. To this connective membrane is webbed the epithelial layer, composed of comparatively long cylindrical cells, many of which contain, exclusive of the nucleus, a granulous substance, and possibly perform the function of glands.

On the œsophagus, which is webbed by strong filaments of connective tissue to the wall of the body, reaching back towards the hyaline portion of the latter, it expands, forming an oblong sac, also highly muscular, and which may be regarded as a stomach, fig. 3, *d*, with walls of diminished thickness where it passes into the intestine, fig. 3, *e*, though there is no instriction.

The intestine now becomes comparatively slender, swerves to the right, then makes a bend, striking off to the left, its walls getting thinner and thinner; but it now commences a series of circumvolutions, entirely filling up the hyaline globular portion, figs. 2, *f*; 3, *f*, and its walls become so thin, that it almost loses the appearance of an intestine. On thus reaching the posterior portion of the perivisceral cavity, it opens into a short rectum, fig. 3, *g*, terminating in the round anal aperture, which occupies the centre of the acuminate and slightly projecting posterior portion, fig. 2, *e*.

The walls of the rectum are thick and firm-textured, much the same as those of the œsophagus; and its outer surface is webbed by numbers of comparatively strong tendinous bands both to the inner wall of the hyaline sac and to the inner surface of the acuminate prominence, fig. 3, *h*, whereas its outer margin, forming the anus, is surrounded by a powerful sphincter.

The muscular integument of the intestine, excepting on the rectum, is exceedingly thin, and the muscular fibres in both layers lie far apart; on the rectum, they are thick and contiguous.

The inner surface of the intestine is invested with epithelium similar to the layer on the œsophagus, saving that the cylindric cells are more dispersed; but here, too, many of them contained the above-mentioned granulated substance.

The intestine was quite full of fæcal boli, elliptic in form, and so thick in the middle that one bolus sufficed to fill out the intestine, figs. 3; 7.

Man kan gjøre sig et Begreb om hvor tynd Tarmens Vægge var, naar vi sige, at det var en Stund, vi troede der ingen Tarm var, da denne var løsreven fra Rectum; men at hele Dyrets Bagdel udgjorde en Sæk for Excrementerne. Ved stærk Loupe kunde man dog imellem hver Bolus se en florfin Hinde, der var Tarmvæggen.

De særegent formede Excrementer dannes sandsynligvis idet Føden passerer Spiserørets bagre udvidede Del (Maven); thi lige der hvor denne gaar over i den egentlige Tarm laa en Bolus, imedens der i Spiserøret kun var den lerholdige Sand, hvori fandtes en Mængde Foraminiferer.

Centralnervestrængen løber som en fin gulhvid Traad, Fig. 4, *b*, langs den uigjennemsigtige forreste Kropsdels Midte, under Spiserøret, og følger dette til dets forreste Ende, hvor den slaar sig om Svælget og sandsynligvis danner en Ring. Paa denne Vei afgiver den mange Sidegrene til Spiserøret og Huden.

Det er ikke alene Hudens Muskler, der forsynes med Grene, men mange af disse forlænge sig igjennem Bindevævet ud i Epithelet lige under Cuticula, hvor de fine Ender dels tabe sig imellem Cylindercellerne, dels gaa over i aflange, næsten kølleformede Legemer, der ere forsynede med en stor Kjerne, og som vel maa betragtes som Organer, der staa i Følelsens Tjeneste, Fig. 5, *f*. Disse fine periferiske Nervegrene danne i deres Løb smaa ganglieformige Knuder, som have en stor Kjerne omgivet af Protoplasma, Fig. 5, *g*, og fra hvilke udgaa snart en, snart flere Grene, der hyppig anastomosere med tilsvarende Grene fra andre Ganglier.

Det er ikke lykkedes os, trods al anvendt Møie, at forfølge Centralnervestrængen længere bag i den glasklare Sæk, eller paa Tarmen, ihvorvel det er sandsynligt, at den langs Sækkens indre Flade strækker sig bag imod Rectum.

Kjønnsorganerne bestaa hos vort Individ af Æggestokken og en Æggebeholder (Uterus). Æggestokken ligger langs Centralnervestrængen, Fig. 4, *c*, og tager sin Begyndelse et Par Millimeter bagenfor Mundaabningen. Den dannes egentlig af en Fold af det Mesenterium, som binder Svælget til Kropsvæggen og ender noget bagenfor den glasklare Kropsdels Begyndelse.

Æggestokken er sammensat af en stor Mængde næsten pæreformede Follikler, Fig. 8, der bestaa af en klar Membran, hvori sees Bindevævslegemer, Fig. 8, *a*, og hvis indre Flade er beklædt med store Celler, Fig. 8, *b*. I den smalle Del af Follikelen saaes et begyndende Æg, omgivet ligesom af en Krands Celler. Vi saa kun Antydninger til Æg i Folliklerne.

Efter alt at dømme foregaar Æggets Udvikling paa

It will give some idea of the extreme thinness of the intestinal walls, that we were actually in doubt at first whether there was an intestine (it had been detached from the rectum), conceiving the whole posterior portion of the animal to constitute a receptacle for the fæces. With a strong magnifier could be just distinguished between the boli a gauzy pellicle, — and this was the wall of the intestine.

Probably the peculiar form into which the fæces are moulded, may be traced to the passage of the food through the posterior distended portion of the oesophagus (the stomach); for, exactly where that organ passes into the intestine lay a bolus, the contents of the oesophagus consisting exclusively of argillaceous sand, in which were numbers of Foraminifera.

The central nervous chord protends as a slender yellowish-white filament, fig. 4, *b*, along the middle of the anterior opaque portion of the body, underneath the oesophagus, accompanying that organ to its anterior extremity, where it winds round the gullet, forming probably a ring. On its course it sends off numerous subsidiary branches to the oesophagus and the skin.

Not only is it the muscles of the skin that are furnished with branches, — many of these offshoots, piercing the connective tissue, pass on into the epithelium, immediately beneath the cuticle, where their delicate extremities either coalesce with the cylindric cells, or expand into elliptic, more or less clavate corpuscles, furnished with a large nucleus, and which may, we think, be regarded as organs subservient to the sense of touch, fig. 5, *f*. These slender peripheral nervous branches form on their course numerous ganglionous nodules, with a large nucleus embedded in protoplasma, fig. 5, *g*, and from which proceed one or more branches, that frequently anastomose with corresponding branches from other ganglions.

We have failed, notwithstanding a most careful microscopic examination, to trace the central nervous chord farther back in the hyaline sac, or on the intestine, though it probably passes along the inner surface of the sac towards the rectum.

The generative organs consist in our specimen of the ovary and one uterus. The ovary protends along the central nervous chord, fig. 4, *c*, and takes its origin a millimetre or two posterior to the buccal aperture. It consists properly of a fold of the mesentery that webs the gullet to the wall of the body, and terminates a little posterior to the commencement of the hyaline portion of the body.

The ovary is built up of large numbers of almost pyriform follicles, fig. 8, consisting of a translucent membrane, in which are seen corpuscles of connective tissue, fig. 8, *a*, and whose inner surface is covered with large cells, fig. 8, *b*. In the narrower portion of the follicle, was seen a rudimentary egg, surrounded by a cincture, as it were, of cells. We saw none but incipient ova in the follicles.

Judging from analogy, there is every reason to believe

samme Maade, som den der er beskrevet af Vejdovsky¹ og senest af Spengel².

Æggebeholderen, Uterus, er langstrakt, næsten ægformig, noget fladtrykt, Fig. 4, *d*, og indtager omtrent den nederste Halvdel af den forreste opake Kropsdels venstre Side. Den bestaar af en gjennemsigtig, temmelig fast Membran, hvis udvendige Flade er beklædt af Peritoneum; indenfor denne er et Bindevævslag, hvortil Muskellaget, der udgjør Tver- og Længdefibre, som krydse hverandre, er bundet. I Hulheden laa fuldt udviklede Æg, to ved Siden af hinanden, Fig. 4, *e*, saa at Bredden af Hulheden indtages af 4 Æg, og det samlede Antal udgjorde omtrent 25.

Fra den nederste Del af Uterus' undre Flade tog Udførselsgangen sin Begyndelse, snoede sig korktrækkerformig langs den nævnte Flade op til den forreste Rand, forlod nu Uterus og løb langs Spiserørets venstre Side paa Bug siden, Fig. 4, *f*, fortil mod dettes forreste Ende, hvor den gjennemborer Huden og udmunder i den før beskrevne lille Fremstaaenhed, lidt bagenfor Mundaabningen. I Udførselsgangen saaes et Par Æg nær Udgangen, Fig. 4, *g*.

Fra den forreste Rand af Uterus, noget til Høire, udgaar en kort, tyk Kanal, der bøier sig noget mod Bugfladen over Centralnervestrængen, hvor den udvider sig tragtformigt og former derved en temmelig vid Aabning, som er Indgangen for de i Kropshulheden fri blevne Æg, der igjennem den føres ned i Uterus.

Æggene i Uterus vare fuldt udviklede; de bestod af en enkelt, temmelig tyk Membran. Blommen, der havde sin Kimblære og Kimplet, var grønlig, og Kornene lignede meget Chlorophylkorn. Saavel Uterus, som dens begge Kanaler vare ved fine Bindevævstraade bundne til den indre Kropsvæg, og kun Tragten var frit flotterende.

Farven.

Den forreste, uigjennemsigtige Kropsdel er hvid, spillende lidt i det Bleg-rosenrøde. Den sækformige, glasklare Del er farvefri; men den bagerste, koniske Endespids er hvid, som den forreste Del.

Kun et Exemplar paa Station 40.

Slægtskarakter.

Legemet kolbeformigt. Den forreste Del cylindrisk, uigjennemsigtig, med en rund Mundaabning paa den fri

¹ Vejdovsky, F. Ueber die Eibildung und die Männchen von *Bonellia viridis*. Zeitschrift f. w. Zoologie. 30 Band, pag. 487. Leipzig 1878.

² Spengel, J. W. Beiträge zur Kenntniss der Gephyreen. Mittheilungen aus der Zoologischen Station zu Neapel. 1 Band, 3 Heft, pag. 357. Leipzig 1879.

that the egg develops in the manner described by Vejdovsky,¹ and latest by Spengel.²

The ovarian pouch (uterus) is elongate, well nigh oval, slightly depressed, fig. 4, *d*, and occupies about the lower half of the left side of the anterior opaque portion of the body. It consists of a translucent, comparatively firm-textured membrane, the outer surface of which is invested with peritoneum; underneath the latter extends a layer of connective tissue, to which is webbed the muscular layer, composed of transverse and longitudinal intersecting fibres. In the cavity lay fully developed ova, two side by side, fig. 4, *e*, 4 eggs abreast corresponding to the width of the cavity; the total number amounted to about 25.

From the inferior portion of the under surface of the uterus issues the genital duct; it winds spirally along the said surface up to the anterior margin, then diverges from the uterus, protending along the left side of the œsophagus, on the ventral surface, fig. 4, *f*, towards the anterior extremity of that organ, where it perforates the integument, disemboing a little posterior to the buccal aperture into the small prominence described above. In the genital duct were seen two eggs near the outlet, fig. 4, *g*.

From the anterior margin of the uterus, a little to the right, issues a short, thick canal, which makes a slight bend across the central nervous chord in the direction of the ventral surface, where it expands, forming a comparatively wide, funnel-shaped opening, through which the eggs pass from the perivisceral cavity down into the uterus.

The ova in the uterus were all mature. They consisted of a single, comparatively thick membrane. The yolk, furnished with a germinal vesicle and a germinal speck, was of a greenish hue; the granules bore a close resemblance to those in *Chlorophyl*. Both the uteri and its two canals were webbed to the wall of the body by slender filaments of connective tissue; the funnel alone floated free.

Colour.

The anterior opaque portion of the body white, shot with a faint tinge of pale rosy red. The sac-like, hyaline portion colourless; but the posterior conical apex is, like the anterior part, white.

One specimen only: at Station 40.

Generic Character.

Body cucurbit-like in form. The anterior portion cylindrical, opaque, with a round buccal opening at the free

¹ Vejdovsky, F. Ueber die Eibildung und die Männchen von *Bonellia viridis*. Zeitschrift f. w. Zoologie. 30 Band, pag. 487. Leipzig 1878.

² Spengel, J. W. Beiträge zur Kenntniss der Gephyreen. Mittheilungen aus der Zoologischen Station zu Neapel. 1 Band, 3 Heft, pag. 357. Leipzig 1879.

Ende. Den bagerste Del, optagende hele Tarmkanalen, næsten kuglerund, glasklar, endende i en opak Conus, paa hvis Spids Anus. Æggestokken i den forreste Del af Kropshulheden. Ingen Børster.

Artskarakter.

Kroppens forreste, cylindriske, opake Del 12^{mm} lang; den bagerste glasklare, kugleformige Del 18^{mm} lang, 12 til 14^{mm} bred. Farven er hvid paa den forreste Kropsdel, spillende lidt i det Blegrøde, og paa den koniske Ende, imedens den kuglerunde, glasklare Del er farvefri.

Ogsaa her ere vi i det beklagelige Tilfælde at maatte gjøre Undskyldning for den mindre fuldstændige Beskrivelse, vi have leveret; thi kun et enkelt Exemplar stod til vor Tjeneste, og da Dyret baade er lidet og paa Grund af dets Zarthed yderst vanskeligt at behandle, have de anatomisk-histologiske Undersøgelser været meget møisommelige, saa ufuldkomne de end ere blevne. Men *Saccosoma vitreum* er jo i sin Form en saa mærkelig Gephyre, at vi ikke kunne undlade at beskrive den; og det eneste Exemplar er derfor saagodtsom ganske ofret paa Videnskabens Alter.

Vi have henført dette høist mærkelige Dyr til Familien *Bonellidæ*, ihvorvel det i flere Henseender afvige derfra; men naar vi ikke vilde danne en ny Familie for det, hvortil vi for Tiden ingen tilstrækkelig Grund finder, maatte vi blive staaende ved den nævnte Familie, hvortil det mest nærmer sig.

*Epithetosoma*¹ *norvegicum*, n. g. & sp.

Tab. VI, Fig. 9—15.

Kroppen er cylindrisk, 12^{mm} lang, 2^{mm} bred med en lidt tykkere afrundet Forende, Fig. 9, *a*, hvorfra udgaar et Appendix (Snabel), der danner et hult halvgjennemsigtigt Rør, Fig. 9, *b*, som er 30^{mm} langt, omtrent 1^{mm} tykt ved Grunden og 0.8^{mm} i den øvrige Længde, indtil den yderste Spids, der er lidt tyndere; og hvori Røret ender blindt.

Kroppen smalner successivt af mod den bagerste Ende, der er konisk afrundet, og paa hvis Spids findes den runde Analaabning.

Strax bagenfor Snabelens Grunddel findes paa hver Side af Kroppen en Spalte, Fig. 13, *a*, der er omtrent 2.5^{mm} lang, har en lidt krum Retning, saa at den forreste Ende, der er den smaleste, bøier noget af mod Rygsiden;

¹ ἐπιζέτον = Tilhæng; σῶμα = Legeme.

extremity. The posterior portion, containing the whole of the intestinal canal, almost globular, hyaline, terminating in an opaque conus, at the apex of which is the anal aperture. The ovary in the anterior portion of the perivisceral cavity. No bristles.

Specific Character.

The anterior cylindrical opaque portion of the body 12^{mm} long; the posterior, hyaline, globular portion 18^{mm} long, 12 — 14^{mm} broad. Colour white, shot with pale red, on the anterior portion of the body and on the conical apex; the globular, hyaline portion colourless.

Of this genus, too, our description is in some respects we regret to say, confessedly incomplete, referring as it does to a single specimen, the only one yet obtained. Besides, the small size and delicate organisation of the animal necessitating the greatest care in handling, its anatomical-histological investigation, however incomplete, has proved a toilsome and perplexing task. But *Saccosoma vitreum* is in form and structure a Gephyrean so truly remarkable, that we could not resist the call to describe it; and a unique specimen of a new genus has, we may say, been sacrificed to the paramount claims of Science.

We have referred this very curious animal to the family *Bonellidæ*, — with which, though differing from it in many important points, *Saccosoma* has most in common — since we are not at present prepared with conclusive reasons warranting the establishment of a new family for its reception.

*Epithetosoma*¹ *norvegicum*, n. g. & sp.

Pl. VI, figs. 9—15.

Trunk cylindrical, 12^{mm} long, 2^{mm} broad, with a somewhat thicker rounded anterior extremity, fig. 9, *a*, from which protends an appendix (the proboscis), constituting a hollow, semi-translucent tube, fig. 9, *b*, 30^{mm} long and about 1^{mm} thick at the base; elsewhere 0.8^{mm} throughout its length to the extreme point, which is a trifle slenderer, and in which the tube terminates cæcally.

The trunk gradually narrows towards its posterior extremity, which is conically rounded, and pierced at the point with the round anal opening.

Immediately posterior to the basal portion of the proboscis, on either side of the trunk, is seen a cleft or fissure, fig. 13, *a*, about 2.5^{mm} in length, and somewhat arcuate, the anterior extremity, which is narrower than the

¹ ἐπιζέτον: appendage; σῶμα: body.

den har temmelig tykke Læber, som ligge næsten til hinanden, uden ganske at slutte sig sammen.

I Bunden af denne Spalte syntes der at være flere fine Aabninger, men som paa Grund af Dyrets Opbevaring i Spiritus vare saa sammentrukne, at de ikke med Bestemthed kunde sees, selv med stærk Loupe.

Bagenfor Tilhængets Grund paa Bugfladen iagttoges den runde Mundaabning, Fig. 13, *b*, der er stærkt foldet, og lidt til Siden af Mundaabningen, noget bagenfor denne, sees en yderst lille, rund Aabning.

Huden er tyk, temmelig fast og ganske uigjennemsigtig paa Kroppen, imedens den paa Snabelen er noget tyndere og gjennemsigtig. Den dannes af en Cuticula, Fig. 14, *a*, der er glasklar, uden Stribning og meget tynd paa Kroppen, saa at den endog er vanskelig at iagttage uden ved meget stærk Forstørrelse; paa Snabelen er den derimod meget tykkere, Fig. 15, *a*.

Indenfor Cuticula er Epithelet, som dannes af et Lag Cylinderceller, der have en bleg, gulgrøn Farve, ere 0.060^{mm} lange, 0.008^{mm} brede ved deres Grunddel. De blive smalle jo mere de nærme sig Overhuden og faa her Udseende af en Række Orgelpiber, Fig. 14, *b*, 15, *b*.

Disse lange Cylinderceller have temmelig tykke Vægge, ere forsynede med en stor mørkere Kjerne og et noget lysere Kjernelegeme, hvilke ere omgivne af et finkornet Protoplasma.

Umiddelbart til dette Epithellag støder den egentlige Cutis, der udgjør et tykt, hyalint Bindevævslag, hvori findes en Mængde noget forskelligt formede Bindevævslegemer, Fig. 14, *c*; 15, *c*.

Indenfor Bindevævslaget er Muskelhuden, der dannes af 3 Lag: det ydre, circulere Lag (Ringmusklerne), som er temmelig bredt med stærke, tæt i hinanden liggende Muskelfibre, som ere sammenbundne med Bindevæv, Fig. 14, *d*; det midterste Lag (Længdemusklerne), der ere bredere end de ydre Ringmuskler, Fig. 14, *e*, og hvis Fibre ere tykkere, og det indre Ringmuskellag, som er yderst smalt, og hvis Fibre ere meget tyndere end de to foregaaendes, Fig. 14, *f*. Det indre Ringmuskellag er beklædt af Peritoneum, der har et Epithelovertræk; om dette er flimrende, hvilket er sandsynligt, kunne vi ikke afgjøre.

Paa Snabelen ere Cylindercellerne noget kortere, og her ligge Fibrene i Muskellagene saa langt fra hverandre, at Muskelhuden er tydelig gittret.

Paa den indre Flade af Huden, just paa det Sted, der svarer til den tidligere beskrevne Spalte paa hver Side af den forreste Kropsende, sees en Række runde Aabninger (vi talte 4 paa hver Side), hvilke vare omgivne af en rund Vold, der dannede ligesom en Sphincter om Aabningen, som førte ind til Spaltens Bund, Fig. 11, *a*, 12, *a*. Her er et Slags Respirationsapparat, hvorved Sø vandet

posterior, slightly inclining towards the dorsal surface; it has comparatively thick edges, near together, but not contiguous.

The bottom of this fissured opening was apparently pierced with divers minute apertures, which, however, had become so shrunk and contracted (the specimen was preserved in spirits) that even under a powerful lens they could not be plainly distinguished.

Posterior to the base of the appendix, on the ventral surface, is seen the round buccal aperture, fig. 13, *b*, prominently folded; and a little aside of, and posterior to, the buccal aperture, occurs an exceedingly minute circular opening.

The skin is thick, comparatively firm-textured, and quite opaque on the trunk; on the proboscis, it is somewhat thinner and translucent. It consists of a cuticle, fig. 14, *a*, which is hyaline, without striæ, and on the trunk exceedingly thin, so thin indeed as to be with difficulty distinguished even under a strong magnifier; on the proboscis, it is much thicker, fig. 15, *a*.

Underneath the cuticle extends the epithelium, consisting of a layer of cylindric cells, in colour a pale yellowish-green, 0.060^{mm} long and 0.008^{mm} broad at the base; they become gradually narrower the nearer they approach the cuticle, where they closely resemble a row of organ-pipes, figs. 14, *b*; 15, *b*.

These long cylindric cells have thickish walls, are furnished with a large, dark-coloured nucleus, and a somewhat lighter nucleolus, both surrounded by finely granulated protoplasma.

Immediately adjoining this epithelial layer, extends the true *cutis*, consisting of a thick hyaline layer of connective tissue, throughout which corpuscles of connective tissue are abundantly dispersed, figs. 14, *c*; 15, *c*.

Underneath the layer of connective tissue extends the muscular integument, composed of 3 layers: an outer circular layer (the annular muscles), comparatively broad, with strong, closely disposed muscular fibres, webbed together by connective tissue, fig. 14, *d*; a medial layer (the longitudinal muscles), broader than the outer annular muscles, fig. 14, *e*, and with thicker fibres; and the inner annular layer, which is exceedingly narrow, and with much slenderer fibres than the two foregoing layers, fig. 14, *f*. The inner annular layer is invested with peritoneum, having a thin epithelial tunic; but whether vibratile — which is probable — or without cilia, we could not determine.

On the proboscis, the cylindrical cells are somewhat shorter, and here the fibres of the muscular layer lie so far apart as to give the integument a distinct tessellated appearance.

On the inner surface of the skin, extending along either side of the anterior extremity of the body, inside the fore-mentioned fissure, are seen a series of round openings (we counted 4 on each side), surrounded by a circular ridge, constituting a kind of sphincter round the opening, which leads down to the bottom of the fissure, figs. 11, *a*; 12, *a*. Here (at the bottom of the fissure) is placed a

korresponderer med Kropshulheden; thi aabenbart kan Spalten udvide og sammentrække sine Læber, alt eftersom Strømningen skal gaa ind eller ud, — en Organisation, der er ganske fremmed for *Gephyreerne*.

Mundaabningen er omgivet af en muskuløs Vold. Spiserøret er omtrent 2.5^{mm} langt, Fig. 11, *b*, og har paa sin indre Flade stærke Længdefolder, som rage temmelig langt ind i Hulheden. Hvor Spiserøret gaar over i Tarmen er en Indsnøring, Fig. 11, *c*, som danner ligesom en Ring paa den indre Flade.

Tarmen, Fig. 10, 11, er meget vid og indtager en stor Del af Kropshulheden; den har en lige Retning bag mod Kroppens bagerste Ende, hvor den danner en yderst kort Rectum med en rund Analaabning. Den er i hele sin Længde paa Bugfladen og Siderne til henimod et Par Millimeter fra Analaabningen forsynet med en Mængde brede ringformige Folder, Fig. 10, *a*; 11, *d*, der rage langt ind i Tarmens Lumen.

Tarmens Rygflade derimod er glat og har paa den udvendige Side et stærkt muskuløst Baand, Fig. 11, *e*, der ved en Mængde Bindevævs- og Muskeltraade er nøie bundet til Kropshulhedens Rygflade, saa at der intet Mellemrum findes imellem denne og Tarmen. Det indre Epithel, der beklæder Tarmen og dens Folder, dannes af temmelig store Cylinderceller, der — foruden Kjerne og Kjernelegeme — indeholder et kornet Protoplasma, Fig. 14, *g*; mange af disse Celler ere meget store og have en temmelig bred Grunddel, og kunne muligens tjene som Afsondringsorganer; forøvrigt er Tarmens histologiske Bygning som hos *Gephyreerne* i Almindelighed.

Spiserøret var temmelig fast bundet til Kropsvæggen ved mange muskuløse Baand, hvoraf enkelte vare meget lange. Tarmens Bugflade var ved et stærkt Mesenterium fæstet til Kropsvæggen.

Der var ingen af de buskede Organer ved Rectum, som findes hos *Bonellia*, *Thalassema*, *Echiurus* og *Hamingia*.

Hvad vi kunne meddelé om Nervesystemet er desto værre meget ufuldkomment; thi Dyrenes slette Konservation har gjort det umuligt at kunne forfølge det i sin Helhed; ved Hjælp af endel Tversnit have vi dog kunnet udrede noget.

Nervestrængen følger langs Bugfladen ved Siden af Tarmmesenteriet og imellem Tarmvæggen og Kropsvæggen indre Ringmuskellag, fra Anus til den forreste Del af Spiserøret. Den er ikke indesluttet i noget Kar; men i dens Centrum er et Lumen, Fig. 14, *h*, hvori vistnok cirkulerer en Vædske og kan betragtes som et Centralkar. Et saadant har ogsaa Greeff iagttaget hos *Echiurus Palassi*¹.

¹ Ueber den Bau und die Entwicklung der *Echiurus* von R. Greeff. Aus den Sitzungsberichten der Gesellschaft zur Beförderung der gesammten Naturwissenschaften zur Marburg, No. 2, Februar 1874.

Den norske Nordhavsexpedition. Danielssen og Koren: *Gephyrea*.

kind of respiratory apparatus, through which the sea-water is made to communicate with the perivisceral cavity; for the labia of the fissure can evidently expand and contract, for the admission and expulsion of the circulating fluid, — a peculiarity of organisation altogether alien to the *Gephyrea*.

The buccal aperture is surrounded by a muscular ridge. The gullet, about 2.5^{mm} long, fig. 11, *b*, exhibits on its inner surface prominent longitudinal folds, extending comparatively far down into the cavity. Where the œsophagus passes into the intestine, is seen an instriction, fig. 11, *c*, forming, as it were, a ring on the inner surface.

The intestine, figs. 10; 11, is exceedingly wide, occupying a considerable portion of the perivisceral cavity; it protends almost straight back towards the posterior extremity of the body, where it opens into an exceedingly short rectum, with a round anal opening. It is furnished throughout its entire length on the ventral surface, and on the sides, to within a millimetre or two from the anal opening, with numerous broad annular folds, figs. 10, *a*; 11, *d*, projecting far down into the lumen of the intestine.

The dorsal surface of the intestine, on the other hand, is smooth, and furnished on the outer surface with an exceedingly muscular band, fig. 11, *e*, closely webbed by numbers of membranous and muscular filaments to the dorsal surface of the perivisceral cavity, no space being left between the latter and the intestine. The inner epithelium, investing the intestine and its folds, is composed of comparatively large cylindrical cells, which, exclusive of a nucleus and a nucleolus, contain granulous protoplasma, fig. 14, *g*; many of these cells are exceedingly large, with a broadish base; they perform, possibly, the office of secretory organs; for the rest, the histological structure of the intestine is that usually distinguishing the *Gephyrea*.

The œsophagus was strongly webbed to the wall of the body by numerous muscular bands, some of them remarkably long. The ventral surface of the intestine was attached to the wall of the body by a strong mesentery.

No trace of the bunchy organs observed on either side of the rectum in *Bonellia*, *Thalassema*, *Echiurus*, and *Hamingia*.

Unfortunately, we have but little to record of the nervous system; for owing to the bad state of the specimens it could not possibly be traced throughout; a few transverse sections enabled us however to observe some of its characteristics.

The nervous chord runs along the ventral surface, accompanying the intestinal mesentery between the wall of the intestine and the inner annular muscular layer in the wall of the body, from the anus to the anterior part of the œsophagus. It is not enclosed in any vessel; but in its centre there is a lumen, fig. 14, *h*, no doubt containing a circulating fluid, and this may be regarded as a central vessel. Greeff observed a similar vessel in *Echiurus Palassi*¹.

¹ Ueber den Bau und die Entwicklung der *Echiurus* von R. Greeff. Aus den Sitzungsberichten der Gesellschaft zur Beförderung der gesammten Naturwissenschaften zu Marburg, No. 2, Februar 1874.

Centralnervestrængen bestaar af en tyk muskuløs Skede, Fig. 14, *i*, indenfor hvilken den egentlige Nervemasse er, som dannes af et ydre celluløst Lag, Fig. 14, *k*, som er det bredeste, og et indre fibrillært, Fig. 14, *l*, der ligesom omgiver Centralkarret. Imellem Cellerne og Fibrillerne er et fint Bindevæv, der kitter Elementerne sammen og som udgaar fra Skedens indre Flade. Paa den forreste Del af Spiserøret tabte Nervestrængen sig i ramolleret Væv, saa vi ikke kunne afgjøre, hvorvidt den danner nogen Svælg-ring, hvilket dog er det sandsynligste; thi i Snabelen forlænger den sig ikke, — det have vi overbevist os om baade ved Tver- og Fladesnit.

Hvad Blodkarsystemet angaar, saa kunne vi Intet derom meddele, da vi ikke have fundet Spor dertil paa Grund af den slette Konservation.

Langs den forreste Halvdel af Tarmens Bugflade og bundet til Mesenteriet saaes et baandformigt, langstrakt Organ, der syntes at være dannet af sækformige Udbugtninger, og hvori kunde iagttages Cellegrupper, der tydede hen paa en begyndende Ægdannelse. Vi antage dette Organ for en Æggestok.

Paa højre Side af Tarmen i Kropshulhedens forreste Del fandtes et langt, næsten cylindrisk Organ, hvis forreste noget smalere Del var fæstet til Bugen; og Tilheftningsstedet svarede til det Sted, hvor der udvendig paa Kroppen saaes den førbeskrevne Aabning.

Lige ved Tilheftningsstedet paa Organets undre Flade saaes en Forlængelse, der sandsynligvis var den tragtformige Aabning for Æggebeholderen, som vi antage dette Organ for at være; men da vi nærmere vilde undersøge denne Forlængelse, viste det sig at Vævet var saa ramolleret, at vi ikke vove med Sikkerhed at antage den for Tragten.

Det langstrakte Organ, Fig. 11, *f*, havde en afrundet fri Ende; men var forresten bundet til Kropsvæggen ved flere fine Bindevævstraade. Vi fandt intet Indhold i dette Organ. Væggene vare muskuløse, men sammenfaldne, og gik let i Stykker ved Berørelse.

Kropsvædsken var kun at iagttage i Snabelen, og den indeholdt en Mængde næsten skiveformige Celler, der havde en svag brungul Farve.

Farven.

Legemet er olivengrønt. Snabelen bleg grønlig, næsten klar.

Findested Station 190; kun to Exemplarer.

The central nervous chord consists of a thick muscular sheath, fig. 14, *i*, underneath which lies the true nervous substance, consisting of an outer cellular layer, fig. 14, *k*, comparatively broad, and of an inner fibrillous layer, fig. 14, *l*, surrounding, as it were, the central vessel. Between the cells and the fibrils extends a layer of delicate connective tissue, uniting the several elements, and which issues from the inner surface of the sheath. On the anterior portion of the œsophagus the nervous chord was lost in a layer of disintegrated tissue, and we could not therefore determine whether it forms an pharyngeal ring, which, however, it most probably does; for it is not produced into the proboscis; of this we are assured from a careful examination both of transverse and longitudinal sections.

As regards the circulatory system (blood vessels) we have nothing whatever to communicate, not having found so much as a trace thereof in the badly preserved specimens.

Along the anterior half of the ventral surface of the intestine, and webbed to the mesentery, was seen a riband-shaped, elongate organ, consisting apparently of a series of sac-like dilatations, and in which groups of cells could be distinguished having the appearance of developping ova. We regard this organ as an ovary.

On the right side of the intestine in the anterior portion of the perivisceral cavity, protended a long, almost cylindrical organ, with its anterior, somewhat slenderer, part webbed to the belly, the line of attachment corresponding to the place on the outer surface of the body in which was seen the fore-described opening.

Close to the line of attachment on the inner surface of the organ, was an elongated prolation, most probably the funnel-shaped opening to the uterine pouch, which we take the said organ to be; but on proceeding to a closer examination, the tissue proved so completely disintegrated that we dare not regard it as the funnel.

The elongate organ, fig. 11, *f*, had a rounded free extremity, but was webbed to the wall of the body by numerous delicate filaments of connective tissue. This organ we found to be void of contents. The walls were muscular, but had fallen in, and crumbled to the touch.

The perivisceral fluid was observed in the proboscis only, and it contained numbers of almost discoid cells, pale brownish-yellow in colour.

Colour.

The body olive-green. The proboscis pale-green, and almost hyaline.

Taken at Station 190: two specimens.

Fam. **Epithetosomatidæ**, Dan. & Kor.

Legemet forsynet med et cylindrisk, hult, med Kroppshulheden korresponderende Rør. Bagenfor dette, paa hver Side af Kroppens Forende, en Spalte, i Bunden forsynet med Aabninger. Ingen Børster.

Slægtskarakter.

Legemet cylindrisk, paa dets forreste Ende forsynet med et langt, ikke retractilt, rørformigt Tilhæng (Snabel). Bagenfor dette, paa Bugsiden, den runde Mundaabning. Paa hver Side af den forreste Kroppsende en Spalte, der i Bunden er forsynet med flere Aabninger. Ingen Analappendices. Anus i Kroppens bagerste Ende.

Artskarakter.

Kroppen cylindrisk, 12^{mm} lang, 2^{mm} bred. Det rørformige Tilhæng 2¹/₂ Gang saa langt som Kroppen. Tarmen lige, stærkt foldet. Farven paa Kroppen olivengrøn, paa Snabelen bleg grønlig.

Den Beskrivelse vi her have leveret er jo i mange Punkter yderst ufuldkommen; thi det Materiale, der har staaet til vor Disposition, har baade været ringe — kun to Exemplarer — og slet konserveret. Ved et Uheld vare de blevne opbevarede paa et saa lidet Glas, at Spiritusindholdet ikke var tilstrækkelig til en god Konservation.

Det var især de indre Organer, der havde lidt, og det i den Grad, at Vævene for en stor Del vare ramrollerede. Men da det her omhandlede Dyr efter vor Formening i flere Henseender har stor Interesse for Videnskaben, fandt vi det rigtigt at offentliggjøre vore Undersøgelser, saa ufuldstændige, de end ere, i Haab om, at naar Opmærksomheden engang var vakt, vilde det senere lykkes Forskere at erholde et bedre og rigere Materiale, hvorved Iagttagelserne ikke alene kunde optages paany, men at ogsaa derved de i vor Beskrivelse muligens indløbne Feil kunne berigtiges og Manglerne udfyldes.

Det vil være indlysende af vor Beskrivelse, at vort nye Dyr ikke kan henføres til nogen af de af Gephyreerne hidtil bekjendte Familier eller Slægter. Det afviger paa saa mange Maader fra disse, og ikke mindst derved, at det har Spalter, der aabne Forbindelsen mellem Søvandet og Kroppsvædsken, at vi et Øieblik var i Tvivl om, hvorvidt vi havde med en Gephyre at gjøre, — en Tvivl, der dog snart hævedes ved den Kundskab, vi erholdt om Dyrets Organisation. Denne tilhører overveiende Gephyreernes. De nævnte Aandespalter? ere joganske eiendommelige og fremmede for denne Klasse af Dyr, og har neppe noget Analogon.

Vi have saaledes ikke alene opstillet en ny Slægt for det; men vi have endog fundet det nødvendigt at grunde en ny Familie, hvortil Slægten kan henføres.

Fam. **Epithetosomatidæ**, Dan. & Kor.

Body furnished with a cylindrical, hollow tube, communicating with the perivisceral cavity. Posterior to this tube, on either side of the anterior extremity of the trunk, a cleft, or fissure, the bottom pierced with apertures. No bristles.

Generic Character.

Body cylindrical, furnished at the anterior extremity with a long, non-retractile, tubiform appendix (proboscis). Posterior to the appendix, on the ventral surface, the round buccal opening. On either side of the anterior extremity of the trunk, a cleft, or fissure, the bottom pierced with several apertures. No anal appendices. The anus on the posterior extremity of the trunk.

Specific Character.

Trunk cylindrical, 12^{mm} long, 2^{mm} in diameter. The tubiform appendix 2¹/₂ times the length of the trunk. The intestine straight, with prominent folds. Colour of trunk olive-green; of proboscis pale-green.

The description we have here ventured to give is in many respects very incomplete, the materials from which it has been furnished having been not only scanty, but — a far greater drawback — also defective: two examples in a bad state of preservation. Unfortunately, the glass jar in which the specimens had to be brought home, was so small, that the quantity of spirits was insufficient for perfect preservation.

The internal organs had suffered most, to that extent indeed, that the greater part of the delicate tissue was found to have become more or less disintegrated. But, as this rare animal will, we opine, prove of great scientific interest, we feel no hesitation in publishing the results of our investigation; however meagre and incomplete, hoping that, when attention shall have been once aroused, zoologists may at some future period succeed in obtaining more extensive and better materials, wherewith could be resumed the observations prematurely arrested, and any errors rectified that may be found to detract from the value of our description.

It will be obvious from the criteria recorded, that *Epithetosoma* cannot be referred to any known genus or family of *Gephyrea*. It differs indeed from them all in so many respects, and not least by reason of the fissured opening through which the sea-water gains access to the perivisceral cavity, that we were a moment in doubt as to whether the animal before us could be a Gephyrean, — a doubt, however, speedily set at rest on our proceeding to investigate its organisation. The aforesaid respiratory fissure is, however, something eminently peculiar, and alien to this class of animals; its analogue probably does not exist.

Hence we have not only had to institute a new genus but have found it necessary to establish a new family for the reception of *Epithetosoma*.

Her skulle vi benytte Anledningen til at yttre, at de to Ordener, hvori Gephyreernes Klasse er inddelt, nemlig *Gephyrea inermia* og *Gephyrea armata*, neppe kan siges at være heldige.

Vi have opstillet 3 nye Slægter, der ifølge deres hele Organisation maa henføres til *Gephyrea armata*, omendskjøndt de ikke ere forsynede med de enkelte Organer (Børster), som udgjør det væsentligste Grundlag for denne Orden. Skulde vi altsaa have holdt os strængt til den systematiske Inddeling, maatte vore 3 nye Slægter henføres til *Gephyrea inermia*, med hvilke de dog kun have lidet tilfælles i Forhold til den store Lighed, de have med de Slægter, der tilhøre den anden Orden.

In conclusion, we will avail ourselves of the opportunity afforded, to remark that the two orders into which the Class *Gephyrea* is divided, viz. *Gephyrea inermia* and *Gephyrea armata*, can hardly be regarded as satisfactory.

We have established 3 new genera, which, by reason of their anatomical structure, are referred to *Gephyrea armata*, through they are not furnished with the characters (bristles) on which that order is based. Had, therefore, in this case, the systematic classification been rigorously applied, our 3 new genera would have had to be referred to *Gephyrea inermia*, with which order they have but little in common, compared to the striking resemblance they bear to the genera comprised in the other.

Fortegnelse

over de paa Nordhavsexpeditionen fundne Slægter og Arter af Gephyreer, samt over den vigtigste Del af deres Synonymi.

Fam. *Sipunculidæ*, Baird.

1. *Sipunculus priapuloides*, Koren & Dan., "Fauna littoralis Norvegiæ", Bergen, 1877, pag. 126. Tab. XIII, Fig. 1—6.

1 Exemplar paa Station 79. To hele, overordentlig store Exemplarer og 4 sønderrevne paa Stat. 252. Et Exemplar og nogle Stumper paa Stat. 255.

2. *Phascolosoma strombi*, Mont.

1799. "Snyltedyr", Jens Rathke. Skrifter af Naturh. Selskab. Hefte 1, pag. 124, Pl. III, Fig. 17. Kjøbenhavn.

1804. *Sipunculus Strombi*, G. Montagu. Transact. Linn. Soc. VII, pag. 74. London.

Sipunculus bernhardus. 1841. E. Forbes. A History of British Starfishes, pag. 251. London.

— *capitatus*. 1843. H. Rathke. Nova Acta, Acad. Leop. Car. XX, pag. 143, Pl. VI, Fig. 20—23.

Phascolosoma concharum. 1844. A. S. Ørsted. De region. mar. pag. 80. Hafniae.

— *strombi*. 1865. Kefenstein. Nachricht. d. K. Ges. d. Wiss. Göttingen, März, pag. 202. Zeitschr. f. wiss. Zool. XV, pag. 431, Pl. XXXI, Fig. 10, et Pl. XXXIII, Fig. 34, 35, 36. Leipzig.

Phascolion strombi. 1875. H. Théel. Bihang till K. Svenska Vet. Akad. Handl. Bd. 3, No. 3. K. Svenska Vet. Akad. Handl. Bd. 14, No. 2.

Den var hyppig og fandtes paa følgende Stationer: 10, 48, 79, 192, 224, 225, 240, 257, 260, 261, 275, 326, 337.

Phascolosoma strombi, varietas *spitsbergense*. *Phascolion spitsbergense*, Théel. Bihang till K. Svenska Vet. Akad. Handl. Bd. 3, No. 6, pag. 15, Pl. I, Fig. 1 et Pl. III, Fig. 16.

Den norske Nordhavsexpedition. Danielssen og Koren: Gephyrea.

List

of the Genera and Species of *Gephyrea* collected on the Norwegian North-Atlantic Expedition, and of their chief Synonyms.

Fam. *Sipunculidæ*, Baird.

1. *Sipunculus priapuloides*, Koren & Dan., "Fauna littoralis Norvegiæ", Bergen, 1877, pag. 126; Pl. XIII, figs. 1—6.

One specimen at Station 79. Two perfect specimens, remarkably large, and 4 mutilated individuals, at Stat. 252. One specimen and a few fragments at Stat. 255.

2. *Phascolosoma strombi*, Mont.

1799. "Snyltedyr," Jens Rathke. Skrifter af Naturh. Selskab. Part 1, pag. 124, Pl. III, fig. 17. Kjøbenhavn.

1804. *Sipunculus Strombi*, G. Montagu. Transact. Linn. Soc. VII, pag. 74. London.

Sipunculus bernhardus. 1841. E. Forbes. A History of British Starfishes, pag. 251. London.

— *capitatus*. 1843. H. Rathke. Nova acta, Acad. Leop. Car. XX, pag. 143, Pl. VI, figs. 20—23.

Phascolosoma concharum. 1844. A. S. Ørsted. De region. mar. pag. 80. Hafniae.

— *strombi*. 1865. Kefenstein. Nachricht. d. K. Ges. d. Wiss. Göttingen, März, pag. 202. Zeitschr. f. wiss. Zool. XV, pag. 431, Pl. XXXI, fig. 10 et Pl. XXXIII, figs. 34, 35, 36. Leipzig.

Phascolion strombi. 1875. H. Théel. Bihang till K. Svenska Vet. Akad. Handl. Bd. 3, No. 3. K. Svenska Vet. Akad. Handl. Bd. 14, No. 2.

Abundant, and brought up at the following Stations: — 10, 48, 79, 192, 224, 225, 240, 257, 260, 261, 275, 326, 337.

Phascolosoma strombi, varietas *spitsbergense*. *Phascolion spitsbergense*, Théel. Bihang till K. Svenska Vet. Akad. Handl. Bd. 3, No. 6, pag. 15, Pl. I, fig. 1 et Pl. III, fig. 16.

Paa Station 323 ved Spitsbergen blev fundet 3 Exemplarer af Théel's *Phascolion spitsbergense*; og vi have derved faaet Anledning til at sammenholde den med en hel Del Exemplarer af *Phascolosoma strombi*, der ere indsamlede dels ved Finmarkens Kyster, dels paa flere Stationer i det norske Hav, saavel fra den kolde, som varme Area. Resultatet har da været, at den Tvivl vi nærede og udtalte i 3die Hefte af "Fauna littoralis Norvegiæ", pag. 154, med Hensyn til Artens Selvstændighed er saa langt fra bleven rokket, at vi tvertimod nu maa antage den for en ikke særdeles stærkt udpræget Varietet af *Phascolosoma strombi*.

3. *Phascolosoma eremita*, M. Sars. Nyt Magazin for Naturvid. 1851, pag. 197.
 — *boreale*, Keferstein. Nachrichten d. K. Ges. d. Wiss., Göttingen 1865, pag. 206. Zeitschr. f. w. Zool. 1865, pag. 437, Tab. XXXI, Fig. 7; Tab. XXXIII, Fig. 33.
 — *boreale*, H. Théel. Bihang till K. Sv. Vet. Akad. Handl. Bd. 3, No. 6, pag. 10, 1875—76.
 — *eremita*, Koren & Dan. "Fauna littoralis Norvegiæ" 3die Hefte, pag. 134, Tab. XV, Fig. 45.

3 Exemplarer paa Stat. 257, et lidet Exempl. paa Stat. 275 og et lignende paa Stat. 326.

4. *Phascolosoma margaritaceum*, M. Sars. Nyt Magazin for Naturv. 1851, pag. 196.
 — *Ørstedii*, Keferstein. Nachrichten d. K. Ges. d. Wiss., Göttingen 1865, pag. 205. Zeitschr. f. w. Zool. 1865, pag. 436, Tab. XXXI, Fig. 8; Tab. XXX, Fig. 39.
 — *Ørstedii*, Ehlers. Sitzungsber. d. phys. med. Soc. zu Erlangen 1871, III, pag. 83.
 — *Ørstedii*, Théel. Bihang till K. Sv. Vet. Akad. Handl. Bd. 3, No. 6, pag. 9, 1875—76.
 — *margaritaceum*, Koren & Dan. "Fauna littoralis Norvegiæ" 3die Hefte, pag. 135, Tab. XV, Fig. 43, 44. Bergen, 1877.

1 Exempl. paa Stat. 2, Sognefjord.

5. *Phascolosoma squamatum*, Koren & Dan. "Fauna littoralis Norvegiæ" 1877, pag. 130, Tab. XIII, Fig. 11; Tab. XIV, Fig. 14, 15.

Flere Exemplarer paa Stat. 9, 1 Exempl. paa Stat. 147, og to Exempl. paa Stat. 149.

6. *Phascolosoma Lilljeborgii*, Dan. & Kor.

Flere Exemplarer paa Stat. 34. Et Par Exempl. paa Stat. 40, 51, 87, 176, 200. 2 Exempl. i Rør paa Stat. 295.

7. *Stephanostoma Hanseni*, Dan. & Kor.

Et helt Exempl. og mange større og mindre Stumper paa Stat. 223. Et næsten helt Exempl. paa Stat. 267.

At Station 323, off Spitzbergen, were brought up 3 specimens of Théel's *Phascolion spitsbergense*, thus affording opportunity of comparing this animal with numerous specimens of *Phascolosoma strombi*, collected in part on the coasts of Finmark and in part at divers Stations in the Norwegian Sea, both from the cold and the warm area. The result of the comparison shows the doubt we entertained and had expressed in Part III of "Fauna littoralis Norvegiæ," pag. 154, touching the claim of *Phascolion spitsbergense* to be regarded as a distinct species, to have been well founded; indeed, we now regard the animal as a mere variety, by no means strongly marked, of *Phascolosoma strombi*.

3. *Phascolosoma eremita*, M. Sars. Nyt Magazin for Naturvid. 1851, pag. 197.
 — *boreale*, Keferstein. Nachrichten d. K. Ges. d. Wiss., Göttingen 1865, pag. 206. Zeitschr. f. w. Zool. 1865, pag. 437. Pl. XXXI, fig. 7, Pl. XXXIII, fig. 33.
 — *boreale*, H. Théel. Bihang till K. Sv. Vet. Akad. Handl. Bd. 3, No. 6, pag. 10, 1875—76.
 — *eremita*, Koren & Dan. "Fauna littoralis Norvegiæ," Hefte III, pag. 134, Pl. XV, fig. 45.

Three specimens at Stat. 257; a small specimen at Stat. 275; another small specimen at Stat. 326.

4. *Phascolosoma margaritaceum*, M. Sars. Nyt Magazin for Naturv. 1851, pag. 196.
 — *Ørstedii*, Keferstein. Nachrichten d. K. Ges. d. Wiss., Göttingen 1865, pag. 205. Zeitschr. f. w. Zool. 1865, pag. 436, Pl. XXXI, fig. 8, Pl. XXX, fig. 39.
 — *Ørstedii*, Ehlers. Sitzungsber. d. phys. med. Soc. zu Erlangen. 1871, III, pag. 83.
 — *Ørstedii*, Théel. Bihang till K. Sv. Vet. Akad. Handl. Bd. 3, No. 6, pag. 9, 1875—76.
 — *margaritaceum*, Koren & Dan. "Fauna littoralis Norvegiæ," Hefte III, pag. 135, Pl. XV, figs. 43, 44. Bergen 1877.

One specimen, at Stat. 2, in the Sognefjord.

5. *Phascolosoma squamatum*, Koren & Dan. "Fauna littoralis Norvegiæ," 1877, pag. 130, Pl. XIII, fig. 11; Pl. XIV, figs. 14, 15.

Several specimens at Stat. 9; one specimen at Stat. 147; two specimens at Stat. 149.

6. *Phascolosoma Lilljeborgii*, Dan. & Koren.

Several specimens at Stat. 34; a few specimens at Stat. 40, 51, 87, 176, 200; two specimens, with tubes, at Stat. 295.

7. *Stephanostoma Hanseni*, Dan. & Koren.

One perfect specimen, and numerous fragments, at Stat. 223; one specimen, almost perfect, at Stat. 267.

8. *Onchnesoma Steenstrupii*, Koren & Dan. "Fauna littoralis Norvegiæ". Bergen 1877, pag. 142, Tab. XV, Fig. 28—36.

Mange Exemplarer paa Stat. 1, Sognefjorden. Nogle Exempl. paa Stat. 147.

9. *Onchnesoma glaciale*, Koren & Dan.

Flere Exempl. paa Stat. 51, 240, 248. 1 Exempl. paa Stat. 251. Mange Exempl., der vare sammenfiltrede ved den lange Snabel, paa Stat. 283.

10. *Aspidosiphon armatum*, Koren & Dan.

1 Exemplar paa Stat. 87.

Fam. **Priapulidæ**, Baird.

11. *Priapulus caudatus*, Lam.

Holothuria priapus, O. Fabr. "Fauna Grønl." O. Fr. Müller, Zoologia Dan. III, pag. 27, Tab. XCVI, Fig. 1. J. Rathke, Zool. Dan. IV, pag. 18, Tab. CXXXV, Fig. 2.

Priapulus caudatus, Frey und R. Leuckart. Beiträge zur Kenntniss wirbelloser Thiere. Braunschweig 1847, pag. 40.

— *caudatus*, Ehlers. Zeitschr. f. w. Zool., 11ter B., pag. 209, Tab. XX.

— *glandifer*, Ehlers. Zeitschr. f. w. Zool., 11ter B., pag. 209, Tab. XXI, Fig. 24.

— *brevicaudatus*, Ehlers. Zeitschr. f. w. Zool., 11ter B., pag. 209.

— *caudatus*, Koren & Dan. "Fauna littoralis Norvegiæ" pag. 150.

Temmelig hyppig ved Spitsbergen, nemlig ved Magdalene-Bay, Advent-Bay og Stat. 366.

12. *Priapuloides typicus*, Koren & Dan. "Fauna littoralis Norvegiæ", pag. 147, Tab. XVI, Fig. 10—14, 3die Hefte 1877.

1 Exemplar paa Stat. 18. 1 Exempl. paa Stat. 192. Et Par hele Exempl. og nogle Stumper paa Stat. 224, 225. Et lidet Exemplar paa Stat. 240. Et lignende paa Stat. 262. Et meget stort og et lidet Exempl. paa Stat. 290. Et meget stort Exempl. paa Stat. 226. Et lidet Exempl. paa Stat. 336 og 338. 2 Exempl. paa Stat. 357.

13. *Halicryptus spinulosus*, v. Siebold.

— *spinulosus*, v. Siebold, 1849. Neue preuss. Provinzialblätter, VII, pag. 184. Königsberg.

— *spinulosus*, v. Siebold, 1862. Zeitschr. f. w. Zool., XI, pag. 413.

— *spinulosus*, Ehlers, 1862. Zeitschr. f. w. Zool., XI, pag. 401, Pl. XXIV.

— *spinulosus*, Ehlers, 1871. Sitzungsbericht d. phys.-med. Soc. zu Erlangen, III, pag. 84.

— *spinulosus*, Willemoes-Suhm, 1871. Zeitschrift f. w. Zool., XXI, pag. 385.

8. *Onchnesoma Steenstrupii*, Koren & Dan. "Fauna littoralis Norvegiæ." Bergen 1877, pag. 142, Pl. XV, figs. 28—36.

Numerous specimens at Station 1, in the Sognefjord; a few specimens at Station 147.

9. *Onchnesoma glaciale*, Koren & Dan.

Several specimens at each of the following Stations:— 51, 240, 248; one specimen at Stat. 251; numerous specimens, with the long probosces interlaced, at Stat. 283.

10. *Aspidosiphon armatum*, Koren & Dan.

One specimen at Stat. 87.

Fam. **Priapulidæ**, Baird.

11. *Priapulus caudatus*, Lam.

Holothuria priapus, O. Fabr. "Fauna Grønl." O. Fr. Müller, Zoologia Dan. Part III, pag. 27, Pl. XCVI, fig. 1. J. Rathke, Zool. Dan. Part IV, pag. 18, Pl. CXXXV, fig. 2.

Priapulus caudatus, Frey und R. Leuckart. Beiträge zur Kenntniss wirbelloser Thiere. Braunschweig, 1847, Part IV, pag. 40.

— *caudatus*, Ehlers. Zeitschr. f. w. Zool., Part XI, pag. 209, Pl. XX.

— *glandifer*, Ehlers. Zeitschr. f. w. Zool., Part XI, pag. 209, Pl. XXI, fig. 24.

— *brevicaudatus*, Ehlers. Zeitschr. f. w. Zool., Part XI, pag. 205.

— *caudatus*, Koren & Dan. "Fauna littoralis Norvegiæ," pag. 150.

Comparatively abundant off Spitzbergen, in particular in Magdalene Bay, Advent Bay, and at Stat. 366.

12. *Priapuloides typicus*, Koren & Dan. "Fauna littoralis Norvegiæ," pag. 147, Pl. XVI, figs. 10—14, Part III, 1877.

One specimen at Stat. 18; one specimen at Stat. 192; two perfect specimens, and a few fragments; at Stat. 224, 225; one small specimen at Stat. 240; another small specimen at Stat. 262; two specimens, one very large and one small, at Stat. 290; one specimen, very large, at Stat. 226; two small specimens, one at Stat. 336 and one at Stat. 338; two specimens at Stat. 357.

13. *Halicryptus spinulosus*, v. Siebold.

— *spinulosus*, v. Siebold, 1849. Neue preuss. Provinzialblätter, VII, pag. 184. Königsberg.

— *spinulosus*, v. Siebold, 1862. Zeitschr. f. w. Zool., XI, pag. 413.

— *spinulosus*, Ehlers, 1862. Zeitschr. f. w. Zool., XI, pag. 401, Pl. XXIV.

— *spinulosus*, Ehlers, 1871. Sitzungsbericht d. phys.-med. Soc. zu Erlangen, III, pag. 84.

— *spinulosus*, Willémoes-Suhm, 1871. Zeitschrift f. w. Zool., XXI, pag. 385.

Fam. **Bonellidæ**, Baird.

14. **Hamingia arctica**, Dan. & Koren.
1 Exemplar paa Station 270.
15. **Saccosoma vitreum**, Dan. & Koren.
1 Exemplar paa Stat. 40.

Fam. **Epithetosomatidæ**, Dan. & Kor.

16. **Epithetosoma norvegicum**, Dan. & Koren.
2 mindre godt konserverede Exemplarer paa Station
190.

Fam. **Bonellidæ**, Baird.

14. **Hamingia arctica**, Dan. & Koren.
One specimen at Station 270.
15. **Saccosoma vitreum**, Dan. & Koren.
One specimen at Stat. 40.

Fam. **Epithetosomatidæ**, Dan. & Kor.

16. **Epithetosoma norvegicum**, Dan. & Koren.
Two specimens (state of preservation not very good),
at Stat. 190.

Fortegnelse

over de Arbeider, der væsentligst ere benyttede ved denne Afhandling over Gephyreerne.

- Baird, W.** Monograph of the Species of Worms belonging to the Subclass *Gephyrea*; with a Notice of such Species as are contained in the Collection of the British Museum. Proceed. of the Zool. Soc. of London 1868.
- Diesing, C. M.** Systema helminthum, II. Vindobonæ 1851.
— Revision der Rhyngodeen, Sitzungs- b. der math.-naturw. Classe d. k. k. Akademie der Wissensch. in Wien, XXXVII, 1859.
- Ehlers, E.** Ueber die Gattung Priapulid. Zeitschr. f. w. Zool. 11ter Bd., pag. 205. Tab. 20—21.
— Ueber Halicyptus spinulosus, v. Siebold. Zeitschr. f. w. Zool. 11ter Bd., pag. 401.
- Forbes, E. A.** History of British Starfishes. London 1841.
- Frey, H. und Leuckart, R.** Beiträge zur Kenntniss wirbelloser Thiere. Braunschweig 1847. 4to.
- Graber, V.** Ueber die Haut einiger Sternwürmer (Gephyrea). Sitzungs- b. d. Akademie d. Wissensch. LXVII. 1ste Abth. Jän-Heft. Wien 1873.
- Greiff, R.** Ueber Thalassema. Sitzungs- b. Gesellsch. d. gesammten Naturwissensch. Marburg 1872. Juli.
— Ueber d. Bau und d. Entwick. d. Echiuren. Arch. f. Nat. 1877, pag. 343.
- Keferstein, W.** Beiträge zur anatomischen und systematischen Kenntniss der Sipunculiden. Zeitschrift f. w. Zool. XV. 1865.
— Untersuchungen über einige amerikanische Sipunculiden. Zeitschr. f. w. Zool. XVII. 1866.
- Koren & Danielssen.** Bidrag til de norske Gephyreers Naturhistorie. Fauna littor. Norvegiæ, 3. Hefte, pag. 111.
- Kowalewsky, A.** Thalassema. Protokoll Naturforskerfor- samling. Kiew 1871.

List

of the principal Works consulted in preparing this Memoir.

- Lacaze-Duthiers, H.** Rech. sur la Bonellie. Ann. Sciences nat. 4 S. 10 T. 1858, pag. 49.
- Müller, J.** Ueber einen neuen Wurm, Sipunculus scutatus. Archiv f. Naturg. X. Berlin 1844.
- Müller, Max.** Observationes anat. de vermibus quibusdam maritimis. Diss. Berol. 1852. 4to. Tab. 1—3.
- Möebius, K.** Gephyrea. Jahresbericht d. Commission zur wiss. Untersuchung der deutschen Meere, 2 und 3 Jahrgang, pag. 156. Berlin 1875.
- Quatrefages, M. A. de.** Histoire naturelle des Annelés, II, 1865.
- Rathke, J.** Iagttagelser henhørende til Indvoldsormenes og Bløddyrenes Naturhistorie. Skrifter af Naturhist. Selsk. V. Kjøbenhavn 1799.
- Rathke, H.** Beiträge zur Fauna Norwegens. Nova Acta, Acad. Leop. Carol. XX. 1843.
- Schmarda, L.** Bonellia. Denkschr. d. Wiener Akad. 4 Bd. 1852, pag. 117, Tab. 4—7.
- Schmidt, O.** Ueber Sipunculoiden (Gephyrea). Zeitschr. f. die gesammten Naturw. III. Halle, 1854.
- Spengel, W. J., Dr.** Beiträge zur Kenntniss der Gephyre- reen. Die Eibildung, die Entwicklung u. das Männchen der Bonellia. Mittheilungen aus der zoologischen Station zu Neapel. 1 B., 3 Hefte. 1879.
- Théel, Hj.** Recherches sur le Phascolion Strombi, Mont. Kongl. Svenska Vetenskaps Aka- demiens Handl. Tab. XIV. No. 2. 1875.
— Études sur les Géphyriens inermes, etc. Stockholm 1875.
- Vejdovsky, Franz.** Ueber die Eibildung und die Männchen von Bonellia viridis. Zeitschr. f. wissensch. Zoologie, 30 B. 1873, pag. 487.

Forklaring over Tavlerne.

- Tab. I, Fig. 1. *Phascolosoma Lilljeborgii*, forstørret. *a* Kroppen; *b* Snabelen; *c* Tentaklerne; *d* Analaabningen.
- 2. Den samme aabnet, forstørret. *a* Retraktor med sine to Rødder; *b* Retraktoren længere fortil; *c* Segmentalorgan; *d* Spiserøret; *e, f* Tarmen; *g* Tarmen, idet den gaar over i Rectum; *h* Rectum; *i* Nervestrængen.
- 3. Tversnit af Huden, forstørret. *a* Cuticula; *b* Epithellaget; *c* Hudkjertelens Grunddel; *d* Udførselsgangen; *e* Den tragtformige Fordybning i Cuticula, hvori Udførselsgangens Aabning; *f* Kjertelens Bindevævs-kapsel; *g* Epithelet, som beklæder Kapselens indvendige Flade; *h* Bindevævs-laget.
- 4. Tversnit af Huden, forstørret. *a* Cuticula; *b* Epithellaget; *c* Kjertelens Grunddel; *d* Udførselsgangen; *e* Udførselsgangens Aabning i Cuticularfordybningen; *f* Epithelet, der beklæder den indvendige Flade af Kjertelen, samt dennes Udførselsgang; *g* Bindevævs-laget; *h* Tver- og Længdemuskler.
- 5. *Aspidosiphon armatum*, forstørret. *a* Indsnøring rundt Kroppens bagerste Ende; *b* det forreste Skjold; *c* det bagerste Skjold.
- 6. Den samme aabnet, forstørret. *a* Skjoldets indvendige Flade; *b* Muskler; *c* Retraktor med dens tvende Rødder; *d* den forreste Ende af Retraktor; *e* Tentaklerne; *f* Spiserøret; *g* Tarmen; *h* Rectum; *i* Æggestokken; *k* Segmentalorganet.
- 15. *Onchnesoma glaciale*, naturlig Størrelse.
- 15¹. Den samme, forstørret.
- 16. Den samme, aabnet, forstørret. *a* Analaabning; *b* Retraktor; *c* Segmentalorgan; *d, e* Spiserør; *f* Begyndende Tarm; *g* Bag-

Explanation of the Plates.

- Pl. I. fig. 1. *Phascolosoma Lilljeborgii*, magnified: *a* trunk; *b* proboscis; *c* tentacles; *d* anal opening.
- 2. Same animal, opened, magnified: *a* retractor, with the two roots; *b* retractor, farther in advance; *c* segmental organ; *d* œsophagus; *e, f* intestine; *g* intestine, where it passes into the rectum; *h* rectum; *i* nervous chord.
- 3. Transverse section of skin, magnified: *a* cuticle; *b* epithelial layer; *c* basal portion of tegumentary gland; *d* excretory duct; *e* funnel-shaped depression in cuticle, with the opening of the excretory duct; *f* capsule of gland; *g* epithelium investing inner surface of capsule; *h* layer of connective tissue.
- 4. Transverse section of skin, magnified: *a* cuticle; *b* epithelial layer; *c* basal portion of gland; *d* excretory duct; *e* opening of excretory duct into the cuticular depression; *f* epithelium investing the inner surface of the gland and of its excretory duct; *g* layer of connective tissue; *h* transverse and longitudinal muscles.
- 5. *Aspidosiphon armatum*, magnified: *a* constriction round posterior extremity of body; *b* foremost shield; *c* hindmost shield.
- 6. Same animal, opened, magnified: *a* inner surface of shield; *b* muscles; *c* retractor, with both roots; *d* anterior extremity of retractor; *e* tentacles; *f* œsophagus; *g* intestine; *h* rectum; *i* the ovary; *k* segmental organ.
- 15. *Onchnesoma glaciale*, natural size.
- 15¹. Same animal, magnified.
- 16. Same animal, opened, magnified: *a* anal opening; *b* retractor; *c* segmental organ; *d, e* œsophagus; *f* commencement of in-

tilløbende Tarmslynge; *h* Fortilløbende Tarmslynge; *i* Rectum; *k* Nervestrængen.

Tab. I, Fig. 17. Tversnit af Huden, forstørret. *a* Cuticula; *b* Epithellag; *c* Bindevævslag; *d* Ringmuskler; *e* Længdemuskler; *f* Hudkjertelens Grunddel; *g* Dens afrundede Spids; *h* Udførselsgangen; *i* Kjertelens indre Epithelbeklædning.

— 18. Tversnit af Snabelens Hud, besat med Hager, forstørret. *a* Cuticula; *b* Epithellaget; *c* Kjertel; *d* Kjertelens Epithel; *e* Hage.

— 19. Den forreste Del af Snabelen med sine Hager, forstørret.

— 20. Hager, seet fra forskellige Sider, forstørret.

Tab. II, Fig. 7. Endeskjoldet af *Aspidosiphon armatum*, forstørret. *a* Randplader; *b* Runde, mere centrale Plader; *c* 5—6 Ringe besatte med Chitinplader.

— 8. Det forreste Skjold, forstørret. *a* Skjoldets Randplader; *b* Furen imellem disse; *c* De runde, ophøjede Plader.

— 9. Hagerækkerne paa Snabelen, forstørret.

— 10. Hagerne, forstørret.

— 11. Et Stykke Hud af *Aspidosiphon armatum*, seet fra oven, forstørret. *a* Porer for Kjertlernes Udførselsgang; *b* Chitinplader.

— 12. Tversnit af Huden af *Aspidosiphon armatum*, forstørret. *a* Cuticula; *b* Chitinplade; *c* Epithellag; *d* Hudkjertel; *e* Dens Udførselsgang; *f* Bindevævslag; *g* Ringmuskler; *h* Længdemuskler.

— 13. Et Stykke Hud af *Aspidosiphon armatum*, seet fra oven, stærkt forstørret. *a* Cuticula; *b* Chitinplade; *c* Aabning for Hudkjertelens Udførselskanal.

— 14. Den indre Flade af det forreste Skjold med dets Muskelapparat, forstørret. *a* Sidemuskler; *b* Centrale Muskler; *c* De forreste Muskler.

— 21. *Stephanostoma Hansenii*, naturlig Størrelse. *a* Krop; *b* Bagenden; *c* Snabelens Grund; *d* Den forreste Del af Snabelen; *e* Snabelens Hals; *f* Mundskiven med den centrale Mundaabning; *g* Tentakler; *h* Anal-aabning.

— 22. Den forreste Ende af Snabelen med Mundskiven og Tentakelkraven, forstørret. *a* Mundskiven; *b* Mundaabning; *c* Tentakler; *d* De i Grupper siddende Papiller.

testine; *g* circumvolution passing backwards; *h* circumvolution passing forwards; *i* rectum; *k* nervous chord.

Pl. I, fig. 17. Transverse section of skin, magnified: *a* cuticle; *b* epithelial layer; *c* layer of connective tissue; *d* annular muscles; *e* longitudinal muscles; *f* basal portion of tegumentary gland; *g* rounded extremity of the gland; *h* excretory duct; *i* epithelial tunic investing inner surface of gland.

— 18. Transverse section of skin of proboscis, studded with chitinous hooks, magnified: *a* cuticle; *b* epithelial layer; *c* a gland; *d* epithelium of the gland; *e* hooks.

— 19. Anterior portion of proboscis, with the hooks, magnified.

— 20. Hooks, viewed in different positions, magnified.

Pl. II, fig. 7. Terminal shield of *Aspidosiphon armatum*, magnified: *a* marginal plates; *b* round plates, more central in position; rings covered with chitinous plates.

— 8. Foremost shield, magnified: *a* the marginal plates; *b* furrows between them; *c* the round, prominent plates.

— 9. Series of hooks on the proboscis, magnified:

— 10. Two of the hooks, magnified.

— 11. Strip of skin of *Aspidosiphon armatum*, viewed from above, magnified: *a* pores for the excretory duct of the gland; *b* chitinous plates.

— 12. Transverse section of the skin of *Aspidosiphon armatum*, magnified: *a* cuticle; *b* chitinous plates; *c* epithelial layer; *d* tegumentary glands; *e* excretory duct; *f* layer of connective tissue; *g* annular muscles; *h* longitudinal muscles.

— 13. A piece of the skin of *Aspidosiphon armatum*, viewed from above, highly magnified: *a* cuticle; *b* a chitinous plate; *c* opening for the excretory canal of the tegumentary gland.

— 14. Inner surface of foremost shield, with its muscular apparatus, magnified: *a* lateral muscles; *b* central muscles; *c* foremost muscles.

— 21. *Stephanostoma Hansenii*, natural size: *a* trunk; *b* posterior extremity; *c* base of proboscis; *d* anterior portion of proboscis; *e* neck of proboscis; *f* buccal disk with the buccal orifice in the centre; *g* tentacles; *h* anal opening.

— 22. Anterior extremity of proboscis, with the buccal disk and tentacular collar, magnified: *a* buccal disk; *b* buccal aperture; *c* tentacles; *d* grouped papilla.

Tab. II, Fig. 23. Snabelens forreste Ende med Mundskiven og Tentakler, seet fra Siden, forstørret. *a* Store Tentakelgrupper; *b* Enkelte Tentakler imellem de store Grupper.

- 24. Et Stykke af Snabelens Hud, seet fra oven, for at vise Papillerne, forstørret.
- 25. Tversnit af Huden, forstørret. *a* Cuticula; *b* Indsynkninger i Cuticula, i hvis Bund Hudkjertlernes Udførselsgang aabner sig; *c* Epithellaget; *d* Hudkjertel; *e* Ringmuskler; *f* Længdemuskler.
- 26. Et Stykke af det nævnte Tversnit, stærkt forstørret. *a* Cuticula; *b* Fordybning i samme, i hvis Bund Udførselsgangen for Hudkjertelen aabner sig; *c* Epithellaget; *d* Kjertelens Grunddel; *e* Kjertelens Spids; *f* Udførselskanalen; *g* Epithelet, som beklæder Kjertelens indre Flade; *h* Binde vævs laget.
- 27. *Stephanostoma Hanseni*, aabnet fra Ryggen; noget forstørret. *a* Spiserøret; *b* Tarmen; *c* Spindelmuskelen bagerste og forreste Ende; *d* Spindelmuskelen; *e* Rectum; *f* Et Blodkar paa Spiserøret; *g* Det kontraktile Kar med sin blinde, frit hængende Ende; *h* Rygretraktor; *i* Segmentalorgan; *k* Nervestræng; *l* Bugretraktor; *m* Indtrukken Snabel.
- 28. Et Segmentalorgan, forstørret. *a* Den ovale tragtformige Aabning.
- 29. Nervestrængen med dens Svælgring, forstørret. *a* Nervestrængen med Sidegrene; *b* Svælgringen; *c* Ryggangliet (Hjernen).

Tab. III, Fig. 1. *Priapulus typicus*, i naturlig Størrelse. *a* Nervestrængen.

- 2. Den samme aabnet fra Ryggen. *a* Huden Længdemuskler; *b* Enkelte Længdemuskler, der gaa over i Tilhænget; *c* Mundhulen med Tandapparatet; *d* Indsnøring paa Spiserøret, hvorved Folden paa den indre Flade dannes; *e* Længdefolder paa Spiserørets indre Flade; *f* Spiserørets Overgang i Tarmen; *g* Tverfolder paa Tarmens indre Flade; *h* Rectum; *i* Æggestokken; *k* Dens Udførselsgang; *l* Udførselsgangens Begyndelse; *m* De lange Retraktorer; *n* De korte Retraktorer.
- 3. Tversnit af Huden, forstørret. *a* Cuticula med Chitinpapillerne; *b* Epithellaget; *c* Binde vævs laget; *d* Ringmusklerne; *e* Længdemusklerne med deres Skede; *f* Mu-

Pl. II, fig. 23. Anterior extremity of proboscis, with the buccal disk and the tentacles, side-aspect, magnified: *a* large groups of tentacles; *b* isolated tentacles dispersed between the large groups.

- 24. Strip of skin of proboscis, figured as seen from above, to show the papillæ, magnified.
- 25. Transverse section of skin, magnified: *a* cuticle; *b* depressions in the cuticle, through the bottom of which opens the excretory duct of the tegumentary glands; *c* epithelial layer; *d* tegumentary gland; *e* annular muscles; *f* longitudinal muscles.
- 26. Part of the same transverse section, highly magnified: *a* cuticle; *b* one of the depressions therein; through the bottom of which opens the excretory duct of the tegumentary glands; *c* epithelial layer; *d* basal portion of the gland; *e* extremity of the gland; *f* excretory canal; *g* epithelium investing the inner surface of the gland; *h* layer of connective tissue.
- 27. *Stephanostoma Hanseni*, viewed through the back, slightly magnified: *a* œsophagus; *b* intestine; *c* posterior and anterior extremities of fusiform muscle; *d* fusiform muscle; *e* rectum; *f* a blood-vessel of the œsophagus; *g* the contractile vessel, with its cæcal free depending extremity; *h* the dorsal retractor; *i* segmental organ; *k* nervous chord; *l* the ventral retractor; *m* proboscis, invaginated.
- 28. The segmental organ, magnified: *a* its oval, funnel-shaped opening.
- 29. The nervous chord, with its pharyngeal ring, magnified: *a* nervous chord with subsidiary branches; *b* pharyngeal ring; *c* dorsal ganglion (brain).

Pl. III, fig. 1. *Priapulus typicus*, natural size: *a* nervous chord.

- 2. Same animal, opened dorsally: *a* longitudinal muscles of the skin; *b* isolated longitudinal muscles, passing into the appendix; *c* cavity of the mouth, with dental apparatus; *d* constriction of the œsophagus, producing a fold on the inner surface of the organ; *e* longitudinal folds on inner surface of œsophagus; *f* passage of the œsophagus into the intestine; *g* transverse folds on inner surface of intestine; *h* rectum; *i* the ovary; *k* its eferent duct; *l* origin of eferent duct; *m* the long retractors; *n* the short retractors.
- 3. Transverse section of skin, magnified: *a* cuticle; with chitinous papillæ; *b* epithelial layer; *c* layer of connective tissue; *d* annular muscles; *e* longitudinal muscles, with

skelbundter; *g* Deres Membran; *h* Fibrillerne; *i* Skraa-tribningen i Fibrillerne; *k* Nerven; *l* Dens Bindevævsskede; *m* Bindevævsseptum; *n* Den indre, brede Del af Nerven.

- Tab. III, Fig. 4. Et Tversnit af Glans, forstørret. *a* Piggens Grunddel; *b* dens Spids; *c* Epithelbeklædningen; *d* Skeden, der omgiver Piggens; *e* Kjertelen; *f* Epithelet paa Kjertelkapselens indre Væg; *g* Udførselsgangens Begyndelse; *h* Dens Fortsættelse op igjennem Piggens; *i* Dens Aabning; *k* Muskelfibre, der gaa til den indre Flade af Skeden; *l* Ringmuskler.
- 5. Et Tversnit, ligeledes af Glans, forstørret. *a* Piggens Grunddel; *b* Dens Spids; *c* Epithelbeklædningen; *d* Skeden; *e* Kjertelen; *f* Dens Epithel; *g* Kjertelens Udførselsgang; *h* Dens Fortsættelse og Aabning; *i* Muskler til Skedens indre Flade.
- 6. Tversnit af den bagerste Del af Mundhulhedens Hud med de deri fæstede Tænder, forstørret. *a* Tandens Grunddel; *b* Dens Spids.
- 7. En Tand; stærkt forstørret. *a* Epithel, som beklæder Tandens Hulhed; *b* Tandens faste Spids.
- 8. Tversnit af den mellemste Del af Mundhulhedens Hud med de deri fæstede Tænder. *a* Chitinhud; *b* Epithel.
- 9. Svælghovedet med Spiserøret og den begyndende Tarm, forstørret. *a* De ydre, brede Muskler; *b* De indre smale Muskler; *c* Indsnøring paa Spiserøret; *d* Muskler, som gaa over i den muskuløse Membran *e*, som fæster sig paa Volden *f*; *g* Rummet imellem Indsnøringen paa Spiserøret og Muskelmembranen; *h* Muskler; *i* overskaarne og opslaaede Retraktorer.
- 10. Tversnit af Tarmens midterste Del, forstørret. *a* Tarmfolder med deres Epithelialbeklædning; *b* Bindevæv; *c* Bindevævslister; der danne Tarmfolderne.
- 11. Tversnit af Huden paa Glans af *Priapulus caudatus*, forstørret. *a* Skeden, som omgiver Piggens nedre Del; *b* Aabningen paa Piggens Spids; *c* Epithelet, som beklæder Piggens indre Flade; *d* Kjertelen.
- 12. Et Hudparti af Glans, seet næsten fra oven, forstørret. *a* Den noget sammen-

sheath; *f* fascicles of muscles; *g* their membrane; *h* fibrils; *i* oblique striature of fibrils; *k* the nerve; *l* its sheath of connective tissue; *m* septum of connective tissue; *n* inner, broad portion of nerve.

- Pl. III, fig. 4. Transverse section of proboscis, magnified: *a* basal portion of spike; *b* its pointed extremity; *c* epithelial tunic; *d* sheath enclosing the spike; *e* the gland; *f* epithelium on the inner wall of the capsule of the gland; *g* origin of excretory duct; *h* its continuation up through the spike; *i* its opening; *k* muscular fibres protending to inner surface of sheath; *l* annular muscles.
- 5. Another transverse section of the proboscis, magnified: *a* base of spike; *b* point of spike; *c* epithelial tunic; *d* sheath; *e* the gland; *f* epithelium investing it; *g* excretory duct of gland; *h* its continuation and opening; *i* muscles protending to inner surface of sheath.
- 6. Transverse section of the posterior portion of the dentiferous integument clothing the cavity of the mouth, showing the teeth affixed thereto, magnified: *a* base of tooth; *b* point of tooth.
- 7. A tooth, highly magnified: *a* epithelium covering the hollow of the tooth; *b* the solid point of the tooth.
- 8. Transverse section of the medial portion of the dentiferous integument clothing the cavity of the mouth, showing the teeth affixed thereto, magnified: *a* chitinous integument; *b* epithelium.
- 9. The gullet, together with the œsophagus and the commencement of the intestine, magnified: *a* the broad exterior muscles; *b* the narrow interior muscles; *c* constriction of the œsophagus; *d* muscles passing into the muscular membrane (*e*), which are attached to the tendinous ridge (*f*); *g* the space between the œsophagus and the muscular membrane; *h* muscles; *i* retractors, cut through and laid open.
- 10. Transverse section of the medial portion of the intestine, magnified: *a* folds of the intestine, invested with epithelium; *b* connective tissue; *c* fillets of connective tissue, producing the folds of the intestine.
- 11. Transverse section of skin of proboscis, in *Priapuloides caudatus*, magnified: *a* sheath enclosing the lower portion of the spike; *b* opening at the point of the spike; *c* epithelium investing the inner surface of the spike; *d* the gland.
- 12. Portion of the skin of the proboscis, viewed almost from above, magnified: *a* the sheath,

trukne Skede; *b* Aabningen paa Pig-
gens Spids; *c* Fordybning i Huden
omkring Piggens Grund.

- Tab. IV & V. Fig. 1. *Hamingia arctica* i naturlig Størrelse. *a* Mundaabning; *b* Den halvmaaneformige Hudfold (Antydning til en Snabel) omkring Munden; *c* Cylindriske, krum-bøiede Papillær (egentlig Udførselsgange for Uteri); *d* Kloakaabning.
- 2. Kroppens forreste Ende, seet forfra, forstørret. *a* Mundaabning; *b, b* De to Hudfolder; *c* Foreningen imellem den forreste og bagerste Hudfold; *d* Furen imellem Mundlæberne og den forreste Hudfold; *e* Den brede Fordybning imellem den forreste og bagerste Hudfold; *f* De to krum-bøiede Papillær.
- 3. Kroppens bagerste Ende med Kloakaabningen i Centrum, forstørret.
- 4. Tversnit af Huden, forstørret. *a* Cuticula; *b, b* Det hyaline Bindevævslag, hvori Cellegrupper ere leirede; *c* To sammenhængende Celler; *d* Ringmuskler; *e* Længdemuskler; *f* Skraamuskler; *g* Centralnerven.
- 5. Huden seet ovenfra, forstørret. *a* Cellegrupper.
- 6. *Hamingia arctica*, aabnet fra Ryggen, naturlig Størrelse. *a* Mündhulheden; *b* Spiserøret; *c* Ringformige Fordybninger, dannede af det fibrillære Bindevæv; *d—t*, Begge inklusive Tarmrøret med dets mange Bøininger; *u* Rectum; *v* Tendinøse Fibre, der binde Kloaken til Kropsvæggen; *x* Rygkarret.
- 7. Tversnit af Spiserøret, forstørret. *a* Epithellaget; *b* Indsynkningerne i det kjernerige, fibrillære Bindevæv; *c* fibrillært Bindevæv; *d* Længdemuskler; *e* Ringmuskler.
- 8. Den bagerste Kropsdel, aabnet, og endel af de tendinøse Fibre overskaarne og slaaede tilside for at vise de to Tarmappendices, lidt forstørret. *a, a* De buskformige Kjertelapparater; *b* Hovedstammen for disse; *c* Endetarmen; *d* de tendinøse Fibre; *e* Kloak.
- 9. *a* En rørformig Gren fra det buskformige Organs Hovedstamme; *b, b* Slangeformige Rør; *c* Tragtformig Aabning for et af disse Rør, forstørret.
- 10. Den øverste Ende af et slangeformigt Rør med sin tragtformigt udvidede Aabning; forsynet med Cilier, samt dens Vægge tapetserede med Celler, forstørret.

slightly contracted; *b* the opening at the point of the spike; *c* depression in the skin round the base of the spike.

- Pls. IV & V. fig. 1. *Hamingia arctica*, natural size: *a* buccal aperture; *b* lunate fold of the skin (rudimentary proboscis) round the mouth; *c* cylindric, arcuate papillæ (strictly, eferent ducts for the uteri); *d* cloacal opening.
- 2. Anterior extremity of body (front aspect), magnified: *a* buccal aperture; *b, b* the two folds of the skin; *c* junction of the anterior with the posterior fold; *d* furrow between the buccal labia and the anterior fold; *e* broad depression between the anterior and the posterior fold; *f* the two arcuate papillæ.
- 3. Posterior extremity of body, with the cloacal opening in the centre, magnified.
- 4. Transverse section of skin, magnified: *a* cuticle; *b, b* hyaline layer of connective tissue, in which are dispersed groups of cells; *c* two connate cells; *d* annular muscles; *e* longitudinal muscles; *f* oblique muscles; *g* the central nerve.
- 5. The skin, viewed from above, magnified: *a* groups of cells.
- 6. *Hamingia arctica*, opened dorsally, natural size: *a* cavity of the mouth; *b* œsophagus; *c* annular depressions in fibrillous connective tissue; *d—t* (inclusive) the intestinal canal, with its numerous convolutions; *u* rectum; *v* tendinous fibres, webbing the cloacum to the wall of the body; *x* dorsal vessel.
- 7. Transverse section of the œsophagus, magnified: *a* epithelial layer; *b* impressions in the nucleal, fibrillous connective tissue; *c* fibrillous connective tissue; *d* longitudinal muscles; *e* annular muscles.
- 8. Posterior portion of the body, opened, and with part of the tendinous fibres cut through and reflected, to show the two intestinal appendices, slightly magnified: *a, a* the bushy glandular apparatus; *b* their principal stem; *c* rectum; *d* tendinous fibres; *e* the cloacum.
- 9. *a*, a tubular branch protending from the principal stem of the bushy organ; *b, b* sinuous tubes; *c* funnel-shaped opening for one of the tubes, magnified.
- 10. Superior extremity of one of the sinuous tubes, with its funnel-shaped, expanded opening, furnished with cilia, and having its walls lined with cells, magnified.

Tab. IV & V, Fig. 11. En Levercelle, forstørret.

- 12. Epithelet paa den indre Flade af de slangeformige Rør, forstørret.
- 13. *a, a, b, b* De enkelte Epithelceller i disse Rør; *c* Runde Smaalegemer, som fandtes i Kropsvædsken.
- 14. *a* Rygkarret paa Mundhulhedens ydre Flade; *b* Det Sted, hvor det gaar over paa venstre Uterus; *c* Løbet paa samme; *d* Hvor det gaar over paa den venstre horizontale Tarmslynge; *e* Hvor det deler sig; *f* Den ene Stammes Grene; *g* Sammentræffet med Grene fra Bugkarret; *h* Bugkarret; *i* Bugkarrets ene Stamme, der følger Tarmen; *k* Bugkarrets anden Stamme, hvis Grene forbinde sig med Rygkarrets; *l, m* Bugkarrets Fortsættelse fortil, imellem Uteri, idet det krydser Rygkarret.
- 15. *a* Centralnervestrængen; *b* Bugkarret; *c, d, e* Grene fra det; *f* Blodkarrets forreste Del, lidt før det deler sig; *g* Deling i to Grene; *h* Den høire udvidede Gren; *i* Det fra Udvidningen udgaaende Kar; *k* Hjerne (?).
- 16. *a* Centralnervestrængen, den midterste Del med dens Sidegrene; *b* Den forreste Del af Centralstrængen med Sidegrene; *c* Gren til Uterus; *d* Delingen fortil af Centralstrængen; *e* Grene til Spiserør og Mundhulhed; *f* Den bagerste Del af Centralstrængen; *g* Dennes Deling i to Grene; *h, h* Uteri; *i* Udførselsgang for den venstre Uterus; *k* Kanalen for Tragten; *l* Tragten; *m* Indgangen til Tragten; *n, n* Æggestokken; *o, o* Føllikelgrupper; *p* Endnu ikke fuldt udviklede Æg.
- 17. *a* Udførselsgang for Uterus; *b* Kanalen for Tragten; *c* Den frie Del af Kanalen; *d* Tragstens Aabning; *e* Cilier, forstørret.
- 18. *Hamingia arctica*, tegnet i levende Live, naturlig Størrelse.
- 19. *Stephanostoma Hansenii*, tegnet i levende Live, naturlig Størrelse.
- 20. *Saccosoma vitreum*, tegnet i levende Live, ganske lidt forstørret.

Pls. IV & V, fig. 11. A: hepatic cell, magnified.

- 12. Epithelium investing the inner surface of the sinuous tubes, magnified.
- 13. *a, a, b, b* isolated epithelial cells dispersed throughout the tubes; *c, c, d, e* round corpuscles, found floating in the perivisceral fluid.
- 14. *a* the dorsal vessel on the outer surface of the cavity of the mouth; *b* the point at which it passes across to the left uterus; *c* course of the vessel; *d* the point at which it passes across to the left horizontal circumvolution of the intestine; *e* that at which it divides; *f* the branches of one of the stems; *g* junction with the branches from the ventral vessel; *h* the ventral vessel; *i* one of the stems of the ventral vessel, accompanying the intestine; *k* the other stem of the ventral vessel, whose branches unite with those of the dorsal vessel; *l, m* continuation of the ventral vessel anteriorly, between the two uteri, where it crosses the dorsal vessel.
- 15. *a* central nervous chord; *b* ventral vessel; *c, d, e* branches proceeding therefrom; *f* anterior portion of the bloodvessel, just before it divides; *g* its dichotomous division; *h* the right, expanded branch; *i* the vessel proceeding from the expansion; *k* the heart (?).
- 16. *a* central nervous chord, medial portion, with the subsidiary branches; *b* anterior portion of central nervous chord, with subsidiary branches; *c* a branch passing to the right uterus; *d* anterior division of central nervous chord; *e* branches proceeding to the oesophagus and the cavity of the mouth; *f* posterior portion of central nervous chord; *g* dichotomous division of the chord; *h, h* the uteri; *i* eferent duct for the left uterus; *k* canal for the funnel; *l* the funnel; *m* entrance to the funnel; *n, n* the ovary; *o, o* groups of follicles; *p* ova, nearly developed.
- 17. *a* eferent duct for one of the uteri; *b* canal for the funnel; *c* the free portion of the canal; *d* opening of the funnel; *e* cilia, magnified.
- 18. *Hamingia arctica*, figured from a living specimen, natural size.
- 19. *Stephanostoma Hansenii*, figured from a living specimen, natural size.
- 20. *Saccosoma vitreum*, figured from a living specimen, very slightly magnified.

- 21. Den bagerste Ende af samme, seet fra oven.
- Tab. VI, Fig. 1. *Saccosoma vitreum*, naturlig Størrelse.
- 2. Den samme, forstørret. *a* Den forreste, cylindriske, opake Del; *b* Mundaabning; *c* Den glasklare, kugleformige Del; *d* Den koniske, opake Ende; *e* Analaabning; *f* Tarmslyngninger.
- 3. Den samme, aabnet efter Rygsiden, forstørret. *a* Længdemuskler; *b* Mundaabning, omgivet af en Vold; *c* Spiserøret; *d* Maven; *e* Begyndende Tarm; *f* Tarmslynger, hvori sees Excrementer; *g* Rectum; *h* Tendinøse Fibre, som binde Rectum til Kropsvæggen; *i* Den tilbage-slaaede Hud.
- 4. Den forreste, cylindriske, opake Del af Legemet, aabnet efter Ryggen og Spiserøret borttaget, forstørret. *a* Længdemuskler; *b* Centralnervestrængen med sine Sidegrene; *c* Æggestokken; *d* Æggeholderen (Uterus); *e* Æg; *f* Udførselskanalen for Uterus; *g* Æg i Udførselskanalen; *h* Tragten.
- 5. Tversnit af Huden paa den forreste, cylindriske, opake Del af Legemet, forstørret. *a* Cuticula; *b* Epithel; *c* Bindevæv; *d* Ringmuskler; *e* Længdemuskler; *f* En fin Nervegren; *g* Ganglieformige Fortykkelser.
- 6. Huden af den glasklare Legemsdel, hvori Muskelfletninger sees, forstørret. *a* Ringmuskler; *b* Længdemuskler; *c* Skraamuskelfibre, der udgaa fra Ringmusklerne.
- 7. Excrementer, forstørret.
- 8. Et Stykke af Æggestokken, forstørret. *a* Follikel; *b* Celler.
- 9. *Epithetosoma norvegicum*, forstørret. *a* Kroppen; *b* Snabelen.
- 10. Den samme, forstørret og aabnet efter Bugfladen. *a* Tarmen.
- 11. Den samme, aabnet efter Ryggen, forstørret. *a* Aabningen paa Hudens indre Flade; *b* Spiserøret; *c* Indsnøring, hvor Spiserøret gaar over i Tarmen; *d* Tarmfolder; *e* Muskelbaand langs Tarmens Rygflade; *f* Uterus.
- 12. Den forreste Kropsende, aabnet for at vise Aabningerne for Sidespalterne, samt Aabningen for Snabelen, forstørret. *a* Spalteaabninger; *b* Snabelaabning.

- 21. Same animal, posterior extremity, viewed from above.
- Pl. VI, fig. 1. *Saccosoma vitreum*, natural size.
- 2. Same animal, magnified: *a* anterior, cylindrical, opaque portion; *b* buccal aperture; *c* the hyaline globular portion; *d* the conical, opaque extremity; *e* anal opening; *f* circumvolutions of the intestine.
- 3. Same animal, opened dorsally, magnified: *a* longitudinal muscles; *b* buccal aperture, surrounded by a ridge; *c* œsophagus; *d* stomach; *e* commencement of intestine; *f* circumvolutions of the intestine, in which are seen fecal pellets; *g* rectum; *h* tendinous fibres, webbing the rectum to the wall of the body; *i* the skin, laid back.
- 4. The anterior, cylindrical, opaque portion of the body, opened dorsally, and with the œsophagus removed, magnified: *a* longitudinal muscles; *b* central nervous chord, with the subsidiary branches; *c* the ovary; *d* the uterine pouch (uterus); *e* ova; *f* the eferent canal for the uterus; *g* ova in the eferent canal; *h* the funnel.
- 5. Transverse section of the skin on the anterior, cylindrical, opaque portion of the body, magnified: *a* cuticle; *b* epithelium; *c* connective tissue; *d* annular muscles; *e* longitudinal muscles; *f* a slender nervous branch; *g* ganglionous inspissations.
- 6. Skin of the hyaline portion of the body, in which are seen muscular reticulations, magnified: *a* annular muscles; *b* longitudinal muscles; *c* oblique protending muscular fibres, issuing from the annular muscles.
- 7. Fæces, magnified.
- 8. A piece of the ovary, magnified: *a* a follicle; *b* cells.
- 9. *Epithetosoma norvegicum*, magnified: *a* the trunk; *b* the proboscis.
- 10. Same animal, magnified, and opened ventrally; *a* the intestine.
- 11. Same animal, opened dorsally, magnified: *a* opening on the inner surface of the skin; *b* œsophagus; *c* an constriction, where the œsophagus passes into the intestine; *d* folds of the intestine; *e* muscular bands passing along the dorsal surface of the intestine; *f* the uterus.
- 12. Anterior extremity of the body, opened to show the apertures for the lateral fissures and the orifice for the proboscis, magnified: *a* fissiform apertures; *b* orifice for the proboscis.

Tab. VI. Fig. 13. Den forreste Kroppsende, forstørret. *a* Sidespalterne; *b* Mundaabning; *c* Snabel.

— 14. Tversnit af Kroppen, forstørret. *a* Cuticula; *b* Epithellag; *c* Bindevævs-lag; *d* Ydre Ringmuskler; *e* Længdemuskler; *f* Indre Ringmuskler; *g* Tarmfolder med sit Epithel; *h* Centralkar i Nervestrængen; *i* Nervestrængens Skede; *k* Nervens ydre cellulære Lag; *l* Nervens indre fibrillære Lag.

— 15. Tversnit af Snabelens Hud, forstørret. *a* Cuticula; *b* Epithel; *c* Bindevæv.

Pl. VI. fig. 13. Anterior extremity of body, magnified: *a* lateral fissures; *b* buccal aperture; *c* proboscis.

— 14. Transverse section of the body, magnified: *a* cuticle; *b* epithelial layer; *c* layer of connective tissue; *d* external annular muscles; *e* longitudinal muscles; *f* internal annular muscles; *g* folds of the intestine, with their epithelial covering; *h* central vessel in the nervous chord; *i* sheath of nervous chord; *k* external cellular layer of the nerve; *l* internal fibrillous layer of the nerve.

— 15. Transverse section of skin of proboscis, magnified: *a* cuticle; *b* epithelium; *c* connective tissue.

Indhold.

	Page
<i>Aspidosiphon armatum</i>	4
<i>Epithetosoma norvegicum</i>	39
<i>Halicryptus spinulosus</i>	47
<i>Hamingia arctica</i>	20
<i>Onchiesoma glaciale</i>	8
— <i>Steenstrupii</i>	47
<i>Phascolosoma eremita</i>	46
— <i>Lilljeborgii</i>	3
— <i>margaritaceum</i>	46
— <i>squamatum</i>	46
— <i>strombi</i>	45
<i>Priapuloides typicus</i>	13
<i>Priapulus caudatus</i>	47
<i>Saccosoma vitreum</i>	34
<i>Sipunculus priapuloides</i>	45
<i>Stephanostoma Hansenii</i>	9

Index.

	Page
<i>Aspidosiphon armatum</i>	4
<i>Epithetosoma norvegicum</i>	39
<i>Halicryptus spinulosus</i>	47
<i>Hamingia arctica</i>	20
<i>Onchiesoma glaciale</i>	8
— <i>Steenstrupii</i>	47
<i>Phascolosoma eremita</i>	46
— <i>Lilljeborgii</i>	3
— <i>margaritaceum</i>	46
— <i>squamatum</i>	46
— <i>strombi</i>	45
<i>Priapuloides typicus</i>	13
<i>Priapulus caudatus</i>	47
<i>Saccosoma vitreum</i>	34
<i>Sipunculus priapuloides</i>	45
<i>Stephanostoma Hansenii</i>	9

Erratum.

Pag. 1, 8de Linie fra oven, staar 2 Familier, læs 1 Familie.

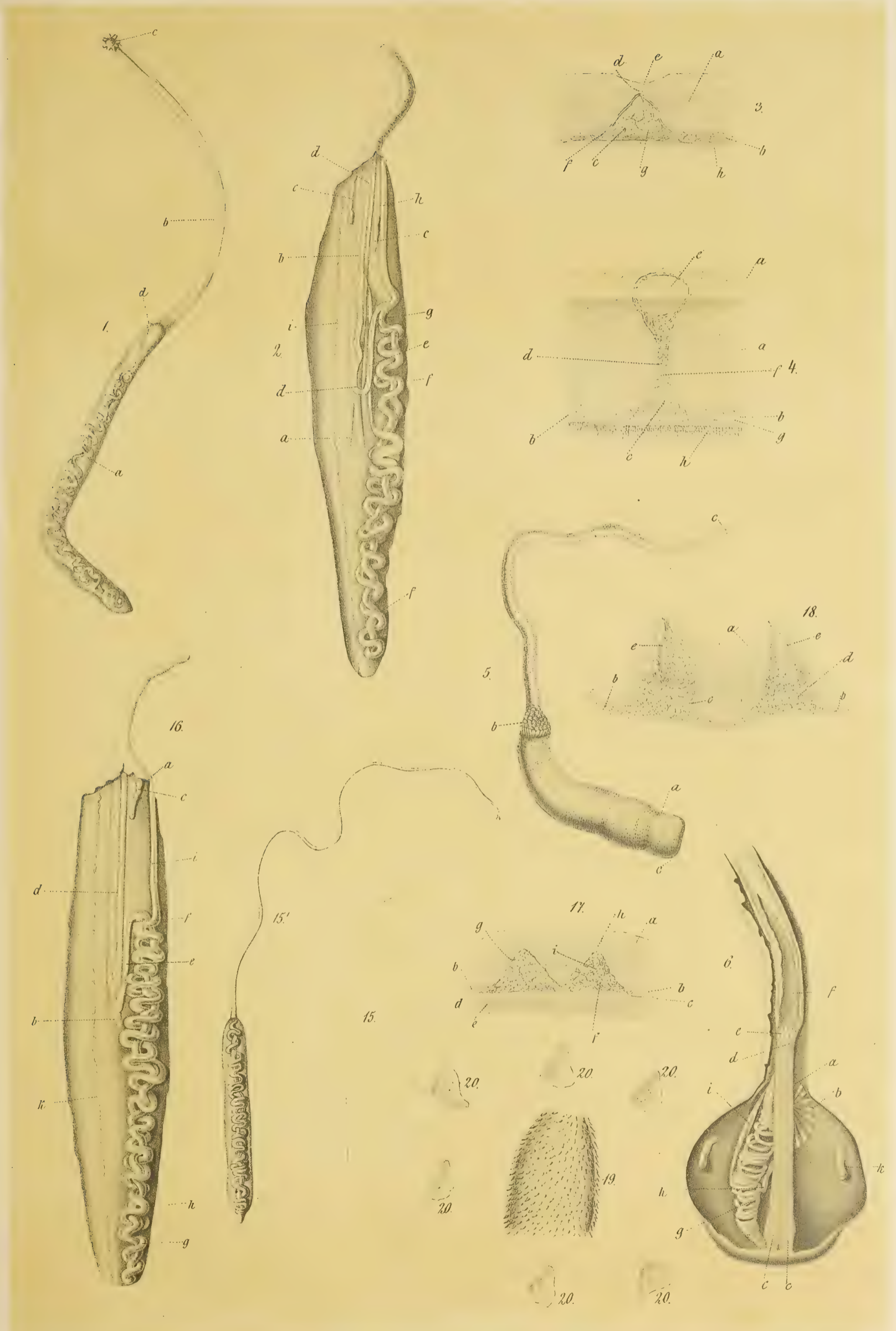
Indleveret til Redactionscomiteen den 18de Juni 1880.

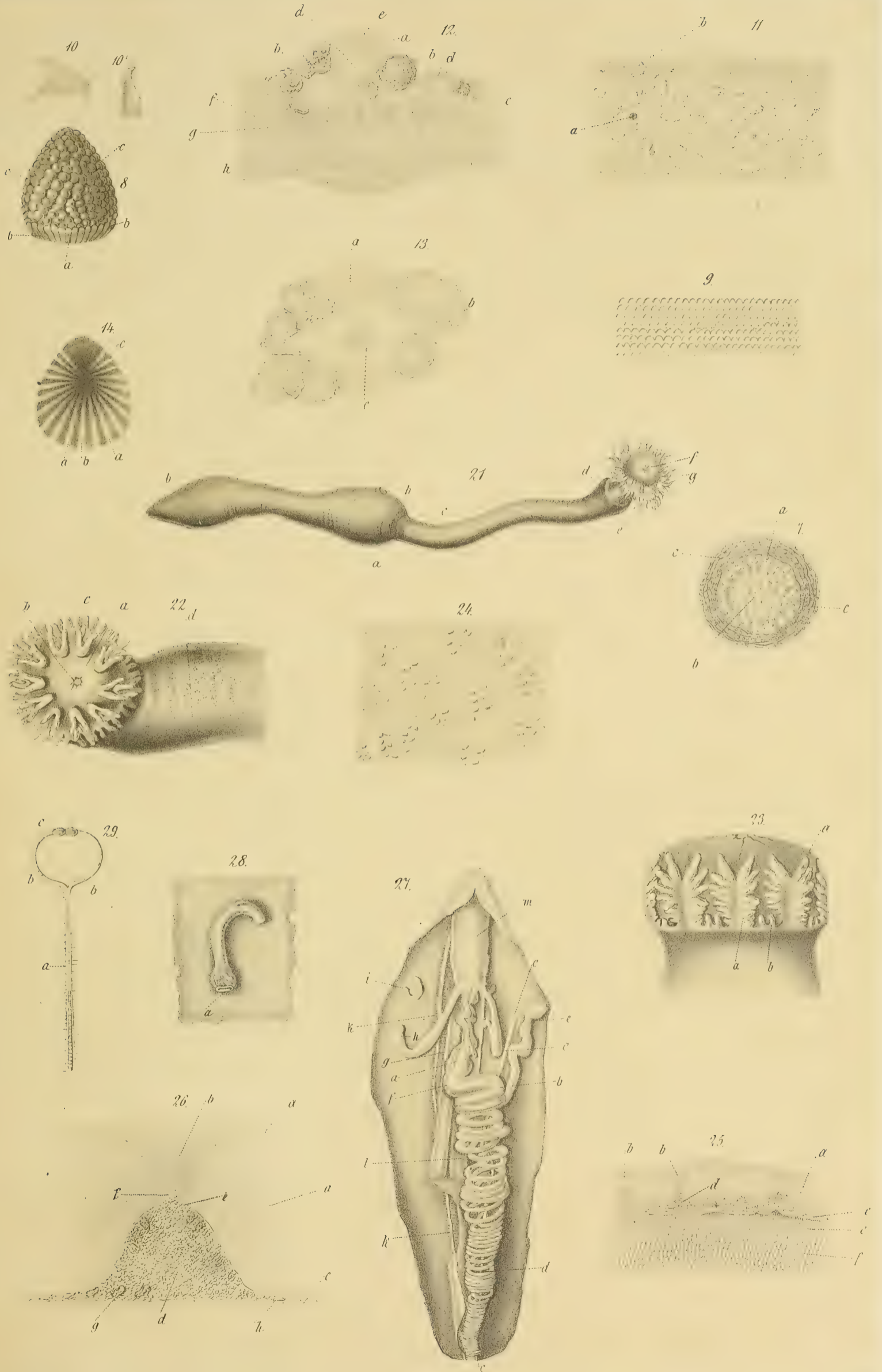
Erratum.

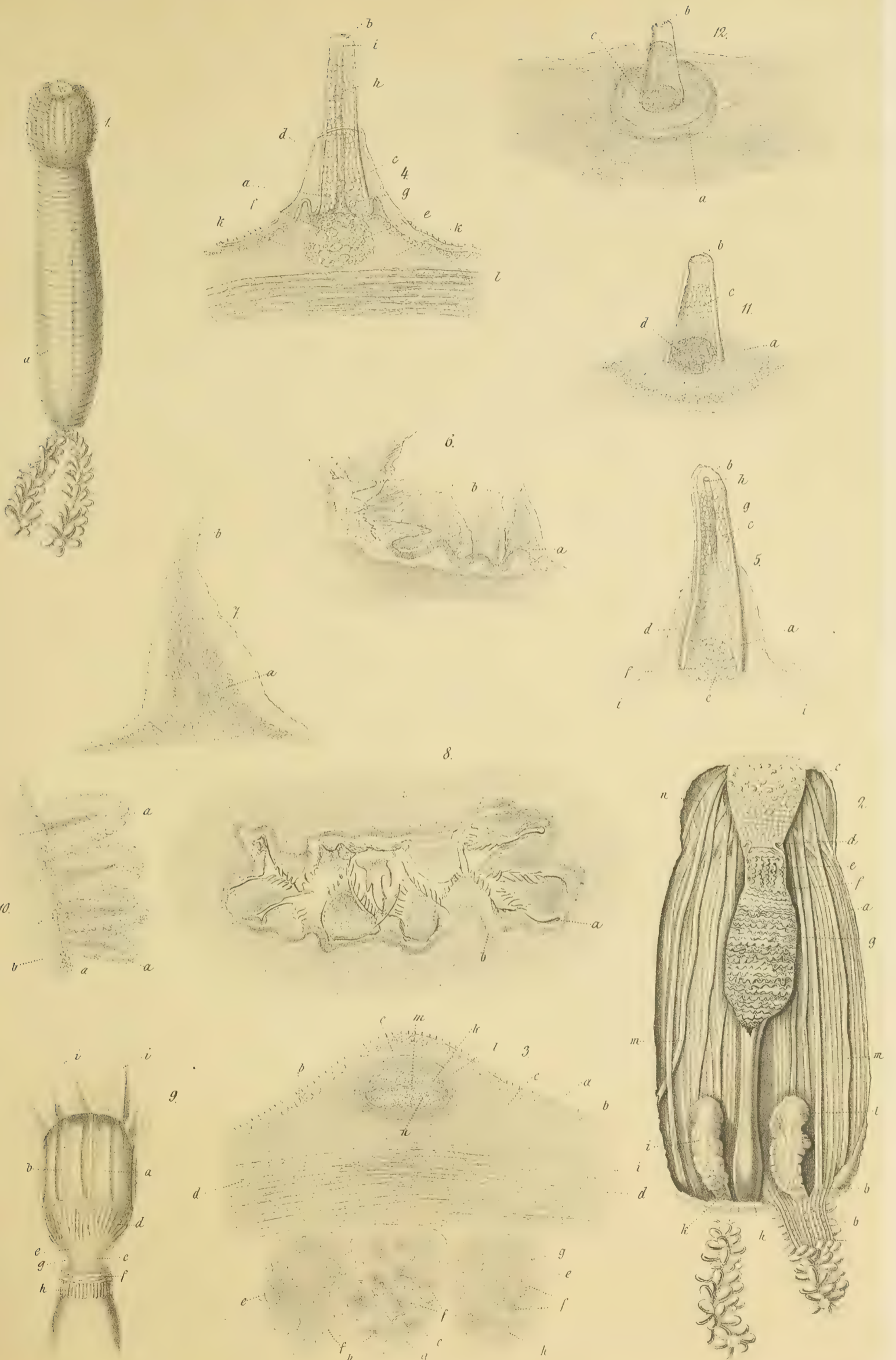
|| Page 1, line 9, from top of page, for '2 families' read 1 'family.'



|| Sent in to the Editorial Committee June 18th 1880.

Translated into English by **John Hazeland.**






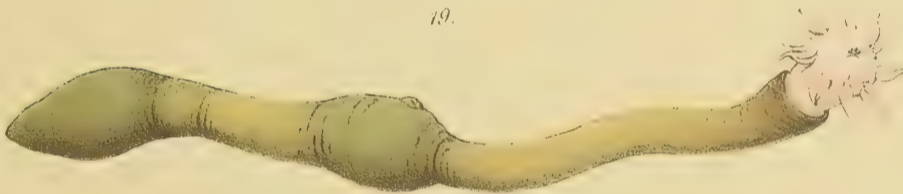





20.



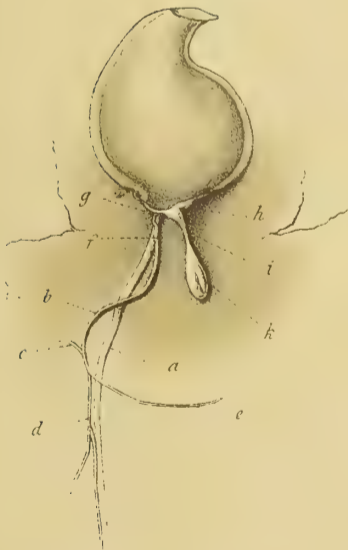19.




21.




15.



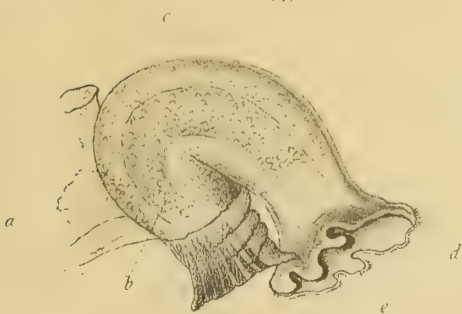4.



9.



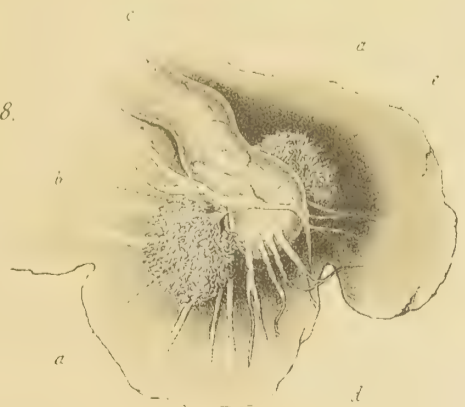
17.

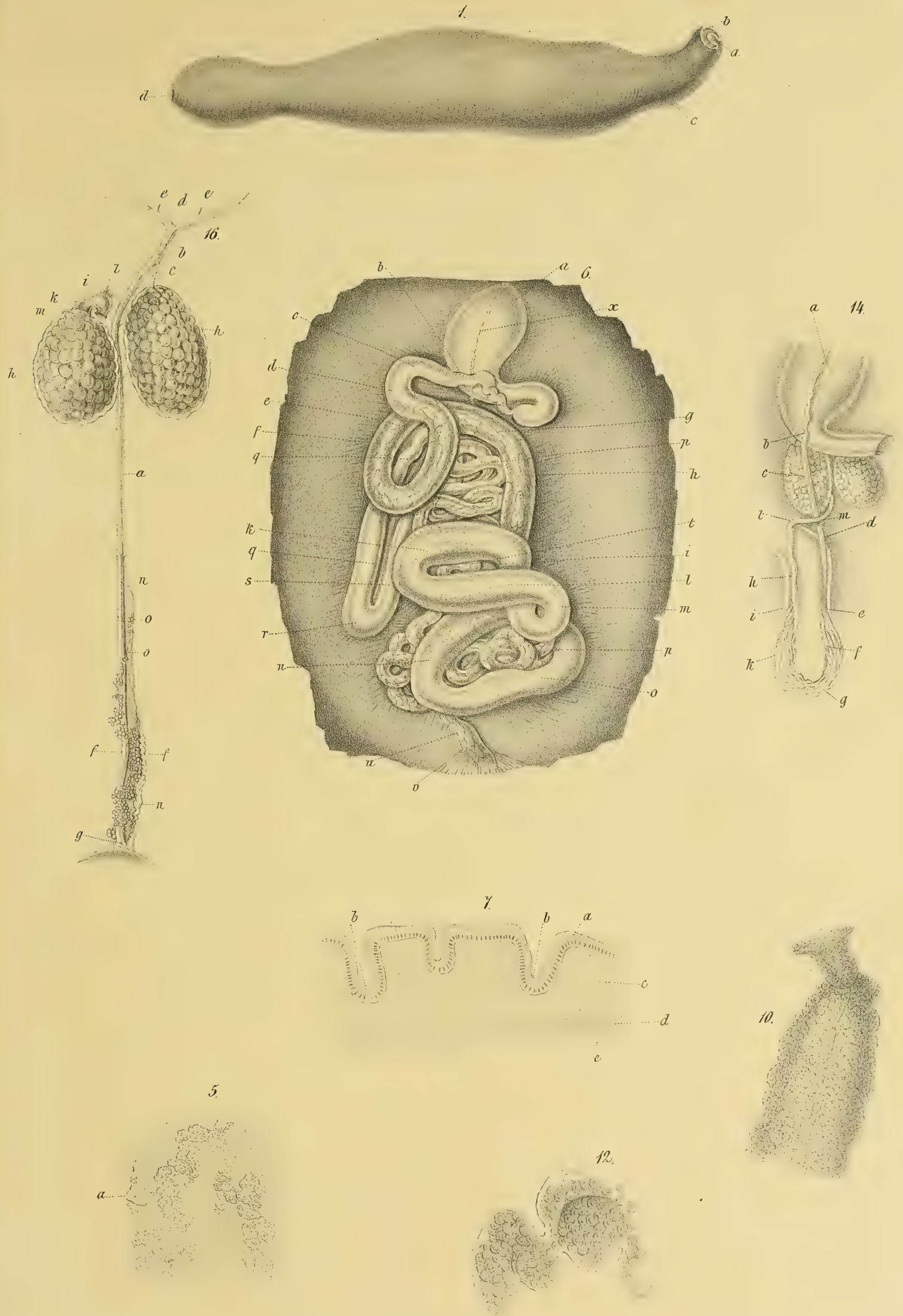


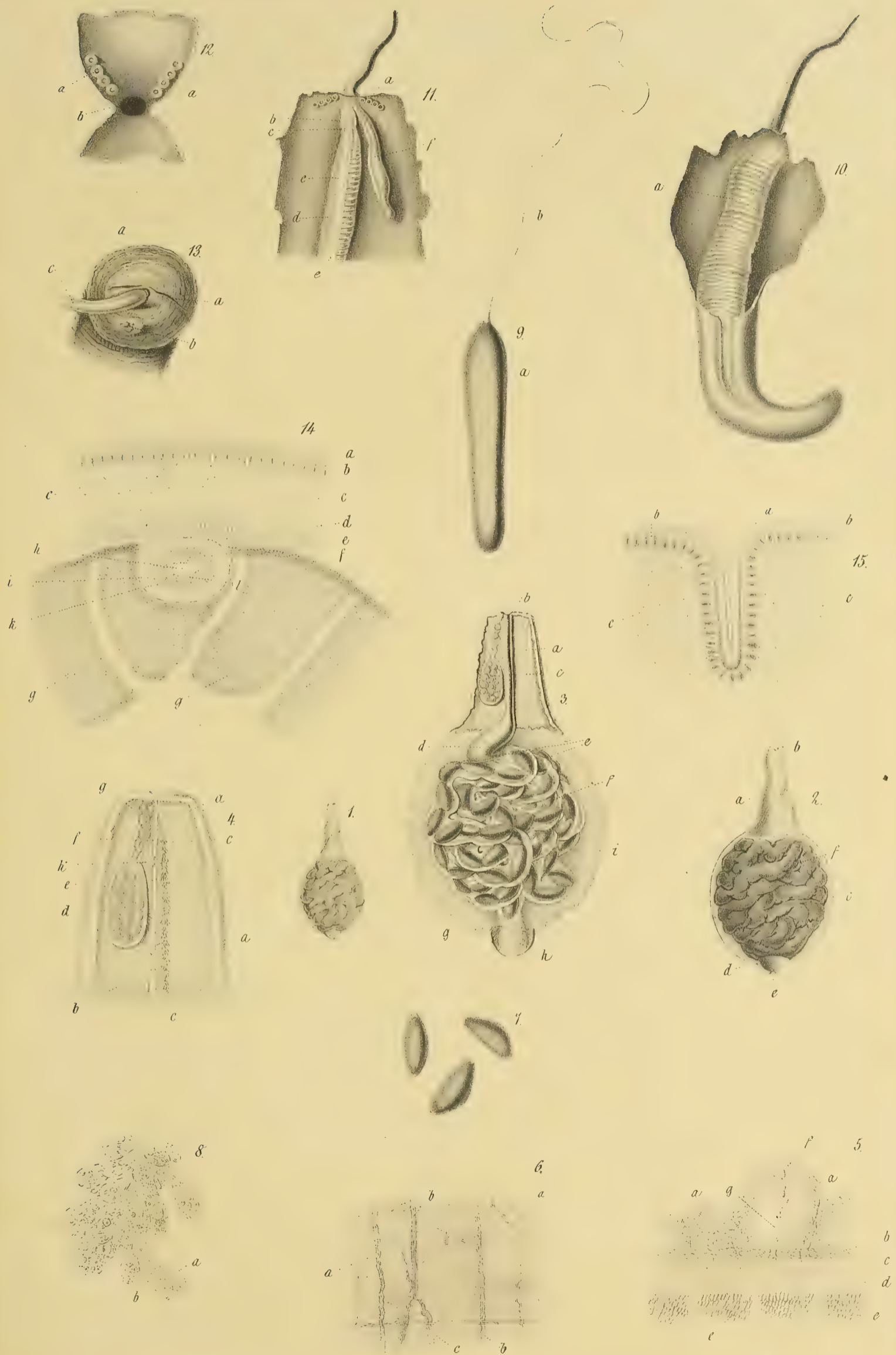
11.

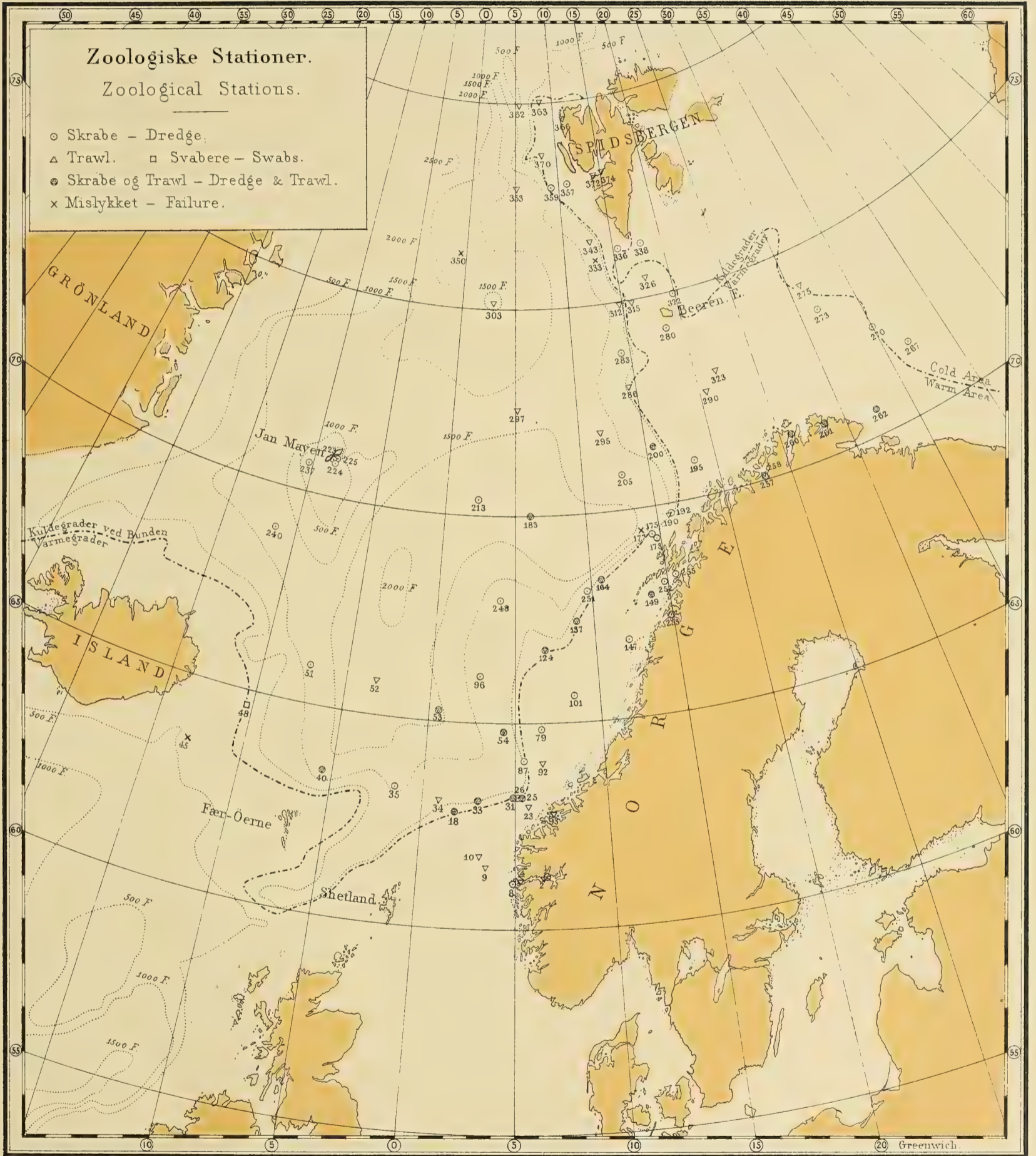


8.









THE NORWEGIAN NORTH-ATLANTIC EXPEDITION

1876—1878.

III.

ZOOLOGY.

GEPHYREA,

BY

D. C. DANIELSSEN AND JOHAN KOREN.

WITH 6 PLATES AND 1 MAP.



CHRISTIANIA.

PRINTED BY GRØNDAHL & SØN.

1881.

DEN NORSKE NORDHAVS-EXPEDITION

1876—1878.

C H E M I.

- I. OM LUFTEN I SØVANDET.
- II. OM KULSYREN I SØVANDET.
- III. OM SALTHOLDIGHEDEN AF VANDET
I DET NORSKE NORDHAV.

AF

HERCULES TORNØE.

MED 3 TRÆSNIT OG 3 KARTER.



CHRISTIANIA.

GRØNDAHL & SØNS BOGTRYKKERI.

1880.

DEN NORSKE NORDHAVS-EXPEDITION

1876—1878.

ZOOLOGI.

FISKE,

VED

ROBERT COLLETT.

MED 5 PLANCHER, 3 TRÆSNIT, OG 1 KART.



CHRISTIANIA.

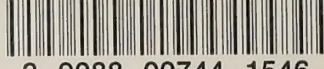GRØNDAHL & SØNS BOGTRYKKERI.

1880.





SMITHSONIAN INSTITUTION LIBRARIES



3 9088 00744 1546